

BRS
BOARD REVIEW SERIES

Neuroanatomy

FIFTH EDITION

Douglas J. Gould

Outline format highlights the most tested topics for USMLE Step 1

More than 575 board-style questions help test your memorization and mastery

Online access—offers greater study flexibility



Wolters Kluwer
Health

Lippincott
Williams & Wilkins

BRS
BOARD REVIEW SERIES

Neuroanatomy

FIFTH EDITION



Neuroanatomy

FIFTH EDITION

Douglas J. Gould, Ph.D.

Professor

Department of Biomedical Sciences

Oakland University William Beaumont School of Medicine

Rochester, Michigan

Author of 1st–4th Editions:

James D. Fix, PhD

(1931–2010)



Wolters Kluwer | Lippincott Williams & Wilkins

Health

Philadelphia • Baltimore • New York • London
Buenos Aires • Hong Kong • Sydney • Tokyo

Acquisitions Editor: Crystal Taylor
Product Manager: Catherine Noonan
Marketing Manager: Joy Fisher-Williams
Designer: Holly Reid McLaughlin
Compositor: S4Carlisle Publishing Services

Fifth Edition

Copyright © 2014, 2008, 2002, 1995 Lippincott Williams & Wilkins, a Wolters Kluwer business.

351 West Camden Street
Baltimore, MD 21201

Two Commerce Square
2001 Market Street
Philadelphia, PA 19103

Printed in China

All rights reserved. This book is protected by copyright. No part of this book may be reproduced or transmitted in any form or by any means, including as photocopies or scanned-in or other electronic copies, or utilized by any information storage and retrieval system without written permission from the copyright owner, except for brief quotations embodied in critical articles and reviews. Materials appearing in this book prepared by individuals as part of their official duties as US government employees are not covered by the above-mentioned copyright. To request permission, please contact Lippincott Williams & Wilkins at 2001 Market Street, Philadelphia, PA 19103, via email at permissions@lww.com, or via website at lww.com (products and services).

Library of Congress Cataloging-in-Publication Data

Gould, Douglas J., author.

Neuroanatomy / Douglas J. Gould.—5th edition.

p. ; cm. — (Board review series)

Revised edition of: Neuroanatomy / James D. Fix. 4th ed. c2008.

Includes bibliographical references and index.

ISBN-13: 978-1-4511-7609-4

ISBN-10: 1-4511-7609-0

I. Fix, James D. Neuroanatomy. Revision of (work): II. Title. III. Series: Board review series.

[DNLM: 1. Neuroanatomy—Examination Questions. 2. Neuroanatomy—Outlines. WL 18.2]

QM451

611'.8076—dc23

2013005723

DISCLAIMER

Care has been taken to confirm the accuracy of the information present and to describe generally accepted practices. However, the authors, editors, and publisher are not responsible for errors or omissions or for any consequences from application of the information in this book and make no warranty, expressed or implied, with respect to the currency, completeness, or accuracy of the contents of the publication. Application of this information in a particular situation remains the professional responsibility of the practitioner; the clinical treatments described and recommended may not be considered absolute and universal recommendations.

The authors, editors, and publisher have exerted every effort to ensure that drug selection and dosage set forth in this text are in accordance with the current recommendations and practice at the time of publication. However, in view of ongoing research, changes in government regulations, and the constant flow of information relating to drug therapy and drug reactions, the reader is urged to check the package insert for each drug for any change in indications and dosage and for added warnings and precautions. This is particularly important when the recommended agent is a new or infrequently employed drug.

Some drugs and medical devices presented in this publication have Food and Drug Administration (FDA) clearance for limited use in restricted research settings. It is the responsibility of the health care provider to ascertain the FDA status of each drug or device planned for use in their clinical practice.

To purchase additional copies of this book, call our customer service department at **(800) 638-3030** or fax orders to **(301) 223-2320**. International customers should call **(301) 223-2300**.

Visit Lippincott Williams & Wilkins on the Internet: <http://www.lww.com>. Lippincott Williams & Wilkins customer service representatives are available from 8:30 am to 6:00 pm, EST.

9 8 7 6 5 4 3 2 1

To Marie for her love, patience, wisdom, and understanding.

To Maggie and Lulu for all the joy they bring.



Reviewers

Marc Braunstein

Merrian Brooks

Christos Constantinidis, PhD

James L. Culberson, PhD

David Crawley

Ana C.G. Felix, MD

Karan Gulaya

Douglas James

Shonda Janke

Amelia Keaton

Kathleen M. Klueber, PhD

Albert Lamperti, PhD

Stephanie Markle

Fiore Mastroianni

Sidney L. Palmer, PhD

Sheree Perron

Nicholas Potvin

Libby Rhee

Amy Shah

Ricci Sylla

Penny Toliopoulos

Anne Williams



Preface

BRS Neuroanatomy, fifth edition, is a concise review of human neuroanatomy intended for health professions students including medical and dental students preparing for the United States Medical Licensing Examination (USMLE) Step 1 and other examinations. It presents the essentials of human neuroanatomy in a concise, tightly-outlined, well-illustrated format. There are more than 600 board-type questions with complete answers and explanations, some included at the end of each chapter and some in a comprehensive examination at the end of the book.

NEW TO THIS EDITION

- Color used throughout to enhance neuroanatomic pathways
- Color used to block in tables and highlight clinical correlations
- Localization of sensory disorders
- Updated color artwork throughout
- Updated terminology to conform with Terminologia Anatomica

To the Student

To make the most of this book, carefully study the illustrations, computed tomography scans, magnetic resonance images, angiograms as well as the figure legends; much of the board question information lies within the images and legends. The answers to at least 30 common USMLE questions are outlined below; refer to these tips as you review the chapters.



Acknowledgments

Special thanks to and in respectful memory of **Dr. James Fix**, for creating the first four editions of *BRS Neuroanatomy*—the foundation upon which this fifth edition is based. I thank my students and colleagues for their valuable input as the fifth edition was developed. I also thank the Lippincott Williams & Wilkins staff and their associates for their contributions to this edition—Crystal Taylor, Acquisitions Editor; Catherine Noonan, Managing Editor; and the student and faculty reviewers, who were invited by the publisher to provide valuable feedback and suggestions.

Contents

Reviewers vi

Preface vii

Acknowledgments viii

1. GROSS ANATOMY OF THE BRAIN 1

Objectives 1

- I. Introduction 1
- II. Divisions of the Brain 1
- III. Atlas of the Brain and Brainstem 10

Review Test 22

2. MENINGES AND CEREBROSPINAL FLUID 24

Objectives 24

- I. Meninges 24
- II. Ventricles 28
- III. Cerebrospinal Fluid 30
- IV. Hydrocephalus 30
- V. Meningitis 31
- VI. Herniation 32
- VII. Circumventricular Organs 34

Review Test 36

3. BLOOD SUPPLY OF THE CENTRAL NERVOUS SYSTEM 39

Objectives 39

- I. Arteries of the Spinal Cord 39
- II. Venous Drainage of the Spinal Cord 40
- III. Arteries of the Brain 41
- IV. Cerebral Arterial Circle (of Willis) 45
- V. Meningeal Arteries 45
- VI. Veins of the Brain 45
- VII. Venous Dural Sinuses 46
- VIII. Angiography 48
- IX. Intracranial Hemorrhage 52

Review Test 54

4. DEVELOPMENT OF THE NERVOUS SYSTEM 58

Objectives 58

- I. Overview 58
- II. Development of the Neural Tube 58
- III. Neural Crest 59
- IV. Placodes 61
- V. Stages of Neural Tube Development 61
- VI. Spinal Cord (Medulla Spinalis) 63
- VII. Medulla oblongata (Myelencephalon) 64
- VIII. Metencephalon 66
- IX. Mesencephalon (Midbrain) 67
- X. Development of the Diencephalon, Optic Structures, and Hypophysis 68
- XI. Development of the Telencephalon 70
- XII. Congenital Malformations of the Central Nervous System 71

Review Test 77

5. NEUROHISTOLOGY 79

Objectives 79

- I. Overview 79
- II. Neurons 79
- III. Neuroglia 82
- IV. Nerve Cell Degeneration and Regeneration 86
- V. Axonal Transport 87
- VI. Capillaries of the Central Nervous System 87
- VII. Sensory Receptors 89

Review Test 91

6. SPINAL CORD 93

Objectives 93

- I. Introduction 93
- II. External Morphology 93
- III. Internal Morphology 98
- IV. Myotatic Reflex 101

Review Test 102

7. TRACTS OF THE SPINAL CORD 104

Objectives 104

- I. Ascending Tracts 104
- II. Descending Tracts 109
- III. Integrative Pathways 111
- IV. Clinical Correlations 112

Review Test 114

8. LESIONS OF THE SPINAL CORD 117

Objectives 117

- I. Lower Motor Neuron Lesions 117
- II. Upper Motor Neuron Lesions (UMNs) 119
- III. Sensory Pathway Lesions 119
- IV. Peripheral Nervous System Lesions 120
- V. Combined Upper and Lower Motor Neuron Lesions 120
- VI. Combined Motor and Sensory Lesions 121
- VII. Intervertebral Disk Herniation 124

Review Test 125

9. BRAINSTEM 129

Objectives 129

- I. Introduction 129
- II. Medulla Oblongata (Myelencephalon) 129
- III. Pons 134
- IV. Mesencephalon (Midbrain) 138
- V. Corticobulbar (Corticonuclear) Fibers 142

Review Test 143

10. CRANIAL NERVES 145

Objectives 145

- I. Introduction 145
- II. Nervus Terminalis (NT; Cranial Nerve 0) 145
- III. Olfactory Nerve (CN I) 145
- IV. Optic Nerve (CN II) 146
- V. Oculomotor Nerve (CN III) 148
- VI. Trochlear Nerve (CN IV) 149
- VII. Trigeminal Nerve (CN V) 150
- VIII. Abducent Nerve (CN VI) 151
- IX. Facial Nerve (CN VII) 151
- X. Vestibulocochlear Nerve (CN VIII) 154
- XI. Glossopharyngeal Nerve (CN IX) 154
- XII. Vagal Nerve (CN X) 155
- XIII. Accessory Nerve (CN XI) 156
- XIV. Hypoglossal Nerve (CN XII) 157

Review Test 159

11. TRIGEMINAL SYSTEM 162

Objectives 162

- I. Trigeminal Nerve (CN V) 162
- II. Ascending Trigeminothalamic Tracts 163

- III. Trigeminal Sensory Nuclei 165
- IV. Trigemino cerebellar Fibers 166
- V. Trigeminal Reflexes 167
- VI. Clinical Correlations 168

Review Test 170

12. LESIONS OF THE BRAINSTEM

172

Objectives 172

- I. Introduction 172
- II. Vascular Lesions of the Medulla 172
- III. Vascular Lesions of the Pons 173
- IV. Lesions of the Midbrain 175
- V. Acoustic Neuroma (Schwannoma) 176
- VI. Internuclear Ophthalmoplegia 177
- VII. Jugular Foramen (Vernet) Syndrome 177
- VIII. Subclavian Steal Syndrome 178

Review Test 179

13. DIENCEPHALON: THALAMUS AND HYPOTHALAMUS

183

Objectives 183

- I. Introduction: The Thalamus 183
- II. Boundaries of the Thalamus 183
- III. Primary Thalamic Nuclei and their Major Connections 184
- IV. Blood Supply of the Thalamus 187
- V. Internal Capsule 187
- VI. Blood Supply of the Internal Capsule 188
- VII. Clinical Correlations 188
- VIII. Overview: The Hypothalamus 189
- IX. Surface Anatomy of the Hypothalamus 189
- X. Hypothalamic Regions and Nuclei 189
- XI. Major Hypothalamic Connections 192
- XII. Major Fiber Systems 194
- XIII. Functional Considerations 195
- XIV. Clinical Correlations 196

Review Test 197

14. AUDITORY SYSTEM

202

Objectives 202

- I. Introduction 202
- II. Outer, Middle, and Inner Ear 202
- III. Auditory Pathway 204
- IV. Efferent Cochlear (Olivocochlear) Bundle 206
- V. Hearing Defects 206

VI. Tuning Fork Tests 207

VII. Brainstem Auditory Evoked Response (Baer) 207

Review Test 209

15. VESTIBULAR SYSTEM

211

Objectives 211

I. Introduction 211

II. Labyrinth 211

III. Vestibular Pathways 213

IV. Efferent Vestibular Connections 214

V. Medial Longitudinal Fasciculus 214

VI. Vestibulo-Ocular Reflexes 215

VII. Decerebrate and Decorticate Rigidity 216

VIII. Clinical Correlations 216

Review Test 218

16. VISUAL SYSTEM

220

Objectives 220

I. Introduction 220

II. The Retina 220

III. Visual Pathway 224

IV. Pupillary Light Reflexes and Pathway 225

V. Pupillary Dilation Pathway 227

VI. The Convergence–Accommodation Reaction 227

VII. Centers for Ocular Motility 228

VIII. Clinical Correlations 229

Review Test 232

17. OLFACTORY, GUSTATORY, AND LIMBIC SYSTEMS

236

Objectives 236

I. Olfactory System 236

II. Gustatory System 237

III. Limbic System 239

Review Test 245

18. BASAL NUCLEI AND THE EXTRAPYRAMIDAL MOTOR SYSTEM

249

Objectives 249

I. Basal Nuclei 249

II. Extrapyrmidal Motor System 249

Review Test 256

19. CEREBELLUM 258

Objectives 258

- I. Overview 258
- II. Major Divisions of the Cerebellum 258
- III. Cerebellar Cortex 260
- IV. Major Cerebellar Pathways 262
- V. Cerebellar Dysfunction 264
- VI. Cerebellar Lesions 264

Review Test 266

20. AUTONOMOUS NERVOUS SYSTEM 268

Objectives 268

- I. Overview 268
- II. Divisions of the Autonomic Nervous System 268
- III. Visceral Afferent Fibers and Pain 272
- IV. Autonomic Innervation of Selected Organs 273
- V. Clinical Correlations 275

Review Test 276

21. NEUROTRANSMITTERS AND PATHWAYS 278

Objectives 278

- I. Introduction 278
- II. Acetylcholine 279
- III. Dopamine 280
- IV. Norepinephrine (Noradrenalin) 281
- V. Serotonin (5-Hydroxytryptamine [5-HT]) 282
- VI. Opioid Peptides 283
- VII. Nonopioid Neuropeptides 284
- VIII. Amino Acids 284
- IX. Nitric Oxide 287
- X. Functional and Clinical Correlations 287

Review Test 289

22. CEREBRAL CORTEX 293

Objectives 293

- I. Overview 293
- II. Neocortex 293
- III. Functional Areas of the Cerebral Cortex 294
- IV. Cerebral Dominance 299
- V. Split-Brain Syndrome 301
- VI. Blood Supply to the Major Functional Cortical Areas 302

- VII. Apraxia 303
- VIII. Aphasia 304
- IX. Dysprosodies 305

Review Test 306

Comprehensive Examination 311

Appendix: Table of Cranial Nerves 339

Glossary 342

Index 353

Gross Anatomy of the Brain

Objectives

- Identify the major structures of the brain from typical brain sections and diagrams—use the Atlas of the Brain and Brainstem on p. 10.
- Describe the telencephalon including the lobes of the cerebral hemispheres and the major gyri of each.
- Differentiate the structures of the limbic and olfactory senses from other parts of the brain.
- List the different parts of the diencephalon, brainstem, and cerebellum.

I. INTRODUCTION

- part of the central nervous system (CNS) that lies within the cranial vault—the **encephalon**. Its surface is convoluted and exhibits **gyri** and **sulci**.
- consists of the **cerebrum** (cerebral hemispheres and diencephalon), the **brainstem** (midbrain, pons, and medulla), and the **cerebellum**.
- weighs 350 g in the newborn and 1400 g in the adult.
- covered by three connective tissue membranes, the **meninges**.
- surrounded by **cerebrospinal fluid (CSF)** that supports it and protects it from trauma.

II. DIVISIONS OF THE BRAIN

The brain is classified into six postembryonic divisions: **telencephalon**, **diencephalon**, **mesencephalon**, **pons**, **medulla oblongata**, and **cerebellum**.

A. Telencephalon

- consists of the **cerebral hemispheres** and the **basal nuclei**. The cerebral hemispheres contain the **lateral ventricles**.
 1. **Cerebral hemispheres** (Figures 1.1 through 1.5)
 - separated by the longitudinal cerebral fissure and the falx cerebri.
 - interconnected by commissural fiber bundles (i.e., corpus callosum).
 - consists of six lobes and the olfactory structures:
 - a. **Frontal lobe** (see Figures 1.3 and 1.4)
 - extends from the central sulcus to the frontal pole.
 - lies superior to the lateral sulcus and anterior to the central sulcus.
 - made up of the following gyri:
 - (1) **Precentral gyrus**
 - consists of the primary motor area (area 4).

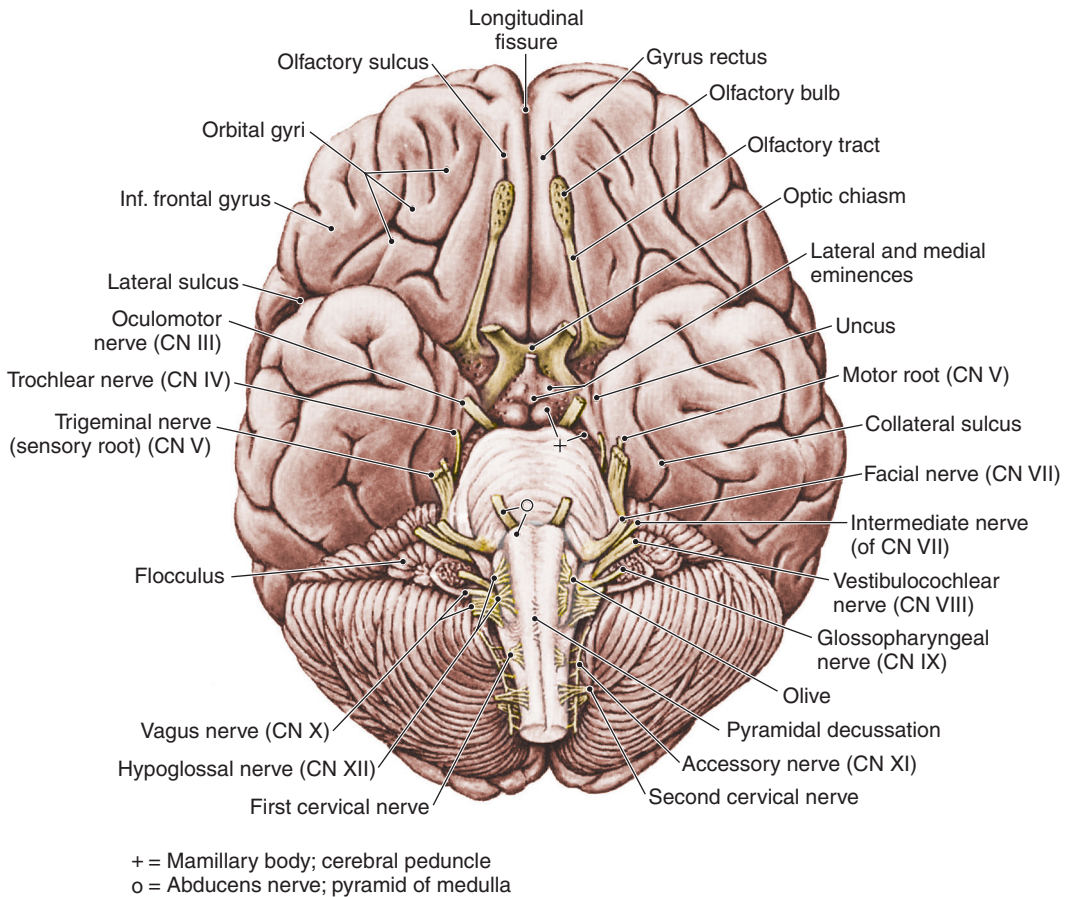


FIGURE 1.1. Base of the brain. (Modified from Truex RC, Kellner CE. *Detailed Atlas of the Head and Neck*. New York, NY: Oxford University Press; 1958:34.)

(2) Superior frontal gyrus

- contains supplementary motor cortex on the medial surface (area 6).

(3) Middle frontal gyrus

- contains the frontal eye field (area 8).

(4) Inferior frontal gyrus

- contains the Broca speech area in the dominant hemisphere (areas 44 and 45).

(5) Gyrus rectus and orbital gyri

- separated by the olfactory sulcus.

(6) Anterior paracentral lobule

- found on the medial surface between the superior frontal gyrus (paracentral sulcus) and the central sulcus.
- represents a continuation of the precentral gyrus on the medial surface.

b. Parietal lobe (see Figures 1.3 through 1.5)

- extends from the central sulcus to the occipital lobe and lies superior to the temporal lobe.
- contains the following lobules and gyri:

(1) Postcentral gyrus

- the primary somatosensory area of the cerebral cortex (areas 3, 1, and 2).

(2) Superior parietal lobule

- comprises association areas involved in somatosensory functions (areas 5 and 7).

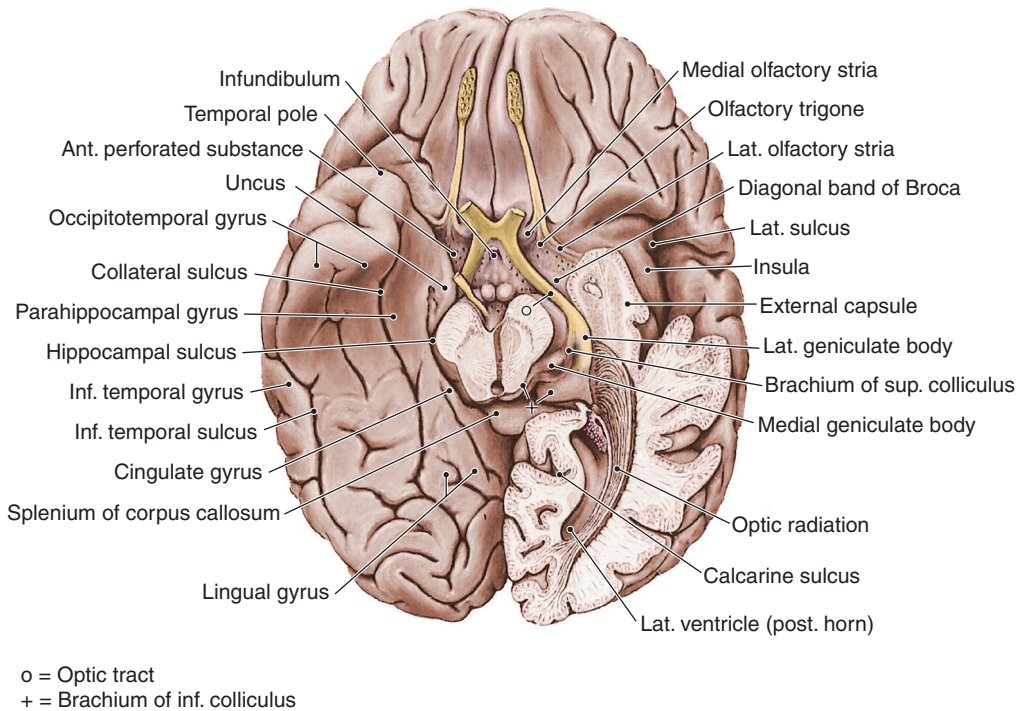


FIGURE 1.2. Inferior surface of the brain showing the principal gyri and sulci. The left hemisphere has been dissected to show the visual pathways and relation of the optic radiation to the lateral ventricle. (Modified from Truex RC, Kellner CE. *Detailed Atlas of the Head and Neck*. New York, NY: Oxford University Press; 1958:46.)

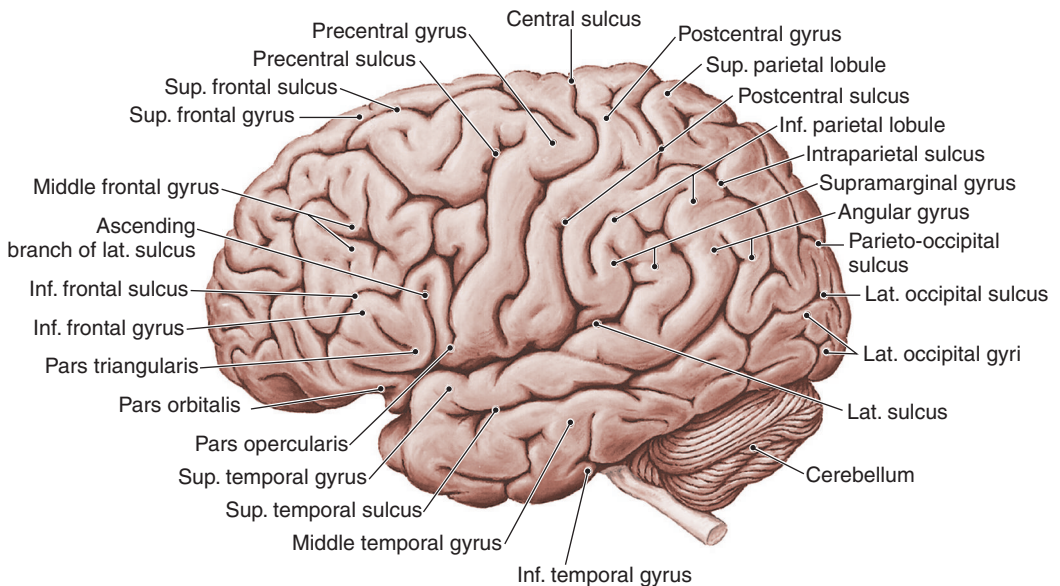
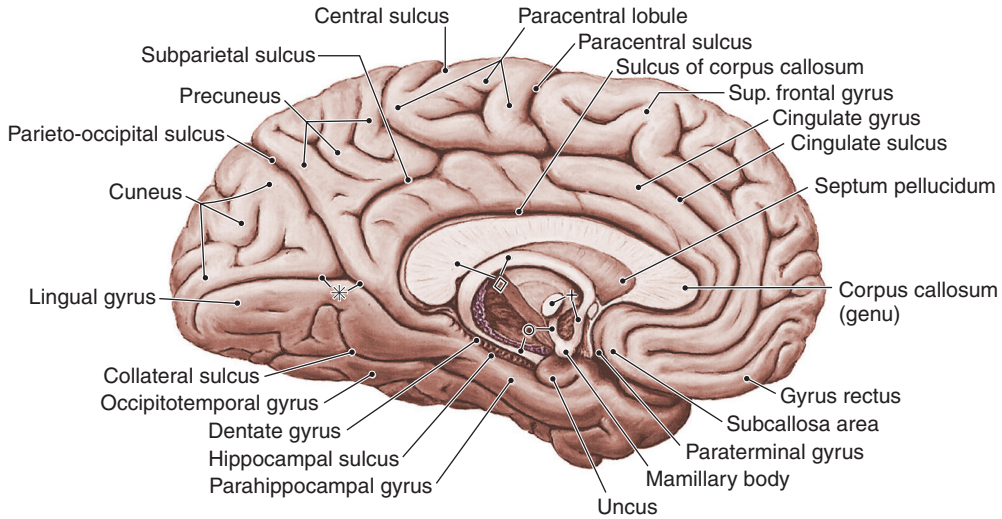


FIGURE 1.3. Lateral surface of the brain showing the principal gyri and sulci. (Modified from Truex RC, Kellner CE. *Detailed Atlas of the Head and Neck*. New York, NY: Oxford University Press; 1958:47.)



* = Calcarine fissure

◇ = Splenium of corpus callosum; body of fornix

+ = Interthalamic adhesion; ant. column of fornix

o = Fimbria of fornix; mamillothalamic tract

FIGURE 1.4. Medial surface of the brain showing the principal gyri and sulci. Parts of the thalamus and hypothalamus have been removed to show the fimbria and anterior column of the fornix and the mamillothalamic tract. (Modified from Truex RC, Kellner CE. *Detailed Atlas of the Head and Neck*. New York, NY: Oxford University Press; 1958:49.)

(3) Inferior parietal lobule

- **Supramarginal gyrus**

- (a) interrelates somatosensory, auditory, and visual inputs (area 40).

- **Angular gyrus** (area 39)

- (a) receives impulses from primary visual cortex.

(4) Precuneus

- located between the paracentral lobule and the cuneus.

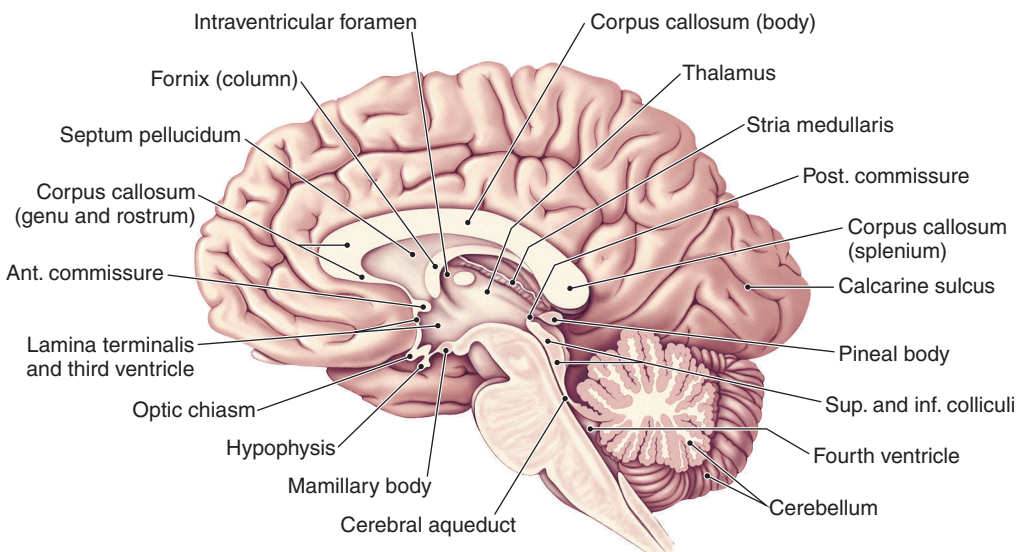


FIGURE 1.5. Midsagittal section of the brain and brainstem showing the structures surrounding the third and fourth ventricles. (Modified from Bear MF, Connors BW, Paradiso MA: *Neuroscience: Exploring the Brain*. 3rd ed. Baltimore, MD: Lippincott Williams & Wilkins; 2007:207.)

- (5) **Posterior paracentral lobule**
- located on the medial surface between the central sulcus and the precuneus.
 - represents a continuation of the postcentral gyrus on the medial surface.
- c. **Temporal lobe** (see Figures 1.2 through 1.4)
- extends from the temporal pole to the occipital lobe, lying inferior to the lateral sulcus.
 - extends from the lateral sulcus to the collateral sulcus.
 - contains the following gyri:
 - (1) **Transverse temporal gyri of Heschl**
 - found within the lateral sulcus.
 - extends from the superior temporal gyrus toward the medial geniculate body (Figure 1.6).
 - the primary auditory areas of the cerebral cortex (areas 41 and 42).
 - (2) **Superior temporal gyrus**
 - associated with auditory functions.
 - contains the **Wernicke speech area** in the dominant hemisphere (area 22).
 - contains the planum temporale on its superior (hidden) surface.
 - (3) **Middle temporal gyrus**
 - (4) **Inferior temporal gyrus**
 - (5) **Lateral occipitotemporal gyrus (fusiform gyrus)**
 - lies between the inferior temporal sulcus and the collateral sulcus.
- d. **Occipital lobe** (see Figures 1.3 through 1.5)
- lies posterior to a line connecting the parieto-occipital sulcus and the preoccipital notch.

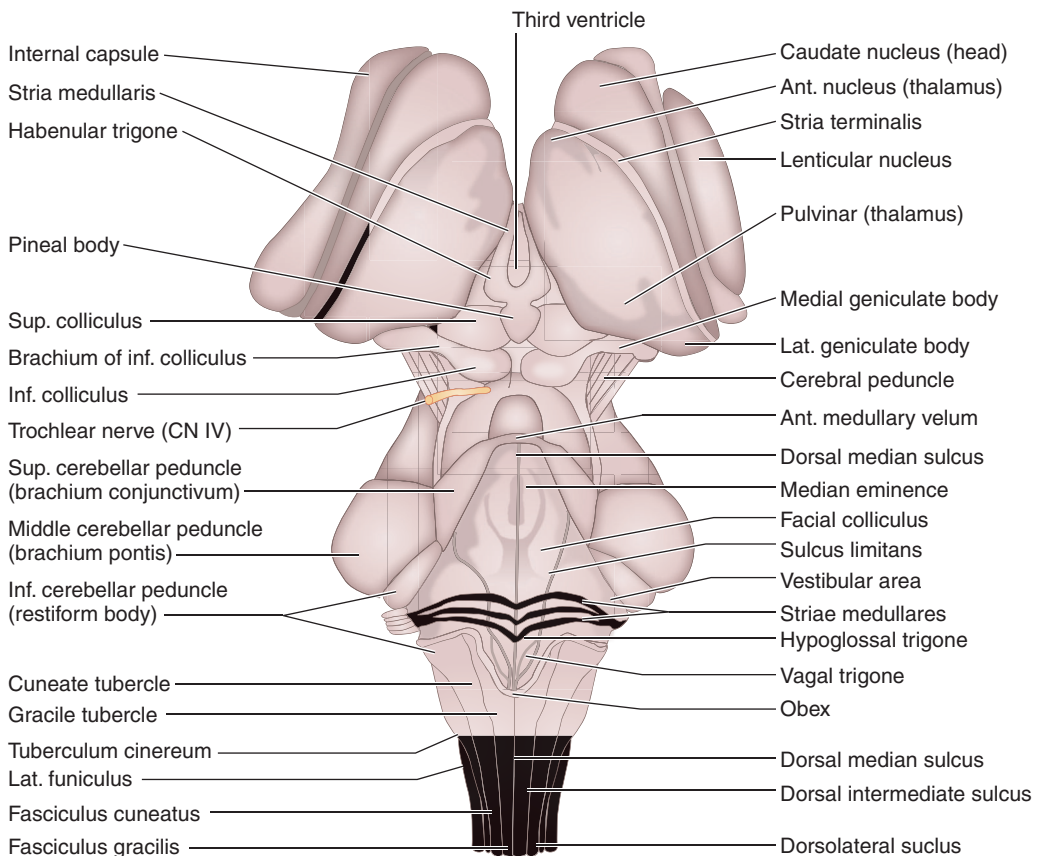


FIGURE 1.6. Posterior surface anatomy of the brainstem. The cerebellum has been removed to show the three cerebellar peduncles and the floor of the fourth ventricle (rhomboid fossa). (Modified from Truex RC, Carpenter MB. *Human Neuroanatomy*. Baltimore, MD: Williams & Wilkins; 1969:31.)

- contains two structures:
 - (1) **Cuneus**
 - situated between the parieto-occipital sulcus and the calcarine sulcus.
 - contains the visual cortex (areas 17, 18, and 19).
 - (2) **Lingual gyrus**
 - lies inferior to the calcarine sulcus.
 - contains the visual cortex (areas 17, 18, and 19).
- e. **Insular lobe** (insula) (see Figure 1.2)
 - lies within the lateral sulcus.
 - has short and long gyri.
- f. **Limbic lobe** (see Figures 1.4 and 22.1B)
 - a C-shaped collection of structures found on the medial hemispheric surface that encircles the corpus callosum and the lateral aspect of the midbrain.
 - includes the following structures:
 - (1) **Paraterminal gyrus and subcallosal area** (see Figure 1.4)
 - located anterior to the lamina terminalis and inferior to the rostrum of the corpus callosum.
 - (2) **Cingulate gyrus**
 - parallel and superior to the corpus callosum.
 - merges with the parahippocampal gyrus.
 - (3) **Parahippocampal gyrus**¹
 - lies between the hippocampal and collateral sulci and terminates in the **uncus**.
 - (4) **Hippocampal formation** (see Figures 1.2 and 1.4)
 - lies between the choroidal and hippocampal fissures.
 - connected to the hypothalamus and septal area via the **fornix**.
 - includes three structures:
 - (a) **Dentate gyrus** (see Figure 1.4)
 - (b) **Hippocampus** and
 - (c) **Subiculum** (see Figure 17.5)
- g. **Olfactory structures** (see Figure 1.2)
 - found on the orbital surface of the brain and include the following:
 - (1) **Olfactory bulb and tract**
 - an outpouching of the telencephalon.
 - (2) **Olfactory bulb**
 - receives the olfactory nerve (CN I).
 - (3) **Olfactory trigone and striae**
 - (4) **Anterior perforated substance**
 - created by penetrating striate arteries.
 - (5) **Diagonal band of Broca** (see Figure 1.2)
 - interconnects the amygdaloid nucleus and the septal area.
- 2. **Basal nuclei (ganglia)** (Figure 1.7; see Figures 1.6 and 18.1)
 - constitute the subcortical nuclei of the telencephalon.
 - include the following structures:
 - a. **Caudate nucleus**
 - part of the striatum, together with the putamen.
 - b. **Putamen**
 - part of the striatum, together with the caudate nucleus.
 - part of the lentiform nucleus along with the globus pallidus.
 - c. **Globus pallidus**
 - part of the lentiform nucleus, together with the putamen.
 - d. **Subthalamic nucleus**
 - part of the diencephalon that functions with the basal nuclei.
- 3. **Lateral ventricles** (see Figure 2.4)
 - ependyma-lined cavities of the cerebral hemispheres.
 - contain **CSF** and **choroid plexus**.

¹Some authorities include the parahippocampal gyrus as a temporal lobe structure.

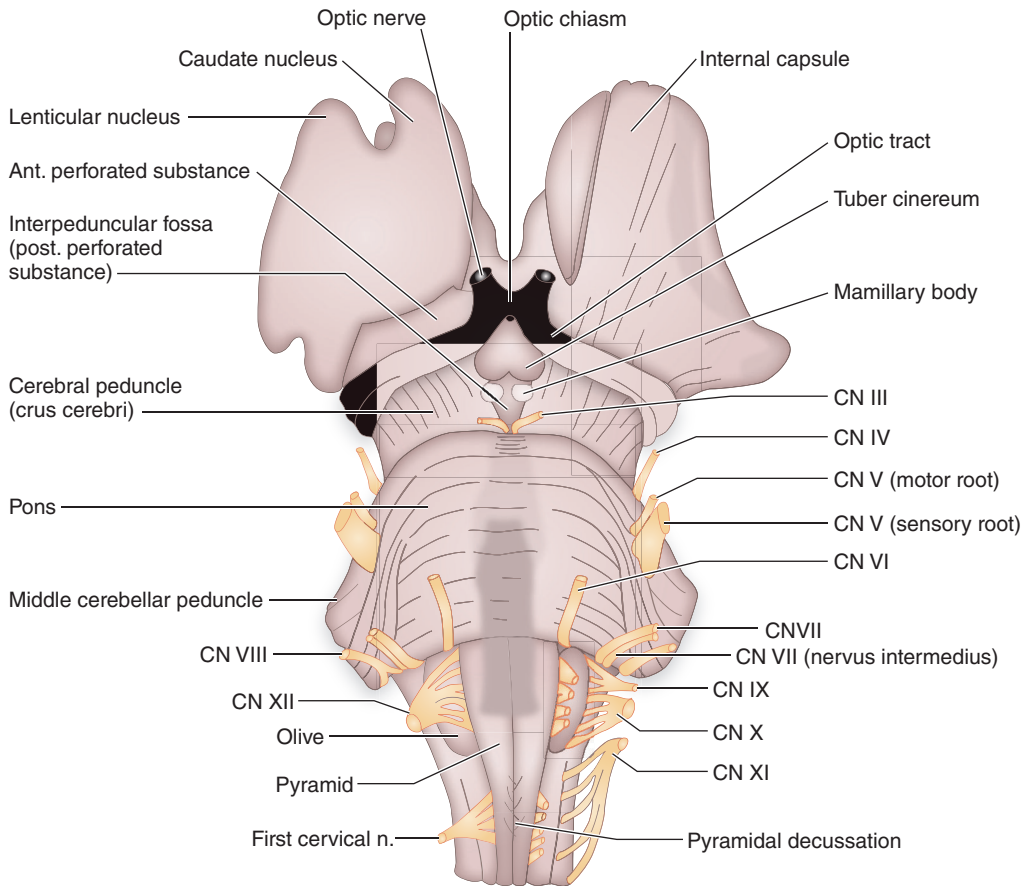


FIGURE 1.7. Anterior surface anatomy of the brainstem. (Modified from Truex RC, Carpenter MB. *Human Neuroanatomy*. Baltimore, MD: Williams & Wilkins; 1969:31.)

- communicate with the third ventricle via the two interventricular foramina (of Monro) (see Figure 2.3).
- separated from each other by the septum pellucidum.

4. Cerebral cortex

- consists of a thin layer or mantle of gray matter.
- covers the surface of each cerebral hemisphere.
- folded into gyri and separated by sulci.

5. White matter

- includes the cerebral commissures and the internal capsule.

a. Cerebral commissures (see Figures 1.4 and 1.5)

- interconnect the cerebral hemispheres and include the following structures:

(1) Corpus callosum

- the largest commissure of the brain.
- interconnects the two hemispheres.
- has four parts:
 - (a) Rostrum
 - (b) Genu
 - (c) Body and
 - (d) Splenium

(2) Anterior commissure

- located in the midsagittal section between the lamina terminalis and the column of the fornix.
- interconnects the olfactory bulbs with the middle and inferior temporal lobes.

(3) Hippocampal commissure (commissure of the fornix)

- located between the fornices and inferior to the splenium of the corpus callosum.

b. Internal capsule (see Figures 1.6, 1.7, and 13.3)

- consists of the white matter located between the basal nuclei and the thalamus.
- has five parts:

(1) Anterior limb

- located between the caudate nucleus and putamen.
- contains a mixture of ascending and descending fibers.

(2) Genu

- located between the anterior and posterior limbs.
- contains primarily the corticobulbar fibers.

(3) Posterior limb

- located between the thalamus and lentiform nucleus (comprising the putamen and the globus pallidus).
- primarily made up of corticospinal fibers.

(4) Retrolenticular portion

- located posterior to the lentiform nucleus.
- contains the optic radiations.

(5) Sublenticular portion

- located inferior to the lentiform nucleus.
- contains auditory radiations.

B. Diencephalon (see Figures 1.5 and 1.6)

- located between the telencephalon and mesencephalon and between the interventricular foramina and the posterior commissure.
- receives the optic nerve (CN II).
- consists of the epithalamus, thalamus, hypothalamus, subthalamus, and the third ventricle and its associated structures.

1. Epithalamus (see Figures 1.5 and 1.6)

- **Pineal body** (epiphysis cerebri)
- **Habenular trigone** (see Figure 1.6)
- **Medullary stria of the thalamus**
- **Posterior commissure**
 - a. mediates the consensual reaction of the pupillary light reflex.
- **Tela choroidea and choroid plexus of the third ventricle**

2. (Dorsal) Thalamus (see Figure 1.6)

- separated from the hypothalamus by the **hypothalamic sulcus**.
- the surface structures are as follows:
 - Pulvinar**
 - Metathalamus**
 - **Medial geniculate body** (auditory system)
 - **Lateral geniculate body** (visual system)
 - Anterior tubercle**
 - Interthalamic adhesion (massa intermedia)**

3. Hypothalamus (see Figures 1.1, 1.2, and 1.6)

- **Optic chiasm**
- **Mamillary bodies**
- **Infundibulum**
- **Tuber cinereum**

4. Subthalamus (ventral thalamus)

- lies inferior to the thalamus and lateral to the hypothalamus.
 - Subthalamic nucleus**
 - Zona incerta and fields of Forel** (see Figure 18.3)

5. Third ventricle and associated structures (see Figures 1.5 and 2.4)

- **Lamina terminalis**
 - results from closure of the cranial neuropore.

- **Tela choroidea**
- **Choroid plexus**
- **Interventricular foramen (of Monro)**
 - a. interconnects the lateral ventricle and the third ventricle.
- **Optic recess**
- **Infundibular recess**
- **Suprapineal recess**
- **Pineal recess**

C. Mesencephalon (midbrain) (see Figure 1.6)

- located between the diencephalon and the pons.
- extends from the posterior commissure to the frenulum of the superior medullary velum.
- contains the **cerebral aqueduct** interconnecting the third and fourth ventricles.
 1. **Anterior surface**
 - **Cerebral peduncle**
 - **Interpeduncular fossa**
 - a. **Oculomotor nerve (CN III)**
 - b. **Posterior perforated substance**
 - created by the penetrating branches of the posterior cerebral and posterior communicating arteries.
 2. **Posterior surface**
 - **Superior colliculus (visual system)**
 - **Brachium of the superior colliculus**
 - **Inferior colliculus (auditory system)**
 - **Brachium of the inferior colliculus**
 - **Trochlear nerve (CN IV)**
 - a. the only cranial nerve to exit the brainstem from the dorsal aspect.

D. Pons (see Figures 1.1 and 1.7)

- located between the midbrain and the medulla.
- extends from the inferior pontine sulcus to the superior pontine sulcus.
 1. **Anterior surface**
 - **Base of the pons**
 - **Cranial nerves**
 - a. **Trigeminal nerve (CN V)**
 - b. **Abducent nerve (CN VI)**
 - c. **Facial nerve (CN VII)**
 - d. **Vestibulocochlear nerve (CN VIII)**
 2. **Posterior surface (rhomboid fossa)**
 - **Locus ceruleus**
 - a. contains the largest collection of norepinephrinergic neurons in the CNS.
 - **Facial colliculus**
 - a. contains the abducent nucleus and internal genu of the facial nerve.
 - **Sulcus limitans**
 - a. separates the alar plate from the basal plate.
 - **Striae medullares of the rhomboid fossa**
 - a. divides the rhomboid fossa into the superior pontine portion and the inferior medullary portion.

E. Medulla oblongata (myelencephalon) (see Figures 1.1 and 1.7)

- located between the pons and the spinal cord.
- extends from the first cervical nerve (C1) to the inferior pontine sulcus (also called the pontobulbar sulcus).
 1. **Anterior surface**
 - **Pyramid**
 - a. contains descending tracts.

- **Olive**
 - a. contains the inferior olivary nucleus.
- **Cranial nerves**
 - a. **Glossopharyngeal nerve (CN IX)**
 - b. **Vagal nerve (CN X)**
 - c. **Accessory nerve (CN XI)²**
 - d. **Hypoglossal nerve (CN XII)**
- 2. **Posterior surface**
 - **Gracile tubercle**
 - **Cuneate tubercle**
 - **Rhomboid fossa (see Figure 1.6)**
 - a. **Striae medullares of the rhomboid fossa**
 - b. **Vagal trigone**
 - c. **Hypoglossal trigone**
 - d. **Sulcus limitans**
 - e. **Area postrema (vomiting center)**

F. Cerebellum (see Figures 1.1 and 1.5)

- located in the posterior cranial fossa.
- attached to the brainstem by three cerebellar peduncles.
- forms the roof of the fourth ventricle.
- separated from the occipital and temporal lobes by the **tentorium cerebelli**.
- consists of **folia** and **fissures** on its surface.
- contains the following surface structures/parts:
 1. **Hemispheres**
 - made up of two lateral lobes.
 2. **Vermis**
 - a midline structure.
 3. **Flocculus and vermal nodulus**
 - form the flocculonodular lobule.
 4. **Tonsil**
 - a rounded lobule on the inferior surface of each cerebellar hemisphere.
 - with increased intracranial pressure, it can herniate through the foramen magnum.
 5. **Superior cerebellar peduncle** (see Figure 1.6)
 - connects the cerebellum to the pons and midbrain.
 6. **Middle cerebellar peduncle** (see Figure 1.6)
 - connects the cerebellum to the pons.
 7. **Inferior cerebellar peduncle** (see Figure 1.6)
 - connects the cerebellum to the pons and medulla.
 8. **Anterior lobe**
 - lies anterior to the primary fissure.
 9. **Posterior lobe**
 - located between the primary and posterolateral fissures.
 10. **Flocculonodular lobe**
 - lies posterior to the posterolateral fissure.

III. ATLAS OF THE BRAIN AND BRAINSTEM (FIGURES 1.8 THROUGH 1.18)

- includes midsagittal, parasagittal, coronal, and axial sections of thick, stained brain slices.

²CN XI's fibers actually ascend from the cervical spinal cord (C1–C4), although the nerve appears to emerge from the medulla.

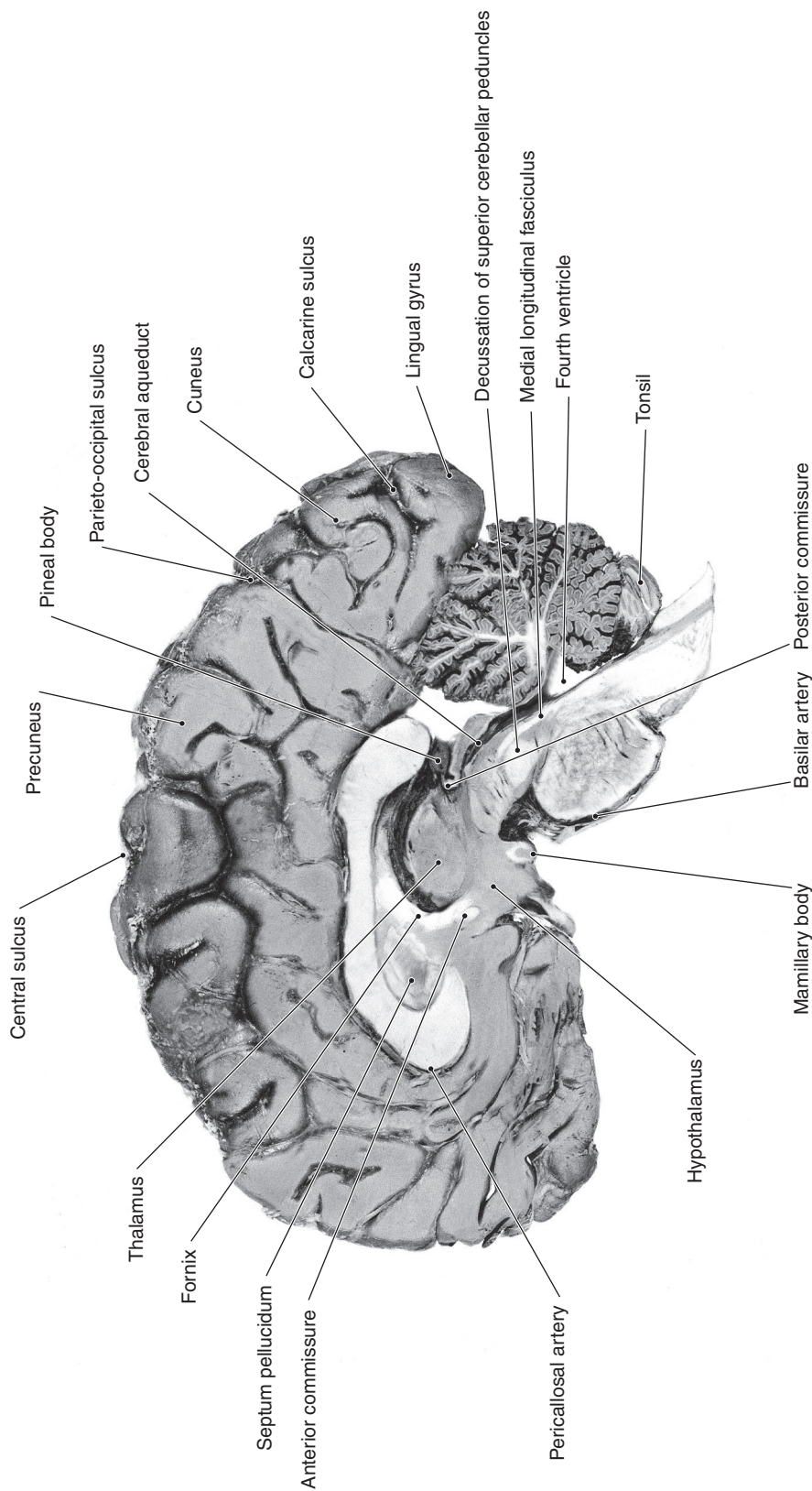


FIGURE 1.8. Midsagittal section of the brain with meninges and blood vessels intact. Arachnoid granulations are seen along the crest of the hemisphere. The posterior commissure, decussation of the superior cerebellar peduncles, and medial longitudinal fasciculus are well demonstrated. (Modified from Roberts M, Hanaway J, Morest DK. *Atlas of the Human Brain in Section*. 2nd ed. Philadelphia, PA: Lea & Febiger; 1987:85.)

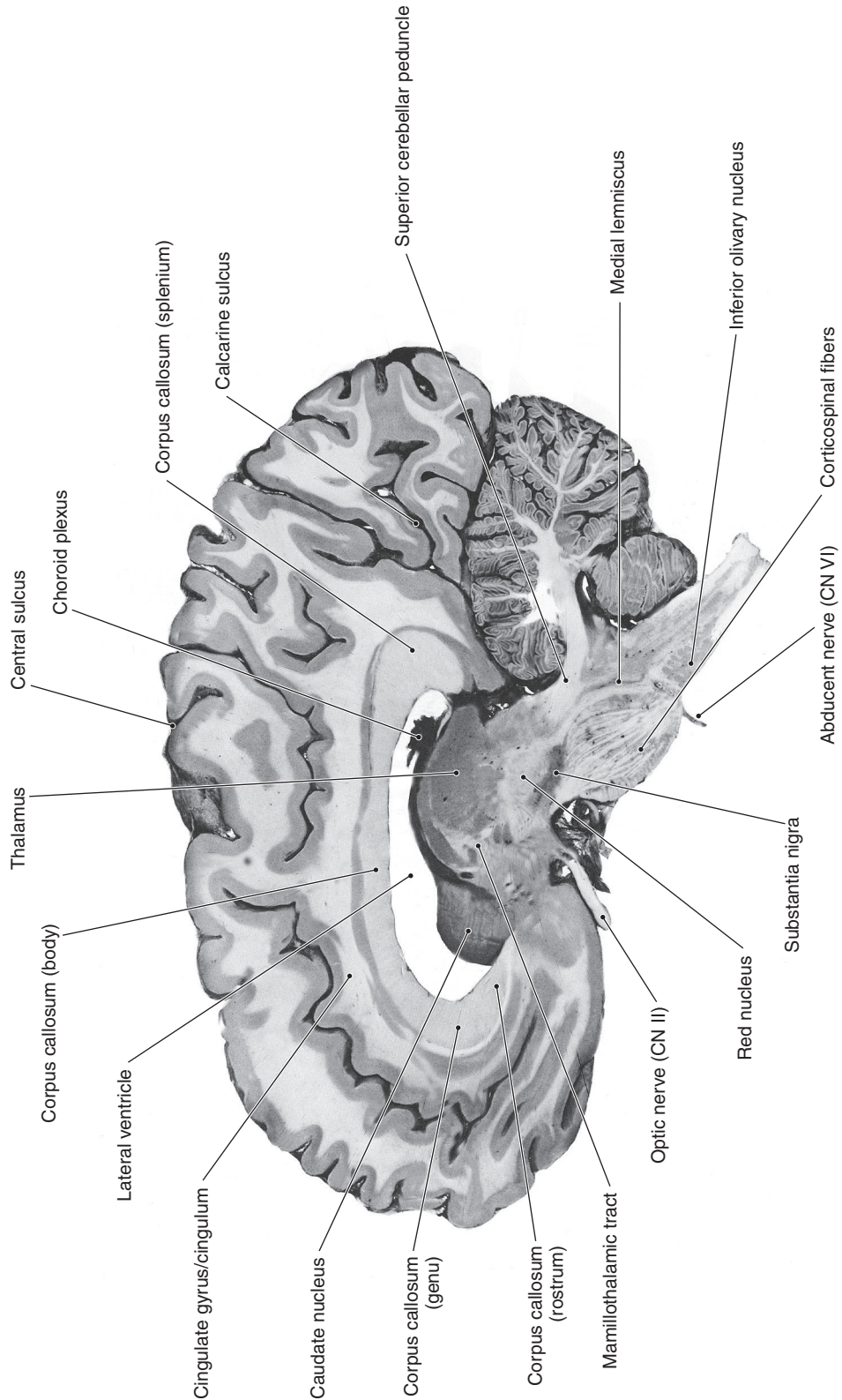


FIGURE 1.9. Parasagittal section through the red nucleus, medial lemniscus, and inferior olivary nucleus. The corticospinal fibers can be traced from the crus cerebri to the spinal cord. The abducent nerve (CN VI) is seen exiting from the junction of the pons and medulla. (Modified from Roberts M, Hanaway J, Morest DK. *Atlas of the Human Brain in Section*. 2nd ed. Philadelphia, PA: Lea & Febiger; 1987:81.)

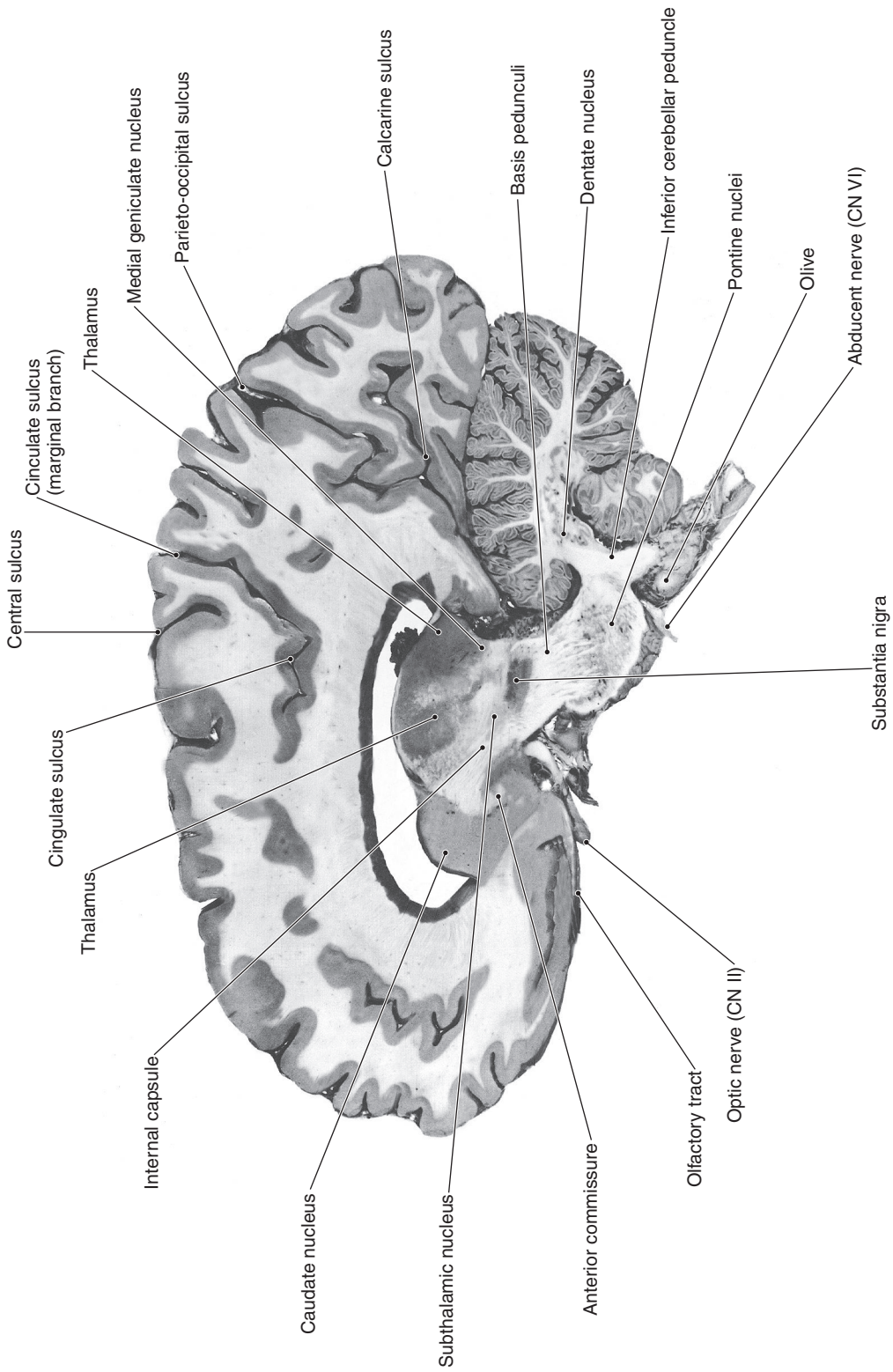


FIGURE 1.10. Parasagittal section through the caudate nucleus, subthalamic nucleus, substantia nigra, and dentate nucleus. (Modified from Roberts M, Hanaway J, Morest DK. *Atlas of the Human Brain in Section*. 2nd ed. Philadelphia, PA: Lea & Febiger; 1987:79.)

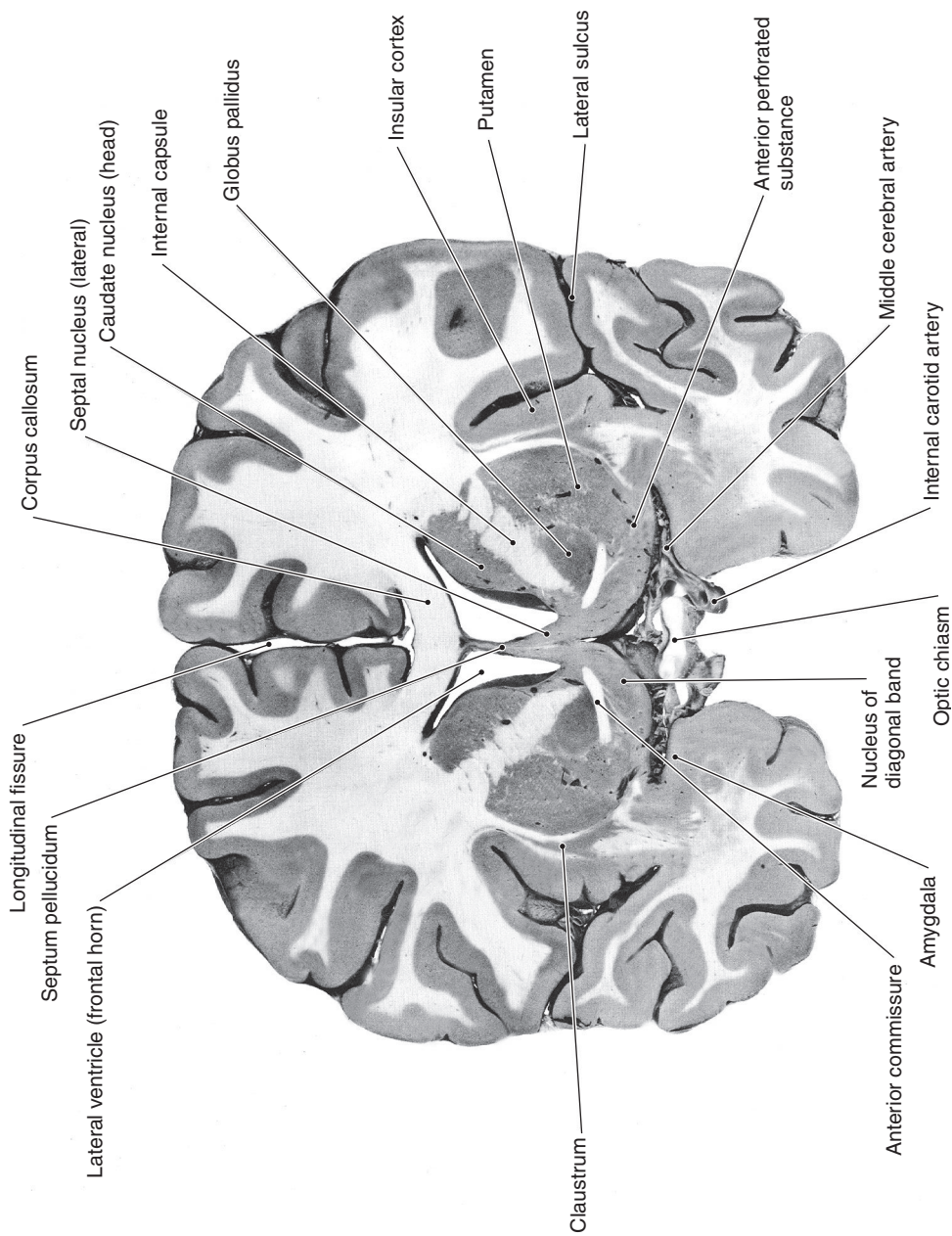


FIGURE 1.11. Coronal section through the anterior commissure, amygdala, septal nuclei, and optic chiasm. (Modified from Roberts M, Hanaway J, Morest DK. *Atlas of the Human Brain in Section*. 2nd ed. Philadelphia, PA: Lea & Febiger; 1987:9.)

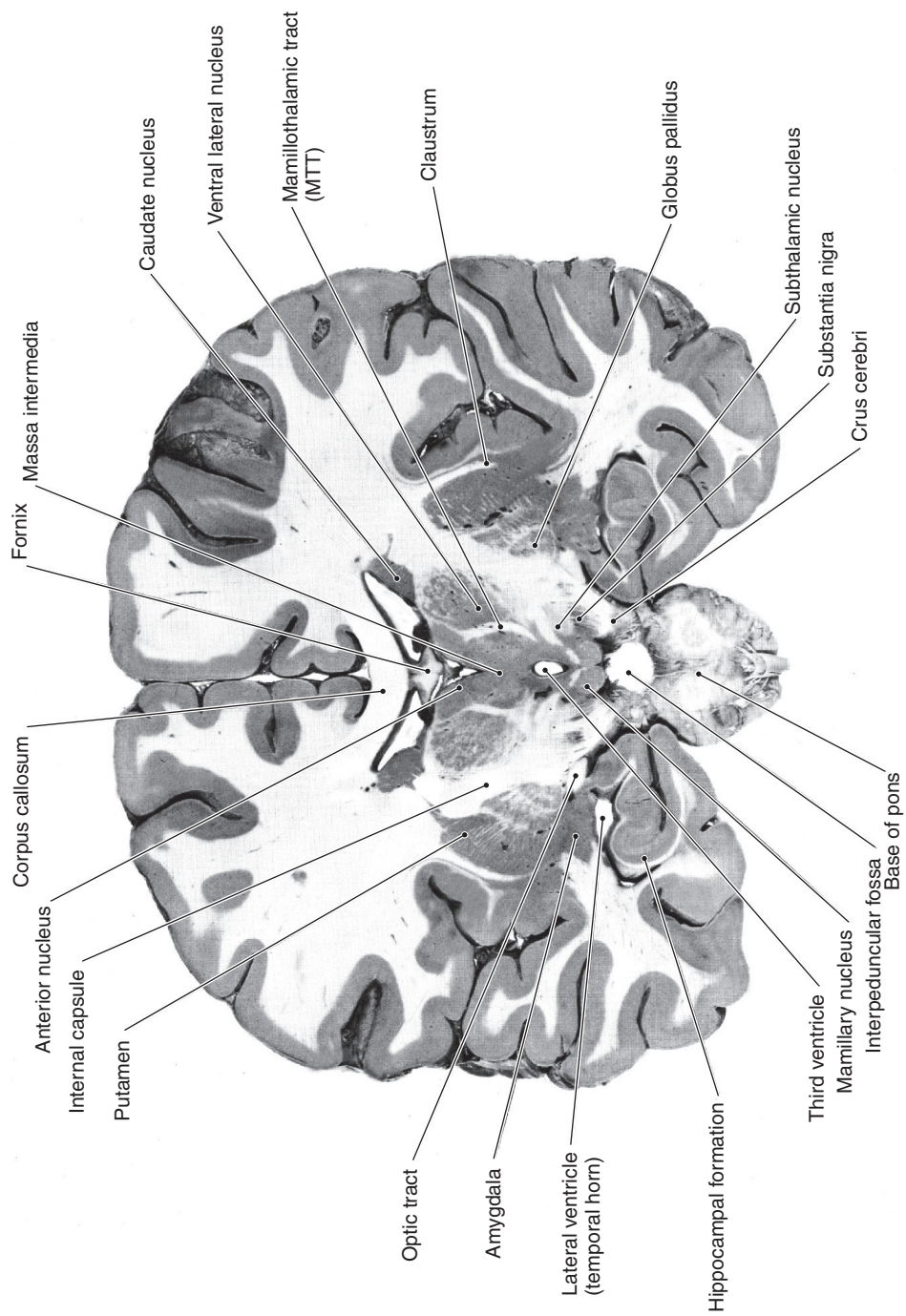


FIGURE 1.12. Coronal section through the posterior limb of the internal capsule, mamillothalamic tract, mamillary body, and hippocampal formation. The optic tracts are visible bilaterally. (Modified from Roberts M, Hanaway J, Morest DK. *Atlas of the Human Brain in Section*. 2nd ed. Philadelphia, PA: Lea & Febiger; 1987:19.)

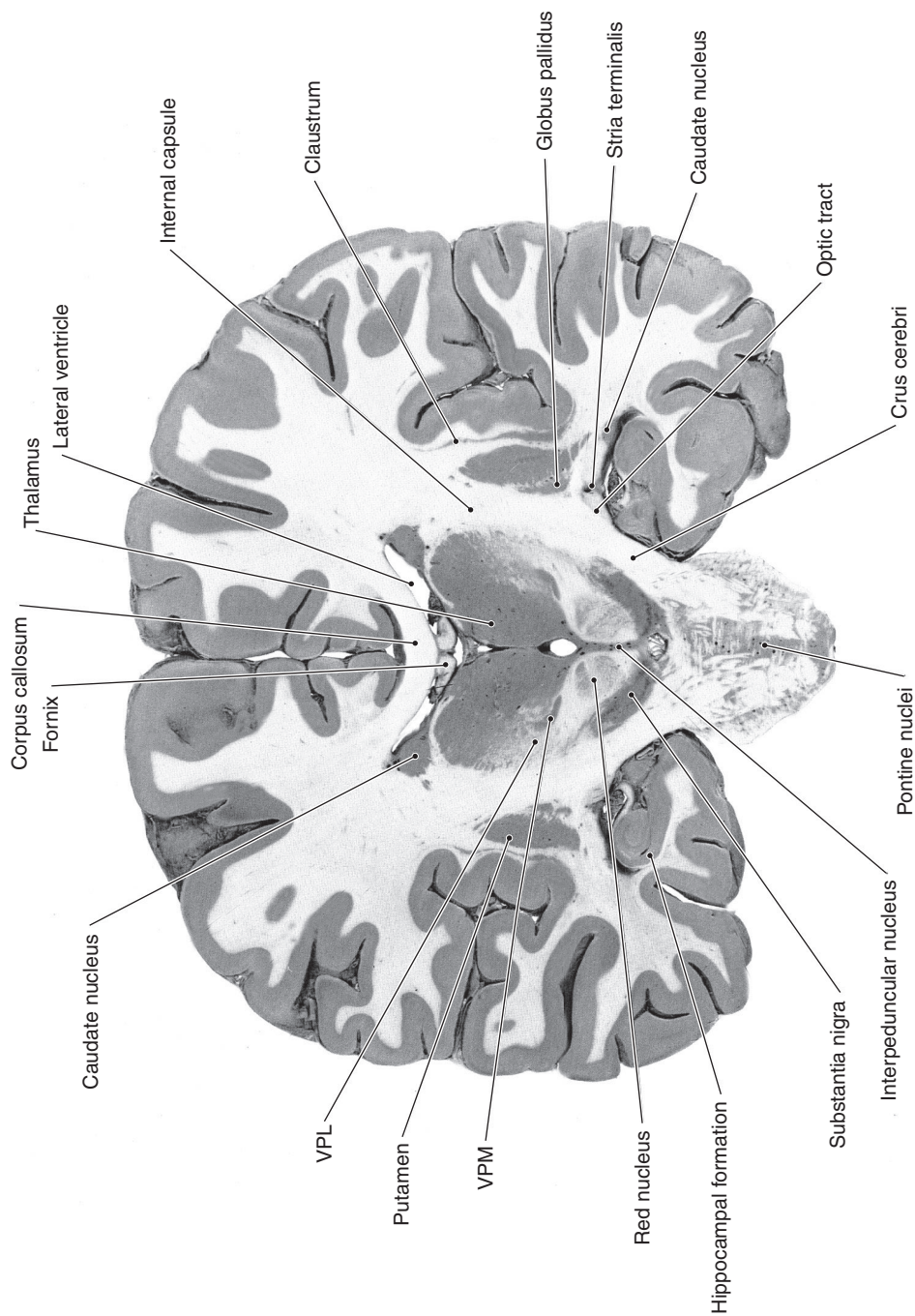


FIGURE 1.13. Coronal section through the thalamus, ventral posteromedial nucleus (VPM) and the ventral posterolateral nucleus (VPL), posterior limb of the internal capsule, substantia nigra, and red nucleus. (Modified from Roberts M, Hanaway J, Morest DK. *Atlas of the Human Brain in Section*. 2nd ed. Philadelphia, PA: Lea & Febiger; 1987:23.)

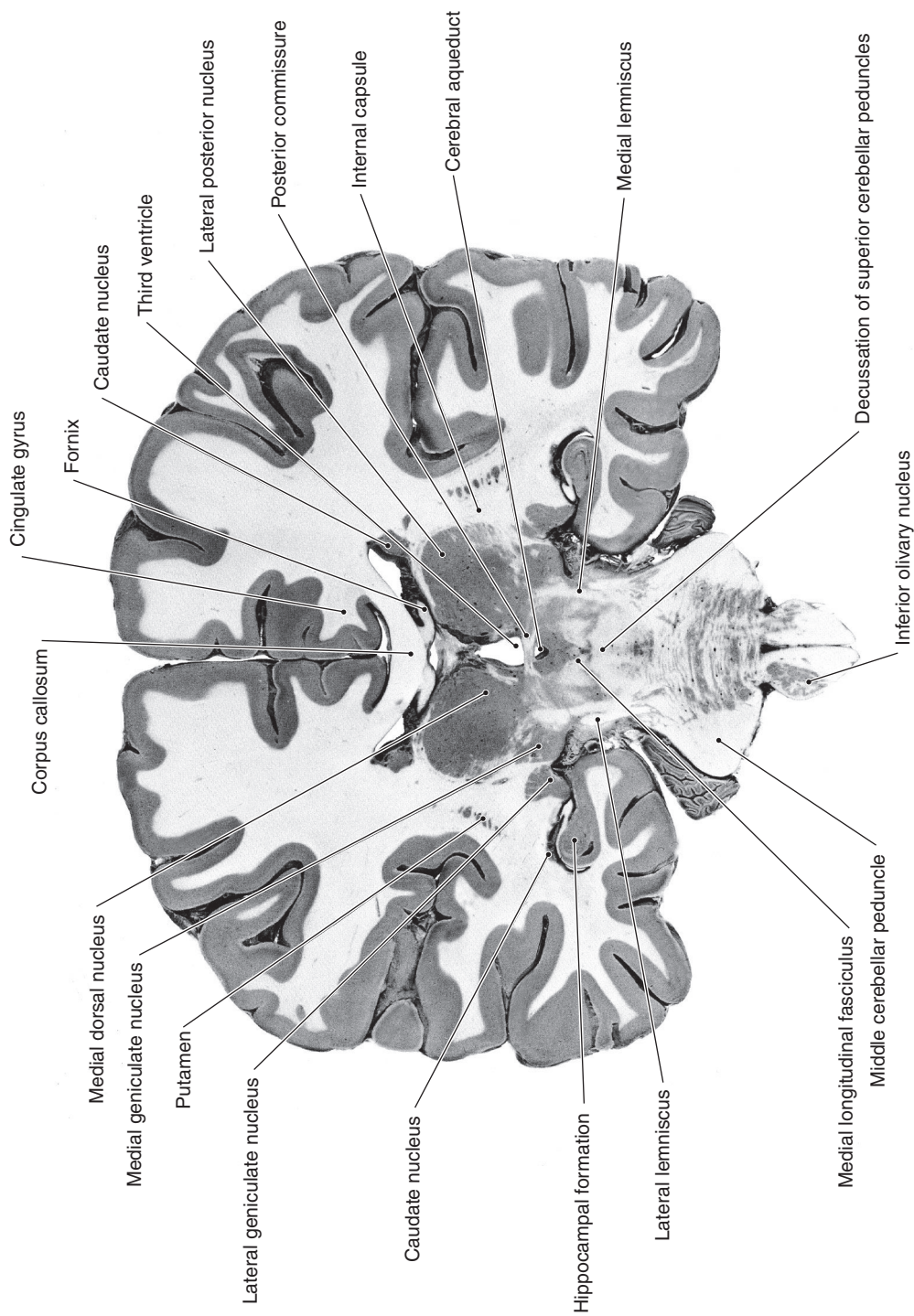


FIGURE 1.14. Coronal section through the lateral and medial lemnisci, lateral and medial geniculate nuclei, and hippocampal formation. (Modified from Roberts M, Hanaway J, Morest DK. *Atlas of the Human Brain in Section*. 2nd ed. Philadelphia, PA: Lea & Febiger; 1987:25.)

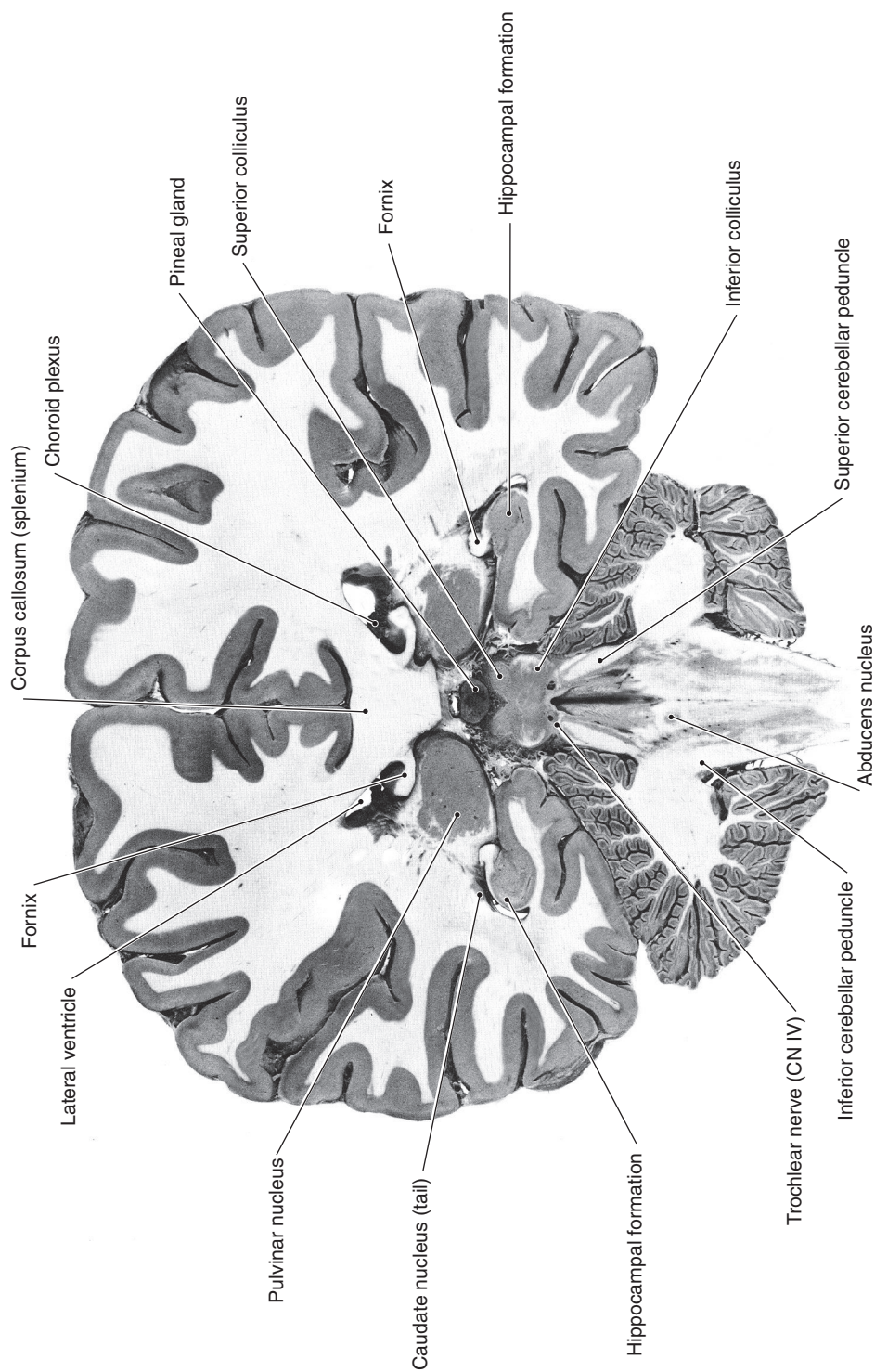


FIGURE 1.15. Coronal section through the pulvinar, pineal gland (epiphysis), superior and inferior colliculi, and trochlear nerve (CN IV). (Modified from Roberts M, Hanaway J, Morest DK. *Atlas of the Human Brain in Section*. 2nd ed. Philadelphia, PA: Lea & Febiger; 1987:29.)

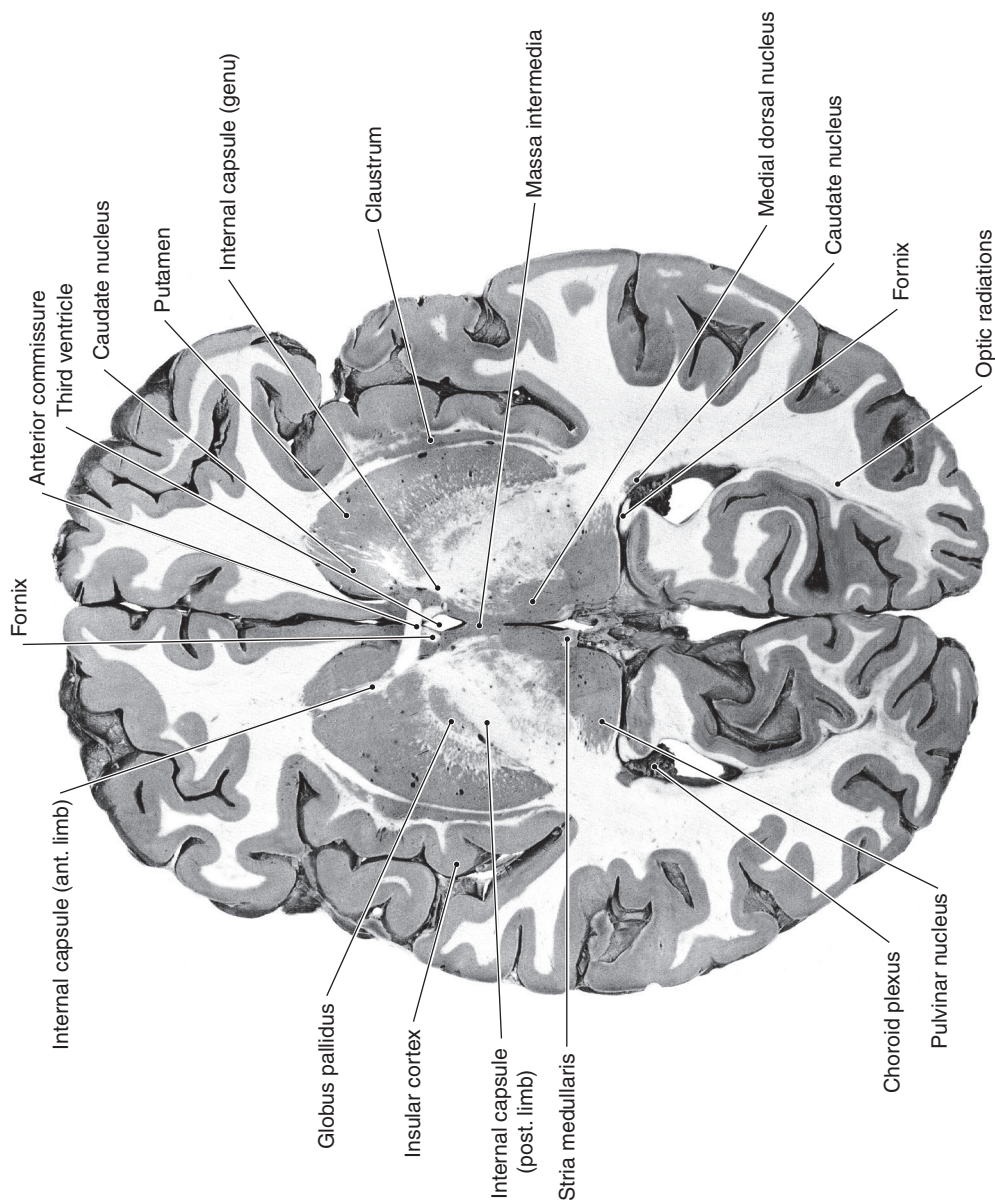


FIGURE 1.16. Axial section through the internal capsule, anterior commissure, and pulvinar nucleus. (Modified from Roberts M, Hanaway J, Morest DK. *Atlas of the Human Brain in Section*. 2nd ed. Philadelphia, PA: Lea & Febiger, 1987:51.)

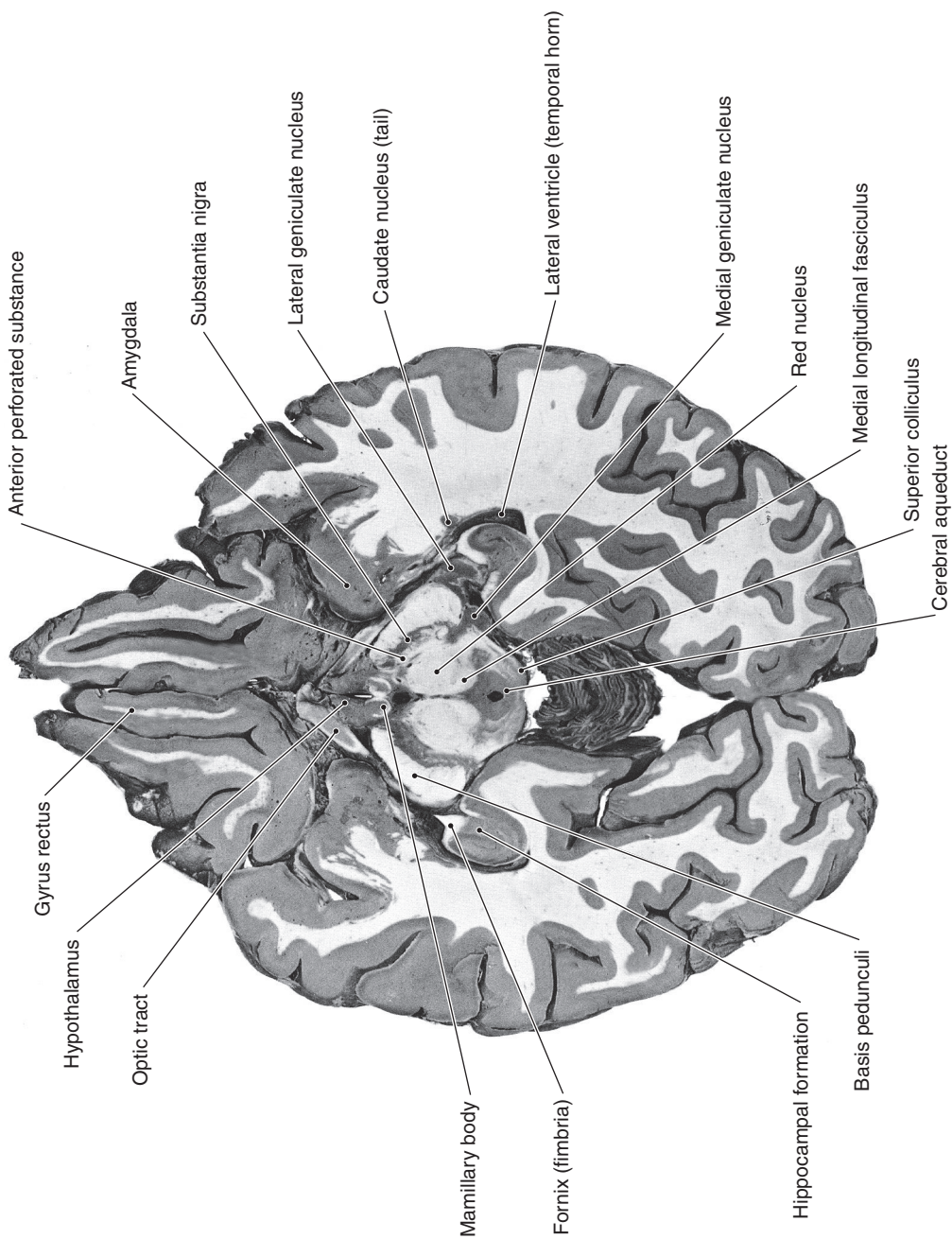


FIGURE 1.17. Axial section through the mamillary nuclei and the superior colliculi. (Modified from Roberts M, Hanaway J, Morest DK. *Atlas of the Human Brain in Section*. 2nd ed. Philadelphia, PA: Lea & Febiger; 1987:57.)

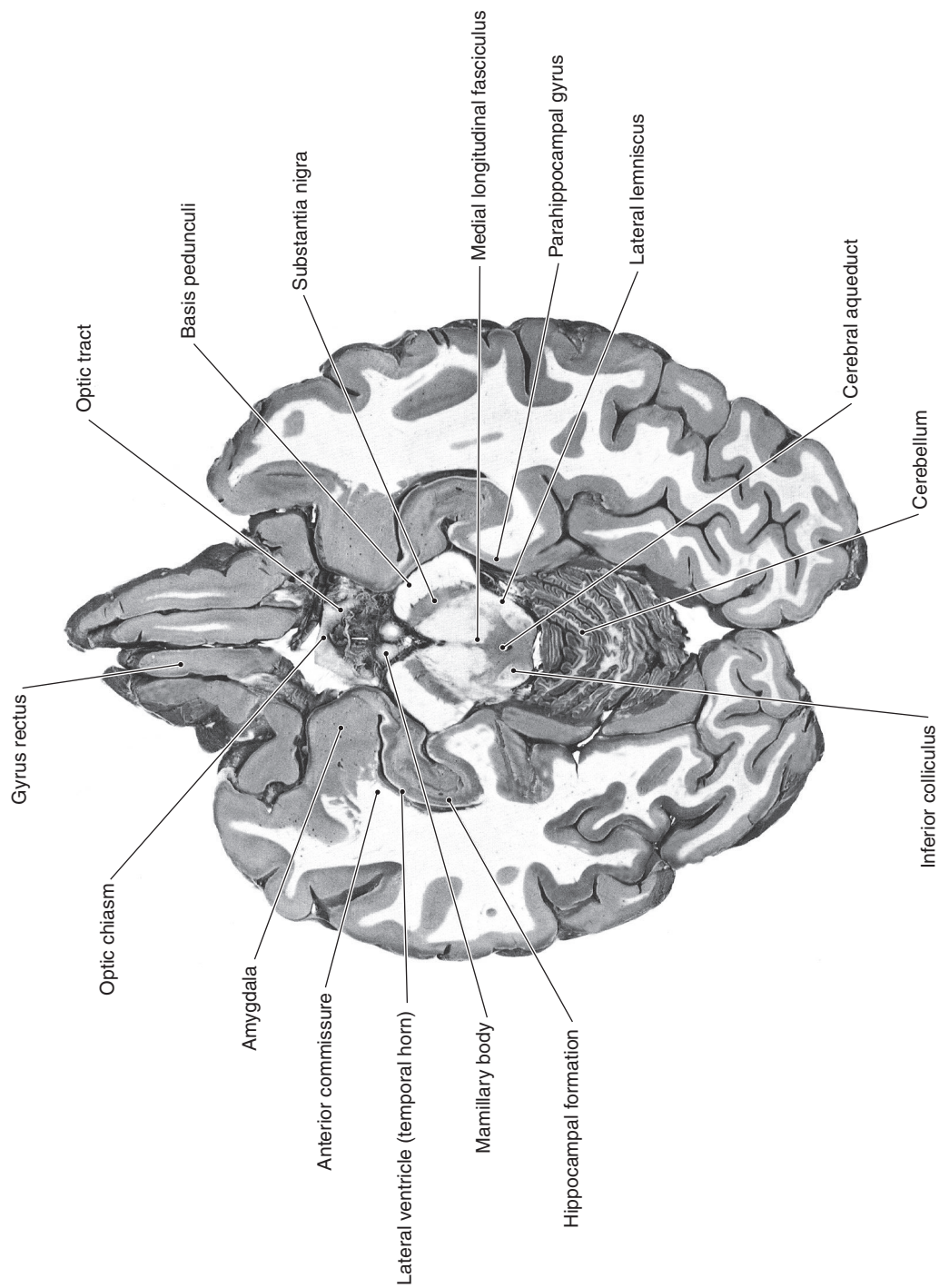


FIGURE 1.18. Axial section through the mamillary nuclei, optic chiasm, and inferior colliculi. (Modified from Roberts M, Hanaway J, Morest DK. *Atlas of the Human Brain in Section*. 2nd ed. Philadelphia, PA: Lea & Febiger; 1987:99.)

Review Test

1. Which one of the following structures is part of the diencephalon?

- (A) Caudate nucleus
- (B) Cerebral hemispheres
- (C) Globus pallidus
- (D) Internal capsule
- (E) Thalamus

2. The hippocampal formation is part of the _____ lobe.

- (A) frontal
- (B) insular
- (C) limbic
- (D) occipital
- (E) parietal

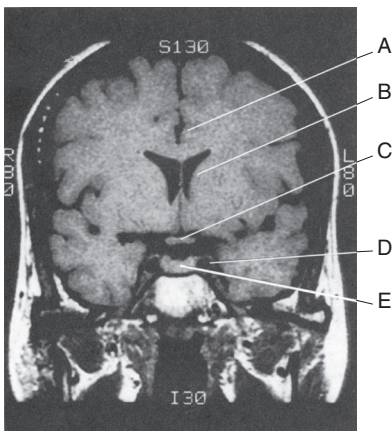
3. Which one of the cranial nerves exits the brainstem from the posterior aspect?

- (A) CN I
- (B) CN II
- (C) CN III
- (D) CN IV
- (E) CN VI

4. From which one of the following structures does Heschl's gyrus receive input?

- (A) Angular gyrus
- (B) Medial geniculate nucleus
- (C) Primary auditory cortex
- (D) Pulvinar
- (E) Supramarginal gyrus

Questions 5 to 9 Match the descriptions in items 5 to 9 with the appropriate lettered structure shown in the T₁-weighted MRI of the coronal section of the brain.



5. Lies within the cavernous sinus

6. Lies within the sella turcica

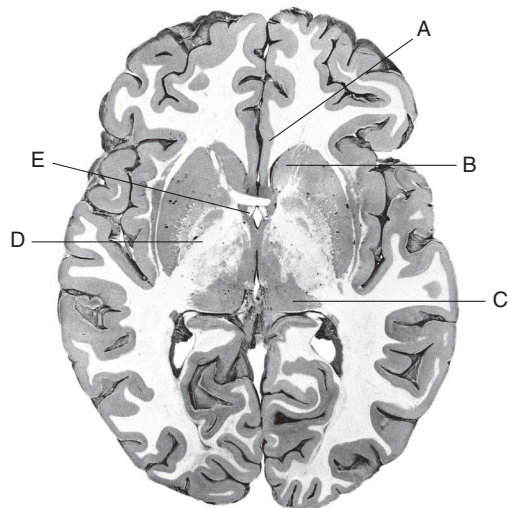
7. Is part of the striatum

8. Is part of the limbic lobe

9. Lies within a cistern

Questions 10 to 14

Match the structure or description in items 10 to 14 with the appropriate lettered structure shown in the stained section of the brain.



(Modified from Roberts M, Hanaway J, Morest DK. *Atlas of the Human Brain in Section*, 2nd ed. Philadelphia, Lea & Febiger, 1987:51.)

10. Has reciprocal connections between the hippocampal formation and the septal nuclei

11. Largest nucleus of the diencephalon

12. Internal capsule

13. Cingulate gyrus

14. Caudate nucleus

Answers and Explanations

- 1–E.** The thalamus, along with the epithalamus, hypothalamus and the subthalamus comprises the diencephalon.
- 2–C.** The hippocampus is part of the limbic system and plays a role in memory consolidation. The hippocampus is one of the first regions damaged in Alzheimer's disease.
- 3–D.** The trochlear nerve (CN IV) is the only cranial nerve to exit the brainstem from the dorsal/posterior aspect.
- 4–B.** Primary auditory cortex (areas 41 and 42) is found in the transverse gyrus of Heschl and receives input from the medial geniculate nucleus. The parietal lobe includes the angular gyrus that receives visual impulses (area 39) and supramarginal gyrus that interrelates somatosensory, auditory, and visual inputs (area 40). Destruction of the angular and supramarginal gyri on the dominant (usually left) side gives rise to Gerstmann syndrome, whose symptoms include agraphia, acalculia, finger agnosia and left-right disorientation.
- 5–D.** The carotid artery lies within the cavernous sinus, in association with CN III, CN IV, CN V₁, CN V₂, and CN VI; aneurysms of the internal carotid artery and tumors of the cavernous sinus may cause cranial nerve palsies.
- 6–E.** The hypophysis (pituitary gland) lies within the hypophyseal fossa of the sella turcica; common tumors in this region are pituitary adenomas, craniopharyngiomas, and meningiomas.
- 7–B.** The caudate nucleus and putamen are parts of the striatum. In Huntington disease there is loss of neurons in the caudate nucleus, whereas in Parkinson disease there is loss of neurons in the substantia nigra.
- 8–A.** The cingulate gyrus is part of the limbic lobe; lesions may result in akinesia, mutism, apathy, and indifference to pain.
- 9–C.** The optic chiasm lies within the chiasmatic cistern.
- 10–E.** The fornix contains fibers from the hippocampal formation and septal nuclei. The fornix projects into the mamillary nuclei of the hypothalamus.
- 11–C.** The pulvinar is the largest nucleus of the thalamus. It has reciprocal connections with the association cortex of the occipital, parietal, and posterior lobes and is concerned with the integration of visual, auditory, and somesthetic inputs.
- 12–D.** The posterior limb of the internal capsule lies between the lentiform nucleus and the thalamus. It contains the corticospinal tract and is perfused by the lateral striate arteries (branches of middle cerebral artery) and the anterior choroidal artery.
- 13–A.** The cingulate gyrus contains the cingulum, a fiber bundle that interconnects the hippocampal formation with the septal nucleus. Bilateral destruction of the cingulate gyrus causes loss of inhibition as well as dulling of the emotions. However, memory is unaffected. Lesions of the anterior cingulate gyri cause placidity; cinglectomy is used to treat severe anxiety and depression.
- 14–B.** The caudate and the putamen comprise the striatum, part of the basal nuclei. In Huntington disease, massive loss of neurons in the head of the caudate results in hydrocephalus ex vacuo. The globus pallidus and subthalamic nucleus are also basal nuclei.

Meninges and Cerebrospinal Fluid

Objectives

- Describe the location and identifying characteristics of the dura mater, arachnoid, and pia mater.
- Identify the meningeal spaces and include a description of what is found in each, and whether the spaces are real or potential.
- List the major cisterns of the subarachnoid space and describe the location of each.
- Identify the ventricles and list the subdivisions and characteristics of each.
- Describe the flow of cerebrospinal fluid (CSF) through the ventricular system.
- Explain where CSF is created and the route it takes to the systemic circulation.
- Describe hydrocephalus and meningitis.
- List the circumventricular organs and describe their significance.

I. MENINGES

- comprise three connective tissue membranes that invest the spinal cord and brain.
- consist of the **pia mater** and the **arachnoid** (together known as the leptomeninges) and the **dura mater** (pachymeninx).

A. Pia mater

- a delicate, vascular layer of connective tissue.
- closely covers the surface of the brain and spinal cord.
- connected to the arachnoid by arachnoid trabeculae.
 1. **Denticulate ligaments** (see Figure 2.1)
 - consist of two lateral flattened bands of pial tissue.
 - adhere to the spinal dura mater with 21 pairs of attachments.
 2. **Filum terminale** (Figure 2.2)
 - consists of an extension of the pia mater.
 - extends from the conus medullaris to the end of the dural sac (interna) and from the dural sac to the coccyx (externa)—the **coccygeal ligament**.

B. Arachnoid

- a delicate, nonvascular connective tissue membrane between the dura mater and the pia mater.
 1. **Arachnoid granulations/villi**
 - accumulations of arachnoid villi, formed of evaginations of arachnoid through the meningeal layer of dura mater.

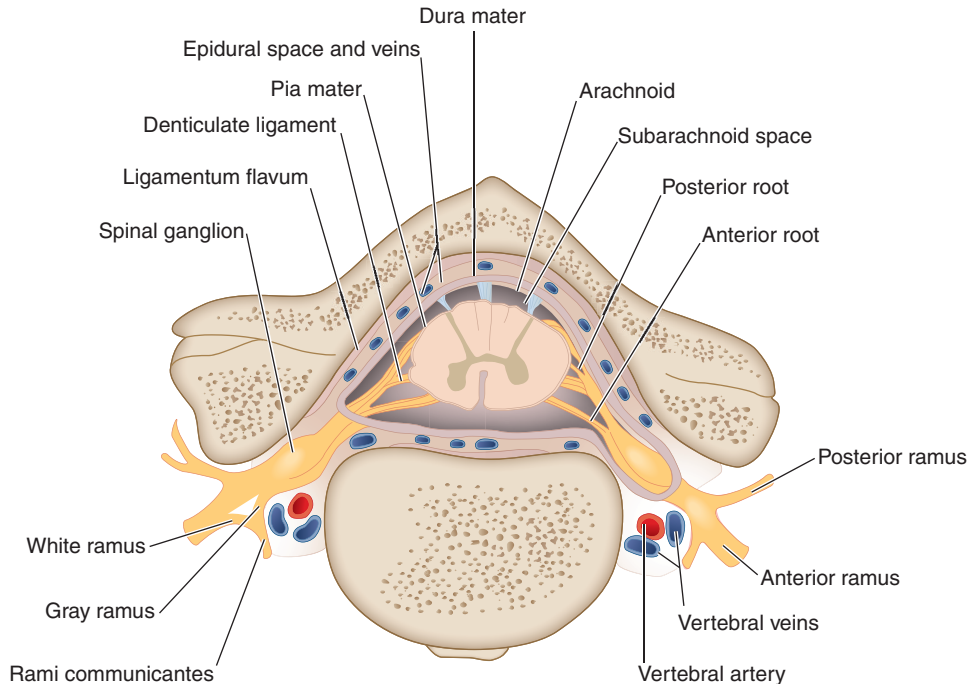


FIGURE 2.1. Cross-section of the spinal cord and its meningeal investments. The subarachnoid, subdural, and epidural spaces are visible. The anterior and posterior longitudinal ligaments are seen but are not labeled. (Modified from Carpenter MB, Sutin J. *Human Neuroanatomy*. 8th ed. Baltimore, MD: Williams & Wilkins; 1983:9.)

- enter the venous dural sinuses and facilitate the one-way flow of cerebrospinal fluid (CSF) from the subarachnoid space into the venous circulation.
- found in large numbers along the **superior sagittal sinus** but are associated with all dural sinuses.

C. Dura mater

- the outer layer of the meninges, consisting of dense connective tissue.
- the supratentorial dura is innervated by the trigeminal nerve; the dura of the posterior cranial fossa is innervated by the vagal and upper spinal nerves.
- in several areas the dura mater divides into two parts, a periosteal layer and a meningeal layer.
- the meningeal layer of dura mater forms reflections that invaginate to support and protect various parts of the brain; the reflections also form the walls of the dural venous sinuses:
 1. **Falx cerebri**
 - lies between the cerebral hemispheres in the longitudinal cerebral fissure.
 - contains the superior and inferior sagittal sinuses between its layers.
 2. **Tentorium cerebelli** (Figure 2.3)
 - separates the posterior cranial fossa from the middle cranial fossa.
 - divides the cranial vault into supra- and infratentorial compartments.
 - separates the temporal and occipital lobes from the cerebellum and infratentorial brainstem.
 - contains the **tentorial incisure**, or notch, through which the brainstem passes.
 3. **Diaphragma sellae**
 - forms the roof of the **hypophyseal fossa**.
 - contains an aperture through which the **hypophyseal stalk** (infundibulum) passes.
 4. **Dural sinuses** (see Figure 2.3)
 - endothelium-lined, valveless venous blood channels typically found in the attached edge of the dural folds.

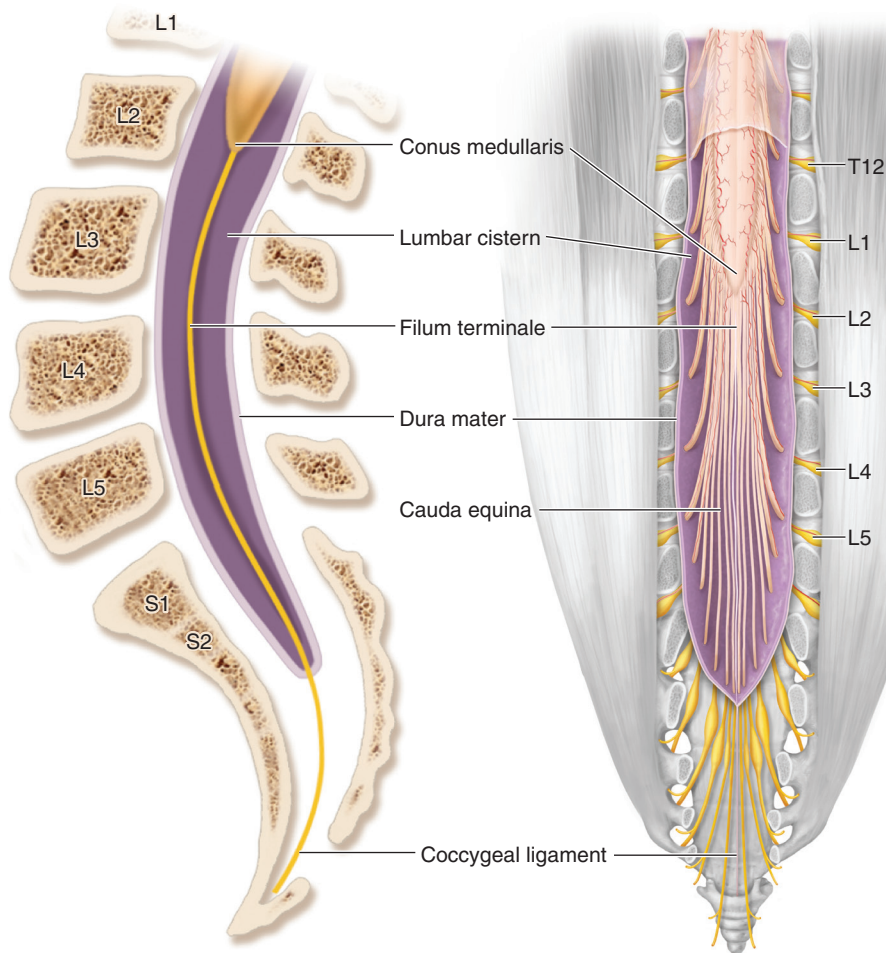


FIGURE 2.2. The caudal part of the spinal cord and lumbar cistern. **(A)** Longitudinal section through the caudal vertebral column and canal showing the conus medullaris and the lumbar cistern. Lumbar puncture is made between the spinous processes of L3 and L4 (or L4 and L5). **(B)** Posterior view of the cauda equina and spinal nerves. The adult spinal cord terminates at the L1–L2 vertebral level. (Modified from Carpenter MB, Sutin J. *Human Neuroanatomy*. 8th ed. Baltimore, MD: Williams & Wilkins; 1983:8.)

D. Meningeal spaces (see Figures 2.1 through 2.3)

1. Spinal epidural space

- located between the spinal dura mater and the vertebral periosteum.
- contains loose areolar tissue, venous plexuses, and lymphatics.
- can be injected with a local anesthetic to produce a paravertebral nerve block.

2. Cranial epidural space

- a *potential* space between the dura mater and the bones of the cranial vault.
- contains the meningeal arteries and veins.

3. Subdural space

- a *potential* space between the dura mater and the arachnoid.
- intracranially transmits cerebral veins to the venous lacunae of the superior sagittal sinus. Laceration of these “bridging veins” results in **subdural hemorrhage** (hematoma).

4. Subarachnoid space

- located between the pia mater and the arachnoid.
- contains **CSF**.

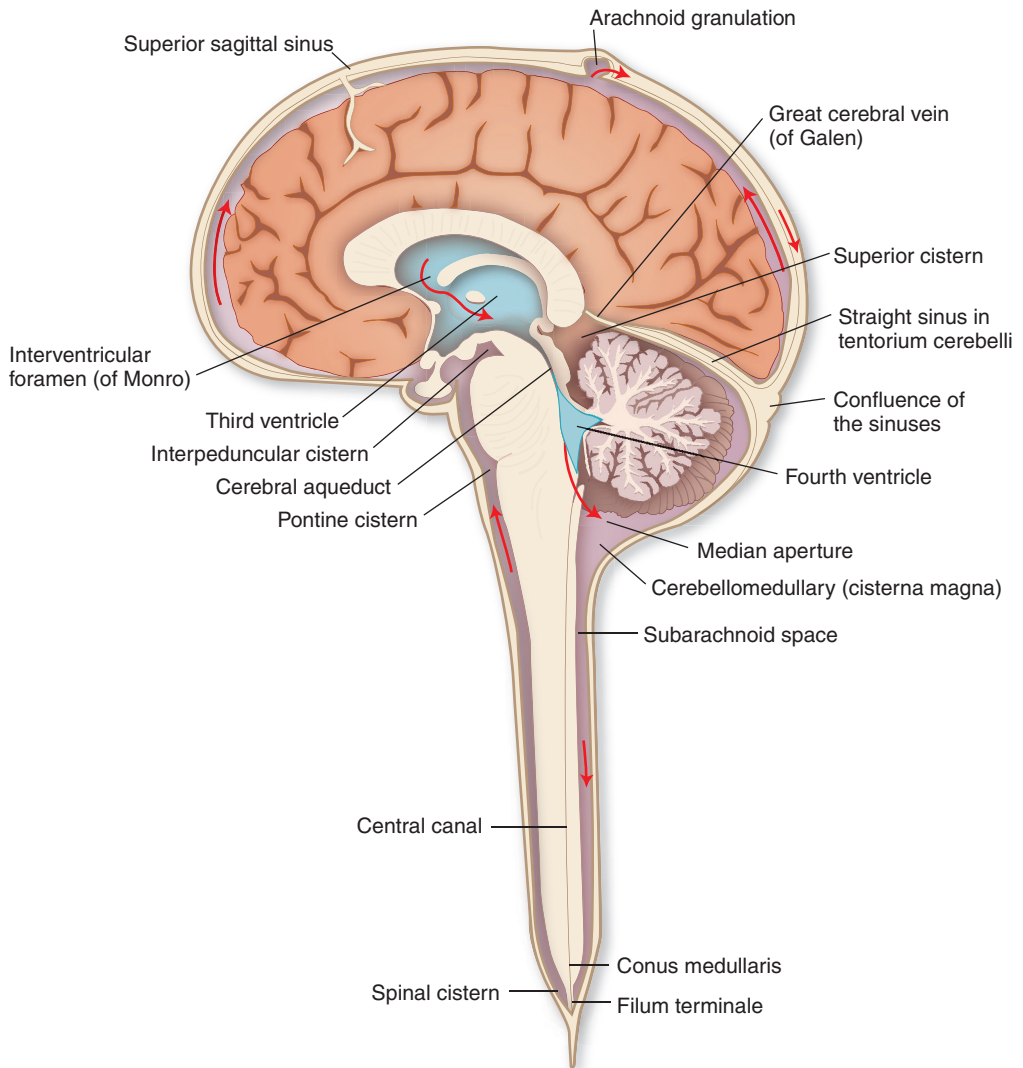


FIGURE 2.3. The subarachnoid spaces and cisterns of the brain and spinal cord. CSF is produced in the choroid plexuses of the ventricles, exits the fourth ventricle, circulates in the subarachnoid space, and enters the superior sagittal sinus via the arachnoid granulations. (Modified from Noback CR, Strominger NL, Demarest RJ. *The Human Nervous System*. 4th ed. Baltimore, MD: Williams & Wilkins; 1991:68.)

- surrounds the entire brain and spinal cord.
 - extends, in the adult, below the conus medullaris to the level of the second sacral vertebra as the **lumbar cistern** (see Figure 2.2A).
- 5. Subarachnoid cisterns** (see Figure 2.3)
- dilations of the subarachnoid space, which contain CSF.
 - named after the structures over which they lie (i.e., pontine, chiasmatic, and interpeduncular cisterns).
- a. Cerebellopontine angle cistern**
 - receives CSF from the fourth ventricle via the lateral foramina (of Luschka).
 - contains the facial nerve (**CN VII**) and the vestibulocochlear nerve (**CN VIII**).
 - b. Cerebellomedullary cistern (cisterna magna)**
 - located in the midline between the cerebellum and the medulla.
 - receives CSF from the fourth ventricle via the median foramen (of Magendie).
 - can be tapped for CSF (suboccipital tap).

c. Ambient cistern

- interconnects the superior and interpeduncular cisterns; contains the trochlear nerve (**CN IV**).

d. Superior cistern

- overlies the midbrain tectum.

E. Meningiomas

- benign, slow-growing, well-demarcated tumors that arise from meningotheelial arachnoid cells.
- comprise 20% of primary intracranial tumors and 25% of spinal tumors.
- found most frequently in the anterior cranial fossa (parasagittal, 25%; convexity, 20%; and basal, 40%).
- histologically characterized by a whorling pattern and calcified **psammoma bodies**.
- enlarge slowly and create a cavity in the adjacent brain tissue.
- occur in adults between 20 and 60 years, most often in women (60%).

II. VENTRICLES (FIGURE 2.4; SEE FIGURE 2.3)

- lined with ependyma and contain CSF.
- contain choroid plexus, which produces CSF at a rate of 500 to 700 ml/day.
- communicate with the subarachnoid space via three foramina in the fourth ventricle.
- consist of four fluid-filled communicating cavities within the brain.

A. Lateral ventricles

- the two ventricles are located within the cerebral hemispheres.
- communicate with the third ventricle via the **interventricular foramina (of Monro)**.
- consist of five parts:
 - 1. Frontal (anterior) horn**
 - located in the frontal lobe; its lateral wall is formed by the head of the caudate nucleus.
 - lacks choroid plexus.
 - 2. Body**
 - located in the medial portion of the frontal and parietal lobes.
 - contains choroid plexus.
 - communicates with the third ventricle via the interventricular foramina.
 - 3. Temporal (inferior) horn**
 - located in the medial part of the temporal lobe.
 - contains choroid plexus.
 - 4. Occipital (posterior) horn** (see Figure 1.2)
 - located in the parietal and occipital lobes.
 - lacks choroid plexus.
 - 5. Trigone (atrium)**
 - found at the junction of the body, occipital horn, and temporal horn of the lateral ventricle.
 - contains the **glomus**, a large tuft of choroid plexus, which is calcified in adults and is visible on x-ray film and computed tomography (CT).

B. Third ventricle (see Figures 1.5, 2.3, and 2.4)

- a slit-like vertical midline cavity of the diencephalon.
- communicates with the lateral ventricles via the interventricular foramina and with the fourth ventricle via the cerebral aqueduct.
- contains choroid plexus in its roof.

C. Cerebral aqueduct (aqueduct of Sylvius)

- lies in the midbrain.
- connects the third ventricle with the fourth ventricle.

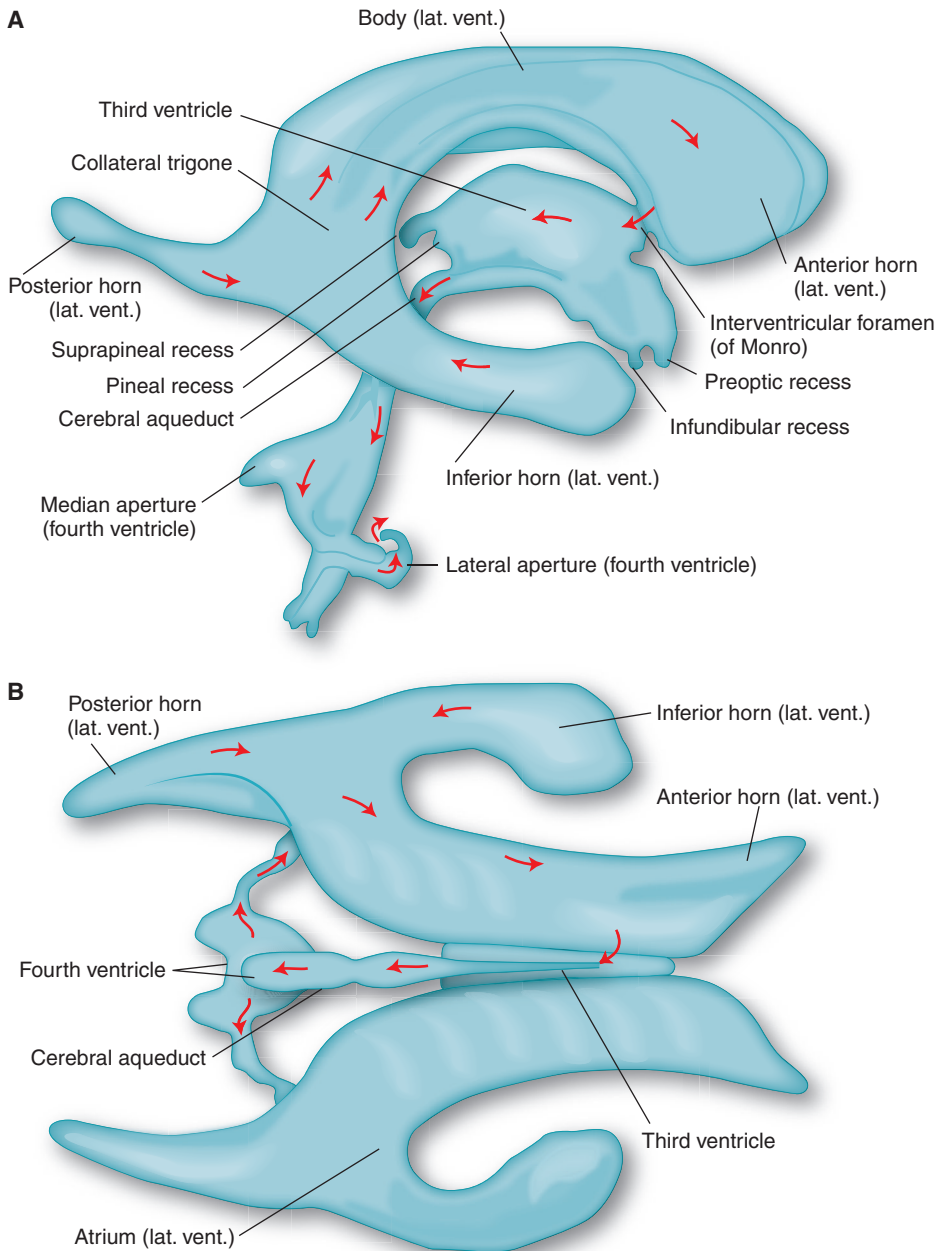


FIGURE 2.4. The ventricular system of the brain. **(A)** Lateral aspect. **(B)** Dorsal aspect. (Modified from Carpenter MB, Sutin J. *Human Neuroanatomy*. 8th ed. Baltimore, MD: Williams & Wilkins; 1983:44.)

- lacks choroid plexus.
- Blockage leads to hydrocephalus (aqueductal stenosis).

D. Fourth ventricle (see Figures 1.5, 2.3, and 2.4)

- lies between the cerebellum and the brainstem.
- contains choroid plexus in the caudal aspect of its roof.
- expresses CSF into the subarachnoid space via the two lateral foramina and the single medial foramen.

III. CEREBROSPINAL FLUID

- a clear, colorless, acellular fluid found in the subarachnoid space and ventricles.

A. Formation

- produced by the **choroid plexus** at a rate of 500 to 700 ml/day. The total CSF volume is approximately 140 ml (see Figures 1.5, 1.7, and 2.3).

B. Function

- supports and cushions the central nervous system (CNS) against concussive injury.
- transports hormones and hormone-releasing factors.
- removes metabolic waste products through absorption; the sites of greatest absorption are the **arachnoid villi** (see Figure 2.3).

C. Circulation (see Figure 2.3)

- flows from the ventricles via the three foramina of the fourth ventricle into the subarachnoid space and over the convexity of the cerebral hemisphere to the superior sagittal sinus, where it enters the venous circulation.

D. Composition

- contains not more than 5 lymphocytes/ μ l and is usually sterile.
- other **normal values** are:
 1. **pH:** 7.35
 2. **Specific gravity:** 1.007
 3. **Glucose:** 66% of plasma glucose
 4. **Total protein:** <45 mg/dl in the lumbar cistern

E. Normal pressure

- is 80 to 180 mm of water (CSF) in the lumbar cistern when the patient is in a lateral recumbent position.

IV. HYDROCEPHALUS

- dilation of the cerebral ventricles caused by blockage of the CSF flow.
- characterized by excessive accumulation of CSF in the cerebral ventricles or subarachnoid space.

A. Noncommunicating hydrocephalus

- results from obstruction within the ventricles (i.e., congenital aqueductal stenosis).

B. Communicating hydrocephalus

- results from blockage within the subarachnoid space (i.e., adhesions after meningitis).

C. Normal-pressure hydrocephalus

- occurs when the CSF is not absorbed by the arachnoid villi, possibly secondary to posttraumatic meningeal hemorrhage.
- characterized clinically by the triad of progressive dementia, ataxic gait, and urinary incontinence (**wacky, wobbly, and wet**).

D. Hydrocephalus ex vacuo

- results from loss of cells in the caudate nucleus (i.e., Huntington disease).

E. Pseudotumor cerebri (benign intracranial hypertension)

- results from increased resistance to CSF outflow at the arachnoid villi.
- characterized by papilledema without mass, elevated CSF pressure, and deteriorating vision. The ventricles may be slit-like.
- typically occurs in obese young women.

V. MENINGITIS

- an inflammation of the pia–arachnoid of the brain, spinal cord, or both.

A. Bacterial (pyogenic) meningitis

- occurs most often in children under 5 years of age (>70% of all cases).
- characterized clinically by fever, headache, and nuchal rigidity, with Kernig sign.
- may result in cranial nerve palsies (CN III, CN IV, CN VI, and CN VIII) and hydrocephalus.
 - Common etiologic agents**
 - In **newborns** (<1 month of age), it is most frequently caused by group B streptococci (*Streptococcus agalactiae*) and *Escherichia coli*.
 - In **older infants and young children** (1 month to 9 years), it is most frequently caused by *Haemophilus influenzae*.
 - In **older children to middle-aged adults** (10–60 years), it is most frequently caused by *S. pneumoniae* and *Neisseria meningitidis*.
 - In **older adults**, it is most frequently caused by *S. pneumoniae*.
 - In **newborns**, immunization against *H. influenzae* has significantly reduced this type of meningitis.
 - CSF findings** (Table 2-1)
 - **Numerous neutrophils**
 - **Decreased glucose level**
 - **Elevated protein level**

B. Viral (lymphocytic) meningitis

- also called aseptic meningitis.
- characterized by fever, headache, and nuchal rigidity, with Kernig sign.
 - Viruses isolated include the following:**
 - **Mumps virus**
 - **Enteric cytopathic human orphan (ECHO) viruses**
 - **Coxsackie virus**
 - **Epstein–Barr virus**
 - **Herpes simplex virus (type 2)**

table 2.1 Properties of CSF in Subarachnoid Hemorrhage, Bacterial Meningitis, and Viral Encephalitis

CSF	Normal	Subarachnoid Hemorrhage	Bacterial Meningitis	Viral Encephalitis
Color	Clear	Bloody	Cloudy	Clear or cloudy
Cell count (per mm ³)	<5 lymphocytes	Red blood cells present (~5 × 10 ⁶ /mm ³)	>1000 PML	25–500 lymphocytes
Protein	<45 mg/dl	Normal to slightly elevated	Elevated (<100 mg/dl)	Slightly elevated (>100 mg/dl)
Glucose (~66% of blood [80–120 mg/dl])	>45 mg/dl	Normal	Reduced	Normal

CSF = cerebrospinal fluid; PML = polymorphonuclear leukocytes.
 In infants: cell counts < 10 cells/mm³; protein = 20 to 170 mg/dl.

2. CSF findings

- Numerous lymphocytes
- Normal glucose
- Normal to slightly increased protein

VI. HERNIATION (FIGURES 2.5 THROUGH 2.8)

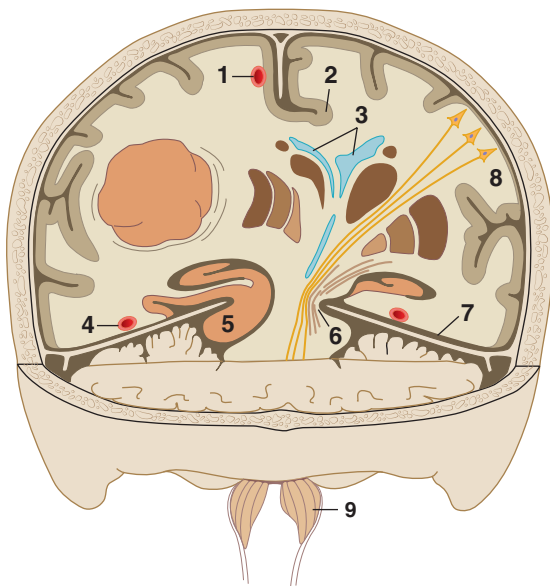


FIGURE 2.5. Coronal section of a tumor in the supratentorial compartment. (1) Anterior cerebral artery; (2) subfalcine herniation; (3) shifting of ventricles; (4) posterior cerebral artery (compression results in contralateral hemianopia); (5) uncus (transtentorial) herniation; (6) Kernohan notch, with damaged corticospinal and corticobulbar fibers; (7) tentorium cerebelli; (8) pyramidal cells that give rise to the corticospinal tract; (9) tonsillar (transforaminal) herniation, which damages vital medullary centers. (Adapted with permission from Leech RW, Shuman RM. *Neuropathology*. New York, NY: Harper & Row; 1982:16.)

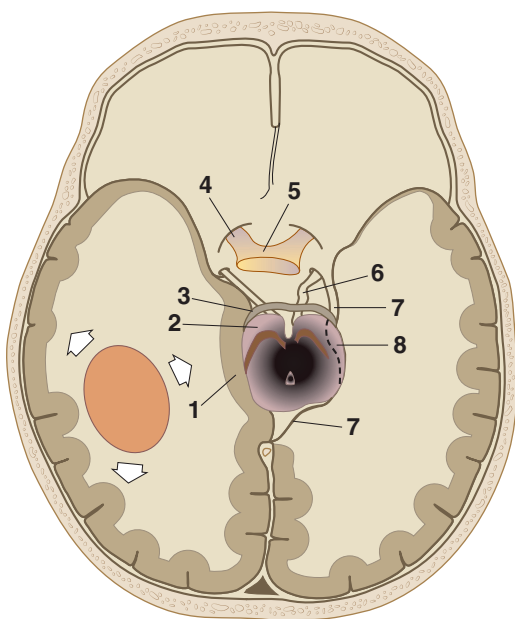


FIGURE 2.6. Axial section through the midbrain and the herniating parahippocampal gyrus (arrows). The left oculomotor nerve is being stretched (dilated pupil). The left posterior cerebral artery is compressed, resulting in a contralateral hemianopia. The right crus cerebri is damaged (Kernohan notch) by the free edge of the tentorial incisura, resulting in a contralateral hemiparesis; the Kernohan notch results in a false localizing sign. The caudal displacement of the brainstem causes rupture of the paramedian arteries of the basilar artery. Hemorrhage into the midbrain and rostral pontine tegmentum is usually fatal (Duret hemorrhages). The posterior cerebral arteries lie superior to the oculomotor nerves. (1) Parahippocampal gyrus; (2) crus cerebri; (3) posterior cerebral artery; (4) optic nerve; (5) optic chiasma; (6) oculomotor nerve; (7) free edge of tentorium; (8) Kernohan notch. (Adapted with permission from Leech RW, Shuman RM. *Neuropathology*. New York, NY: Harper & Row; 1982:19.)

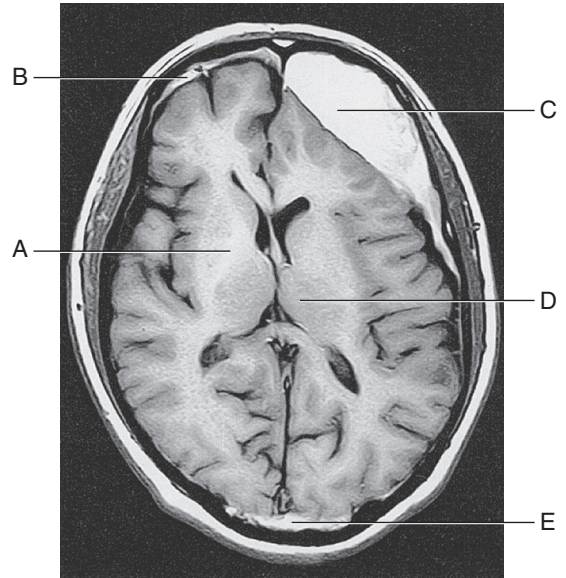


FIGURE 2.7. MRI (T₁-weighted image) showing brain trauma. Epidural hematomas may cross dural attachments. Subdural hematomas do not cross dural attachments. (A) Internal capsule; (B) subdural hematoma; (C) subdural hematomas; (D) thalamus; (E) epidural hematoma. (Modified from Fix JD. *High-Yield Neuroanatomy*. 3rd ed. Philadelphia, PA: Lippincott Williams & Wilkins; 2005:27.)

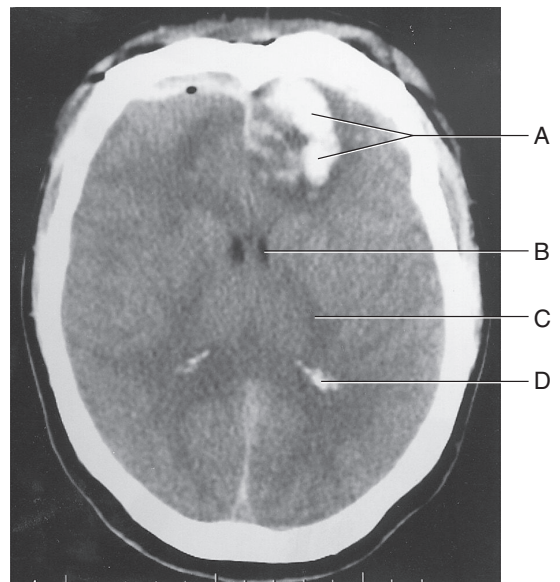


FIGURE 2.8. CT scan (axial section) showing an intraparenchymal hemorrhage in the left frontal lobe. (A) Intraparenchymal hemorrhage; (B) lateral ventricle; (C) internal capsule; (D) calcified glomus in the trigone region of the lateral ventricle. (Modified from Fix JD. *High-Yield Neuroanatomy*. 3rd ed. Philadelphia, PA: Lippincott Williams & Wilkins; 2005:27.)

A. Transtentorial (uncal) herniation

- protrusion of the brain through the tentorial incisura.

B. Transforaminal (tonsillar) herniation

- protrusion of the brainstem and cerebellum through the foramen magnum.

C. Subfalcial herniation

- herniation below the falx cerebri.

VII. CIRCUMVENTRICULAR ORGANS

- chemosensitive areas that monitor the varying concentrations of circulating hormones in the blood and CSF.
- located in the periphery of the third ventricle; the **area postrema** is found on the floor of the fourth ventricle.
- highly vascularized with fenestrated capillaries and no blood–brain barrier (the subcommissural organ is an exception).
- include the following structures:

A. Organum vasculosum of the lamina terminalis

- considered to be a vascular outlet for luteinizing hormone–releasing hormone and somatostatin.

B. Median eminence of the tuber cinereum (see Figure 1.1)

- contains neurons that elaborate releasing and inhibiting hormones into the hypophyseal portal system.

C. Subfornical organ

- located on the inferior surface of the fornix at the level of the interventricular foramina.
- contains neurons that project to the supraoptic nuclei and the organum vasculosum.
- a central receptor site for angiotensin II.

D. Subcommissural organ

- located below the posterior commissure at the junction of the third ventricle and the cerebral aqueduct.
- composed of specialized ependymal cells, glial elements, and a capillary bed containing non-fenestrated endothelial cells.

E. Pineal body (see Figures 1.5 and 1.6)

- contains **calcareous granules**, in **brain sand** or *acervulus cerebri*, which are seen on x-ray film and CT; calcification occurs after 16 years of age.
- contains **pinealocytes** (epiphyseal cells) and is highly vascular, with fenestrated capillaries.

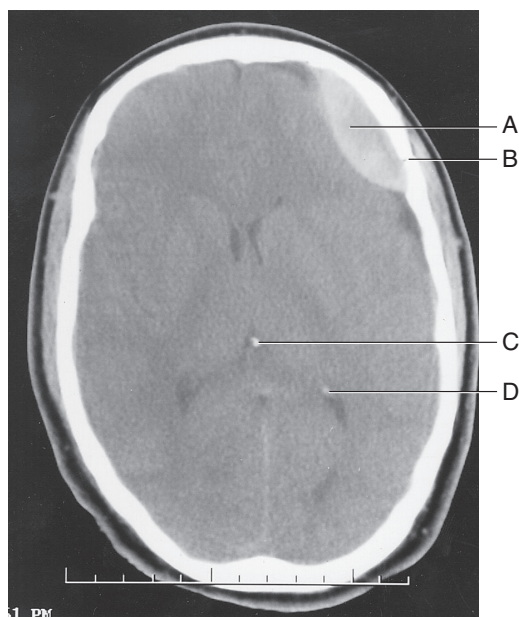


FIGURE 2.9. CT scan (axial section) showing an epidural hematoma and a skull fracture. The epidural hematoma has a classic biconvex, or lentiform, shape. (A) Epidural hematoma; (B) skull fracture; (C) calcified pineal gland; (D) calcified glomus in the trigone region of the lateral ventricle.

- derived from the diencephalon.
- innervated solely via postganglionic fibers from the superior cervical ganglion of the autonomic nervous system.
- synthesizes serotonin and melatonin. Clinical observation suggests an **antigonadotrophic function**.
- **Pinealomas** may result in dorsal midbrain syndrome (see Figure 12.3A).

F. Area postrema (Figure 2.9)

- consists of two small subependymal oval areas on either side of the fourth ventricle, rostral to the obex.
- contains modified neurons and astrocyte-like cells surrounded by fenestrated capillaries.
- considered to be a chemoreceptor zone that triggers vomiting in response to circulating emetic substances.
- plays a role in food intake and cardiovascular regulation.

Review Test

1. A 25-year-old woman complains of headaches of 4 months' duration. She is obese and has bilateral papilledema, and her vision is deteriorating. Her opening CSF pressure is elevated; other CSF findings are normal. CT and MRI scans are normal. These signs are due to the result of impairment of CSF egress. At which of the following loci is obstruction most likely?

- (A) Arachnoid villi
- (B) Cerebral aqueduct
- (C) Foramen of Luschka (lateral)
- (D) Foramen of Magendie (median)
- (E) Foramen of Monro (interventricular)

2. Which of the following pathogens would most likely be seen in bacterial meningitis of the newborn?

- (A) *Haemophilus influenzae*
- (B) Herpes simplex type 2
- (C) *Neisseria meningitidis*
- (D) *Streptococcus agalactiae*
- (E) *Streptococcus pneumoniae*

3. Which part of the ventricular system contains choroid plexus?

- (A) Cerebral aqueduct
- (B) Frontal horn
- (C) Interventricular foramen
- (D) Occipital horn
- (E) Third ventricle

4. Choose the normal quantity of daily CSF production.

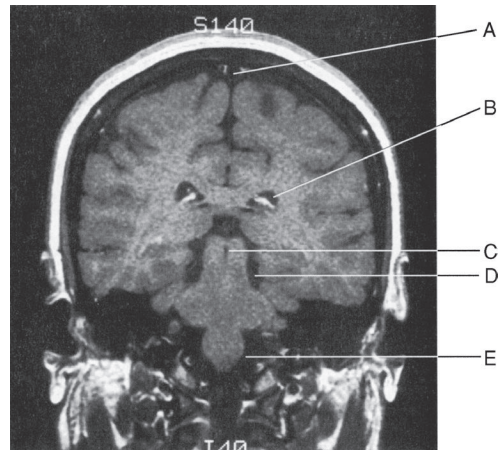
- (A) 300 ml
- (B) 400 ml
- (C) 500 ml
- (D) 600 ml
- (E) 700 ml

5. Which one of the following tumors contains cellular whorls and psammoma bodies?

- (A) Acoustic schwannoma
- (B) Astrocytoma
- (C) Glioblastoma multiforme
- (D) Meningioma
- (E) Oligodendroglioma

Questions 6 to 10

Match each structure or description in items 6 to 10 with the appropriate lettered structure shown in the T₁-weighted MRI of a coronal section of the brain.



6. Olive

7. It contains the trochlear nerve (CN IV)

8. Its stenosis results in hydrocephalus

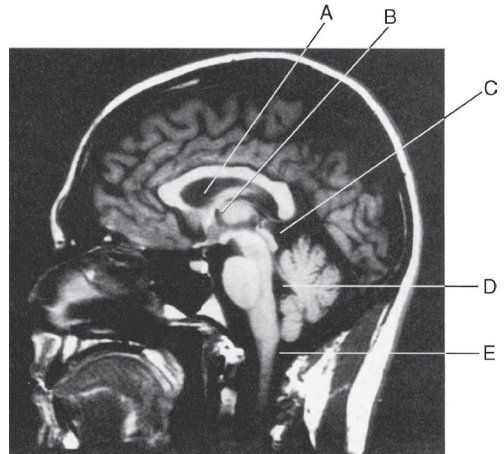
9. Contains a calcified glomus

10. Receives CSF from the arachnoid villi

Questions 11 to 15

Match each structure or description in items 11 to 15 with the appropriate lettered structure shown on the T₁-weighted MRI of a midsagittal section of the brain.

- 11. Superior cistern
- 12. Blockage resulting in hydrocephalus
- 13. Lateral ventricle
- 14. Contains the two lateral foramina of Luschka
- 15. Receives CSF via the median foramen (of Magendie)



Answers and Explanations

- 1–A.** This condition, called pseudotumor cerebri (benign intracranial hypertension), is seen primarily in young obese women. It is linked to an excessive amount of CSF.
- 2–D.** *Streptococcus agalactiae* is seen frequently in newborns. *Haemophilus influenzae* immunization has greatly reduced this type of meningitis. *S. pneumoniae* is frequently the cause of meningitis in older adults. *Neisseria meningitidis* is seen in older children to middle-aged adults. Herpes simplex type 2 is a virus.
- 3–E.** The third ventricle has a choroid plexus; the frontal lobe, the occipital lobe, and the cerebral aqueduct are all devoid of a choroid plexus; the interventricular foramen has no choroid plexus.
- 4–C.** The choroid plexus produces CSF at a rate of 500 ml/day.
- 5–D.** Meningiomas contain cellular whorls and calcified psammoma bodies; are associated with neurofibromatosis-2; gender, females > males; astrocytomas type II have near normal cellularity, little nuclear pleomorphism, no endothelial proliferation, and no necrosis; acoustic schwannomas are benign tumors arising from Schwann cells—histopathology shows Antoni A and Antoni B tissue and Verocay bodies; oligodendrogliomas show calcification in 50% of cases—cells look like fried eggs (perinuclear halos); glioblastoma multiforme represents 55% of gliomas, is malignant and rapidly fatal; most common primary brain tumor; contains pseudopalis, peravascular pseudorosettes, and microvascular proliferation.
- 6–E.** The olive is a prominent surface structure of the medulla.
- 7–D.** The ambient cistern contains the trochlear nerve (CN IV).
- 8–C.** Stenosis of the cerebral aqueduct prevents CSF from entering the fourth ventricle; this results in a noncommunicating hydrocephalus.
- 9–B.** The trigone of the lateral ventricle contains a large tuft of choroid plexus called the glomus. It is usually calcified and highly visible in CT images.
- 10–A.** The superior sagittal sinus receives CSF via the arachnoid villi.
- 11–C.** The superior (quadrigeminal) cistern overlies the dorsal/posterior aspect of the midbrain.
- 12–B.** Blockage of the interventricular foramen (of Monro) (e.g., due to a colloid cyst of the third ventricle) results in hydrocephalus involving the lateral ventricle.
- 13–A.** The lateral ventricle is seen between the corpus callosum and the fornix.
- 14–D.** The fourth ventricle contains the two lateral foramina (of Luschka), which drain into the two cerebellopontine angle cisterns.
- 15–E.** The cerebellomedullary cistern receives CSF via the median foramen (of Magendie).

Blood Supply of the Central Nervous System

Objectives

- List the major branches of the vertebral and internal carotid arteries and indicate the regions/structures that each artery supplies.
- Describe the cerebral arterial circle (of Willis).
- List the major deep cerebral veins.
- Explain and identify the dural venous sinuses and include a description of their drainage patterns and location of each sinus.
- Describe the various types of intercranial hemorrhage.

I. ARTERIES OF THE SPINAL CORD

- arise from the vertebral and segmental arteries.

A. Vertebral artery (Figure 3.1)

- a branch of the subclavian artery.
- gives rise to the anterior spinal artery and may give rise to the posterior spinal artery.
 1. **Anterior spinal artery**
 - supplies the anterior two-thirds of the spinal cord, including the anterior and lateral horns and anterior and lateral funiculi.
 - supplies the pyramids, medial lemniscus, and intra-axial fibers of the hypoglossal nerve (CN XII) in the medulla.
 2. **Posterior spinal arteries**
 - supply the posterior third of the spinal cord, including the posterior horns and columns.
 - supply the gracile and cuneate fasciculi and nuclei in the medulla.

B. Segmental arteries

- arise from the aorta, vertebral arteries, and common iliac arteries as medullary arteries, which anastomose with the anterior and posterior spinal arteries.
- provide the main blood supply to the spinal cord at thoracic and lumbar levels where the spinal arteries become inconsistent. Typically the second lumbar artery gives rise to a large anterior medullary artery, the **artery of Adamkiewicz**. Its origin varies from T12 to L4, and it usually arises on the left side.

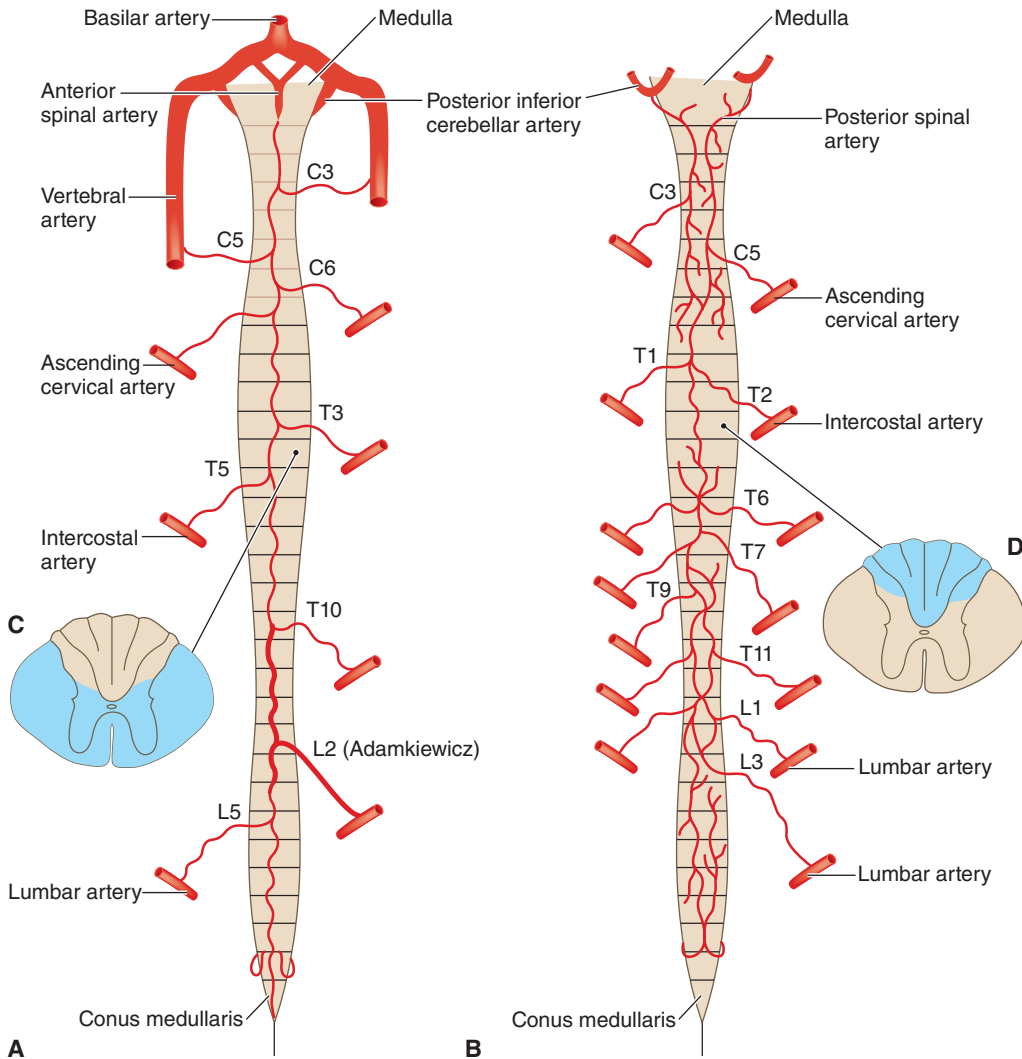


FIGURE 3.1. Arterial blood supply of the spinal cord. **(A)** Anterior surface, **(B)** posterior surface, **(C)** occlusion of the anterior spinal artery resulting in infarction of the anterior two-thirds of the spinal cord, **(D)** occlusion of the posterior spinal arteries resulting in infarction of the posterior columns. Note the large lumbar feeder artery of Adamkiewicz, whose origin varies from segments T12 to L4. (Adapted from Parent A. *Carpenter's Human Neuroanatomy*. 9th ed. Baltimore, MD: Williams & Wilkins; 1995:94 with permission.)

II. VENOUS DRAINAGE OF THE SPINAL CORD

- generally follow the arterial pattern.
- blood passes from spinal veins within the subarachnoid space to the epidural internal venous plexus before draining into intracranial, cervical, thoracic, intercostal, or abdominal veins.
- conducted by valveless veins that permit bidirectional flow, depending on the existing pressure gradients and body position.
- a pathway for transmission of infectious agents and tumor cells.

III. ARTERIES OF THE BRAIN (FIGURES 3.2 THROUGH 3.6)

- provide the brain with 20% of the oxygen used by the body; 15% of the cardiac output goes to the brain.
- have a normal blood flow of 50 ml/100 g of brain tissue per minute.
- consist of two pairs of vessels—the **internal carotid arteries** and the **vertebral arteries**. At the junction between the medulla and the pons, the two vertebral arteries fuse to form the **basilar artery**.

A. Internal carotid artery

- enters the cranium via the carotid canal of the temporal bone.
- lies within the cavernous sinus as the carotid siphon.
- supplies tributaries to the dura mater, hypophysis, tympanic cavity, and trigeminal ganglion.
- provides branches to the optic nerve, optic chiasm, hypothalamus, and genu of the internal capsule.
- the following branches are given off from the artery:
 1. **Ophthalmic artery**
 - enters the apex of the orbit via the optic canal with the optic nerve (CN II).
 2. **Central artery of the retina**
 - a branch of the **ophthalmic artery** that runs with the optic nerve.
 - provides the only blood supply to the inner aspect of the retina.
 - an end artery; its **occlusion results in blindness**.

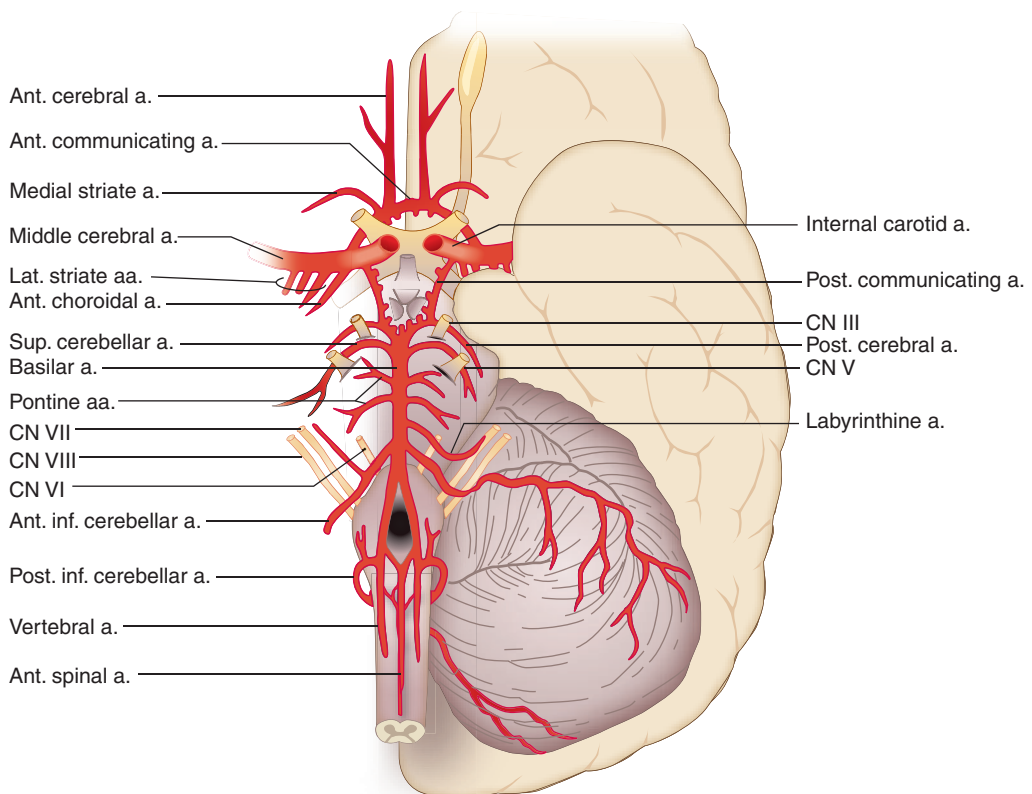


FIGURE 3.2. Arteries of the base of the brain and brainstem, including the arterial circle of Willis. The medial and lateral striate arteries and the anterior choroidal artery supply the basal nuclei and internal capsule.

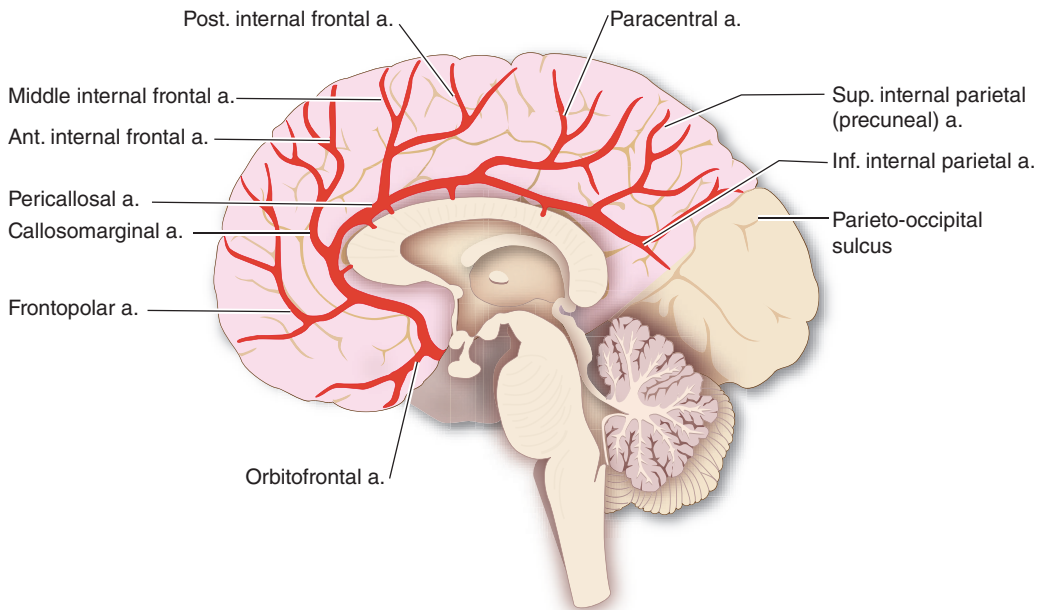


FIGURE 3.3. Cortical branches of the anterior cerebral artery on the medial hemispheric surface. The temporal pole is supplied by the middle cerebral artery; the occipital lobe is supplied by the posterior cerebral artery.

3. Posterior communicating artery (see Figures 3.2 and 3.6)

- joins the posterior and the middle cerebral arteries.
- supplies the optic chiasm and tract, hypothalamus, subthalamus, and anterior half of the ventral/inferior portion of the thalamus.
- a common site of berry aneurysms.

4. Anterior choroidal artery (see Figures 3.2 and 3.6)

- arises from the internal carotid artery.
- supplies the choroid plexus of the temporal horn of the lateral ventricle, hippocampus, amygdala, optic tract, lateral geniculate body, globus pallidus, and part of the posterior limb of the internal capsule.

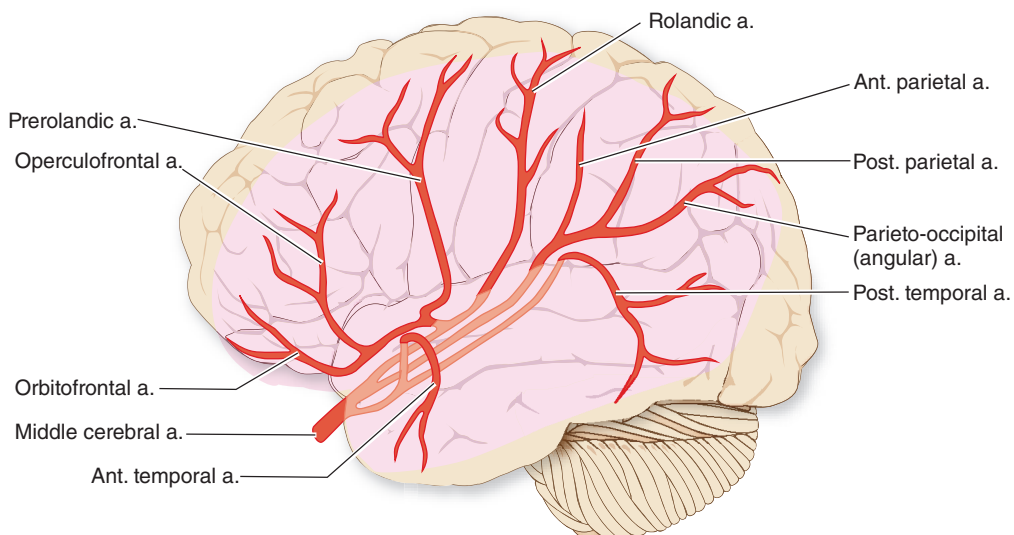


FIGURE 3.4. Cortical branches of the middle cerebral artery. The *unshaded* area represents the terminal territories of the anterior and posterior cerebral arteries.

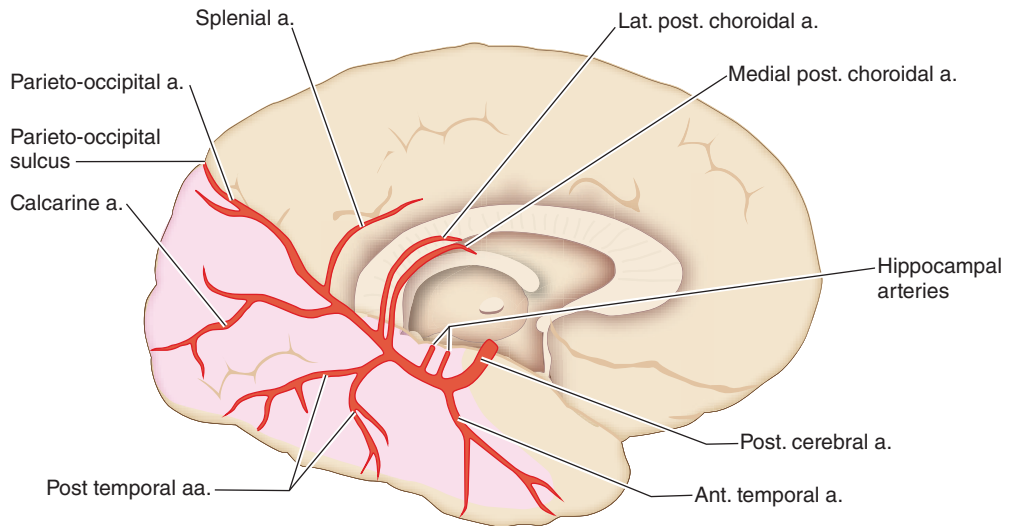


FIGURE 3.5. Cortical branches of the posterior cerebral artery seen from the inferior and medial surfaces. The splenium of the corpus callosum is supplied by the callosal branch of the posterior cerebral artery.

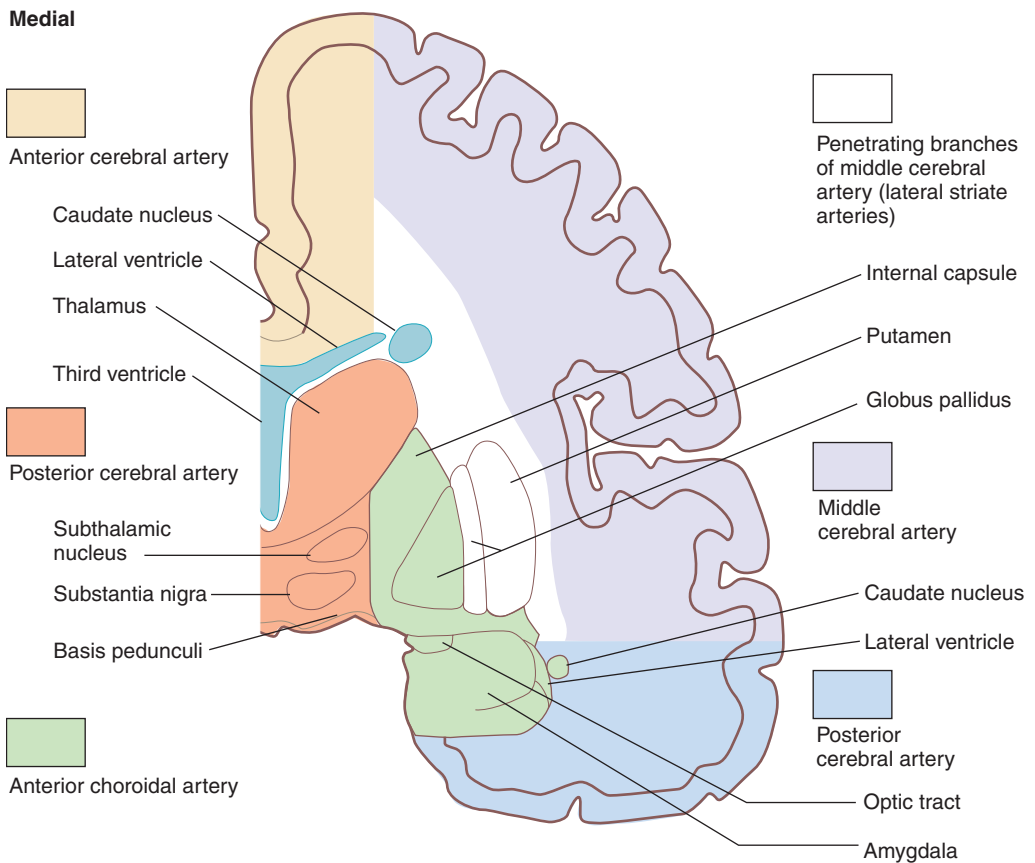


FIGURE 3.6. Schematic drawing of a coronal section through the cerebral hemisphere at the level of the internal capsule and thalamus, showing the major vascular territories. (Modified from Fix JD. *High-Yield Neuroanatomy*. 3rd ed. Philadelphia, PA: Lippincott Williams & Wilkins; 2005:31.)

- supplies the proximal portion of the optic radiations as they leave the lateral geniculate body to form Meyer's loop.
- 5. **Anterior cerebral artery** (see Figure 3.3)
 - together with the middle cerebral artery is one of the terminal branches of the internal carotid artery.
 - branches into the optic chiasm.
 - supplies the medial surface of the frontal and parietal lobes and the corpus callosum.
 - supplies part of the corpus striatum and the anterior limb of the internal capsule via the **medial striate artery (of Heubner)** (see Figure 3.2).
 - supplies the leg and foot area of the motor and sensory cortices (paracentral lobule) (see Figure 22.1).
- 6. **Anterior communicating artery**
 - connects the two anterior cerebral arteries.
 - the commonest site of berry aneurysms.
- 7. **Middle cerebral artery** (see Figures 3.3 and 3.5)
 - together with the anterior cerebral artery is one of the terminal branches of the internal carotid artery.
 - supplies the lateral convexity of the cerebral hemisphere and insula.
 - supplies the trunk, arm, and face areas of the motor and sensory cortices.
 - supplies Broca's and Wernicke's speech areas.
 - supplies the striatum, pallidum, and anterior and posterior limbs of the internal capsule via the **lateral striate arteries**.

B. Vertebral artery (see Figure 3.1)

- a branch of the subclavian artery.
- joins to form the basilar artery.
 1. **Anterior spinal artery**
 2. **Posterior inferior cerebellar artery**
 - gives rise to the posterior spinal artery.
 - supplies the dorsolateral zone of the medulla.
 - supplies the inferior surface of the cerebellum and the choroid plexus of the fourth ventricle.
 - supplies the medial and inferior vestibular nuclei, inferior cerebellar peduncle, nucleus ambiguus, intra-axial fibers of the glossopharyngeal nerve (CN IX) and the vagal nerve (CN X), spinothalamic tract, and spinal trigeminal nucleus and tract.
 - supplies the hypothalamospinal tract to the ciliospinal center (of Budge) at T1–T2 (Horner syndrome).

C. Basilar artery (see Figure 3.1)

- formed by the joining of the two vertebral arteries.
 1. **Pontine arteries**
 - include penetrating and short circumferential branches.
 - supply corticospinal tracts and the intra-axial exiting fibers of the abducent nerve (CN VI).
 2. **Labyrinthine artery**
 - supplies the inner ear.
 3. **Anterior inferior cerebellar artery**
 - supplies the inferior surface of the cerebellum.
 - supplies the facial motor nucleus and intra-axial fibers, spinal trigeminal nucleus and tract, vestibular nuclei, cochlear nuclei, intra-axial fibers of the vestibulocochlear nerve, spinothalamic tract, and inferior and middle cerebellar peduncles.
 - gives rise to the labyrinthine artery in 85% of the population.
 - supplies the hypothalamospinal tract (Horner syndrome).
 4. **Superior cerebellar artery**
 - supplies the superior surface of the cerebellum and the cerebellar nuclei.
 - supplies the rostral and lateral pons, including the superior cerebellar peduncle and spinothalamic tract.

5. Posterior cerebral artery (see Figure 3.5)

- forms the terminal branches of the basilar artery.
- provides the major blood supply to the midbrain.
- supplies the posterior half of the thalamus and the medial and lateral geniculate bodies.
- supplies the occipital lobe, visual cortex, and inferior surface of the temporal lobe, including the hippocampal formation.
- gives rise to the lateral and medial **posterior choroidal arteries** that supply the dorsal thalamus, pineal body, and choroid plexus of the third and lateral ventricles.

IV. CEREBRAL ARTERIAL CIRCLE (OF WILLIS) (SEE FIGURE 3.2)

- formed by the anterior communicating, anterior cerebral, internal carotid, posterior communicating, and posterior cerebral arteries.
- gives off penetrating arteries to supply the inferior aspect, hypothalamus, subthalamus, thalamus, and the midbrain.

V. MENINGEAL ARTERIES

- supply the intracranial dura mater.
- usually arise from branches of the external carotid artery.

A. Anterior meningeal arteries

- arise from the anterior and posterior ethmoidal arteries.
- supply the dura mater of the anterior cranial fossa.

B. Middle meningeal artery

- a branch of the **maxillary artery**.
- enters the cranium via the **foramen spinosum**.
- lies between the periosteal and meningeal dura deep into the temporal and parietal bones.
- supplies most of the dura mater.
- laceration results in **epidural hemorrhage** (hematoma).

C. Posterior meningeal arteries

- branches of the ascending pharyngeal, vertebral, and occipital arteries.
- supply the dura mater of the posterior cranial fossa.

VI. VEINS OF THE BRAIN

- devoid of valves and lie along the surface sulci.
- drain from the cortex and subcortical substance.
- terminate in the dural sinuses.

A. Superficial cerebral veins

- drain into the superior sagittal sinus (bridging veins).
- laceration of these vessels results in subdural hemorrhage (hematoma).

B. Deep cerebral veins (see Figures 3.8 and 3.13)

- drain the deep subcortical structures of the cerebral hemispheres: **septal area, thalamus, and basal nuclei.**
 - 1. Internal cerebral veins**
 - drain the following vessels:
 - a. Septal vein**
 - b. Thalamostriate vein**
 - c. Terminal vein**
 - d. Venous angle**
 - the point where the septal and the thalamostriate veins meet.
 - marks the location of the interventricular foramen (of Monro).
 - 2. Great cerebral vein (of Galen)**
 - receives blood from the internal cerebral veins and drains into the straight sinus.

VII. VENOUS DURAL SINUSES (FIGURE 3.7)

- endothelium-lined valveless channels whose walls are formed by the periosteal and meningeal layers of dura mater.
- collect blood from the superficial and deep cerebral veins.
- receive arachnoid granulations and absorb cerebrospinal fluid (CSF).

A. Superior sagittal sinus (see Figure 2.3)

- extends from the foramen cecum to the internal occipital protuberance and usually terminates in the right transverse sinus.
- receives blood from the superficial cerebral veins, diploic veins, and emissary veins.
- receives most arachnoid granulations.

B. Inferior sagittal sinus

- courses in the inferior (free) edge of the falx cerebri.
- joins the great cerebral vein to form the straight sinus.

C. Straight sinus

- formed by the junction of the great cerebral vein and the inferior sagittal sinus.
- terminates at the internal occipital protuberance and usually drains into the left transverse sinus.
- drains the superior surface of the cerebellum.

D. Left and right transverse sinuses

- originate at the confluence of the sinuses and course anterolaterally along the edge of the tentorium cerebelli to become the sigmoid sinus at the point where the superior petrosal sinuses join it.

E. Confluence of the sinuses

- lies at the internal occipital protuberance.
- formed by the union of the superior sagittal, straight, and transverse sinuses.

F. Sigmoid sinus

- a continuation of the transverse sinus at the superior petrosal sinuses.
- passes inferiorly and medially into the jugular foramen.

G. Sphenoparietal sinus

- lies along the lesser wing of the sphenoid bone and drains into the cavernous sinus.

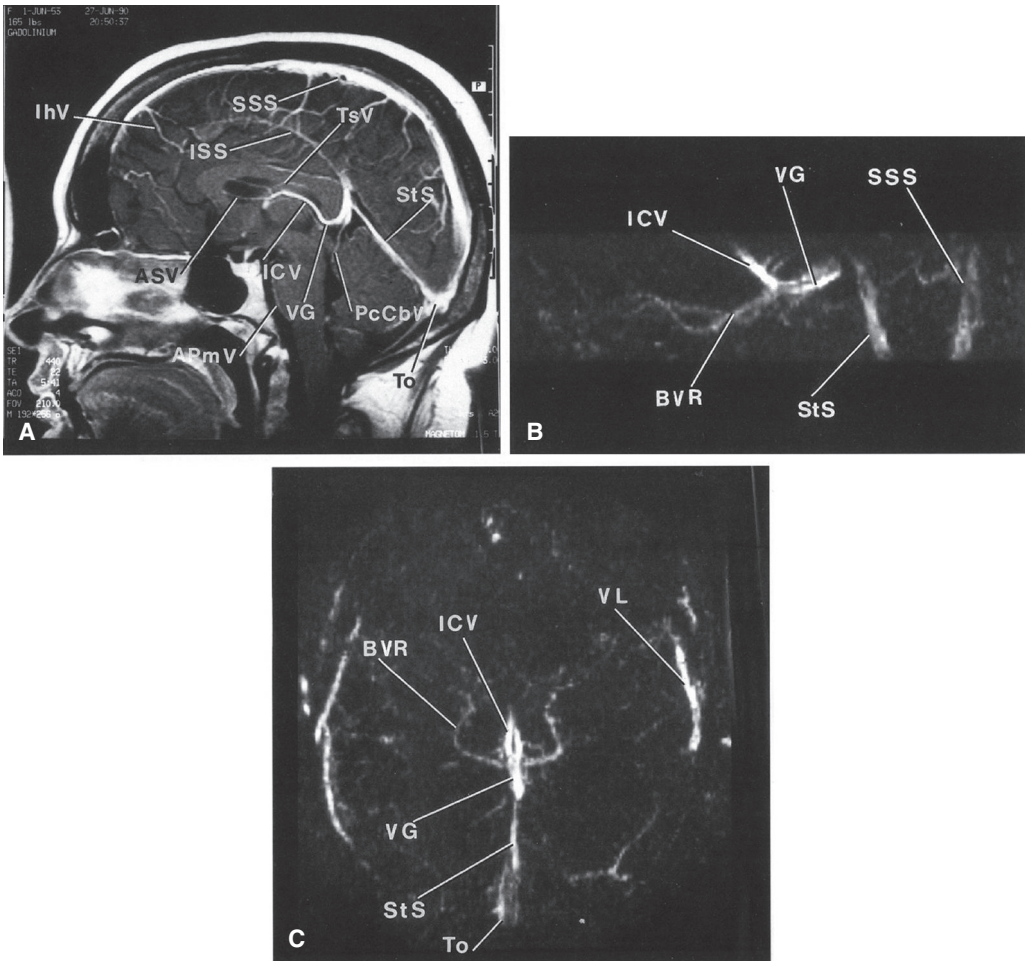


FIGURE 3.7. Venous anatomy of a magnetic resonance section; midsagittal (**A**), lateral (**B**), and submental–vertex (**C**). *IhV* = interhemispheric veins; *SSS* = straight sinus; *PcCbV* = precentral cerebellar vein; *To* = torcula; *VG* = vein of anterior pontomesencephalic veins. (Modified from Grossman CB. *Magnetic Resonance Imaging and Computed Tomography of the Head and Spine*. 2nd ed. Philadelphia, PA: Williams & Wilkins; 1996:124.)

H. Superior petrosal sinus

- extends from the cavernous sinus to the junction of the transverse and sigmoid sinus.
- receives tributaries from the pons, medulla, cerebellum, and inner ear.

I. Inferior petrosal sinus

- passes between the glossopharyngeal (CN IX) and vagal (CN X) nerves and drains into the internal jugular vein after exiting the skull via jugular foramen.
- drains the inferior portion of the cerebellum.
- drains the cavernous sinus and clival plexus into the internal jugular vein.

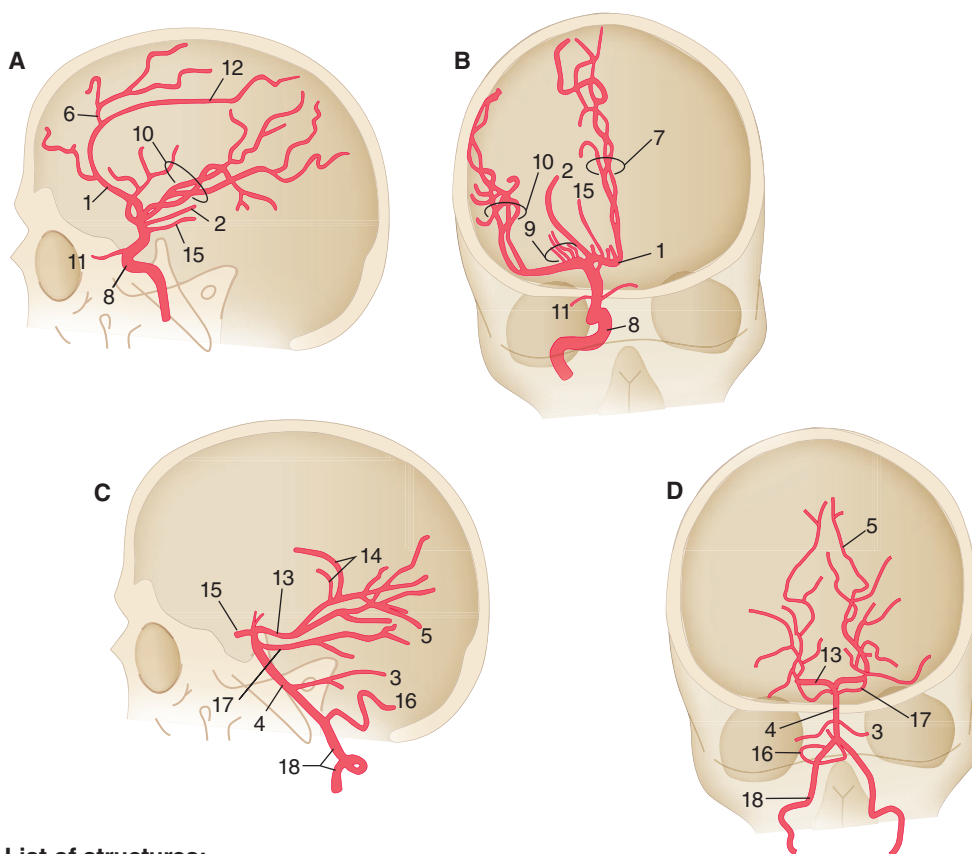
J. Cavernous sinus (see Figure 11.4)

- surrounds the sella turcica and the body of the sphenoid bone.
- contains, *within the sinus*, the internal carotid artery, its periarterial plexus, and the abducent nerve (CN VI).
- contains, *within the lateral wall of the sinus*, the oculomotor nerve (CN III), the trochlear nerve (CN IV), the ophthalmic nerve (CN V-1), and the maxillary branches (CN V-2) of the trigeminal nerve (CN V).
- receives blood from the superior and the inferior ophthalmic veins of the orbit.

VIII. ANGIOGRAPHY

A. Carotid angiography (Figures 3.8A and B through 3.11) shows the following arteries:

1. Internal carotid artery
2. Anterior cerebral artery
3. Middle cerebral artery



List of structures:

- | | |
|--|--|
| 1. Anterior cerebral artery | 10. Middle cerebral artery |
| 2. Anterior choroidal artery | 11. Ophthalmic artery |
| 3. Anterior inferior cerebellar artery | 12. Pericallosal artery |
| 4. Basilar artery | 13. Posterior cerebral artery |
| 5. Calcarine artery | 14. Posterior choroidal arteries |
| 6. Callosomarginal artery | 15. Posterior communicating artery |
| 7. Callosomarginal and pericallosal arteries (of anterior cerebral artery) | 16. Posterior inferior cerebellar artery |
| 8. Internal carotid artery | 17. Superior cerebellar artery |
| 9. Lateral striate arteries | 18. Vertebral artery |

FIGURE 3.8. (A) Carotid angiogram, lateral projection; (B) carotid angiogram, anteroposterior projection; (C) vertebral angiogram, lateral projection; (D) vertebral angiogram, anteroposterior projection. (Modified from Fix JD. *High-Yield Neuroanatomy*. 3rd ed. Philadelphia, PA: Lippincott Williams & Wilkins; 2005:33.)

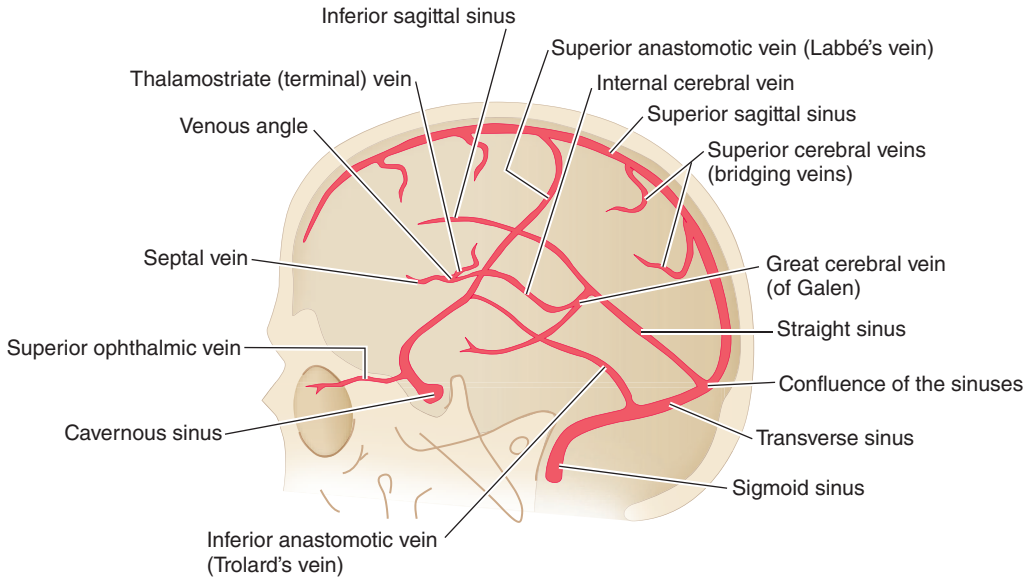


FIGURE 3.9. Carotid angiogram, venous phase, lateral projection showing cerebral veins and venous sinuses. (Modified from Fix JD. *High-Yield Neuroanatomy*. 3rd ed. Philadelphia, PA: Lippincott Williams & Wilkins; 2005:36.)

B. Vertebral angiography (see Figures 3.8C and D; Figures 3.12 and 3.13) shows the following arteries:

1. **Vertebral artery**
2. **Posterior inferior cerebellar artery**
3. **Basilar artery**
4. **Anterior inferior cerebellar artery**
5. **Superior cerebellar artery**
6. **Posterior cerebral artery**

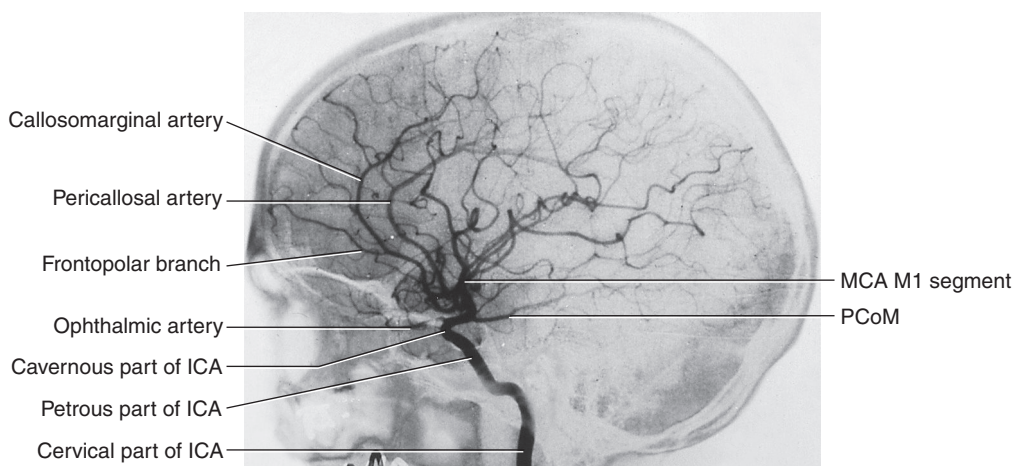


FIGURE 3.10. Carotid angiogram, lateral projection. Identify the cortical branches of the anterior cerebral artery (ACA) and middle cerebral artery (MCA). Follow the course of the internal carotid artery (ICA). PCoM = posterior communicating artery. (Modified from Fix JD. *High-Yield Neuroanatomy*. 3rd ed. Philadelphia, PA: Lippincott Williams & Wilkins; 2005:36.)

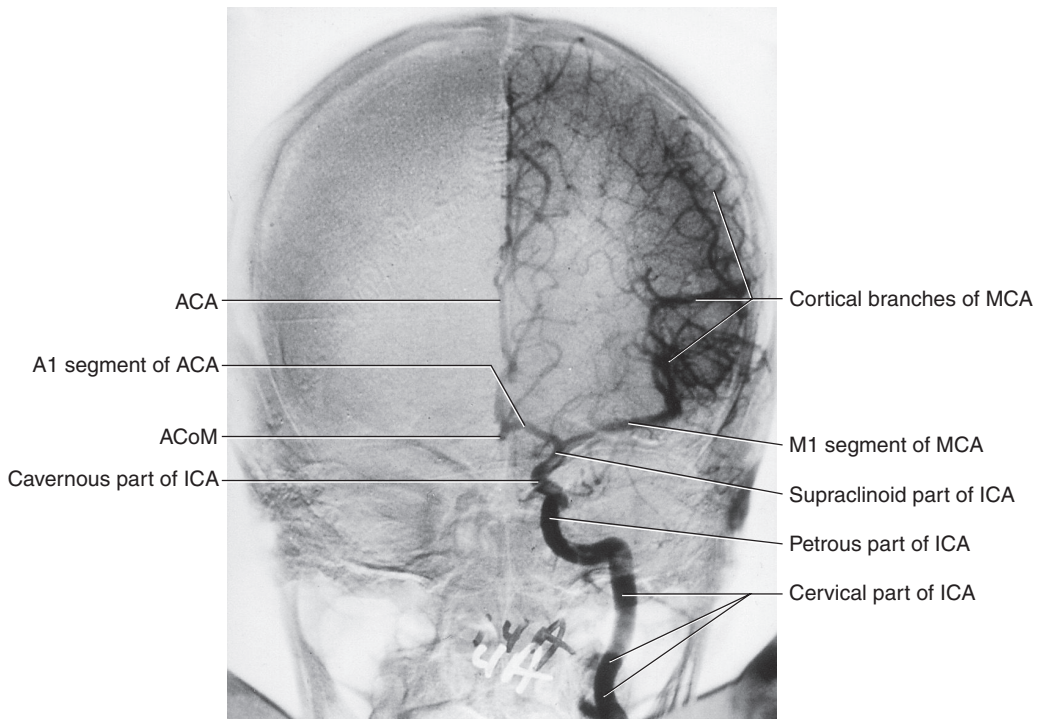


FIGURE 3.11. Carotid angiogram, anteroposterior projection. Identify the anterior cerebral artery (ACA), middle cerebral artery (MCA), and internal carotid artery (ICA). ACoM = anterior communicating artery. (Modified from Fix JD. *High-Yield Neuroanatomy*. 3rd ed. Philadelphia, PA: Lippincott Williams & Wilkins; 2005:37.)

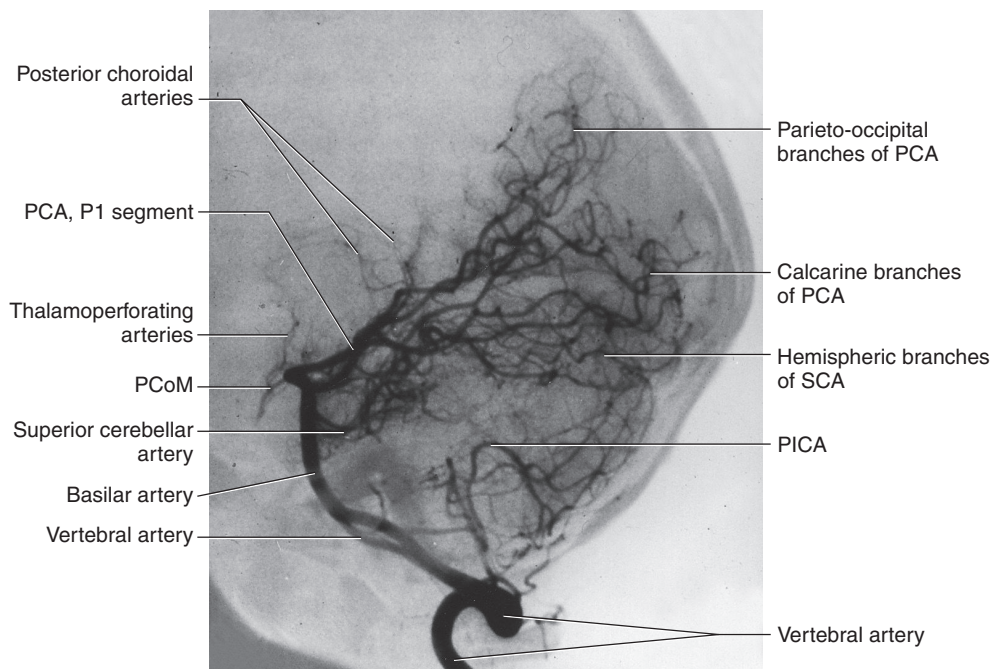


FIGURE 3.12. Vertebral angiogram, lateral projection. PCoM = posterior communicating artery; PICA = posterior inferior cerebellar artery; SCA = superior cerebellar artery. (Modified from Fix JD. *High-Yield Neuroanatomy*. 3rd ed. Philadelphia, PA: Lippincott Williams & Wilkins; 2005:37.)

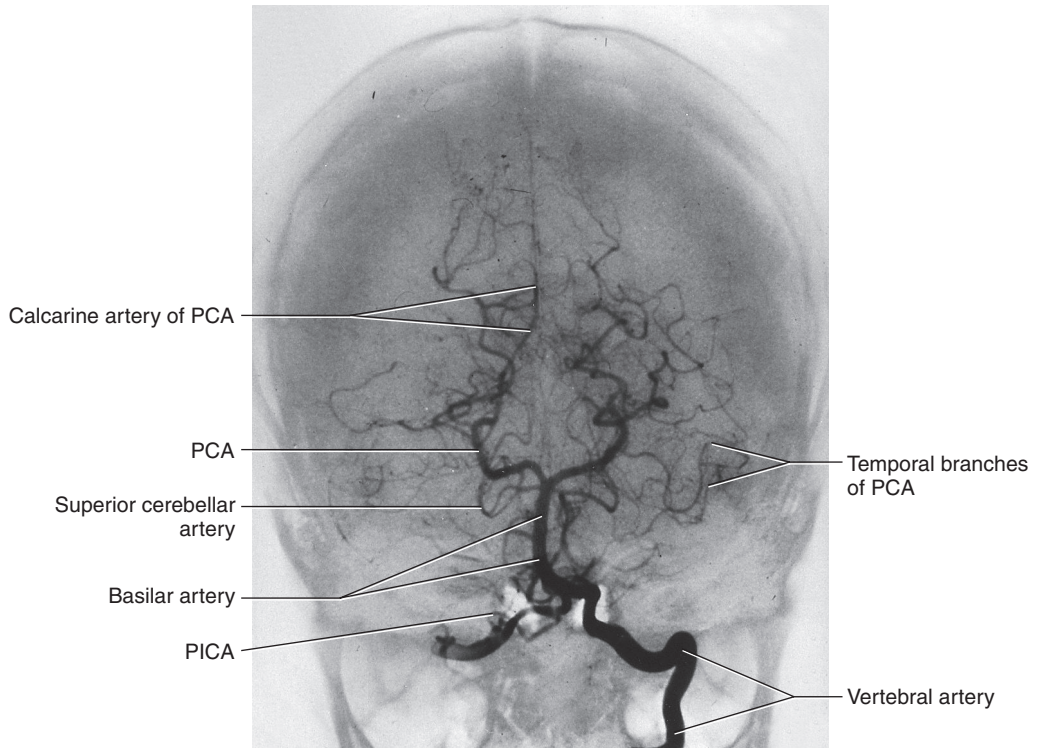


FIGURE 3.13. Vertebral angiogram, anteroposterior projection. Occlusion of the posterior cerebral artery (PCA; calcarine artery) results in a contralateral homonymous hemianopia, with macular sparing. PICA = posterior inferior cerebellar artery. (Modified from Fix JD. *High-Yield Neuroanatomy*. 3rd ed. Philadelphia, PA: Lippincott Williams & Wilkins; 2005:38.)

C. Cerebral veins and dural sinuses (Figure 3.14)

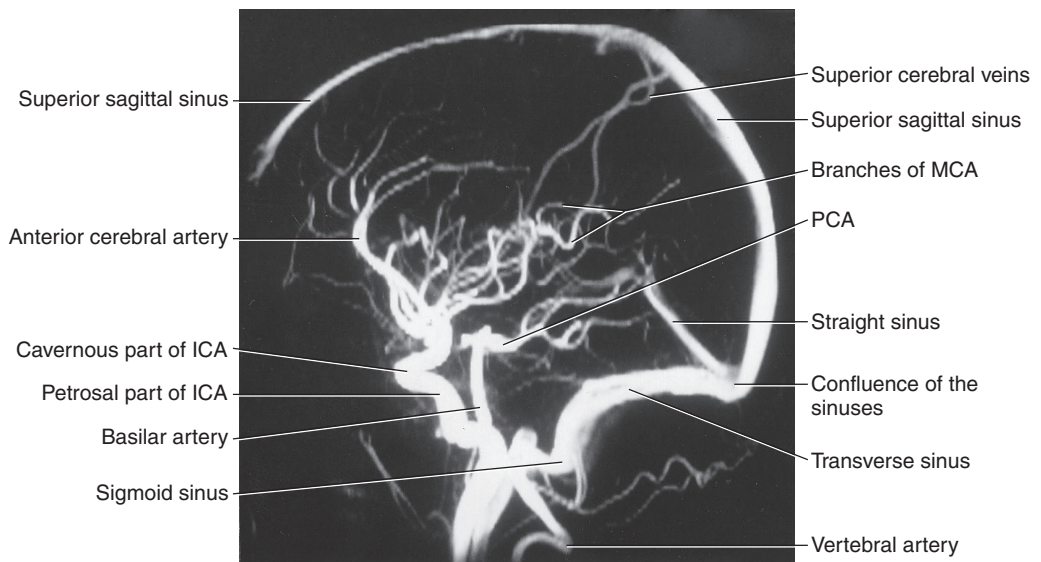

FIGURE 3.14. Magnetic resonance angiogram—lateral projection—showing the major venous sinuses and arteries. Note the bridging veins entering the superior sagittal sinus. ICA = internal carotid artery; MCA = middle cerebral artery; and PCA = posterior cerebral artery. (Modified from Fix JD. *High-Yield Neuroanatomy*. 3rd ed. Philadelphia, PA: Lippincott Williams & Wilkins; 2005:32.)

IX. INTRACRANIAL HEMORRHAGE

A. Aneurysms

- circumscribed dilations (ectasias) of an artery.
 1. **Berry (saccular) aneurysms** (Figure 3.15)
 - typically develop at arterial bifurcations. The **cerebral arterial circle** contains 60% of aneurysms; 30% arise from the middle cerebral artery; and the remaining 10% are found in the vertebrobasilar system.
 - of the anterior communicating artery may pressure the optic chiasm and cause a **bitemporal lower quadrantanopia**.
 - of the posterior communicating artery may cause a **oculomotor nerve palsy**.
 - rupture is a common cause of nontraumatic **subarachnoid hemorrhage**.
 2. **Microaneurysms (Charcot–Bouchard aneurysms)**
 - found in small arteries, most frequently within the territory of the middle cerebral artery (i.e., the lenticulostriate arteries).
 - rupture occurs most frequently in the basal nuclei and is the commonest cause of non-traumatic **intraparenchymal hemorrhage**.

B. Subdural hemorrhage (hematoma) (Figure 3.16)

- results from **rupture of the superior cerebral veins**, the “bridging” veins that drain into the superior sagittal sinus.

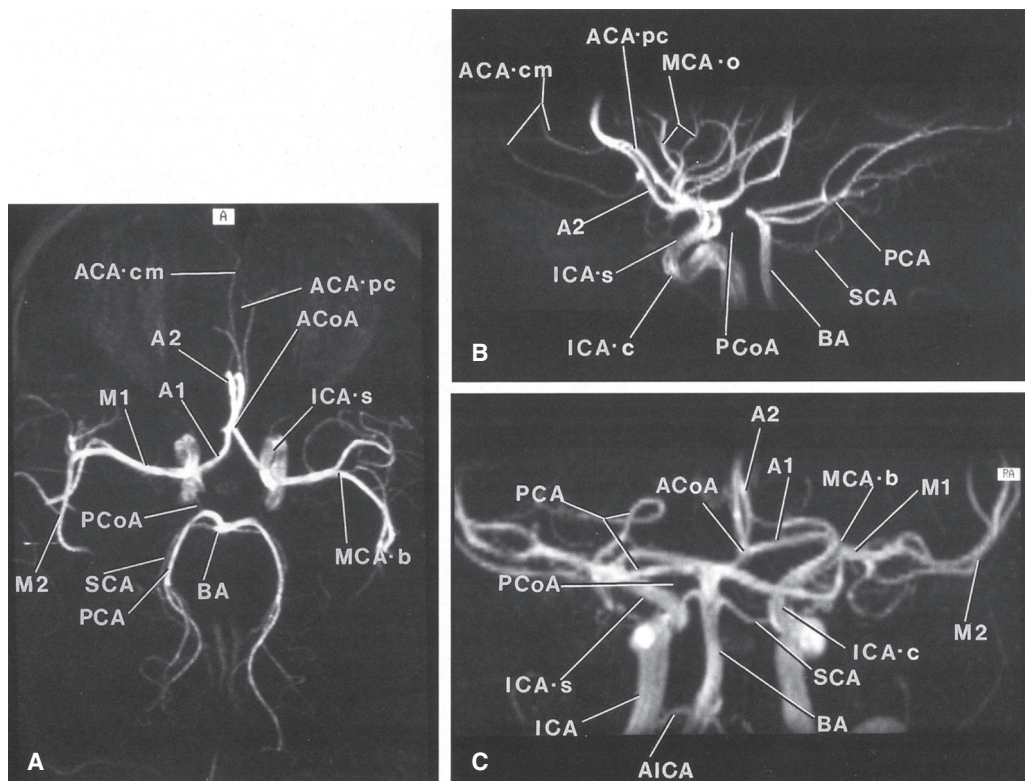


FIGURE 3.15. Arterial anatomy of a magnetic resonance section: axial (A), sagittal (B, C), and coronal (C). ACA_{cm} = anterior cerebral artery, callosal marginal branch; A2 and A1 are branches of the anterior cerebral artery; ACA_{pc} = pericallosal branch of the anterior cerebral artery; ACoA = anterior communicating artery; M1 and M2 are segments of the middle cerebral artery (MCA); MCA_b = bifurcation; ICAs = internal carotid artery siphon; PAC = posterior cerebral artery; PCoA = posterior communicating artery; BA = basilar artery; and SCA = superior cerebellar artery. (Modified from Grossman CB. *Magnetic Resonance Imaging and Computed Tomography of the Head and Spine*. 2nd ed. Philadelphia, PA: Williams & Wilkins; 1996:124.)

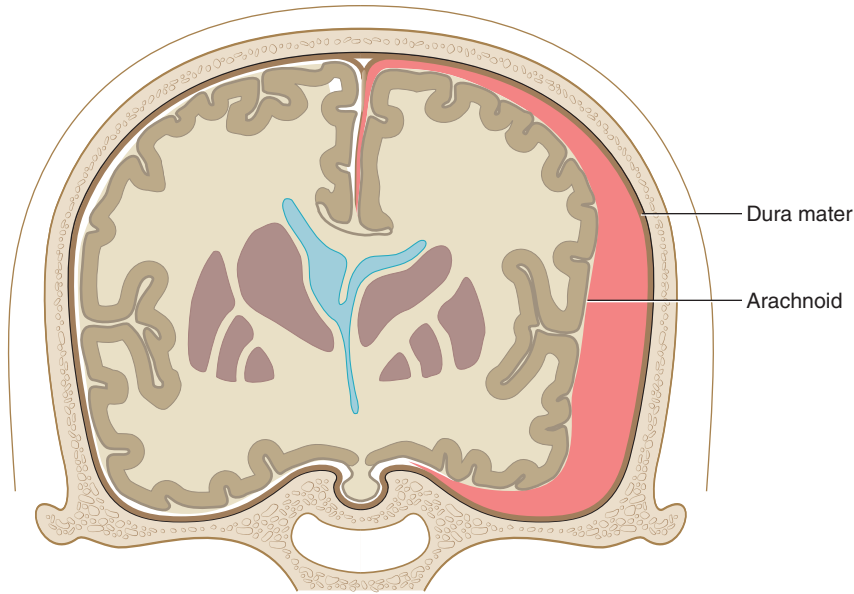


FIGURE 3.16. Subdural hematomas result from lacerated bridging veins. Subdural hematomas are frequently accompanied by traumatic subarachnoid hemorrhages and cortical contusions. Sudden deceleration of the head causes tearing of the superior cerebral veins. The hematoma extends over the crest of the convexity into the interhemispheric fissure but does not cross the dural attachment of the falx cerebri; the clot can be crescent-shaped, biconvex, or multiloculated. Subdural hematomas, which are more common than epidural hematomas, commonly cause brain damage. (Modified from Osburn AG, Tong KA. *Handbook of Neuroradiology: Brain and Skull*. St Louis, MO: Mosby; 1996:192.)

C. Epidural hemorrhage (hematoma) (Figure 3.17)

- typically result from **rupture of the middle meningeal artery** that lies between the dura mater and the inner table of the skull.

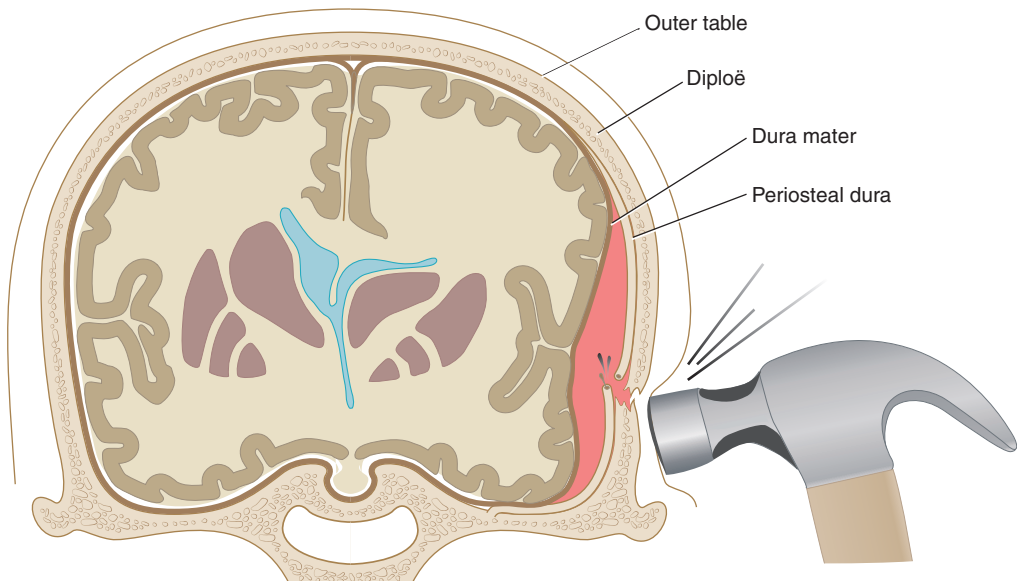


FIGURE 3.17. Epidural hematomas result from laceration of the meningeal arteries. Arterial bleeding into the epidural space forms a biconvex clot. The classic lucid interval is seen in 50% of cases. Skull fractures are typically found. Epidural hematomas seldom cross sutural lines. (Modified from Osburn AG, Tong KA. *Handbook of Neuroradiology: Brain and Skull*. St Louis, MO: Mosby; 1996:191.)

Review Test

1. A 50-year-old hypertensive woman complains of numbness and weakness in her left leg and foot. Which of the following arteries' occlusion can account for this complaint?

- (A) Anterior cerebral
- (B) Anterior choroidal
- (C) Interior carotid
- (D) Middle cerebral
- (E) Posterior

2. A 15-year-old boy is hit on the temple with a baseball and becomes unconscious. After about 10 minutes, he regains consciousness, but he soon becomes lethargic, and over the next 2 hours, he becomes stuporous. His pupils are unequal. Intracranial hemorrhage is suspected. Which of the following arteries is most likely to be the source of the hemorrhage?

- (A) Anterior cerebral
- (B) Anterior communicating
- (C) Basilar
- (D) Middle cerebral
- (E) Middle meningeal

3. Which artery supplies the caudate and putamen and anterior limb of the internal capsule via the medial striate artery (of Heubner)?

- (A) Anterior cerebral
- (B) Anterior choroidal
- (C) Anterior communicating
- (D) Middle cerebral
- (E) Posterior communicating

4. Which artery supplies the cochlea?

- (A) Anterior inferior cerebellar
- (B) Labyrinthine
- (C) Pontine
- (D) Posterior cerebral
- (E) Superior cerebellar

5. Which sinus drains the superior surface of the cerebellum?

- (A) Inferior petrosal
- (B) Inferior sagittal

- (C) Sigmoid
- (D) Sphenoparietal
- (E) Straight

6. A 40-year-old female graduate student had an excruciating headache. When she looked in the mirror, she noticed that her eyelid was drooping; when she lifted the eyelid, she saw that her eyeball was looking down and out and her pupil was huge. She complained of both blurred and double vision. An magnetic resonance angiogram scan showed an aneurysm of the cerebral arterial circle. Which artery gives rise to the offending aneurysm?

- (A) Anterior choroidal
- (B) Anterior communicating
- (C) Charcot-Bouchard's
- (D) Heubner's
- (E) Posterior communicating

Questions 7 to 11

The response options for items 7 to 11 are the same. Select one answer for each item in the set.

- (A) Anterior inferior cerebellar artery
- (B) Anterior spinal artery
- (C) Posterior cerebral artery
- (D) Posterior inferior cerebellar artery
- (E) Superior cerebellar artery

Match each of the following descriptions with the most appropriate artery.

7. Usually gives rise to the artery that supplies the inner ear

8. Supplies the facial nucleus and the spinal trigeminal nucleus and tract

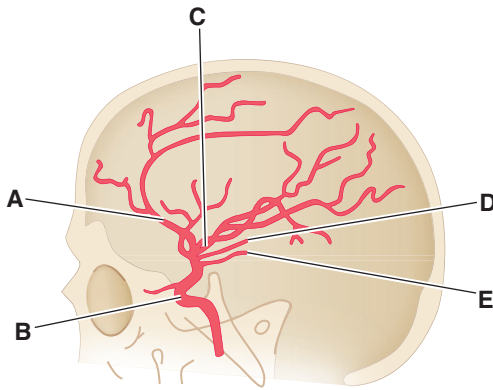
9. Is the terminal branch of the basilar artery

10. Supplies the deep cerebellar nuclei

11. Supplies the nucleus ambiguus

Questions 12 to 16

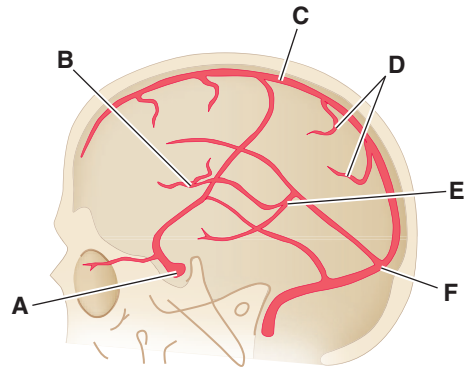
Match the statements in items 12 to 16 with the appropriate lettered artery shown in the figure.



- 12.** An aneurysm of this artery may cause a third nerve palsy
- 13.** Irrigates the posterior limb of the internal capsule
- 14.** Occlusion of this artery results in a fluent receptive aphasia
- 15.** An aneurysm of this artery may result in Horner syndrome
- 16.** Occlusion of this artery results in infarction of the paracentral lobule with Babinski sign

Questions 17 to 23

Match the statements in items 17 to 23 with the appropriate lettered artery shown in the figure.



- 17.** Thrombosis may result in an abducent palsy
- 18.** Drains the deep cerebral veins
- 19.** Marks the site of the interventricular foramen (of Monro)
- 20.** Receives the arachnoid granulations
- 21.** Receives blood from the ophthalmic veins
- 22.** Laceration results in subdural hemorrhage
- 23.** Receives blood from the straight, sagittal, superior, and transverse sinuses

Answers and Explanations

1–A. The anterior cerebral artery perfuses the paracentral lobule, which represents the motor and sensory areas of the leg and foot areas.

2–E. Laceration of the middle meningeal artery gives rise to an epidural hematoma. Classic signs of an epidural hematoma are skull trauma, usually with fracture, and sequential progression from unconsciousness to lucidity to progressive coma to death owing to transtentorial herniation with ipsilateral third palsy.

3–A. The anterior cerebral artery supplies part of the caudate nucleus and putamen and anterior limb of the internal capsule via the medial striate artery (of Heubner) (see Figure 3.2).

4–B. The labyrinthine artery supplies the cochlea and the vestibular apparatus. In 15% of the population, it arises from the basilar artery; in the remaining 85% of the population, it arises from the anterior inferior cerebellar artery.

5–E. The straight sinus drains the superior surface of the cerebellum. It is formed by the great cerebral vein (of Galen) and the inferior sagittal sinus.

6–E. The posterior communicating artery can give rise to a berry aneurysm, which compresses the third cranial nerve and results in incomplete third nerve palsy (see Figure 3.14). Heubner's artery is a branch of the anterior cerebral artery. A communicating artery may harbor berry aneurysms that impinge on the optic chiasm causing a bitemporal lower quadrantanopia. Charcot-Bouchard microaneurysms are found in the territory of the lateral striate arteries and are the commonest cause of nontraumatic intraparenchymal hemorrhage. Rupture occurs most frequently in the basal nuclei. The anterior choroidal artery is a branch of the internal carotid artery and irrigates the globus pallidus and posterior limb of the internal capsule.

7–A. The anterior inferior cerebellar artery usually gives rise to the labyrinthine artery, which supplies the structures of the inner ear (i.e., the cochlea and vestibular apparatus).

8–A. The facial motor nucleus and the spinal trigeminal nucleus and tract are supplied by the anterior inferior cerebellar artery.

9–C. The posterior cerebral artery is the terminal branch of the basilar artery.

10–E. The superior cerebellar artery supplies the superior surface of the cerebellum and the cerebellar nuclei (dentate nucleus).

11–D. The posterior inferior cerebellar artery supplies the posterolateral medullary field, including nucleus ambiguus.

12–E. An aneurysm of the posterior communicating artery may cause a third nerve palsy.

13–D. The anterior choroidal artery irrigates the posterior limb of the internal capsule.

14–C. Occlusion of the proximal stem of the left middle cerebral artery results in Wernicke aphasia—a fluent receptive aphasia.

15–B. An aneurysm of the internal carotid artery within the cavernous sinus can interrupt postganglionic sympathetic fibers, resulting in Horner syndrome.

16–A. The anterior cerebral artery perfuses the medial aspect of the hemisphere from the frontal pole to the parieto-occipital sulcus, including the paracentral lobule. The paracentral lobule gives rise to corticospinal fibers to the contralateral foot and leg. Destruction of these fibers results in the Babinski sign.

17–A. Cavernous sinus thrombosis may result in cranial nerve palsies, including CN III, IV, VI, V₁, and V₂.

- 18–E.** The great cerebral vein (of Galen) drains the deep cerebral veins that drain the thalamus and basal nuclei. The great cerebral vein empties into the straight sinus.
- 19–B.** The venous angle marks the site of the interventricular foramen (of Monro); it is the point where the septal and thalamostriate veins meet.
- 20–C.** The superior sagittal sinus receives cerebrospinal fluid (CSF) via the arachnoid granulations.
- 21–A.** The inferior and superior ophthalmic veins drain into the cavernous sinus.
- 22–D.** Laceration of the superior cerebral veins (bridging veins) results in subdural hemorrhage (hematoma).
- 23–F.** The confluence of the sinuses (torcular herophili) receives blood from the straight, sagittal, superior, and transverse sinuses.

Development of the Nervous System

Objectives

- Describe the development of the neural tube, including the stages of development and the adult derivatives of each vesicle.
- Trace the lineage of the cells and layers of the neural tube wall.
- Identify the derivatives of the neural crest.
- Describe the development of the spinal cord and include a description of the alar and basal plates.
- Describe the development of the brainstem and cerebellum as well as the general arrangement of motor versus sensory components and somatic versus visceral components.
- Describe the development of the diencephalon.
- Describe the development of the telencephalon and list the major adult derivatives.
- List and characterize major congenital malformations of the central nervous system.

I. OVERVIEW

A. Central nervous system (CNS)

- begins to form in the third week of embryonic development as the **neural plate**. The neural plate becomes the **neural tube**, which gives rise to the brain and spinal cord.

B. Peripheral nervous system (PNS)

- consists of spinal, cranial, and visceral nerves and spinal, cranial, and autonomic ganglia.
- derived from three sources:
 1. **Neural crest cells**
 - give rise to peripheral ganglia, Schwann cells, and afferent nerve fibers.
 2. **Neural tube**
 - gives rise to all preganglionic autonomic fibers and all fibers that innervate skeletal muscles.
 3. **Mesoderm**
 - gives rise to the dura mater and to connective tissue investments of peripheral nerve fibers (endoneurium, perineurium, and epineurium).

II. DEVELOPMENT OF THE NEURAL TUBE (FIGURES 4.1 AND 4.2)

- begins in the third week and is complete in the fourth week.

A. Neural plate

- a thickened pear-shaped region of embryonic ectoderm between the primitive node and the oropharyngeal membrane.

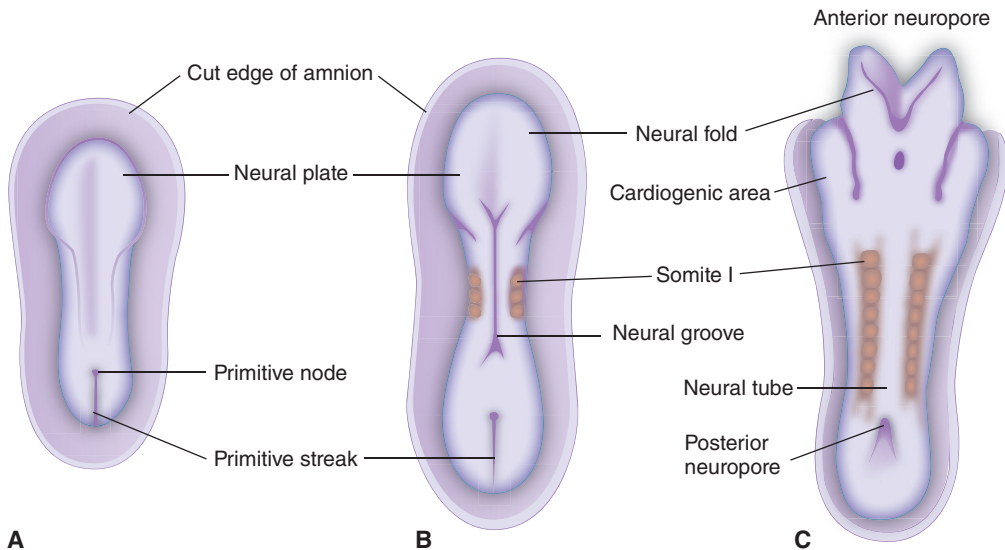


FIGURE 4.1. Diagrams illustrating the dorsal aspect of the human embryo. **(A)** Late presomite and early neural plate stage. **(B)** Early somite stage and neural groove stage. **(C)** Eight-somite stage and early neural tube stage. The anterior and posterior neuropores provide transitory communication between the neural canal and the amniotic cavity. (Modified from Carpenter MB, Sutin J. *Human Neuroanatomy*. 8th ed. Baltimore, MD: Williams & Wilkins; 1983:63.)

B. Neural groove

- forms as the neural plate begins to grow and fold inward.
- flanked by neural folds that are parallel to each other.
- deepens as the neural folds continue to expand and close over it.

C. Neural folds

- fuse in the midline beginning near the middle and proceed cranially and caudally to form the neural tube.
- the edges are the sites of neural crest cell differentiation.

D. Neural tube

- forms as the neural folds fuse in the midline and separate from the surface ectoderm.
- lies between the surface ectoderm and the notochord.
- gives rise to the CNS:
 1. The **cranial part** becomes the brain.
 2. The **caudal part** becomes the spinal cord.
 3. The **cavity** gives rise to the central canal of the spinal cord and ventricles of the brain.
 4. The **two openings in the neural tube** connect the central canal with the amniotic cavity:
 - **Anterior neuropore**
 - a. closes in the fourth week (day 25) and becomes the **lamina terminalis**.
 - **Posterior neuropore**
 - a. closes in the fourth week (day 27).

III. NEURAL CREST (SEE FIGURE 4.2)

- forms near edges of neural folds
- a group of multipotent migratory cells

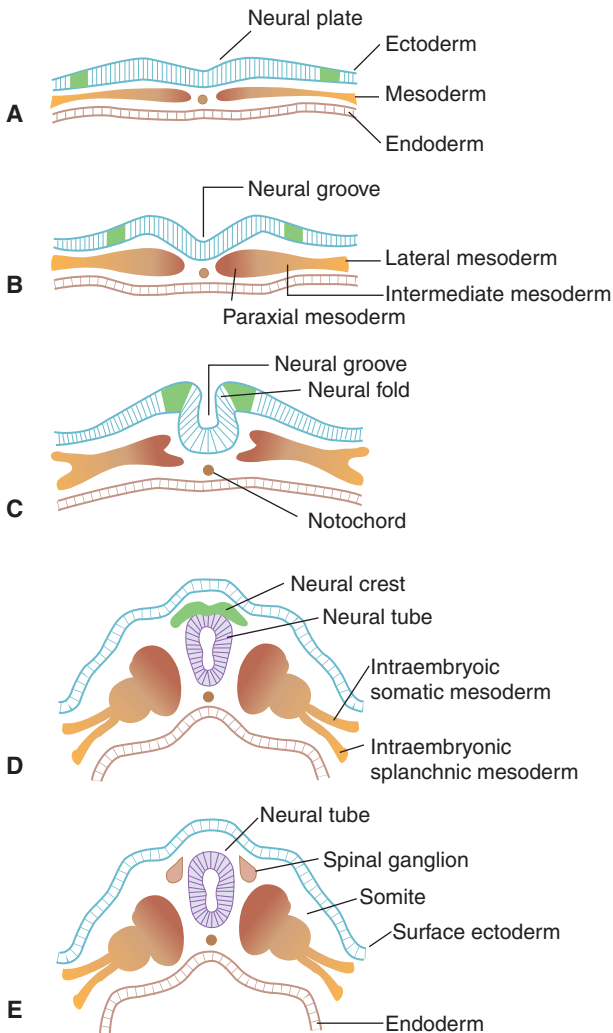


FIGURE 4.2. Schematic diagrams of transverse sections of embryos at various stages. **(A)** Neural plate stage. **(B)** Early neural groove stage. **(C)** Late neural groove stage. **(D)** Early neural tube and neural crest stage. **(E)** Neural tube and spinal ganglion stage. (Modified from Truex RC, Carpenter MB. *Human Neuroanatomy*. Baltimore, MD: Williams & Wilkins; 1969:91.)

- A. Pseudounipolar cells of the spinal and cranial nerve ganglia
- B. Schwann cells
- C. Multipolar cells of the autonomic ganglia
- D. Leptomeninges (pia–arachnoid cells)
- E. Chromaffin cells of the suprarenal medulla
- F. Pigment cells (melanocytes)
- G. Odontoblasts (dentin-forming cells), dental papilla, and the dental follicle
- H. Aorticopulmonary septum of the heart
- I. Parafollicular cells (calcitonin-producing C-cells)
- J. Skeletal and connective tissue components of the pharyngeal arches

IV. PLACODES

- localized thickenings of the cephalic surface ectoderm.
- give rise to cells that migrate into the underlying mesoderm and develop into the sensory receptive organs of the olfactory nerve (CN I) and the vestibulocochlear nerve (CN VIII).

A. Olfactory placodes

- differentiate into neurosensory cells that give rise to the **olfactory nerve (CN I)**.
- induce formation of the **olfactory bulbs**.

B. Otic placodes

- give rise to the following statoacoustic organs:
 1. **Organ of Corti and spiral ganglion**
 2. **Cristae ampullares, maculae of the utricle and saccule, and vestibular ganglion**
 3. **Vestibulocochlear nerve (CN VIII)**

V. STAGES OF NEURAL TUBE DEVELOPMENT

A. Vesicle development

1. **Three primary brain vesicles** and associated flexures (Figure 4.3)
 - develop during the fourth week.
 - give rise to dilations of the primary brain vesicles and two curvatures.
 - a. **Prosencephalon (forebrain)**
 - associated with the appearance of the **optic vesicles**.
 - (1) **Telencephalon**
 - (2) **Diencephalon**
 - b. **Mesencephalon (midbrain)**
 - remains as the mesencephalon.

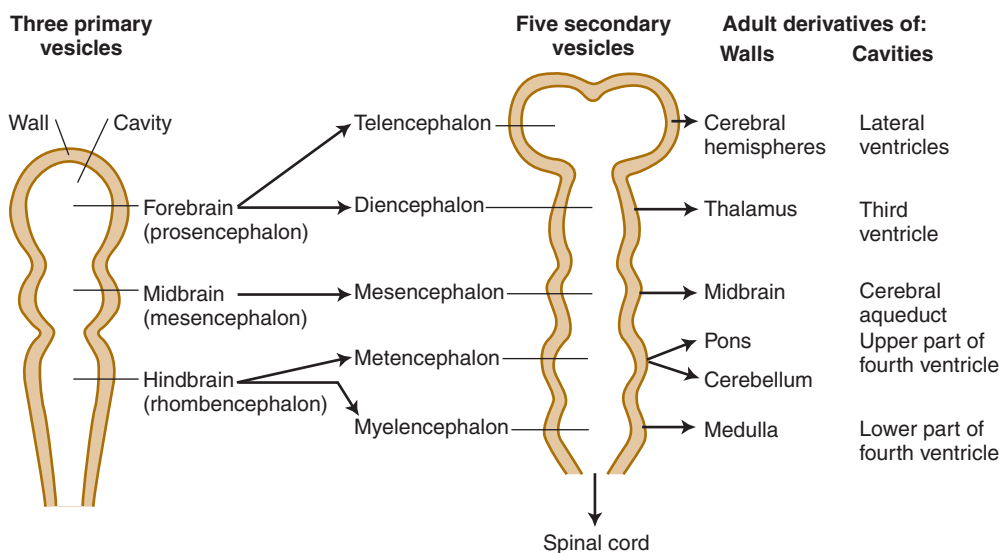


FIGURE 4.3. Diagrammatic sketches of the brain vesicles indicating the adult derivatives of their walls and cavities. (Modified from Moore KL. *The Developing Human: Clinically Oriented Embryology*. 4th ed. Philadelphia, PA: WB Saunders; 1988:380.)

- c. **Rhombencephalon (hindbrain)**
 - gives rise to:
 - (1) **Metencephalon**
 - forms the pons and cerebellum.
 - (2) **Myelencephalon (medulla oblongata)**
 - d. **Cephalic flexure (midbrain flexure)**
 - located between the prosencephalon and the rhombencephalon.
 - e. **Cervical flexure**
 - located between the rhombencephalon and the future spinal cord.
2. **Five secondary brain vesicles** (with four ventricles) (see Figure 4.3)
- become visible in the sixth week; the brain vesicles are visible as the primordia of the five major brain divisions:
 - a. **Telencephalon**
 - lateral outpocketings that form the **cerebral hemispheres**.
 - inferior outpocketings that form the **olfactory bulbs**.
 - visible lateral ventricles.
 - b. **Diencephalon**
 - third ventricle, optic chiasm and nerves, infundibulum, and mamillary eminences become visible.
 - c. **Mesencephalon**
 - contains a large cavity that will become the **cerebral aqueduct**.
 - d. **Metencephalon**
 - separated from the mesencephalon by the rhombencephalic isthmus.
 - separated from the myelencephalon by the pontine flexure.
 - contains **rhombic lips** on the dorsal surface that give rise to the cerebellum.
 - becomes the **pons** and the **cerebellum**.
 - contains the rostral half of the fourth ventricle.
 - e. **Myelencephalon (medulla oblongata)**
 - lies between the pontine and cervical flexures.
 - becomes the medulla.
 - contains the **caudal half of the fourth ventricle**.

B. Histogenesis

1. Cells of the neural tube wall

- neuroepithelial cells that give rise to the following:
 - a. **Neuroblasts**
 - form all neurons found in the CNS.
 - b. **Glioblasts**
 - form the supporting cells of the CNS.
 - (1) **Macroglia**
 - **Astroglia (astrocytes)**
 - (a) contain glial fibrillary acidic protein (**GFAP**), a marker for astrocytes.
 - (b) surround blood capillaries with perivascular feet.
 - **Radial glial cells**
 - (a) of astrocytic lineage and **GFAP**-positive.
 - (b) provide guidance for migrating neuroblasts.
 - **Oligodendroglia (oligodendrocytes)**
 - (a) produce the myelin of the CNS.
 - (2) **Ependymal cells**
 - ciliated.
 - (a) **Ependymocytes**
 - line the ventricles and the central canal.
 - (b) **Tanocytes**
 - located in the wall of the third ventricle.
 - transport substances from the cerebrospinal fluid (**CSF**) to the hypothyseal portal system.

(c) **Choroid plexus cells**

- produce CSF.
- form the blood–CSF barrier with the arachnoid membrane.

c. **Microglia**

- macrophages of the CNS.
- arise from monocytes and not from glioblasts.
- enter the developing nervous system in the third week with the developing blood vessels.

2. **Layers of the neural tube wall**• **Neuroepithelial (ventricular) layer**

- a. the innermost layer.
- b. a monocellular layer of ependymal cells that lines the central canal and future brain ventricles.

• **Mantle (intermediate) layer**

- a. the middle layer.
- b. consists of neurons and glial cells.
- c. contains the developing **alar** and **basal plates**.

• **Marginal layer**

- a. the outermost layer.
- b. contains nerve fibers of neuroblasts of the mantle layer and glial cells.
- c. produces the **white matter of the spinal cord** through the myelination of axons growing into this layer.

VI. **SPINAL CORD (MEDULLA SPINALIS) (FIGURE 4.4)**

- develops from the neural tube caudal to the fourth pair of somites.

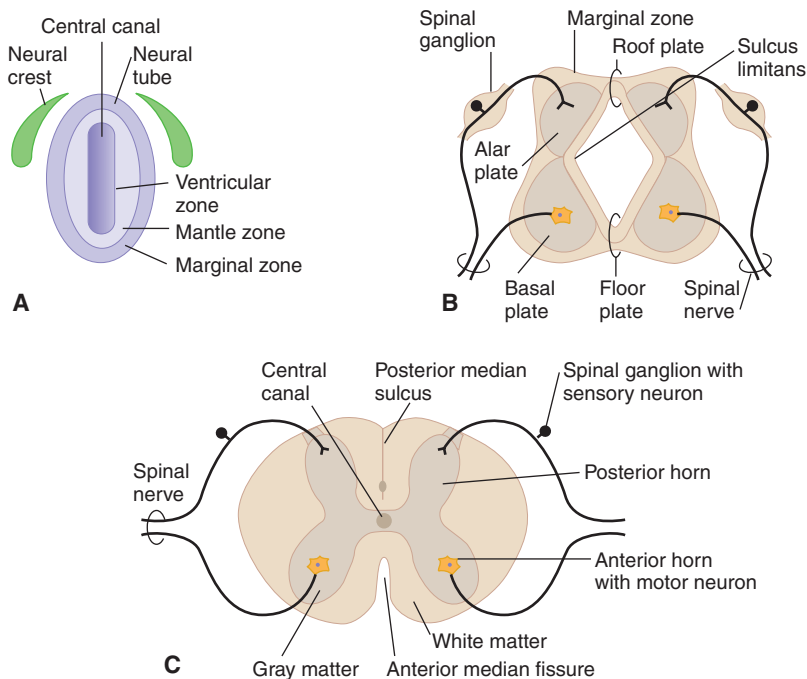


FIGURE 4.4. Schematic illustration of three successive stages in the development of the spinal cord. The neural crest gives rise to the spinal ganglion and the alar and basal plates give rise to the posterior and anterior horns, respectively. (Modified from Fix JD, Dudek RW. *BRS Embryology*. 3rd ed. Baltimore, MD: Williams & Wilkins; 2005:67.)

A. Alar and basal plates, sulcus limitans, and roof and floor plates

1. Alar plate

- a posterolateral thickening of the mantle layer of the neural tube.
- gives rise to second-order **sensory neuroblasts** of the posterior horn (general somatic afferent [GSA] and general visceral afferent [GVA] cell regions).
- receives axons from the spinal ganglion to become the posterior roots.
- becomes the **posterior horn** of the spinal cord.

2. Basal plate

- an antero-lateral thickening of the mantle layer of the neural tube.
- gives rise to the **motor neuroblasts** of the anterior and lateral horns (general somatic efferent [GSE] and general visceral efferent [GVE] cell regions). Axons from motor neuroblasts exit the spinal cord and form the anterior roots.
- becomes the **anterior horn** of the spinal cord.

3. Sulcus limitans

- a longitudinal groove in the lateral wall of the neural tube that appears during the fourth week.
- separates the alar (sensory) and the basal (motor) plates.
- disappears in the adult spinal cord but is retained in the rhomboid fossa of the brainstem.
- extends from the spinal cord to the rostral midbrain.

4. Roof plate

- the nonneural roof of the central canal.

5. Floor plate

- the nonneural floor of the central canal.
- contains the anterior white commissure.

B. Myelination

- commences in the fourth fetal month in the spinal cord motor roots.
 1. **Oligodendrocytes accomplish myelination of the CNS.**
 2. **Schwann cells accomplish myelination of the PNS.**
 3. **Myelination of the corticospinal tracts** is not complete until the **end of the second post-natal year** (i.e., when the corticospinal tracts become myelinated and functional).
 4. **Myelination of the association neocortex** extends into the **third decade**.

C. Positional changes of the spinal cord

- Disparate growth results in formation of the **cauda equina**, consisting of posterior and anterior roots (L3–Co) that descend inferior to the conus medullaris, and in formation of the **filum terminale**, which anchors the spinal cord to the dura mater and coccyx.
 1. At **8 weeks**, the spinal cord extends the entire length of the vertebral canal.
 2. At **birth**, the **conus medullaris** extends to the level of the third lumbar vertebra (VL3).
 3. In **adults**, the conus medullaris terminates at the VL1–VL2 level.

VII. MEDULLA OBLONGATA (MYELENCEPHALON) (FIGURE 4.5)

- develops from the caudal rhombencephalon.
- contains the medullary pyramids (corticospinal tracts) in its base.

A. Alar (sensory) and basal (motor) plates

1. Closed (caudal) medulla

- **Alar plate sensory neuroblasts give rise to the following:**
 - a. **Posterior column nuclei** made up of the gracile and cuneate nuclei
 - b. **Inferior olivary nuclei** — cerebellar relay nuclei
 - c. **Solitary nucleus** forms the GVA (taste) and special visceral afferent (SVA) column
 - d. **Spinal trigeminal nucleus** forms the GSA column

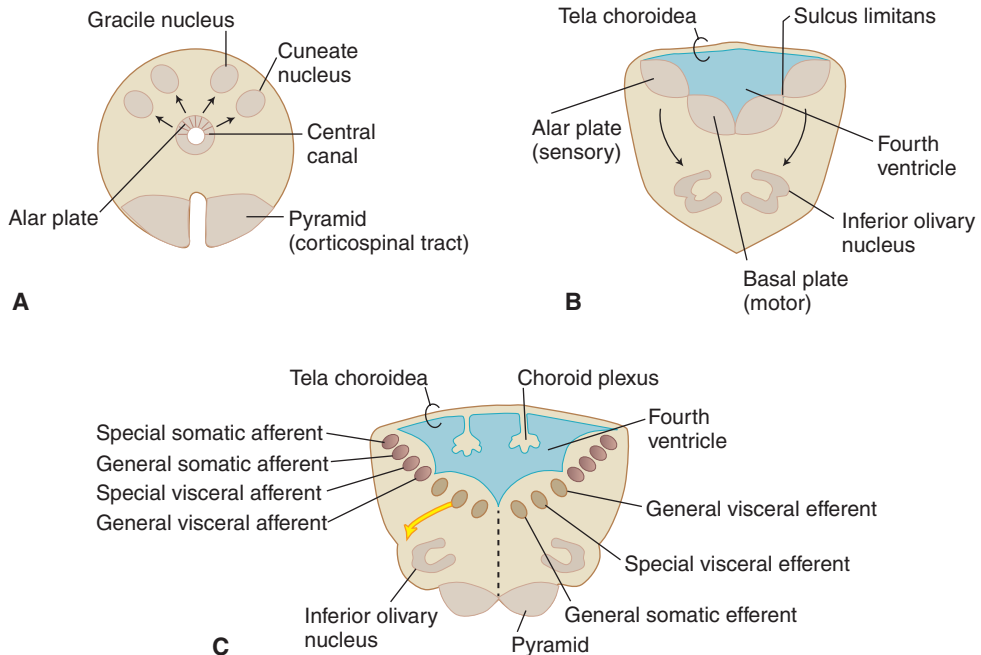


FIGURE 4.5. Schematic illustrations of the development of the medulla. **(A)** Transverse section of the caudal medulla showing the development of the gracile and cuneate nuclei from the alar plates. **(B)** Schematic sketch through the rostral (open) medulla showing the relationships of the alar and basal plates; the inferior olivary nucleus is derived from the alar plate. **(C)** A later stage of B shows the four sensory modalities of the alar plate and the three motor modalities of the basal plate; the yellow arrow indicates the lateral migration of the SVE column (CN IX and CN X); pyramids consist of motor fibers, the corticospinal tracts. (Adapted with permission from Fix JD, Dudek RW. *BRS Embryology*. 3rd ed. Baltimore, MD: Williams & Wilkins; 2005:69.)

- e. **Cochlear and vestibular nuclei**
 - form the special somatic afferent (SSA) column.
 - lie in the medullopontine junction.
- **Basal plate motor neuroblasts give rise to the following:**
 - a. **Hypoglossal nucleus** forms the **GSE column**
 - b. **Nucleus ambiguus** forms the special visceral efferent (SVE) column (CN IX and CN X)
 - c. **Dorsal motor nucleus of the vagus and the inferior salivatory nucleus of the glossopharyngeal nerve** form the GVE column
- 2. **Open (rostral) medulla** (Figure 4.6; see Figure 4.5)
 - extends from the **obex** to the **striae medullares** of the rhomboid fossa (see Figure 1.6)
 - formation of the pontine flexure causes the lateral walls of the rostral medulla to open like a book and form the rhomboid fossa (the floor of the fourth ventricle).
 - a. **Alar plate**
 - lies lateral to the sulcus limitans.
 - its sensory neuroblasts give rise to the following:
 - (1) **Solitary nucleus**
 - forms the GVA and SVA columns.
 - (2) **Cochlear and vestibular nuclei**
 - form the special SSA column.
 - (3) **Spinal trigeminal nucleus**
 - forms the GSA column.
 - b. **Basal plate**
 - lies medial to the sulcus limitans.

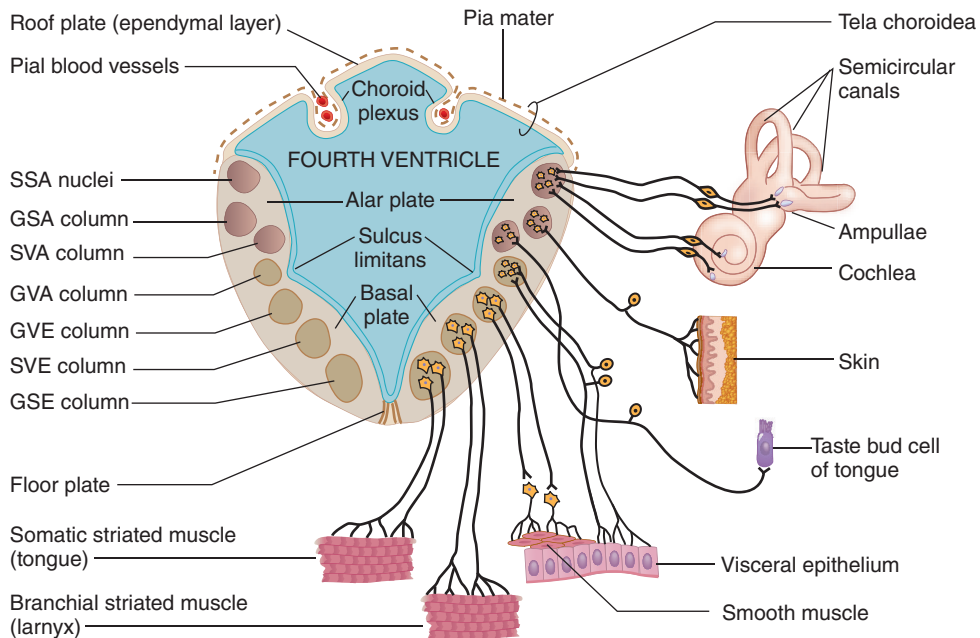


FIGURE 4.6. Schematic diagram of the brainstem illustrating the cell columns derived from the alar and basal plates. The seven cranial nerve modalities are shown. *GSA* = general somatic afferent, *GVA* = general visceral afferent, *GVE* = general visceral efferent; *SSA* = special somatic afferent, *SSE* = special somatic efferent; *SVA* = special visceral afferent, *SVE* = special visceral efferent. (Adapted with permission from Fix JD, Dudek RW. *BRS Embryology*. 3rd ed. Baltimore, MD: Williams & Wilkins; 2005:69.)

- its motor neuroblasts give rise to the following:
 - (1) **Hypoglossal nucleus**
 - forms the GSE column.
 - (2) **Nucleus ambiguus**
 - forms the SVE column.
 - (3) **Dorsal motor nucleus of the vagus and the inferior salivatory nucleus of the glossopharyngeal nerve**
 - form the GVE column.

B. Roof plate

- forms the caudal roof of the fourth ventricle.
- the **tela choroidea**, a monolayer of ependymal cells covered with pia mater.
- invaginated by pial vessels to form the **choroid plexus of the fourth ventricle**.

VIII. METENCEPHALON (FIGURE 4.7; SEE FIGURE 4.3)

- develops from the **rostral division of the rhombencephalon**.
- gives rise to the **pons** and the **cerebellum**.

A. Pons

1. **Alar plate sensory neuroblasts give rise to the following:**
 - **Solitary nucleus**—forms the GVA and the SVA (taste) columns of CN VII
 - **Cochlear and vestibular nuclei**—form the SSA column of CN VIII

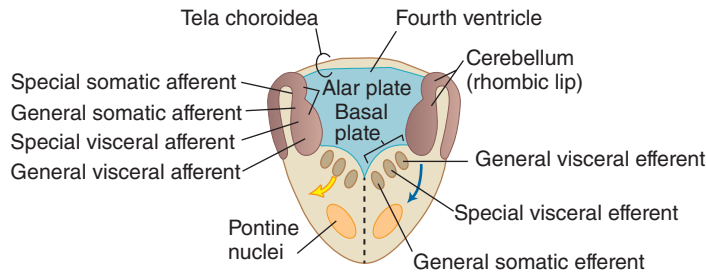


FIGURE 4.7. Schematic illustration (transverse section) of the development of the pons and cerebellum. The alar plate (rhombic lip) gives rise to the cerebellum, the four sensory cell columns, and the pontine nuclei. The basal plate gives rise to the three motor columns. The base of the pons contains the descending corticospinal tracts, which originate from the motor and sensory strips of the cerebral cortex. The *yellow arrow* indicates the lateral migration of the SVE column (V and CN VII). (Modified from Fix JD, Dudek RW. *BRS Embryology*. 3rd ed. Baltimore, MD: Williams & Wilkins; 2005:71.)

- **Spinal and principal trigeminal nuclei**—form the GSA column of CN V
- **Pontine nuclei**—consist of cerebellar relay nuclei (pontine gray)
- 2. **Basal plate motor neuroblasts give rise to the following:**
 - **Abducent nucleus** —forms the GSE column
 - **Facial and trigeminal motor nuclei of CN VII and CN V**—form the SVE column
 - **Superior salivatory nucleus**—forms the GVE column of CN VII
- 3. **Base of the pons**
 - contains pontine nuclei from the alar plate.
 - contains corticobulbar, corticospinal, and corticopontine fibers..
 - contains pontocerebellar fibers that are axons of neurons found in the pontine nuclei.

B. Cerebellum

- formed by the **rhombic lips**, which are the thickened alar plates of the mantle layer. The **rostral** part of the cerebellum is derived from the **caudal mesencephalon**.
- the **cerebellar anlage (primordium)**.
 1. **Vermis**
 2. **Cerebellar hemispheres**
 3. **Cerebellar cortex (molecular layer, Purkinje cell layer, and granular [internal] cell layer) and four pairs of cerebellar nuclei** formed by cell migration from the ventricular zone into the marginal layer
 4. **External granular layer (EGL)**
 - a germinal layer on the surface of the cerebellum, present from week 8 of development to the end of the second postnatal year.
 - gives rise only to granule cells, not to basket (inner stellate) or stellate (outer stellate) neurons.
 - persistent cell nests can give rise to a neoplasm, **medulloblastoma** (see Chapter 19 VI E 2).
 - sensitive to antiviral agents that block DNA synthesis.
 5. **Folia and fissures**

IX. MESENCEPHALON (MIDBRAIN) (FIGURE 4.8; SEE FIGURE 4.3)

- develops from the walls of the mesencephalic vesicle.
- contains the **cerebral aqueduct** that develops from the mesencephalic cavity.

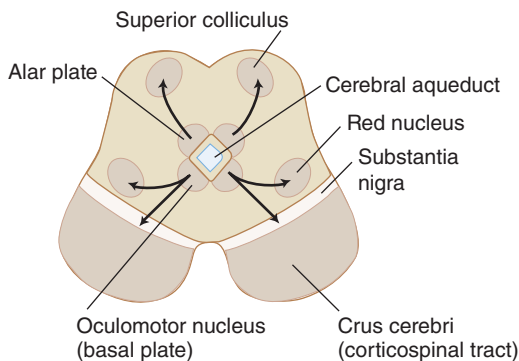


FIGURE 4.8. Schematic illustration (transverse section) of the development of the midbrain. The alar plate gives rise to the layers of the superior colliculus and the nuclei of the inferior colliculus. The basal plate gives rise to the oculomotor and trochlear nuclei, the substantia nigra, and the red nucleus. The cerebral peduncles contain the descending corticospinal tracts. (Modified from Fix JD, Dudek RW. *BRS Embryology*. 3rd ed. Baltimore, MD: Williams & Wilkins; 2005:71.)

A. Alar plate sensory neuroblasts

- form the cell layers of the superior colliculi and the nuclei of the inferior colliculi.

B. Basal plate motor neuroblasts

- give rise to the:
 1. **Trochlear and oculomotor nuclei of CN IV and III** that form the GSE column
 2. **Accessory oculomotor nucleus of CN III** that forms the most rostral cell group of the GVE column
 3. **Red nucleus and substantia nigra**

C. Basis pedunculi (crus cerebri)

- contains corticobulbar, corticospinal, and corticopontine fibers from the cerebral cortex.

X. DEVELOPMENT OF THE Diencephalon, OPTIC STRUCTURES, AND HYPOPHYSIS

A. Diencephalon (see Figure 4.3)

- develops from the **caudal part of the prosencephalon**, within the walls of the primitive third ventricle.
 1. **Epithalamus**
 - develops from the embryonic roof plate and posterior aspects of the alar plates.
 - gives rise to the **pineal body** (epiphysis) and the habenular nuclei.
 - gives rise to the habenular and posterior commissures.
 - gives rise to the **tela choroidea** and **choroid plexus of the third ventricle** from the roof plate and the pia mater.
 2. **Thalamus**
 - an alar plate derivative that gives rise to thalamic nuclei.
 - includes the **metathalamus** that includes the lateral geniculate body (relays visual impulses) and the medial geniculate body (relays auditory impulses).
 3. **Hypothalamus**
 - develops inferior to the hypothalamic sulcus from the alar plate and floor plates.
 - gives rise to hypothalamic nuclei, including the **mamillary bodies**, and to the **neurohypophysis**.
 4. **Subthalamus**
 - an alar plate derivative located inferior to the thalamus and lateral to the hypothalamus.
 - includes the **subthalamic nucleus**, **zona incerta**, and **lenticular and thalamic fasciculi**.
 - contains subthalamic neuroblasts that migrate into the telencephalon and form the **globus pallidus** (pallidum).

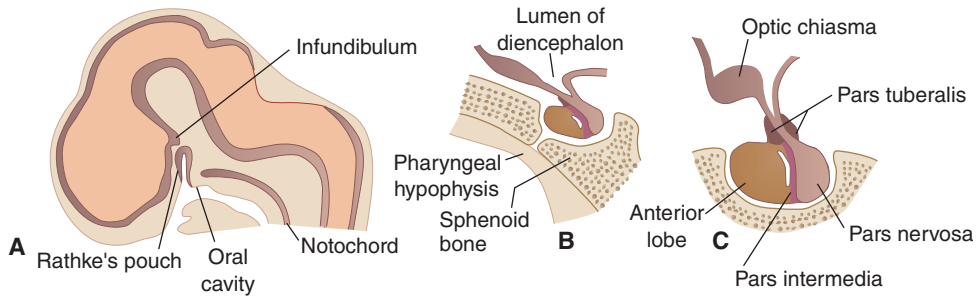


FIGURE 4.9. Schematic drawings illustrating the development of the hypophysis (pituitary gland). **(A)** Midsagittal section through the 6-week old embryo showing Rathke's pouch as a dorsal outpocketing of the oral cavity and the infundibulum as a thickening in the floor of the hypothalamus. **(B and C)** Development at 11 weeks and 16 weeks, respectively. The anterior lobe, the pars tuberalis, and the pars intermedia are derived from Rathke's pouch. (Adapted with permission from Sadler TW. *Langman's Medical Embryology*. 10th ed. Baltimore, MD: Lippincott Williams & Wilkins; 2006:301.)

B. Optic vesicles, cups, and stalks (see Figure 4.3)

- derivatives of diencephalic vesicle walls.
- give rise to the retina, optic nerve, optic chiasm, and optic tract.

C. Hypophysis (pituitary gland) (Figure 4.9)

1. Anterior lobe (adenohypophysis)

- develops from the **Rathke pouch**, an ectodermal diverticulum of the primitive oral cavity (**stomodeum**). Remnants of the Rathke pouch can give rise to a congenital cystic tumor, a **craniopharyngioma** (Figure 4.10; see Chapter 13 VII A:).
- includes the pars tuberalis, pars intermedia, and pars distalis.

2. Posterior lobe (neurohypophysis)

- develops from a ventral evagination of the hypothalamus.
- includes the median eminence, infundibular stem, and pars nervosa.

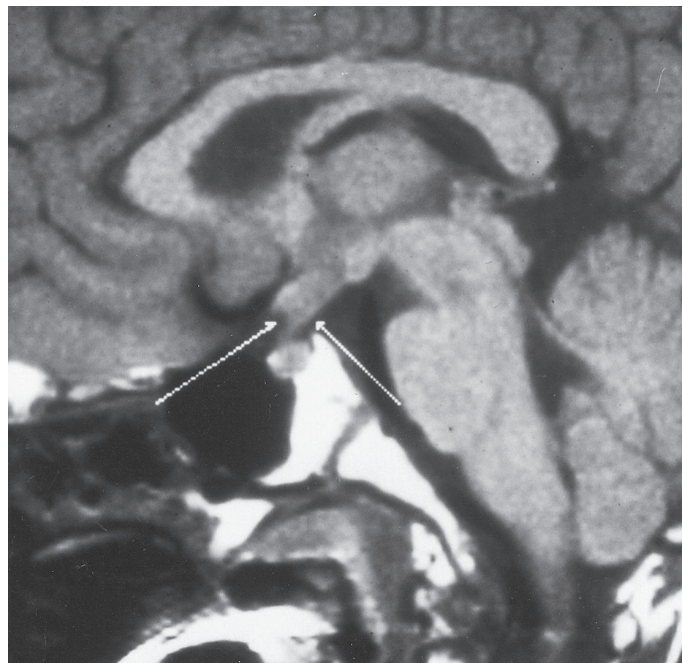


FIGURE 4.10. Midsagittal section of T₁-weighted magnetic resonance image through the brainstem and diencephalon. A craniopharyngioma (arrow) lies suprasellar in the midline, compressing the optic chiasm and hypothalamus. This tumor, the commonest supratentorial tumor occurring in childhood, is the commonest cause of hypopituitarism in children. (Modified from Fix JD. *High-Yield Neuroanatomy*. 3rd ed. Philadelphia, PA: Lippincott Williams & Wilkins; 2005:45.)

XI. DEVELOPMENT OF THE TELECEPHALON

A. Cerebral hemispheres (Figure 4.11; see Figure 4.3)

- develop as **bilateral evaginations** of the lateral walls of the **prosencephalic vesicle**.
- contain the **cerebral cortex**, **cerebral white matter**, **basal nuclei**, and **lateral ventricles**.
- are interconnected by three commissures: the **corpus callosum**, **anterior commissure**, and **hippocampal (fornix) commissure**.
- continuous hemispheric growth gives rise to frontal, parietal, occipital, and temporal lobes, which overlie the insula and posterior brainstem.

B. Cerebral cortex (pallium)

- formed by prosencephalic neuroblasts that migrate from the mantle layer into the marginal layer and give rise to cortical cell layers
- classified phylogenetically as
 1. **Neocortex** (isocortex), a six-layered cortex
 - separated from the paleocortex by the **rhinal sulcus**, a continuation of the collateral sulcus.
 - represents 90% of the cortical mantle.
 2. **Allocortex**, a three-layered cortex, including the following:
 - **Paleocortex** (olfactory cortex)
 - **Archicortex** (hippocampal cortex)

C. Corpus striatum (see Figure 4.11)

- appears in the fifth week as a bulging striatal eminence on the floor of the lateral telencephalic vesicle.
- gives rise to the caudate nucleus, putamen, amygdaloid nucleus, and claustrum. The neurons of the **globus pallidus** originate in the subthalamus; they migrate into the telencephalic white matter and become the medial segments of the lentiform nucleus.
- divided into the caudate nucleus and the lentiform nucleus by corticofugal and corticopetal fibers; these fibers make up the **internal capsule**.

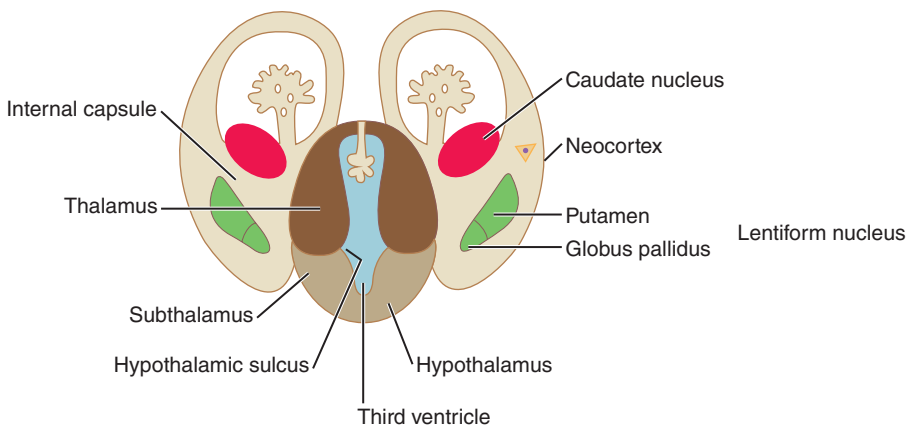


FIGURE 4.11. Schematic illustration (transverse section) of the development of the forebrain. The cerebral cortex and basal nuclei are shown. The internal capsule divides the corpus striatum into the caudate nucleus and the lentiform nucleus. The alar plate of the diencephalon gives rise to the thalamus and the hypothalamus. Cells from the subthalamus give rise to the globus pallidus. (Adapted with permission from Fix JD, Dudek RW. *BRS Embryology*. 2nd ed. Baltimore, MD: Williams & Wilkins; 1998:90.)

D. Commissures

- fiber bundles that interconnect the two cerebral hemispheres.
- cross the midline via the **lamina terminalis**.
 1. **Anterior commissure**
 - the first commissure to appear.
 - interconnects the olfactory structures and the middle and inferior temporal gyri.
 2. **Hippocampal commissure (fornical commissure)**
 - the second commissure to appear.
 - interconnects the two hippocampi.
 3. **Corpus callosum**
 - appears between weeks 12 and 22 of development.
 - the third commissure to appear.
 - the largest commissure of the brain and interconnects the corresponding neocortical areas of the two cerebral hemispheres.
 - does *not* project commissural fibers from the visual cortex (area 17) or the hand area of the motor or sensory strips (areas 1, 2, 3, and 4).

E. Gyri and sulci (fissures)

- In the fourth month, no gyri or sulci are present; the brain is smooth or **lissencephalic**.
- At the eighth month, all major gyri and sulci are present; the brain is convoluted or **gyrencephalic**.

XII. CONGENITAL MALFORMATIONS OF THE CENTRAL NERVOUS SYSTEM

- result from failure of the neural tube to close or separate from the surface ectoderm (e.g., spina bifida).
- result from failure of the vertebral arches to fuse.
- result from failure of midline cleavage of the embryonic forebrain (e.g., holoprosencephaly).

A. Neural tube defects (e.g., spina bifida and anencephaly)

- can be detected prenatally by screening for **high alpha-fetoprotein levels** in the amniotic fluid or in the maternal serum (**low alpha-fetoprotein levels** are found in **Down syndrome**) and subsequently confirmed through ultrasound.
 1. **Spina bifida** (Figure 4.12)
 - usually occurs in the sacrolumbar region.
 - results from failure of the **posterior neuropore** to close.
 - includes the following variations:
 - a. **Spina bifida occulta**
 - a defect in the vertebral arches.
 - the least severe type of spina bifida.
 - occurs in 10% of the population.
 - b. **Spina bifida cystica**
 - the major form of **dysraphism**.
 - most often localized in lumbar and lumbosacral regions.
 - (1) **Spina bifida with meningocele**
 - occurs when the meninges project through a vertebral defect forming a sac filled with CSF.
 - exists with the spinal cord remaining in its normal position.
 - (2) **Spina bifida with meningomyelocele**
 - occurs when the meninges and spinal cord project through a vertebral defect and forms a sac.
 - is the commonest variation of spina bifida cystica (80%–90%).
 - is usually present in Arnold–Chiari malformation (see p. 74, C).

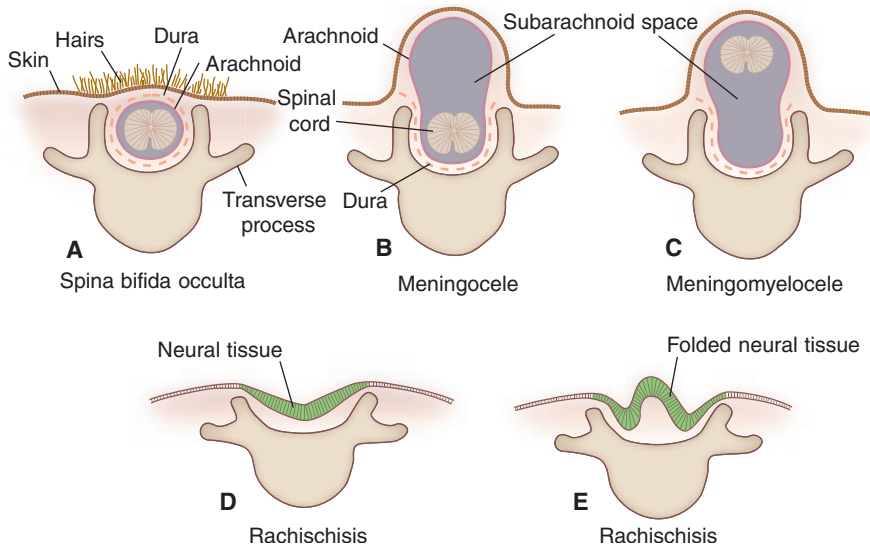


FIGURE 4.12. Schematic drawings illustrating a variety of neural tube defects involving the spinal cord. The term *spina bifida* applies to all of the defects because the bony arch of one or more vertebrae has failed to fuse posterior to the spinal cord. (Modified from Sadler TW. *Langman's Medical Embryology*. 10th ed. Baltimore, MD: Lippincott Williams & Wilkins; 2006:294.)

(3) Spina bifida with myeloschisis

- the most severe type of spina bifida.
- results in an open neural tube that lies on the surface of the back.

2. Anencephaly (meroanencephaly)

- results from failure of the **anterior neuropore** to close.
- occurs when the brain fails to develop; a rudimentary brainstem is usually present, and no cranial vault is formed.
- the commonest serious birth defect in stillborn fetuses.
- occurs once in every 1,000 births.

B. Ossification defects of the occipital bone (Figure 4.13)

- are also called **cranium bifidum**.
- occur once in every 2,000 births.
- **Encephaloceles** occur in the occiput (75%) and in the sinciput (25%).

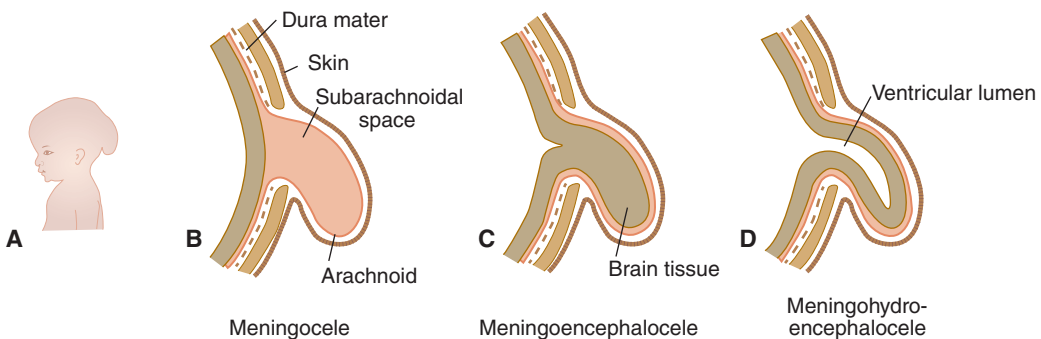


FIGURE 4.13. Schematic drawings illustrating the various types of occipital encephaloceles (cranium bifidum). (Adapted with permission from Sadler TW. *Langman's Medical Embryology*. 10th ed. Baltimore, MD: Lippincott Williams & Wilkins; 2006:308.)

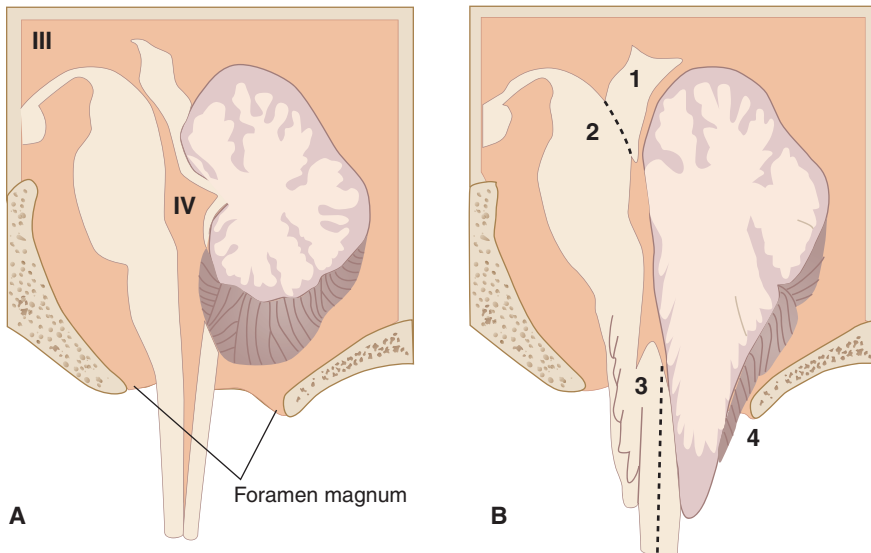


FIGURE 4.14. Arnold–Chiari malformation, midsagittal section. **(A)** Normal cerebellum, fourth ventricle, and brainstem. **(B)** Abnormal cerebellum, fourth ventricle, and brainstem showing the common congenital anomalies: (1) breaking of the tectal plate, (2) aqueductal stenosis, (3) kinking and transforaminal herniation of the medulla into the vertebral canal, and (4) herniation and unrolling of the cerebellar vermis into the vertebral canal. An accompanying meningocele is common. (Modified from Fix JD. *High-Yield Neuroanatomy*. 3rd ed. Philadelphia, PA: Lippincott Williams & Wilkins; 2005:46.)

- include the following variations:
 1. **Cranial meningocele**
 2. **Meningoencephalocele**
 3. **Meningohydroencephalocele**

C. Arnold–Chiari malformation (Figures 4.14 and 4.15)

- a cerebellomedullary malformation where the caudal vermis, cerebellar tonsils, and medulla herniate through the foramen magnum and result in an obstructive hydrocephalus.
- frequently associated with spina bifida (meningocele) and platybasia, with malformation of the occipitovertebral joint.

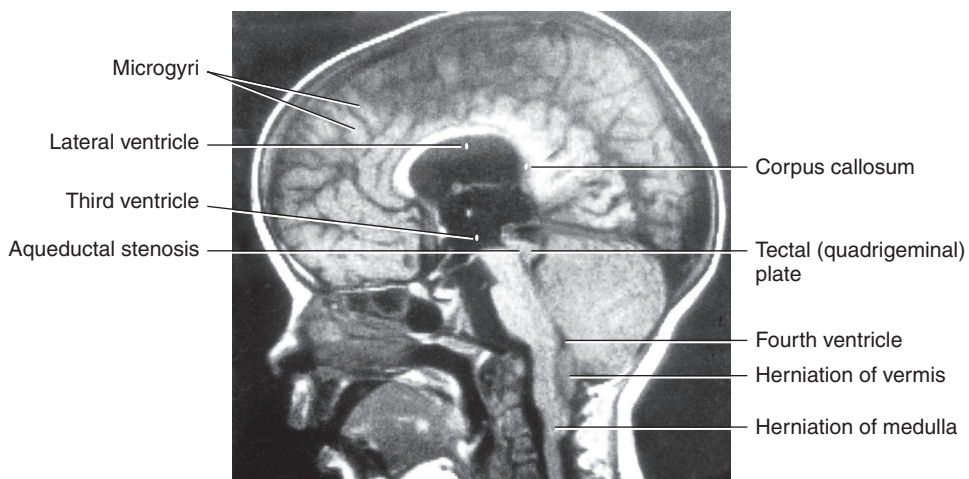


FIGURE 4.15. Arnold–Chiari malformation, midsagittal section, T₂-weighted MRI.

- affected children may have dysphonia, laryngeal stridor, and respiratory arrest (involvement of CN X).
- occurs once in every 1,000 births.

D. Dandy–Walker syndrome (Figure 4.16)

- consists of a huge **cyst of the posterior fossa** associated with atresia of the outlet foramina of the fourth ventricle.
- associated with dilation of the fourth ventricle, **agenesis of the cerebellar vermis**, occipital meningocele, and frequently agenesis of the splenium of the corpus callosum.

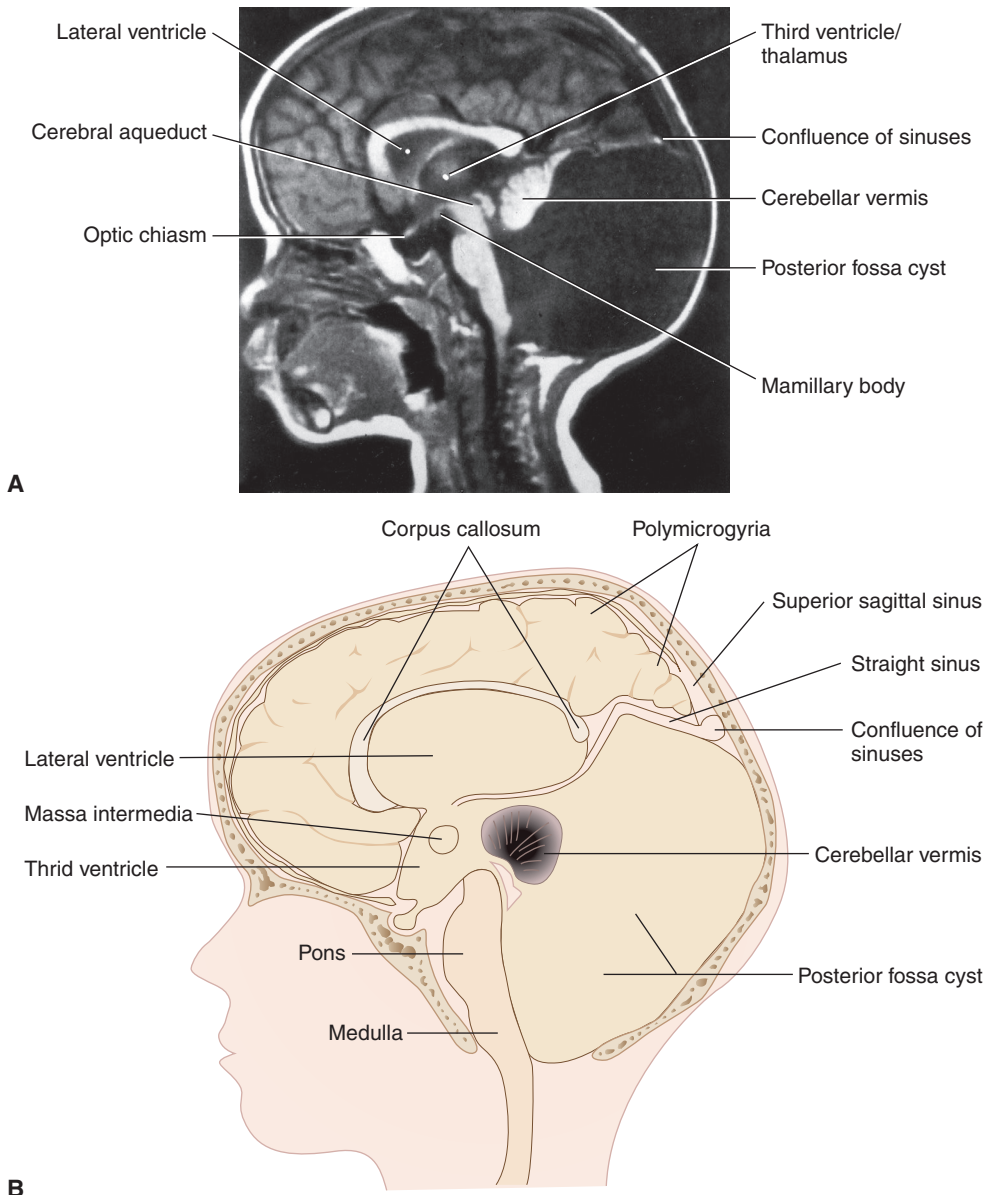


FIGURE 4.16. Dandy–Walker malformation, midsagittal section. **(A)** T₂-weighted MRI. **(B)** Diagram. An enormous dilation of the fourth ventricle results from failure of the median and lateral foramina to open. This condition is associated with occipital meningocele, elevation of the confluence of the sinuses (torcular herophili), agenesis of the cerebellar vermis, and splenium of the corpus callosum. (Modified from Fix JD. *High-Yield Embryology*. 3rd ed. Baltimore, MD: Williams & Wilkins; 2005:46.)

E. Fetal alcohol syndrome

- includes growth retardation, microcephaly, and congenital heart anomalies.
- considered the commonest cause of mild mental retardation.
- occurs once in every 500 live births.

F. Hydrocephalus (Figure 4.17)

- a dilation of the ventricles owing to an excess of CSF.
- may result from blockage of CSF circulation (e.g., aqueductal stenosis) or overproduction of CSF (e.g., choroid plexus papilloma of lateral ventricle). **Aqueductal stenosis** is the commonest cause of congenital hydrocephalus; it may be transmitted by an X-linked trait or may be caused by **cytomegalovirus** infection or **toxoplasmosis**.
 1. **Communicating hydrocephalus** results from obstruction distal to the ventricles (e.g., **sub-arachnoid hemorrhage** or **meningitis**).
 2. **Noncommunicating hydrocephalus** results from obstruction within the ventricle system (e.g., **aqueductal stenosis** or **ependymitis**).

G. Holoprosencephaly (Figure 4.18)

- results from failure of midline cleavage (diverticularization) of the embryonic forebrain. The telencephalon contains a single ventricular cavity.
- characterized by the absence of olfactory bulbs and tracts (**arhinencephaly**).
- seen in trisomy 13 (**Patau syndrome**).
- may result from alcohol abuse during pregnancy, especially in the first 4 weeks.
- the most severe manifestation of **fetal alcohol syndrome**.
- in extreme forms (alobar and semilobar), it results in the absence of corpus callosum and septum pellucidum.

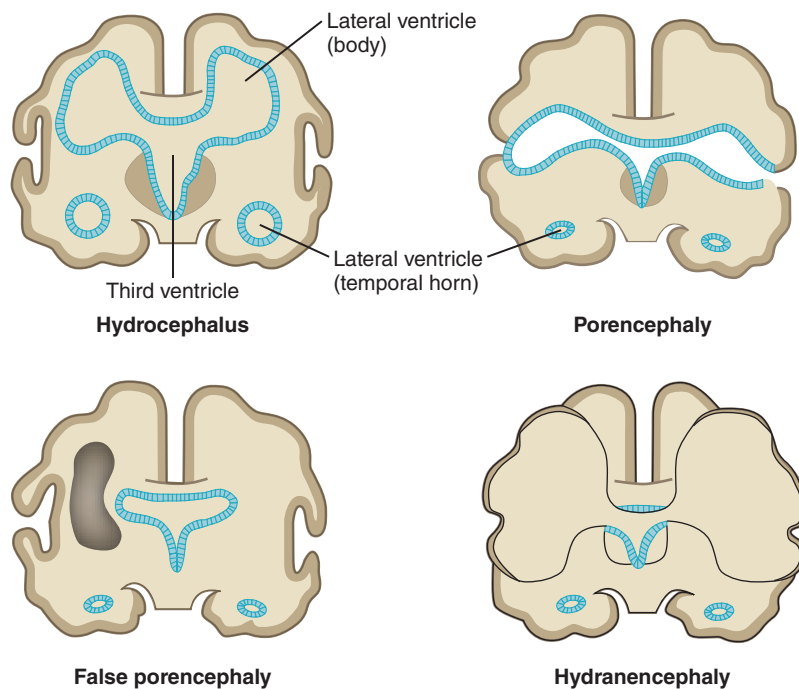


FIGURE 4.17. Cystic malformations of the prosencephalon (forebrain). Note the ependymal lining of these cysts. In hydranencephaly, the cyst is lined by glia and leptomeninges. In false porencephaly, the cyst is lined by glia. (Modified from Dudek RW, Fix JD. *BRS Embryology*. 2nd ed. Baltimore, MD: Williams & Wilkins; 1998:98.)

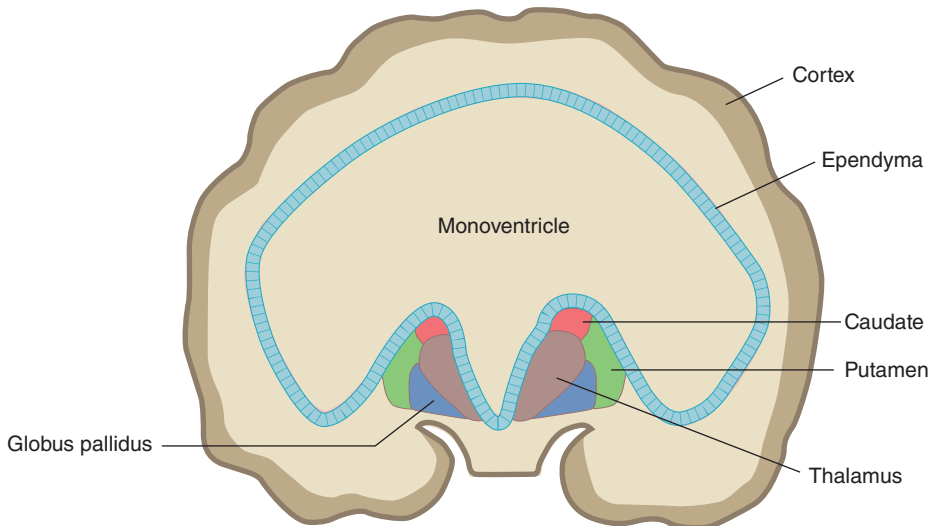


FIGURE 4.18. Holoprosencephaly results from failure of midline cleavage of the embryonic prosencephalon. The telencephalon contains a single ventricular cavity. It may result from alcohol abuse, especially during the first 4 weeks of pregnancy. (Modified from Dudek RW, Fix JD. *BRS Embryology*. 2nd ed. Baltimore, MD: Williams & Wilkins; 1998:99.)

H. Polyhydramnios

- an excess of amniotic fluid resulting from the inability of the fetus to swallow amniotic fluid.
- may result from esophageal atresia.

I. Hydranencephaly (see Figure .17)

- a congenital absence of the cerebral hemispheres that are replaced by immensely dilated ventricles.
- results from bilateral hemispherical infarction secondary to occlusion of the carotid arteries in utero.
- results also from severe necrotizing encephalitis in utero from **T**oxoplasma, **R**ubella, **C**ytomegalovirus, or **H**erpesvirus (TORCH).

J. Porencephaly (see Figure 4.17)

- cystic cavitation of the prosencephalon owing to agenesis of the cortical mantle. The cavity is lined with ependyma and communicates with the lateral ventricle.
- called schizencephaly when the condition is bilateral.

K. False porencephaly (see Figure 4.17)

- a malformation consisting of cystic cavities that are lined with glia and do not communicate with the lateral ventricle.

L. Tethered spinal cord (filum terminale syndrome)

- results from a thick, short filum terminale.
- leads to weakness and sensory deficits in the lower extremity and a neurogenic bladder. Deficits usually improve after transection.

Review Test

1. The neural retina is derived from the

- (A) alar plate
- (B) choroid
- (C) neural crest
- (D) neural tube
- (E) telencephalic vesicle wall

2. At which vertebral level is the conus medullaris found at birth?

- (A) VT12
- (B) VL1
- (C) VL3
- (D) VS1
- (E) VS4

3. Caudal herniation of the cerebellar tonsils and medulla through the foramen magnum is called

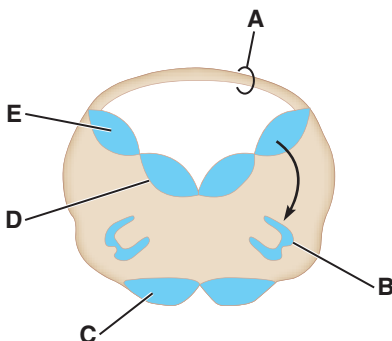
- (A) Arnold-Chiari syndrome
- (B) cranium bifidum
- (C) Dandy-Walker syndrome
- (D) Down syndrome
- (E) myeloschisis

4. A newborn has multiple congenital defects owing to dysgenesis of the neural crest. Which of the following cells is most likely to be spared?

- (A) Geniculate ganglion cells
- (B) Melanocytes
- (C) Motor neurons
- (D) Parafollicular cells
- (E) Spinal ganglion cells

Questions 5 to 9

Match the statements in items 5 to 9 with the appropriate lettered structure shown in the figure.



5. Is derived from the telencephalon

6. Gives rise to the choroid plexus

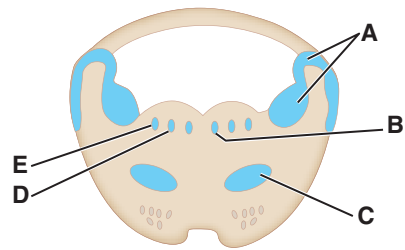
7. Is derived from the alar plate

8. Gives rise to motor neurons that innervate the tongue

9. Gives rise to the solitary nucleus

Questions 10 to 14

Match the statements in items 10 to 14 with the appropriate lettered structure shown in the figure.



10. Innervates the lateral rectus muscle

11. Gives rise to a parasympathetic nucleus

12. Gives rise to the cerebellum

13. Is derived from the alar plate

14. Gives rise to motor neurons that migrate into the lateral pontine tegmentum

Answers and Explanations

- 1–D.** The retina is derived from the neural tube, which gives rise to the entire CNS.
- 2–C.** At birth, the conus medullaris extends to VL3, and in the adult it extends to the VL1–VL2 interspace. At 8 weeks, the spinal cord extends the entire length of the vertebral canal.
- 3–A.** Arnold–Chiari syndrome is a cerebellomedullary malformation where the inferior vermis and medulla herniate through the foramen magnum and result in communicating hydrocephalus. Arnold–Chiari syndrome is frequently associated with spina bifida.
- 4–C.** Motor neurons develop from the neural tube, more specifically from the basal plate. The other options are derivatives of the neural crest.
- 5–C.** The corticospinal tract (pyramid) has its origin in the neocortex of the telencephalon.
- 6–A.** The tela choroidea gives rise to the choroid plexus.
- 7–B.** The inferior olivary nucleus is derived from the alar plate of the developing medulla.
- 8–D.** The basal plate gives rise to the hypoglossal nucleus.
- 9–E.** The alar plate gives rise to the solitary nucleus.
- 10–B.** The GSE column innervates the lateral rectus muscle.
- 11–E.** The GVE column gives rise to the superior salivatory nucleus of CN VII. This parasympathetic nucleus innervates the lacrimal, the sublingual, and the submandibular glands and also the palatine and nasal glands.
- 12–A.** The cerebellum is derived from the alar plate. The alar plate gives rise to the rhombic lip, which becomes the cerebellum.
- 13–C.** The pontine nuclei are derived from the alar plate.
- 14–D.** The SVE column gives rise to motor neurons that migrate into the lateral pontine tegmentum and become the facial nucleus, CN VII.

Objectives

- Classify neurons according to their morphology.
- Recognize unique structural and functional characteristics of neurons.
- List the various types of neuroglia and include a description of each along with a description of the various types of gliomas.
- Describe the processes of nerve cell degeneration and regeneration.
- List the types of axonal transport and the mechanisms associated with each type.
- Describe the types of peripheral nervous system (PNS) receptors and include characteristics such as adaption level, modality, and fiber types associated with each.

I. OVERVIEW

- develop from ectoderm (neural tube and neural crest).
- consists of neurons and glial cells.

II. NEURONS

- constitute the genetic, anatomic, trophic, and functional units of the nervous system (known as the neuron doctrine).
- mostly lost the capacity to undergo cell division.
- capacity to *receive* impulses from receptor organs or other neurons.
- capacity to *transmit* impulses to other neurons or effector organs.
- consist of a **cell body** and its processes, **dendrites**, and a single **axon**.

A. Classification of neurons (Figure 5.1)

- according to **number of processes** (unipolar, bipolar, or multipolar), **axonal length**, **function**, and **neurotransmitter**.
 1. **Processes**
 - **Unipolar or pseudounipolar neurons**
 - a. sensory neurons in the posterior root and cranial nerve ganglia and in the mesencephalic nucleus of the trigeminal nerve (CN V).
 - **Bipolar neurons**
 - a. located in the vestibular and cochlear ganglia of the vestibulocochlear nerve (CN VIII), the retina, and the olfactory epithelium (CN I).

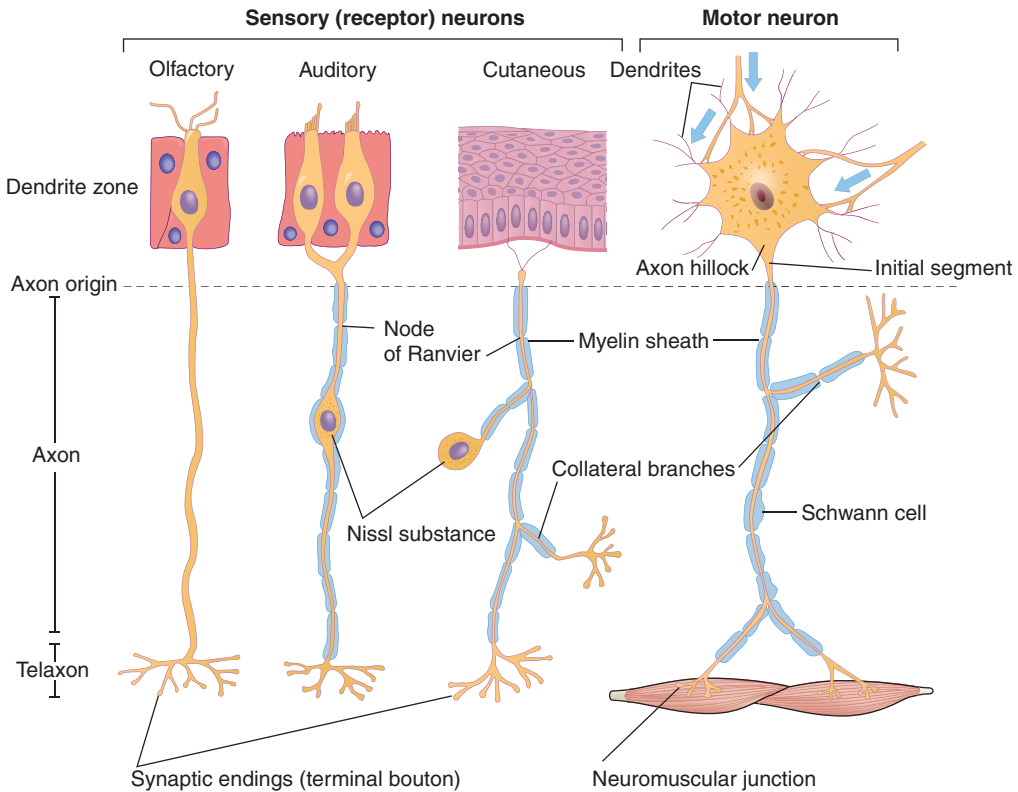


FIGURE 5.1. Types of nerve cells. Olfactory neurons are bipolar and unmyelinated, whereas auditory neurons are bipolar and myelinated. Spinal ganglion cells (cutaneous) are pseudounipolar and myelinated and motor neurons are multipolar and myelinated. *Arrows* indicate input via axons of other neurons. Nerve cells are characterized by the presence of Nissl substance and rough endoplasmic reticulum. (Modified from Carpenter MB, Sutin J. *Human Neuroanatomy*. 8th ed. Baltimore, MD: Williams & Wilkins; 1983:92.)

- **Multipolar neurons**
 - a. possess one axon and more than one dendrite.
 - b. the largest population of nerve cells in the nervous system.
 - c. include motor neurons, interneurons, pyramidal cells of the cerebral cortex, and Purkinje cells of the cerebellar cortex.
- 2. **Axonal length**
 - **Golgi type I neurons**
 - a. long axons (e.g., giant pyramidal cells of Betz of the motor cortex).
 - **Golgi type II neurons**
 - a. short axons (e.g., interneurons).
- 3. **Function**
 - **Motor neurons**
 - a. conduct impulses to muscles, glands, and blood vessels.
 - b. found in the anterior horn of the spinal cord.
 - **Sensory neurons**
 - a. receive stimuli from the external and internal environment (e.g., spinal ganglion cells).
 - **Interneurons**
 - a. intercalated or internuncial neurons that interconnect motor or sensory neurons within the central nervous system (CNS).
- 4. **Neurotransmitter (cholinergic neurons)**
 - elaborates acetylcholine as a neurotransmitter (e.g., anterior horn motor neurons).

B. Nerve cell body

- also called the **soma** or **perikaryon**.
- contains the organelles found in other cells, including a large nucleus and a prominent nucleolus.
- has receptor molecules on its plasmalemmal surface that confer sensitivity to various neurotransmitters.
- incorporates or gives rise to the following structures:
 1. **Nissl substance**
 - characteristic of nerve cells and consists of rosettes of polysomes and rough endoplasmic reticulum.
 - plays a role in **protein synthesis**.
 - abundant throughout cytoplasm and dendrites but is *not* found in the axon hillock or in the axon.
 2. **Lysosomes**
 - membrane-bound dense bodies that contain hydrolytic enzymes and are involved in the process of **intracellular digestion**.
 - a genetic defect in the synthesis of lysosomal enzymes results in a storage disease (e.g., Tay–Sachs disease [GM₂ gangliosidosis]).
 3. **Filamentous protein structures**
 - form an internal supportive network—the **cytoskeleton**:
 - a. **Microtubules** (25 nm in diameter)
 - found in the cell body, dendrites, and axons.
 - play a role in the **development** and **maintenance** of cell shape.
 - play a role in intracellular transport.
 - b. **Neurofilaments** (10 nm in diameter)
 - consist of spiral protein threads that play a role in **developing** and **regenerating nerve fibers**.
 - degenerate in Alzheimer's disease to form **neurofibrillary tangles**.
 - contain a neurofilament protein that is exclusive to neurons and their precursors.
 - c. **Microfilaments** (5 nm in diameter)
 - composed of **actin**.
 - found in the tips of growing axons.
 - facilitate movement of plasma membrane and growth of nerve cell processes.
 4. **Inclusion bodies**
 - pigment granules:
 - a. **Lipofuscin (lipochrome) granules**
 - common pigmented inclusions of cytoplasm that accumulate with aging.
 - considered to be residual bodies derived from lysosomes.
 - b. **Neuromelanin (melanin)**
 - blackish pigment in the neurons of the substantia nigra and locus ceruleus.
 - disappears from the substantia nigra and the locus ceruleus in Parkinson disease.
 - c. **Lewy bodies**
 - eosinophilic intracytoplasmic inclusion bodies found in the substantia nigra in patients with Parkinson disease.
 5. **Dendrites**
 - processes that extend from the cell body.
 - contain cytoplasm similar in composition to that of the cell body; however, no Golgi apparatus is present.
 - conduct in a decremental fashion and capable of generating action potentials.
 - receive synaptic input and transmit it toward the cell body.
 6. **Axons**
 - arise from either the cell body or the dendrite.
 - originate from the axon hillock that lacks Nissl substance.
 - give rise to collateral branches.
 - myelinated or unmyelinated.
 - **generate, propagate, and transmit action potentials**.
 - end distally in terminal boutons in synapses with neurons, muscle cells, and glands.

table 5.1 Classification of Nerve Fibers

Fibers	Diameter (mm) ^a	Conduction Velocity (m/sec)	Function
Sensory axons			
Ia (A-α)	12–20	70–120	Proprioception and muscle spindles
Ib (A-α)	12–20	70–120	Proprioception and Golgi tendon organs
II (A-β)	5–12	30–70	Touch, pressure, and vibration
III (A-β)	2–5	12–30	Touch, pressure, fast pain, and temperature
IV (C)	0.5–1	0.5–2	Slow pain and temperature, unmyelinated fibers
Motor axons			
Alpha (A-α)	12–20	15–120	Alpha motor neurons of anterior horn (innervate extrafusal muscle fibers)
Gamma (A-γ)	2–10	10–45	Gamma motor neurons of anterior horn (innervate intrafusal muscle fibers)
Preganglionic autonomic fibers (B)	<3	3–15	Myelinated preganglionic autonomic fibers
Postganglionic autonomic fibers (C)	1	2	Unmyelinated postganglionic autonomic fibers

^aMyelin sheath included if present.

7. Nerve fibers (Table 5.1)
 - consist of axons, dendrites, and their glial investments.
 - classified by function, fiber size, and conduction velocity.
8. Myelin sheath
 - produced in the PNS by Schwann cells.
 - produced in the CNS by oligodendrocytes.
 - interrupted by the nodes of Ranvier.
 - consists of wrappings of the Schwann cells or oligodendrocyte plasma membrane.
9. Synapses
 - the **sites of functional contact** of a nerve cell with another nerve cell, an effector cell, or a sensory receptor cell.
 - consist of presynaptic membrane, synaptic cleft, and postsynaptic membrane.
 - classified by the site of contact (e.g., axosomatic, axodendritic, or axoaxonic).
 - also classified as chemical or electrical:
 - a. **Chemical synapses**
 - use neurotransmitters.
 - b. **Electrical synapses (ephapses)**
 - consist of gap junctions.
 - allow ions to pass from cell to cell.

III. NEUROGLIA

- nonneuronal cells of the CNS and the PNS.
 - arise from the neural tube and neural crest.
 - capable of cell division throughout life.
 - best revealed with gold and silver impregnation stains.
 - classified as **macroglia** (**astrocytes** and **oligodendrocytes**), **microglia**, and **ependyma**. Schwann cells are classified as peripheral neuroglia.
- A. Astrocytes
 - the largest glial cells.
 - consist of **fibrous astrocytes** that are found mainly in white matter and **protoplasmic astrocytes** that are found mainly in gray matter.

- play a role in the metabolism of certain neurotransmitters (gamma-aminobutyric acid [GABA], serotonin, and glutamate).
- buffer the potassium concentration of the extracellular space.
- contain glial filaments and glycogen granules as their most characteristic cytoplasmic components.
- form glial scars in damaged areas of the brain—a condition called **gliosis**.
- contain or give rise to the following structures:
 1. **Astrocytic end feet**
 - the processes that form the external glial limiting membrane (interface between pia mater and the CNS) and the internal glial limiting membrane (interface between the ependyma and the CNS).
 - a. **Perivascular end feet**
 - surround capillaries.
 - b. **Perineuronal end feet**
 - surround neurons.
 2. **Glial filaments**
 - contain **glial fibrillary acidic protein (GFAP)**, a marker for astrocytes.
 3. **Glycogen granules**
 - accumulations of polysaccharide.

B. Oligodendrocytes

- small glial cells with few short processes.
- lack glial filaments and glycogen granules.
- the myelin-forming cells of the CNS; one oligodendrocyte can myelinate numerous axons.
 1. **Interfascicular oligodendrocytes**
 - found in white matter.
 2. **Satellite cells**
 - found in gray matter.

C. Microglia

- arise from monocytes that enter the CNS from the blood.
- activated by inflammatory and degenerative processes.
- macrophages are migratory and phagocytize debris.

D. Ependymal cells

- line the central canal of the spinal cord and ventricles of the brain.
- possess cilia only in embryologic stages.
- include choroid epithelial cells of the choroid plexus and tanycytes of the third ventricle; the choroid plexus cells produce cerebrospinal fluid (CSF) and are interconnected by tight junctions that constitute the **blood–CSF barrier**.

E. Schwann cells (neurolemmal cells)

- derivatives of the neural crest.
- myelin-forming cells of the PNS; a Schwann cell myelinates only one internode.
- invest unmyelinated axons of the PNS.
- function in regeneration and remyelination of severed axons in the PNS (Figure 5.2).
- separated from each other by the **node of Ranvier**.

F. Tumors (gliomas) (Figure 5.3)

- derived from astrocytes, oligodendrocytes, or ependymocytes.
- result from proliferation of glioblasts—embryonic precursors.
- represent 51% of CNS tumors.
 1. **Astrocytomas** (see Figure 5.3)
 - most commonly found in the white matter of the cerebral hemisphere in middle and late life.

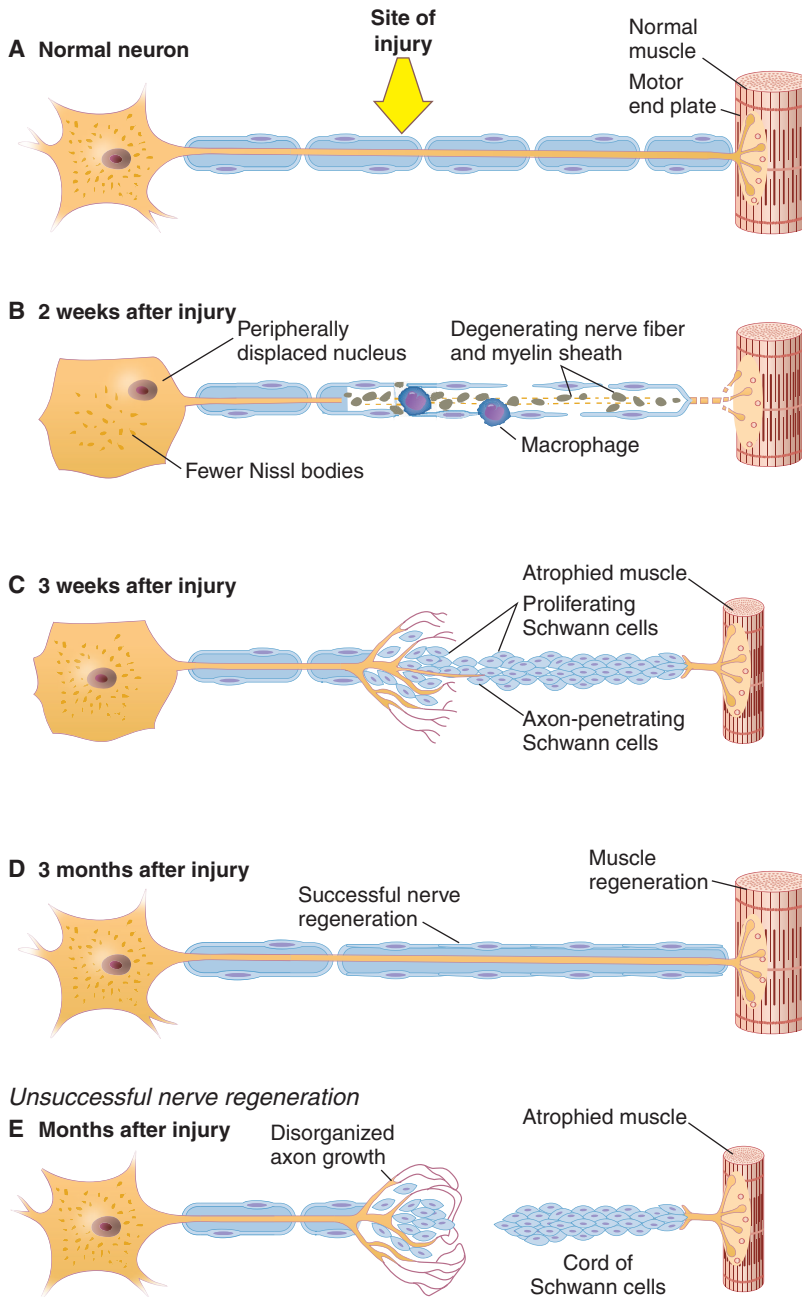


FIGURE 5.2. Wallerian (anterograde) degeneration and regeneration of a nerve fiber.

- astrocytomas of the cerebellum are the commonest intracranial tumor in children.
- commonest type of brain cancer.
 - Benign astrocytomas**
 - slow-growing neoplasms of infiltrative character.
 - arise from **astroblasts**, embryonic precursors.
 - represent 25% of primary intracranial tumors.
 - frequently become malignant (**anaplastic astrocytomas**).

A**Germinomas**

- germ cell tumors commonly seen in pineal region (> 50%)
- overlie tectum of midbrain
- cause obstructive hydrocephalus due to aqueductal stenosis
- common cause of Parinaud's syndrome

Brain abscesses

- may result from sinusitis, mastoiditis, hematogenous spread
- location: frontal and temporal lobes, cerebellum
- organisms: streptococci, staphylococci, and pneumococci
- result in cerebral edema and herniation

Colloid cysts of third ventricle

- comprise 2% of intracranial gliomas
- are of ependymal origin
- found at interventricular foramina
- ventricular obstruction results in increased intracranial pressure and may cause positional headaches, "drop attacks," or sudden death

Meningiomas

- derived from arachnoid cap cells and represent second most common primary intracranial brain tumor after astrocytomas (15%)
- are not invasive; they indent brain; may produce hyperostosis
- pathology: concentric whorls and calcified psammoma bodies
- location: parasagittal and convexity
- gender: females > males
- associated with neurofibromatosis-2 (NF-2)

Astrocytomas

- represent 20% of gliomas
- histologically benign
- diffusely infiltrate hemispheric white matter
- most common glioma found in posterior fossa of children

Glioblastoma multiforme

- represents 55% of gliomas
- malignant; rapidly fatal astrocytic tumor
- commonly found in frontal and temporal lobes and basal nuclei
- frequently crosses midline via corpus callosum (butterfly glioma)
- most common primary brain tumor
- histology: pseudopalisades, perivascular pseudorosettes

Oligodendrogliomas

- represent 5% of all gliomas
- grows slowly and are relatively benign
- most common in frontal lobe
- calcification in 50% of cases
- cells look like fried eggs (perinuclear halos)

Ependymomas**B****Choroid plexus papillomas**

- histology: benign; no necrosis or invasive features
- represent 2% of the gliomas
- one of the most common brain tumors in patients <2 years of age
- occur in decreasing frequency: fourth, lateral, and third ventricle
- CSF overproduction may cause hydrocephalus

Cerebellar astrocytomas

- benign tumors of childhood with good prognosis
- most common pediatric intracranial tumor
- contain pilocytic astrocytes and Rosenthal fibers

Medulloblastomas

- represent 7% of primary brain tumors
- represent primitive neuroectodermal tumors (PNET)
- second most common posterior fossa tumor in children
- responsible for posterior vermis syndrome
- can metastasize via CSF tracts
- highly radiosensitive

Hemangioblastomas

- characterized by abundant capillary blood vessels and foamy cells; most often found in cerebellum
- when found in cerebellum and retina, may represent part of von Hippel-Lindau syndrome
- 2% of primary intracranial tumors; 10% of posterior fossa tumors

Intraspinal tumors

- Schwannomas 30%
- Meningiomas 25%
- Gliomas 20%
- Sarcomas 12%
- Ependymomas represent 60% of intramedullary gliomas

Ependymomas

- represent 5% of the gliomas
- histology: benign, ependymal tubules, perivascular pseudorosettes
- 40% are supratentorial; 60% are infratentorial (posterior fossa)
- most common spinal cord glioma (60%)
- third most common posterior fossa tumor in children and adolescents

Craniopharyngiomas

- represent 3% of primary brain tumors
- derived from epithelial remnants of Rathke pouch
- location: suprasellar and inferior to optic chiasma
- cause bitemporal hemianopia and hypopituitarism
- calcification is common

Pituitary adenomas (PA)

- most common tumors of pituitary gland
- prolactinoma is most common PA
- derived from the stomodaeum (Rathke pouch)
- represent 8% of primary brain tumors
- may cause hypopituitarism, visual field defects (bitemporal hemianopia and cranial nerve palsies CN III, IV, VI, V₁ and V₂, and postganglionic sympathetic fibers to dilator pupillae)

Schwannomas (acoustic neuromas)

- consist of Schwann cells and arise from vestibular division of CN VIII
- comprise approx. 8% of intracranial neoplasms
- pathology: Antoni A and B tissue and Verocay bodies
- bilateral acoustic neuromas are diagnostic of NF-2
- gender: females > males

Brainstem glioma

- usually benign pilocytic astrocytoma
- usually causes cranial nerve palsies
- may cause "locked-in" syndrome

FIGURE 5.3. Tumors of the central nervous system and peripheral nervous system. **(A)** Supratentorial tumors. **(B)** Infratentorial tumors (posterior fossa) and intraspinal tumors. In children, 70% of tumors are infratentorial. In adults, 70% of tumors are supratentorial. CN = cranial nerve; CSF = cerebrospinal fluid. (Modified from Fix JD. *High-Yield Neuroanatomy*. 3rd ed. Philadelphia, PA: Lippincott Williams & Wilkins; 2005:52.)

- b. Malignant astrocytomas (glioblastoma multiforme)**
 - rapid-growing, fatal astrocytic tumors.
 - occur twice as frequently in men as in women.
 - arise from **astroblasts**.
 - the commonest primary brain tumors.
- 2. Oligodendrogliomas** (see Figure 5.3)
 - slow-growing, benign tumors.
 - occur mainly in adults.
 - most frequently found in the cerebral hemisphere.
 - may arise from **oligodendroblasts**, embryonic precursors.
 - usually well-circumscribed and are frequently calcified.
 - may change and become glioblastomas.
- 3. Ependymomas** (see Figure 5.3)
 - slow-growing, benign circumscribed neoplasms typically found within the ventricles.
 - the commonest gliomas found in the spinal cord, most frequently in the lumbosacral segments.
 - arise from **ependymal cells**.
- 4. Schwannomas** (see Figure 5.3)
 - benign tumors of peripheral nerves.
 - account for 6% of primary intracranial tumors.
 - occur twice as frequently in females as in males.
 - arise from **Schwann cells**.
- 5. Meningiomas** (see Figure 5.3)
 - slow-growing tumors of mesenchymal origin.
 - account for 15% of primary intracranial tumors.
 - supratentorial in 90% of cases.
 - have a female-to-male ratio of 3:2.
- 6. Medulloblastomas** (see Figure 5.3)
 - found in the infratentorial compartment and are thought to arise from the external granular layer of the cerebellar cortex.
 - represent 20% of the primary intracranial tumors found in children.

IV. NERVE CELL DEGENERATION AND REGENERATION (SEE FIGURE 5.2)

A. Retrograde degeneration

- occurs toward the proximal end of an axon, including the cell body.
- takes place in both the CNS and the PNS.
- reaction begins 2 days or even sooner after insult and reaches a maximum in about 20 days.
- involves the following changes:
 1. Disappearance of Nissl substance (chromatolysis)
 2. Swelling of the cell body
 3. Flattening and displacement of the nucleus to the periphery

B. Anterograde (wallerian) degeneration (see Figure 5.2)

- occurs toward the distal end of the axon.
- takes place in both the PNS and the CNS.
- characterized by successive fragmentation and disappearance of axons and myelin sheaths and by secondary proliferation of Schwann cells.

C. Regeneration of the peripheral nerve fiber (see Figure 5.2)

- If the severed distal nerve fiber maintains its integrity and the tube of basement membrane and endoneurium is maintained, an axon sprout may grow into it.

- Schwann cells proliferate along a degenerating axon and myelinate a new axon sprout, which grows at the rate of 3 mm/day.
- If the path of regenerating axons is blocked, a traumatic neuroma forms at the site of obstruction. A neuroma comprises a proliferative mass of axons and Schwann cells.

D. Regeneration of axons in the CNS

- No Schwann cell basement membranes or endoneurial investments surround axons of the CNS.
- Effective regeneration does not occur in the CNS.

V. AXONAL TRANSPORT

- mediates the intracellular distribution of secretory proteins, organelles, and cytoskeletal elements.
- inhibited by colchicine that depolymerizes microtubules.

A. Fast anterograde transport

- responsible for transporting newly synthesized membranous organelles (vesicles) and precursors of neurotransmitters at 200 to 400 mm/day.
- mediated by microtubules and **kinesin** (fast transport is microtubule-dependent).

B. Fast mitochondrial transport

- occurs at the rate of 50 to 100 mm/day.

C. Slow anterograde transport

- responsible for transporting cytoskeletal and cytoplasmic elements at 1 to 5 mm/day.
- moves unidirectionally away from the cell body.
- transports neurofilaments and microtubules.

D. Fast retrograde transport

- returns used materials from the axon terminal to the cell body for degradation and recycling at the rate of 100–200 mm/day.
- transports nerve growth factor and neurotropic viruses and toxins (herpes simplex, rabies, polioviruses, and tetanus toxin).
- mediated by microtubules and **dynein**.

VI. CAPILLARIES OF THE CENTRAL NERVOUS SYSTEM (FIGURE 5.4)

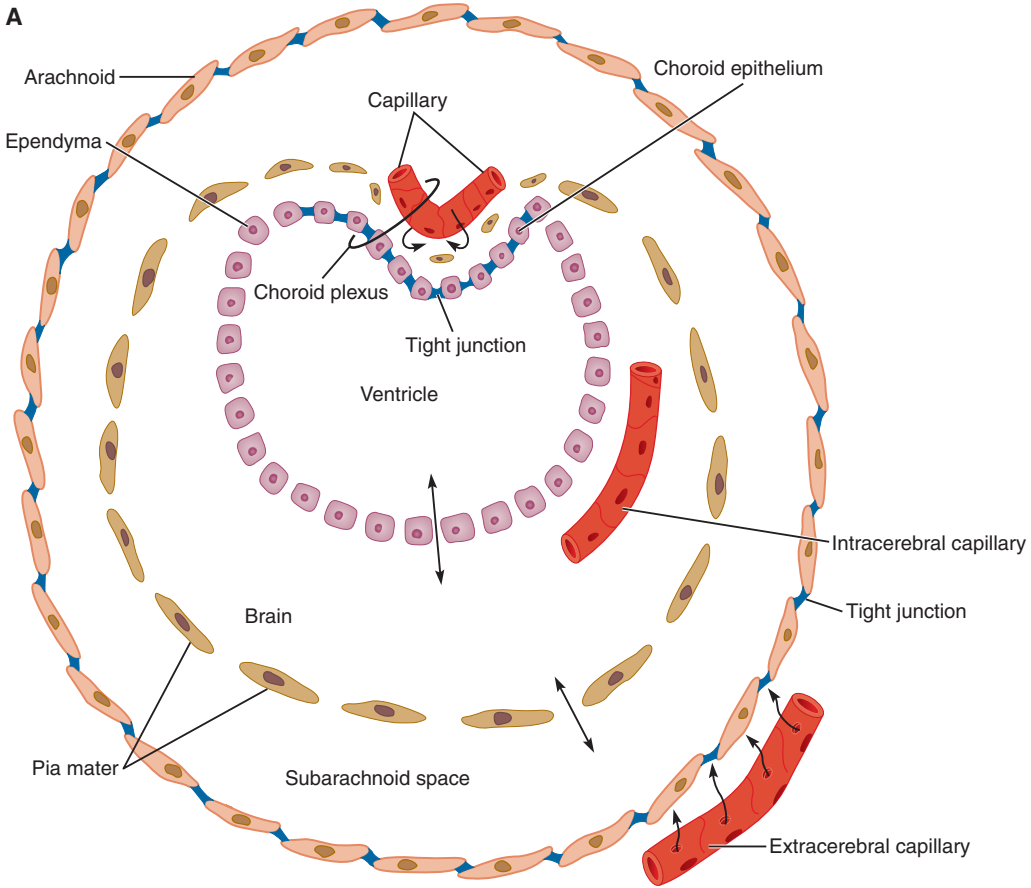
- have a higher density in gray matter than in white matter and are of two types:

A. Nonfenestrated capillaries

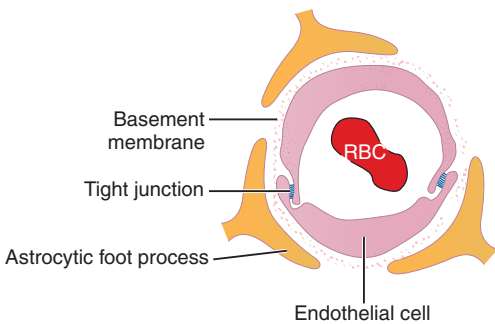
- ubiquitous in white and gray matter.
- have endothelial cells with tight junctions surrounded by a continuous basement membrane and an outer investment of astrocytic foot processes; the endothelial cells and their tight junctions constitute the **blood–brain barrier**.

B. Fenestrated capillaries

- consist of endothelial cells with fenestrations that permit the free passage of blood-borne substances into the extracellular spaces of the CNS.
- located in specialized areas of the brain that lack a blood–brain barrier (e.g., circumventricular organs).



B Brain Capillary



C General Capillary

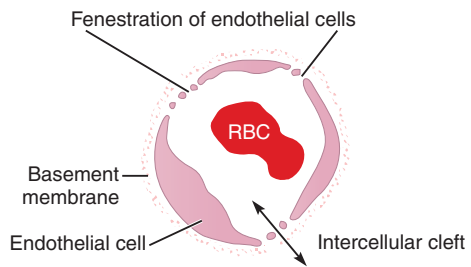


FIGURE 5.4. The blood–brain barrier and the blood–CSF barrier. Compare the difference between the intracerebral capillaries (**B**), the extracerebral capillaries (**C**), and the capillaries of the choroid plexus (**A**). Barrier function is mediated by tight junctions between the endothelial cells and between choroid plexus epithelial cells. Tumors and cerebrovascular accidents disrupt the endothelial wall and cause cerebral edema (vasculotoxic edema). *CSF* = cerebrospinal fluid. (Adapted from Nolte J. *Human Brain*. 2nd ed. Washington, DC: Mosby; 1988, with permission.)

VII. SENSORY RECEPTORS

A. Pain and temperature receptors

- free (nonencapsulated) nerve endings.
- ubiquitous (e.g., in the epidermis, dermis, cornea).
- associated with A delta (group III) and C (group IV) fibers.
- project via the anterolateral system.
- slow-adapting.

B. Cutaneous mechanoreceptors

- endings that respond to touch and pressure.

1. Merkel tactile disks

- nonencapsulated endings found in the basal layer of the epidermis.
- mediate light (crude) touch (e.g., stroking the skin with a wisp of cotton).
- associated with group II fibers.
- project centrally via the anterolateral system and the posterior column–medial lemniscus pathway.
- slow-adapting.

2. Meissner corpuscles (Figure 5.5)

- encapsulated endings found in the dermal papillae of glabrous skin.
- mediate fine discriminative tactile sensation via the posterior column–medial lemniscus pathway.
- associated with group II fibers.
- rapidly adapting.

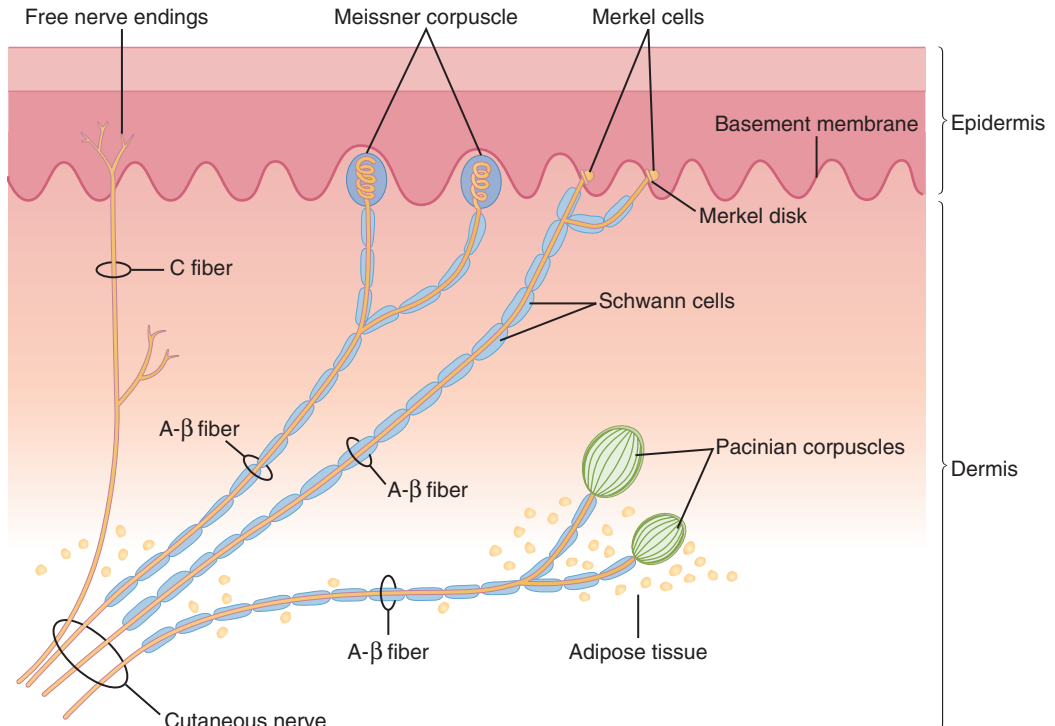


FIGURE 5.5. Four cutaneous receptors: free nerve endings—mediate pain and temperature sensation; Meissner corpuscles of the dermal papillae—mediate tactile two-point discrimination; pacinian corpuscles of the dermis—mediate touch, pressure, and vibration sensation; and Merkel disks—mediate light touch. (Modified from Fix JD. *High-Yield Neuroanatomy*. 3rd ed. Philadelphia, PA: Lippincott Williams & Wilkins; 2005:53, with permission.)

3. Pacinian corpuscles

- found in the dermis, mesenteries, and periosteum.
- respond to pressure and vibration sensation via the posterior column–medial lemniscus pathway.
- associated with group II fibers.
- rapidly adapting.

C. Muscle and tendon receptors

- encapsulated mechanoreceptors and proprioceptors.

1. Muscle spindles

- consist of capsules containing intrafusal fibers (i.e., nuclear bag and nuclear chain fibers).
- arranged parallel with the extrafusal fibers of the muscle.
- mediate via group Ia afferents, the muscle stretch reflex (MSR) and the myotatic reflex (e.g., patellar reflex).
- sense the relative length of the muscle (static function) and the rate of change of length (dynamic function).
- the activity of the gamma motor neurons regulates the sensitivity of the muscle spindle to stretch.

a. Nuclear bag fibers

- receive group Ia primary afferent fibers (annulospiral endings) and static and dynamic gamma efferent fibers.
- respond primarily to the rate of change of muscle length.

b. Nuclear chain fibers

- receive group Ia primary and group II secondary afferent fibers (flower spray endings) and static gamma efferent fibers.
- respond primarily to muscle length.

2. Gamma motor neurons

- consist of static and dynamic motor neurons.
- found in the anterior horn with alpha motor neurons.
- receive input from descending motor pathways (e.g., corticospinal and reticulospinal tracts).
- modify the sensitivity of muscle spindles.
- coactivated along with alpha motor neurons.

3. Golgi tendon organs (GTOs)

- found at the junction of the muscle and its tendon and are connected with the muscle fibers in series.
- respond to muscle tension during muscle stretch and contraction and are also sensitive to the velocity of tension development.
- innervated by group Ib fibers.

Review Test

1. Peripheral nerve fibers regenerate at the rate of ____ mm/day.

- (A) 0.1
- (B) 3
- (C) 100
- (D) 200
- (E) 400

2. Fast pain has a conduction velocity of ____ m/sec.

- (A) 1
- (B) 5
- (C) 15
- (D) 50
- (E) 100

3. A 10-year-old boy has severed his radial nerve. Which of the following cells plays a major role in axonal regrowth?

- (A) Fibrous astrocytes
- (B) Fibroblasts
- (C) Oligodendrocytes
- (D) Protoplasmic astrocytes
- (E) Schwann cells

4. Which of the following receptors initiates the MSR?

- (A) End bulbs of Krause
- (B) Merkel disks
- (C) Muscle spindles
- (D) Ruffini end bulbs
- (E) Vater-Pacini corpuscles

5. Wallerian degeneration involves:

- (A) chromatolysis.
- (B) only the CNS.
- (C) successive fragmentation of the axon.
- (D) swelling of the cell body.
- (E) the proximal end of the axon.

6. A 46-year-old female nurse complains of right-sided hearing loss and vertigo (dizziness). A small tumor was demonstrated within the internal auditory canal. Which structure

listed below accounts for the hearing loss and vertigo?

- (A) Arachnoid cyst
- (B) Ependymoma
- (C) Epidermoid cyst
- (D) Meningioma
- (E) Schwannoma

7. A 9-year-old boy has a stumbling gait, dizziness, diplopia, headache, vomiting, and coarse nystagmus toward the side of the lesion. He scans his speech. Tests for dysdiadochokinesia, papilledema, elevated CSF protein, and intention tremor are positive. Match this symptom complex with the best-fitting choice.

- (A) Craniopharyngioma
- (B) Medulloblastoma
- (C) Meningioma
- (D) Oligodendroglia
- (E) von Hippel-Lindau disease

Questions 8 to 12

The response options for items 8 to 12 are the same. Select one answer for each item in the set.

- (A) Astrocytes
- (B) Microglial cells
- (C) Oligodendrocytes
- (D) Schwann cells
- (E) Tanycytes

Match each of the following descriptions with the corresponding type of nerve cell.

8. Are a variety of ependymal cell found in the wall of the third ventricle

9. Arise from monocytes

10. Are neural crest derivatives

11. Contain glial filaments and glycogen granules

12. Are perineuronal satellite cells in the CNS

Answers and Explanations

- 1–B.** Peripheral nerve fibers regenerate at 3 mm/day.
- 2–C.** Fast pain has a nerve fiber (A delta) conduction velocity of 12 to 30 m/sec. Slow pain has a nerve fiber (C) conduction velocity of 0.5 to 2 m/sec.
- 3–E.** Schwann cells play a major role in axon regeneration (axon regrowth) in the PNS.
- 4–C.** The muscle stretch reflex is initiated by muscle spindles.
- 5–C.** Wallerian, or anterograde, degeneration occurs toward the distal end of the axon in both the CNS and PNS and is characterized by successive fragmentation and disappearance of axons and myelin sheaths and by secondary proliferation of Schwann cells. Retrograde degeneration occurs toward the proximal end of the axon and in the cell body. It takes place in both the CNS and PNS and is characterized by chromatolysis, cell body swelling, and flattening and displacement of the nucleus to the periphery.
- 6–E.** A schwannoma is a benign tumor derived from Schwann cells of the vestibular division of CN VIII (acoustic neuroma of CN VIII). Schwannomas occur twice as frequently in females as in males. Symptoms arise from pressure on the vestibular division, resulting in vertigo, and pressure on the cochlear division, resulting in nerve deafness (sensorineural). Acoustic neurinomas represent 8% of intracranial neoplasms. When bilateral they are diagnostic of type 2 neurofibromatosis. The internal auditory canal contains the facial and vestibulocochlear nerves and the labyrinthine artery, a branch of the anterior inferior cerebellar artery. An arachnoid cyst is a congenital disorder; it is a CSF sac that forms in the cranium or spinal cord. An ependymoma is a slow-growing, benign circumscribed neoplasm typically found within the ventricles. An epidermoid cyst is a benign cyst derived from ectodermal tissue. A meningioma is a slow-growing intracranial tumor of mesenchymal origin.
- 7–B.** The medulloblastomas are malignant neoplasms comprising one-third of the tumors in the posterior fossa of children. They are radiosensitive. Metastatic spread within the neuraxis is frequent. Meningiomas are benign tumors originating from arachnoid cells; they contain psammoma bodies that are calcified and visible on computed tomography. Oligodendroglia are the myelin-producing cells of the CNS. Craniopharyngiomas, congenital epidermoid tumors, are the commonest supratentorial tumors found in children. Von Hippel–Lindau disease is a rare genetic disorder that results in tumor growth in blood-rich areas of the body.
- 8–E.** Tanycytes are a variety of ependymal cell found in the wall of the third ventricle. The processes of these cells extend from the lumen of the third ventricle to the capillaries of the hypophyseal portal system and also to the neurosecretory neurons of the arcuate nucleus.
- 9–B.** Microglial cells, the scavenger cells of the CNS, arise from monocytes and enter the CNS via abnormal blood vessels.
- 10–D.** Schwann cells are derived from the neural crest; they myelinate the axons of the PNS.
- 11–A.** Astrocytes are characterized by the presence of glial filaments and glycogen; glial filaments contain GFAP, a marker for astrocytes.
- 12–C.** Oligodendrocytes are perineuronal satellite cells; they myelinate the axons of the CNS.

Objectives

- Identify the various external parts of the spinal cord; include attachments and structural characteristics.
- Describe the spinal nerve; include all possible components and derivatives and their locations.
- Identify the various internal parts of the spinal cord; include the subdivisions of the gray and white matter.
- Identify unique features of various spinal cord levels.
- Describe the myotatic reflex.

I. INTRODUCTION (FIGURE 6.1)

- derived from the caudal part of the neural tube.
- maintains segmental organization throughout development.
- surrounded by three membranes, the **meninges**.
- weighs about 30 g and comprises 2% of the weight of the adult brain.

II. EXTERNAL MORPHOLOGY

A. Location

- extends, in adults, from the foramen magnum to the inferior border of the first lumbar vertebra; in newborns, it extends to the third lumbar vertebra.
- continuous with the **medulla oblongata** at the spinomedullary junction, a plane defined by three structures: the foramen magnum, the pyramidal decussation, and the emergence of the first cervical nerve anterior rootlets.
- lies within the **subarachnoid space** that extends caudally to the level of the second sacral vertebra (see Figure 2.2).

B. Attachments

- suspend and anchor the spinal cord within the dural sac.
- arise from the **pia mater**, which closely invests the spinal cord.
 1. **Denticulate ligaments**
 - two flattened bands of pial tissue that attach to the spinal dura comprising 21 pairs of tooth-shaped extensions.

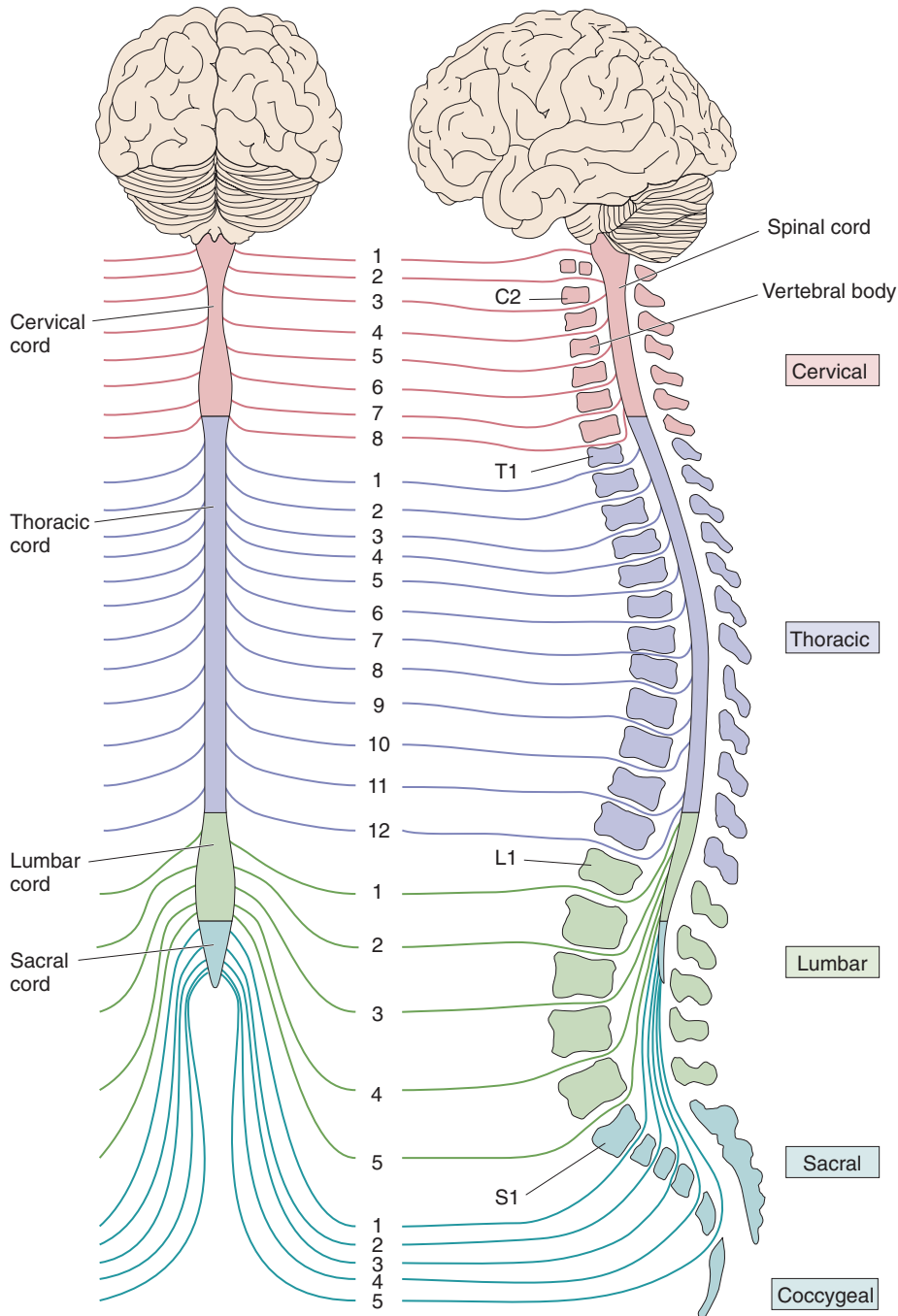


FIGURE 6.1. Diagram of the position of the spinal cord with reference to the vertebral bodies and spinous processes. The conus medullaris lies in the L1–L2 interspace. The dural sac ends at S2. (Adapted with permission from Bear MF, Connors BW, Paradiso MA. *Neuroscience: Exploring the Brain*. 2nd ed. Philadelphia, PA: Lippincott Williams & Wilkins; 2001, Fig. 12-10.)

2. Filum terminale

- an extension of pia mater that extends from the conus medullaris to the dural sac (internus) and from the dural sac to the coccyx (externus).

3. Spinal nerve roots

- provide strong anchorage and fixation of the spinal cord to the vertebral canal.

C. Shape

- an elongated and nearly cylindrical structure, approximately 1 cm in diameter.
- **cervical** (C5–T1) and **lumbar** (L1–S2) **enlargements** for the nerve supply of the upper and lower extremities.
- terminates caudally as the **conus medullaris**.
- in length, averages 45 cm in males and 42 cm in females.

D. Spinal nerves (Figure 6.2; see Figure 5.1)

- consist of 31 pairs of nerves that emerge from the spinal cord: **8 cervical**, **12 thoracic**, **5 lumbar**, **5 sacral**, and **1 coccygeal**.
- contain both motor and sensory fibers.

1. Special considerations

- The first cervical nerve and the coccygeal nerve usually have neither the posterior (sensory) roots nor the corresponding dermatomes.
- The first cervical nerve passes between the atlas and the skull.
- The second cervical nerve passes between the atlas and the axis.
- With the exception of C1, spinal nerves exit the vertebral canal via intervertebral or sacral foramina.

2. Functional components of spinal nerve fibers (Figure 6.3)

- **General somatic afferent (GSA) fibers**
 - a. convey sensory input from skin, muscle, bone, and joints to the central nervous system (CNS).
- **General visceral afferent (GVA) fibers**
 - a. convey sensory input from visceral organs to the CNS.
- **General somatic efferent (GSE) fibers**
 - a. convey motor output from anterior horn motor neurons to skeletal muscle.

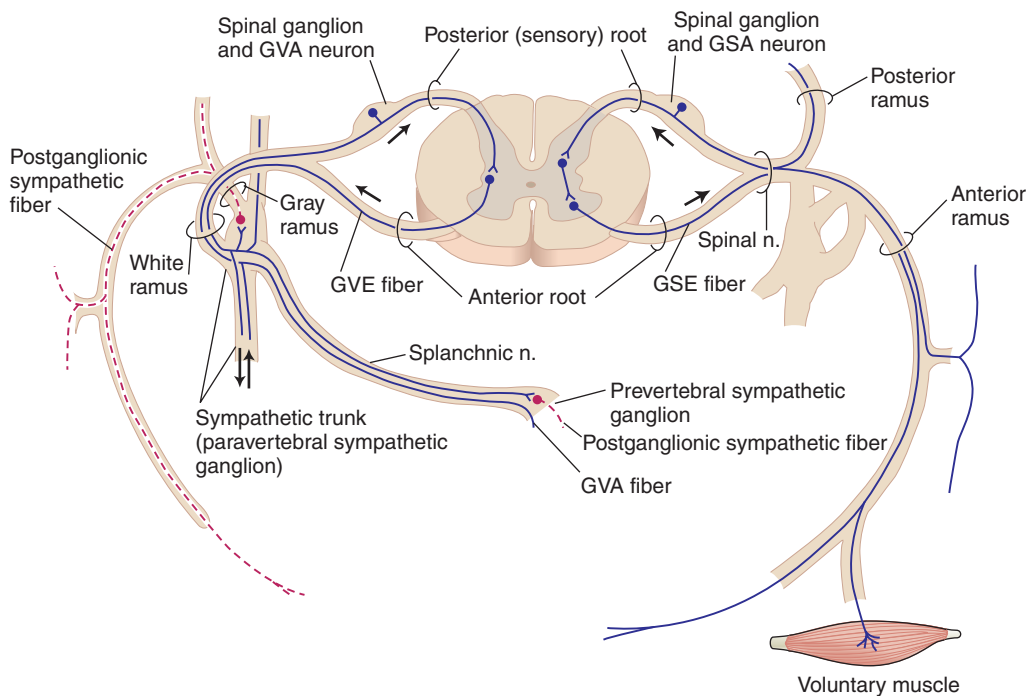


FIGURE 6.2. The typical thoracic spinal nerve and its branches and reflex connections. White communicating rami are found only at thoracolumbar levels T1 to L2. Gray communicating rami are found at all spinal cord levels. *GVA* = general visceral afferent; *GSA* = general somatic afferent; *GSE* = general somatic efferent; and *GVE* = general visceral efferent.

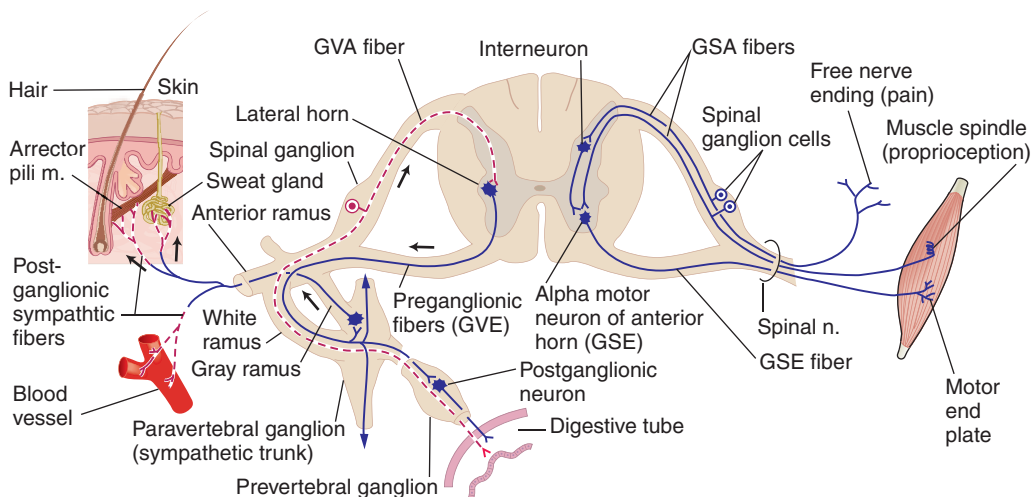


FIGURE 6.3. Diagram of the four functional components of the thoracic spinal nerve: general visceral afferent (GVA), general somatic afferent (GSA), general somatic efferent (GSE), and general visceral efferent (GVE). Proprioceptive, cutaneous, and visceral reflex arcs are shown. The muscle stretch (myotatic) reflex (MSR) includes the muscle spindle, GSA spinal ganglion cell, GSE anterior horn motor neuron, and skeletal muscle.

- **General visceral efferent (GVE) fibers**
 - a. convey motor output from intermediolateral cell column neurons, via paravertebral or prevertebral ganglia, to glands, smooth muscle, and visceral organs (sympathetic divisions of the autonomic nervous system).
 - b. convey motor output from the sacral parasympathetic nucleus to the pelvic viscera via intramural ganglia.
- 3. **Components and branches of spinal nerves**
 - The spinal nerve is formed by the union of posterior and anterior roots within the intervertebral foramen, resulting in a mixed nerve.
 - a. **Posterior root**
 - enters the posterior lateral sulcus as posterior rootlets and conveys sensory input from the body via the spinal ganglion.
 - contains, distally, the spinal ganglion.
 - joins the anterior root distal to the spinal ganglion and within the intervertebral foramen to form the spinal nerve.
 - b. **Spinal ganglion**
 - located within the posterior root and within the **intervertebral foramen**.
 - contains **pseudounipolar neurons** of neural crest origin that transmit sensory input from the periphery (GSA and GVA) to the spinal cord via the posterior roots.
 - c. **Anterior root**
 - emerges as anterior rootlets from the anterior lateral sulcus and conveys motor output from visceral and somatic motor neurons.
 - joins the posterior roots distal to the spinal ganglion and within the intervertebral foramen to form the spinal nerve.
 - d. **Cauda equina**
 - consists of lumbosacral (posterior and anterior) nerve roots (L2–Co) that descend from the spinal cord through the subarachnoid space to exit through their respective intervertebral or sacral foramina.
 - e. **Spinal nerve rami**
 - **Posterior ramus**
 - (1) innervates the skin and muscles of the back.

- **Anterior ramus**
 - (1) innervates the anterior and lateral muscles and skin of the trunk, extremities, and visceral organs.
- **Meningeal ramus**
 - (1) innervates the meninges and vertebral column.
- **Gray communicating rami**
 - (1) contain **unmyelinated** postganglionic sympathetic fibers.
 - (2) associated with *all* spinal nerves.
- **White communicating rami**
 - (1) contain **myelinated** preganglionic sympathetic fibers and myelinated GVA fibers (splanchnic nerves).
 - (2) found only in thoracolumbar segments of the spinal cord (T1–L2).

E. Spinal nerve innervation (Figure 6.4)

- One spinal nerve innervates the derivatives from one **somite** that includes the following:
 1. **Dermatome** (see Figure 6.4)
 - consists of a **cutaneous area** innervated by the fibers of one spinal nerve.

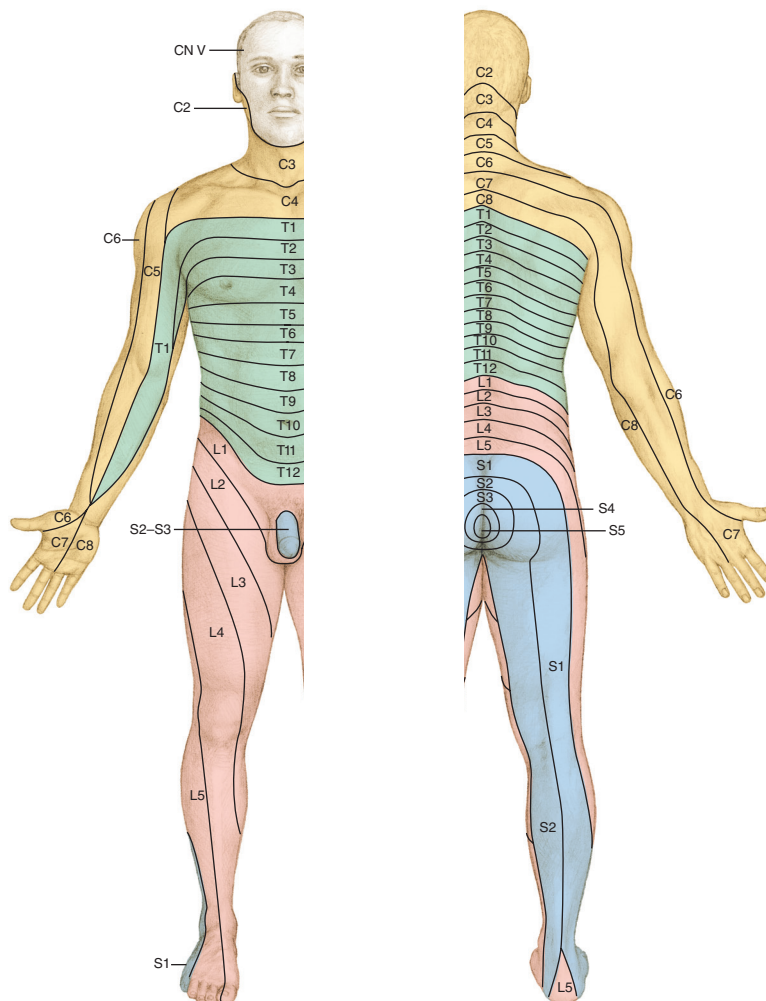


FIGURE 6.4. Cutaneous distribution of spinal nerves, the dermatomes. (Modified from Haymaker W, Woodhall B. *Peripheral Nerve Injuries*. 2nd ed. Philadelphia, PA: WB Saunders; 1952:32.)

2. Myotome

- consists of **muscles** innervated by the fibers of one spinal nerve.

3. Sclerotome

- consists of **bones and ligaments** innervated by the fibers of one spinal nerve.

F. Surface structures and sulci (Figure 6.5)

1. Anterior median fissure

- a deep anterior midline groove in which the anterior spinal artery is found superficially.

2. Anterior lateral sulcus

- a shallow groove from which the anterior rootlets emerge.

3. Posterior lateral sulcus

- a shallow groove into which the posterior rootlets enter.

4. Posterior intermediate sulcus

- a shallow groove that is continuous with the posterior intermediate septum.
- found between the posterior lateral and posterior median sulci but only rostral to T6.
- separates the fasciculus gracilis from the fasciculus cuneatus.

5. Posterior median sulcus

- a shallow posterior midline groove that is continuous with the posterior median septum.

III. INTERNAL MORPHOLOGY (SEE FIGURE 6.5)

- In transverse sections, the spinal cord consists of central gray matter and peripheral white matter.

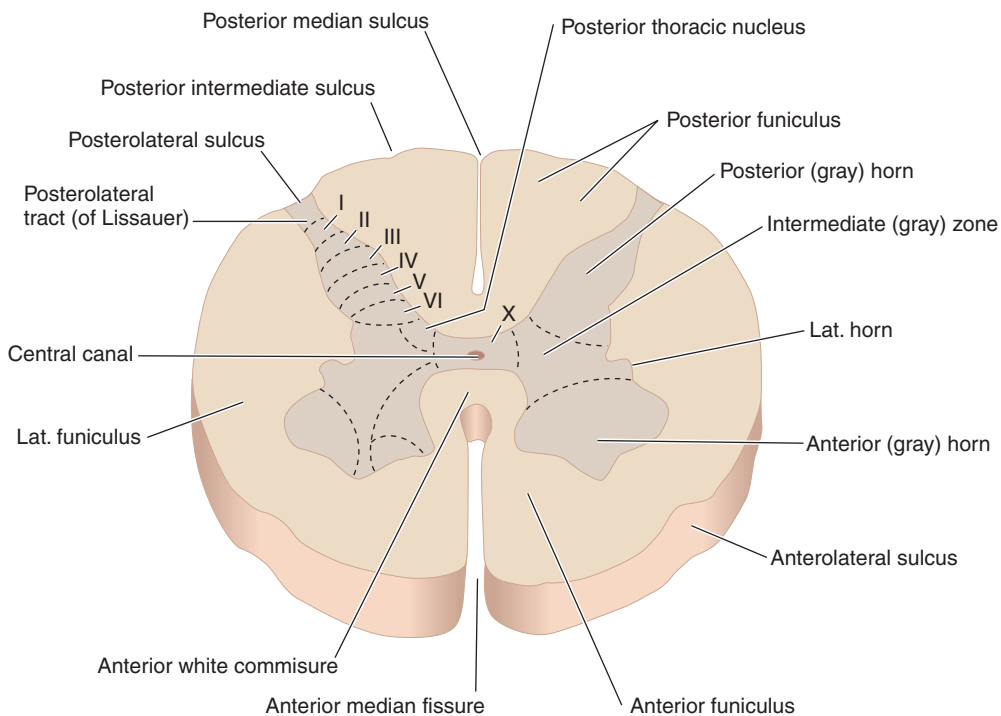


FIGURE 6.5. Topography of the spinal cord in transverse section: horns (columns), sulci, funiculi, and Rexed laminae. The lateral horn is found only at thoracolumbar cord levels (T1–L2). The posterior intermediate sulcus and septum are found only above T6.

A. Gray matter

- toward the center of the spinal cord.
- butterfly- or **H-shaped** that varies according to spinal cord level.
- contains a central canal.
- divided into cytoarchitectural areas called **Rexed laminae**, expressed with Roman numerals (see Figure 6.5).
- divided into three horns or cell columns on each side:
 1. **Posterior horn (column)**
 - receives and processes sensory input.
 - found at all levels.
 - includes the following nuclei:
 - a. **Posteromarginal nucleus (Rexed lamina I)**
 - found at all cord levels.
 - associated with light touch, pain, and temperature sensation.
 - origin of some fibers of anterolateral system.
 - b. **Substantia gelatinosa (Rexed lamina II)**
 - found at all cord levels.
 - homologous to the spinal trigeminal nucleus.
 - associated with light touch, pain, and temperature sensation.
 - origin of some fibers of anterolateral system.
 - c. **Nucleus proprius (Rexed laminae III and IV)**
 - found at all cord levels.
 - associated with light touch, pain, and temperature sensation.
 - origin of some fibers of anterolateral system.
 - d. **Posterior thoracic nucleus (also known as Nucleus dorsalis of Clarke) (Rexed lamina VII)**
 - found at the base of the posterior horn.
 - extends from (C8) T1 to L2.
 - homologous to the **accessory cuneate nucleus** of the medulla.
 - subserves unconscious proprioception from muscle spindles and Golgi tendon organs (GTOs).
 - the origin of the posterior spinocerebellar tract.
 2. **Lateral horn (column) (Rexed lamina VII)**
 - receives viscerosensory input.
 - found between the posterior and anterior horns.
 - extends from T1 to L2.
 - contains the **intermediolateral nucleus** (column), a visceromotor nucleus that extends from T1 to L2.
 - contains preganglionic sympathetic neurons (GVE).
 - contains, at T1–T2, the **cilio-spinal center of Budge** (sympathetic innervation of the eye).
 3. **Anterior horn (column) (Rexed laminae VII, VIII, and IX)**
 - contains predominantly motor nuclei.
 - found at all levels.
 - includes the following nuclei:
 - a. **Spinal border cells**
 - extend from L2 to S3.
 - subserve unconscious proprioception from GTOs and muscle spindles.
 - the origin of the anterior spinocerebellar tract.
 - b. **Sacral parasympathetic nucleus (Rexed lamina VII)**
 - extends from S2 to S4.
 - gives rise to preganglionic parasympathetic fibers that innervate the pelvic viscera via the pelvic splanchnic nerves.
 - c. **Somatic motor nuclei (Rexed lamina IX)**
 - found at all levels.
 - subdivided into medial and lateral groups that innervate axial and appendicular muscles, respectively.

d. Spinal accessory nucleus (Rexed lamina IX)

- extends from C1 to C6.
- gives rise to the **spinal accessory nerve** (CN IX).
- innervates the sternocleidomastoid and trapezius.

e. Phrenic nucleus (Rexed lamina IX)

- extends from C3 to C6.
- innervates the diaphragm.

B. White matter (see Figure 6.5)

- consists of bundles of myelinated fibers that surround the central gray matter.
- consists of ascending and descending fiber pathways called tracts.
- divided bilaterally by sulci into three major divisions.
 - 1. Posterior funiculus (posterior column)**
 - located between the posterior median sulcus and the posterior lateral sulcus.
 - is subdivided above T6 into two fasciculi:
 - a. Fasciculus gracilis**
 - located between the posterior median sulcus and the posterior intermediate sulcus and septum.
 - found at all cord levels.
 - b. Fasciculus cuneatus**
 - located between the posterior intermediate sulcus and septum and the posterior lateral sulcus.
 - found only at the upper thoracic and cervical cord levels (C1–T6).
 - 2. Lateral funiculus**
 - located between the posterior lateral and anterior lateral sulci.
 - 3. Anterior funiculus**
 - located between the anterior median fissure and the anterior lateral sulcus.
 - contains the **anterior white commissure**:
 - a.** located between the central canal and the anterior medial fissure.
 - b.** contains decussating spinothalamic fibers.

C. Characterization of spinal cord levels

- based on regional variation in the shape of the gray matter and the presence of the posterior intermediate sulci and septa.
 - 1. Cervical cord**
 - posterior intermediate sulci and septa are present.
 - anterior horns are massive from C3 to C8.
 - 2. Thoracic cord**
 - Posterior intermediate sulci and septa are present from T1 to T6.
 - The posterior thoracic nucleus is present at all thoracic levels but is most prominent at T11 and T12.
 - Lateral horns are present at all thoracic levels.
 - Posterior and anterior horns are typically slender and **H-shaped**.
 - 3. Lumbar cord**
 - The posterior thoracic nucleus is very prominent at L1 and L2.
 - Contains massive anterior and posterior horns from L2 to L5; the substantia gelatinosa is greatly enlarged.
 - The lumbar section is difficult to distinguish from the upper sacral segments.
 - The lateral horn is prominent only at L1.
 - 4. Sacral cord**
 - contains massive anterior and posterior horns; the substantia gelatinosa is greatly enlarged.
 - greatly reduced in diameter from S3 to S5.
 - 5. Coccygeal segment**
 - contains posterior horns that are more voluminous than the anterior horns.
 - has a greatly reduced diameter.

IV. MYOTATIC REFLEX (SEE FIGURE 6.3)

- a monosynaptic and ipsilateral muscle stretch reflex (MSR).

A. Afferent limb

- includes a muscle spindle (receptor) and a spinal ganglion neuron and its Ia fiber.

B. Efferent limb

- includes an anterior horn motor neuron that innervates striated muscle (effector).

Review Test

1. Which of the following reflexes is monosynaptic?

- (A) Achilles
- (B) Babinski
- (C) Corneal
- (D) Extensor plantar
- (E) Pupillary light

2. The spinal cord of a newborn baby terminates at:

- (A) VL1.
- (B) VL3.
- (C) VS1.
- (D) VS3.
- (E) VS5.

3. Which spinal nerve rami contain unmyelinated postganglionic sympathetic nerve fibers?

- (A) Anterior primary
- (B) Gray communicating
- (C) Meningeal
- (D) Posterior primary
- (E) White communicating

4. The efferent limb of a myotatic reflex includes a(n):

- (A) anterior horn motor neuron.
- (B) lateral horn visceromotor nucleus.
- (C) muscle spindle.
- (D) preganglionic sympathetic neuron.
- (E) spinal ganglion neuron.

Questions 5 to 9

The response options for the items 5 to 9 are the same. Select one answer for each item in the set.

- (A) Cervical
- (B) Coccygeal
- (C) Lumbar
- (D) Inferior thoracic
- (E) Sacral
- (F) Superior thoracic

Match each characteristic below with the spinal cord level it best describes.

5. Contains preganglionic parasympathetic neurons

6. Contains the brachial plexus

7. Has a ciliospinal center (of Budge)

8. Contains the spinal accessory nucleus (CN XI)

9. Contains the phrenic nucleus

Answers and Explanations

1–A. The Achilles reflex, or ankle jerk reflex, is a myotatic monosynaptic reflex that is mediated by cord segment S1.

2–B. In the newborn, the spinal cord ends at the level of the third lumbar vertebra (VL3). In the adult, the spinal cord ends at the lower border of the first lumbar vertebra (VL1), and the dural sac ends at the level of the second sacral vertebra (VS2).

3–A. Gray communicating rami contain unmyelinated preganglionic sympathetic fibers, whereas white communicating rami contain myelinated preganglionic sympathetic fibers and myelinated GVA fibers. The meningeal ramus innervates the meninges and vertebral column; the posterior primary ramus innervates the skin and muscles of the back; and the anterior primary ramus innervates the anterolateral muscles and skin of the trunk, extremities, and visceral.

4–A. The myotatic reflex is a monosynaptic and ipsilateral MSR. The efferent limb consists of the axon of an anterior horn alpha motor neuron that innervates striated muscle fibers (effector); the afferent limb consists of a muscle spindle (receptor) and an Ia fiber (axon) of a spinal ganglion neuron. The quadriceps (patellar) and triceps surae (ankle) MSRs are myotatic reflexes.

5–E. The sacral cord contains the sacral parasympathetic nucleus (S2–S4), which gives rise to preganglionic fibers that synapse in the intramural ganglia of the pelvic viscera.

6–A. The cervical cord contains massive anterior horns, which give rise to the brachial plexus (C5–C8).

7–F. The ciliospinal center (of Budge) is found in the lateral horn at T1. This sympathetic nucleus innervates the dilator pupillae and the nonstriated superior and inferior tarsal muscles.

8–A. The spinal accessory nucleus extends from C1 to C6 and gives rise to the spinal accessory nerve; it innervates the sternocleidomastoid and trapezius muscles.

9–A. The phrenic nucleus extends from C3 to C6 and innervates the diaphragm.

Tracts of the Spinal Cord

Objectives

- List the three major ascending spinal cord pathways and describe the location of their primary, secondary, and tertiary neurons and the modalities each is concerned with.
- List the major descending spinal cord pathways and describe the function of each.
- Describe somatotopic organization and list the spinal cord tracts that possess somatotopic organization and describe how the fibers are organized in each.

I. ASCENDING TRACTS

- represent functional pathways that convey sensory information from the periphery to higher levels.
- usually consist of a chain of three neurons: first-, second-, and third-order neurons. The first-order neuron is always in the spinal ganglion.
- mostly decussate before reaching their final destination.
- give rise to collateral branches that serve in local spinal reflex arcs.

A. Posterior column–medial lemniscus pathway (Figure 7.1)

- mediates fine touch, conscious proprioception, and vibratory sense.
 - somato-topically organized.
 - receives input from Pacinian and Meissner's corpuscles, joint receptors, muscle spindles, and Golgi tendon organs (GTOs).
1. **First-order neurons**
 - located in spinal ganglia at all levels.
 - give rise to the **fasciculus gracilis** from the lower extremity.
 - give rise to the **fasciculus cuneatus** from the upper extremity.
 - give rise to axons that ascend in the posterior columns and terminate in the gracile and cuneate nuclei of the medulla.
 2. **Second-order neurons**
 - located in the gracile and cuneate nuclei of the caudal medulla.
 - give rise to axons, **internal arcuate fibers** that decussate and form a compact fiber bundle, the **medial lemniscus**. The medial lemniscus ascends through the contralateral brainstem to terminate in the ventral posterolateral (**VPL**) nucleus of the thalamus.
 3. **Third-order neurons**
 - located in the VPL nucleus of the thalamus.
 - project via the posterior limb of the internal capsule to the postcentral gyrus, the **somato-sensory cortex** (areas 3, 1, and 2).

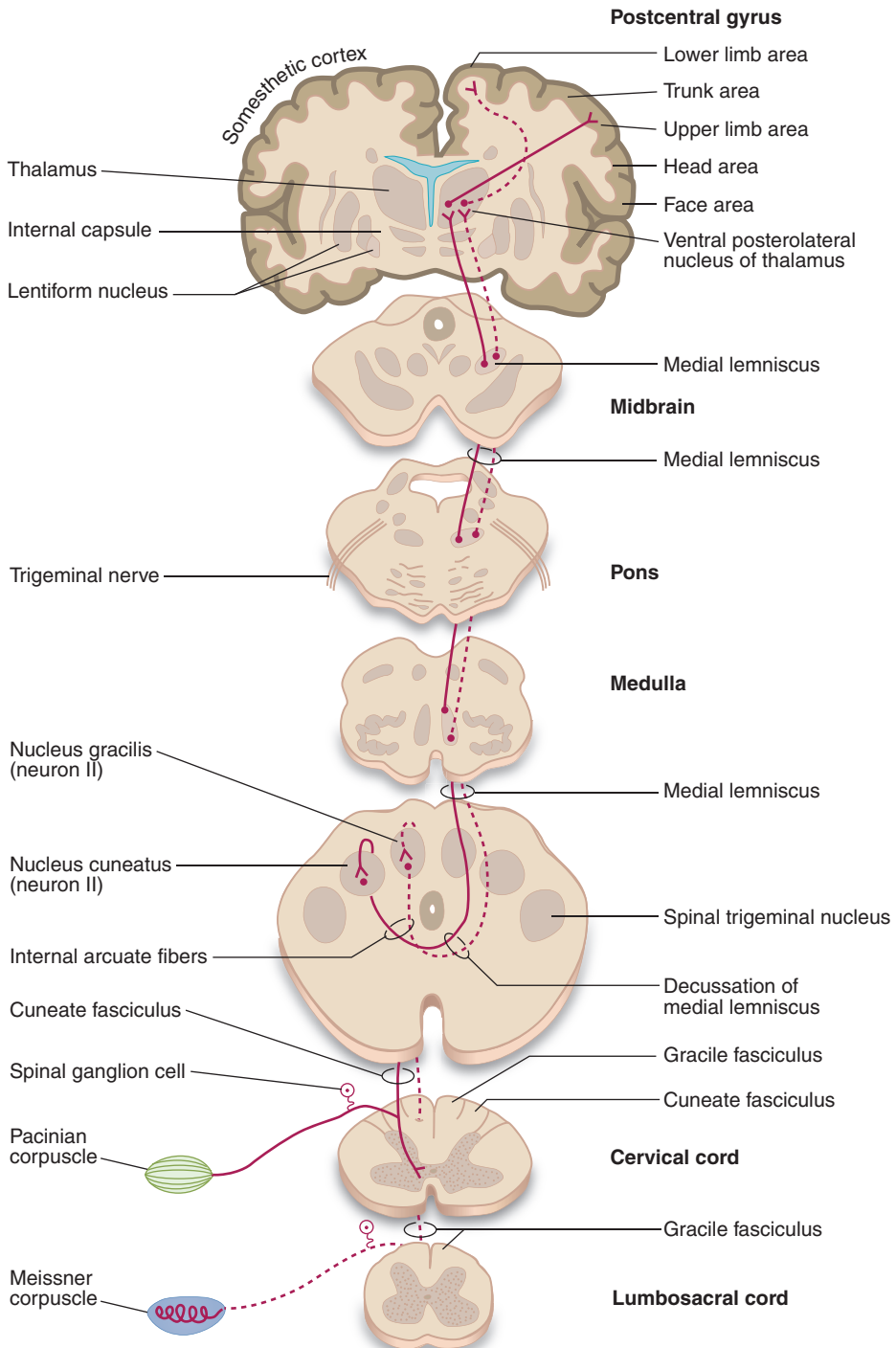


FIGURE 7.1. The posterior column–medial lemniscus pathway. (Adapted with permission from Carpenter MB, Sutin J. *Human Neuroanatomy*. 8th ed. Baltimore, MD: Williams & Wilkins; 1983:266.)

B. Anterolateral system

1. Anterior spinothalamic tract

- concerned with **crude touch**, the sensation produced by stroking glabrous skin with a wisp of cotton.
- receives input from free nerve endings and from Merkel tactile disks.
 - First-order neurons**
 - found in spinal ganglia at all levels.
 - project axons into the medial root entry zone to second-order neurons in the posterior horn.
 - Second-order neurons**
 - located in the **posterior horn**.
 - give rise to axons that decussate in the anterior white commissure and ascend in the contralateral anterior funiculus.
 - terminate in the VPL nucleus of the thalamus.
 - Third-order neurons**
 - found in the **VPL nucleus** of the thalamus.
 - project via the posterior limb of the internal capsule and corona radiata to the postcentral gyrus (areas 3, 1, and 2).

2. Lateral spinothalamic tract (Figure 7.2)

- mediates itch, pain, and temperature sensation.
- receives input from free nerve endings and thermal receptors.
- receives input from A- δ and C fibers (i.e., fast- and slow-conducting pain fibers).
- somatotopically organized with sacral fibers posterolaterally and cervical fibers anterolaterally.
 - First-order neurons**
 - found in spinal ganglia at all levels.
 - project axons via the **posterolateral tract (of Lissauer)** to second-order neurons in the posterior horn.
 - synapse with second-order neurons in the posterior horn.
 - Second-order neurons**
 - found in the posterior horn.
 - give rise to axons that decussate in the **anterior white commissure** and ascend in the anterior half of the lateral funiculus.
 - project collaterals to the reticular formation.
 - terminate contralaterally in the VPL nucleus and bilaterally in the intralaminar nuclei of the thalamus.
 - Third-order neurons**
 - found in the VPL nucleus and in the intralaminar nuclei.
 - VPL neurons**
 - project via the posterior limb of the internal capsule to the somesthetic cortex of the postcentral gyrus (areas 3, 1, and 2).
 - Intralaminar neurons**
 - project to the caudatoputamen and to the frontal and parietal cortex.

C. Cerebellar

1. Posterior spinocerebellar tract (Figure 7.3)

- transmits unconscious proprioceptive information to the cerebellum.
- receives input from muscle spindles, GTOs, and pressure receptors.
- involved in fine coordination of posture and the movement of individual muscles of the lower limb.
- an uncrossed tract.
 - First-order neurons**
 - found in the spinal ganglia from C8 to S3.
 - project via the medial root entry zone to synapse in the **posterior thoracic nucleus**.

Some authors refer to the spinothalamic tracts as the anterolateral system. The anterolateral system (tract) contains the anterior and lateral spinothalamic tracts (amongst others).

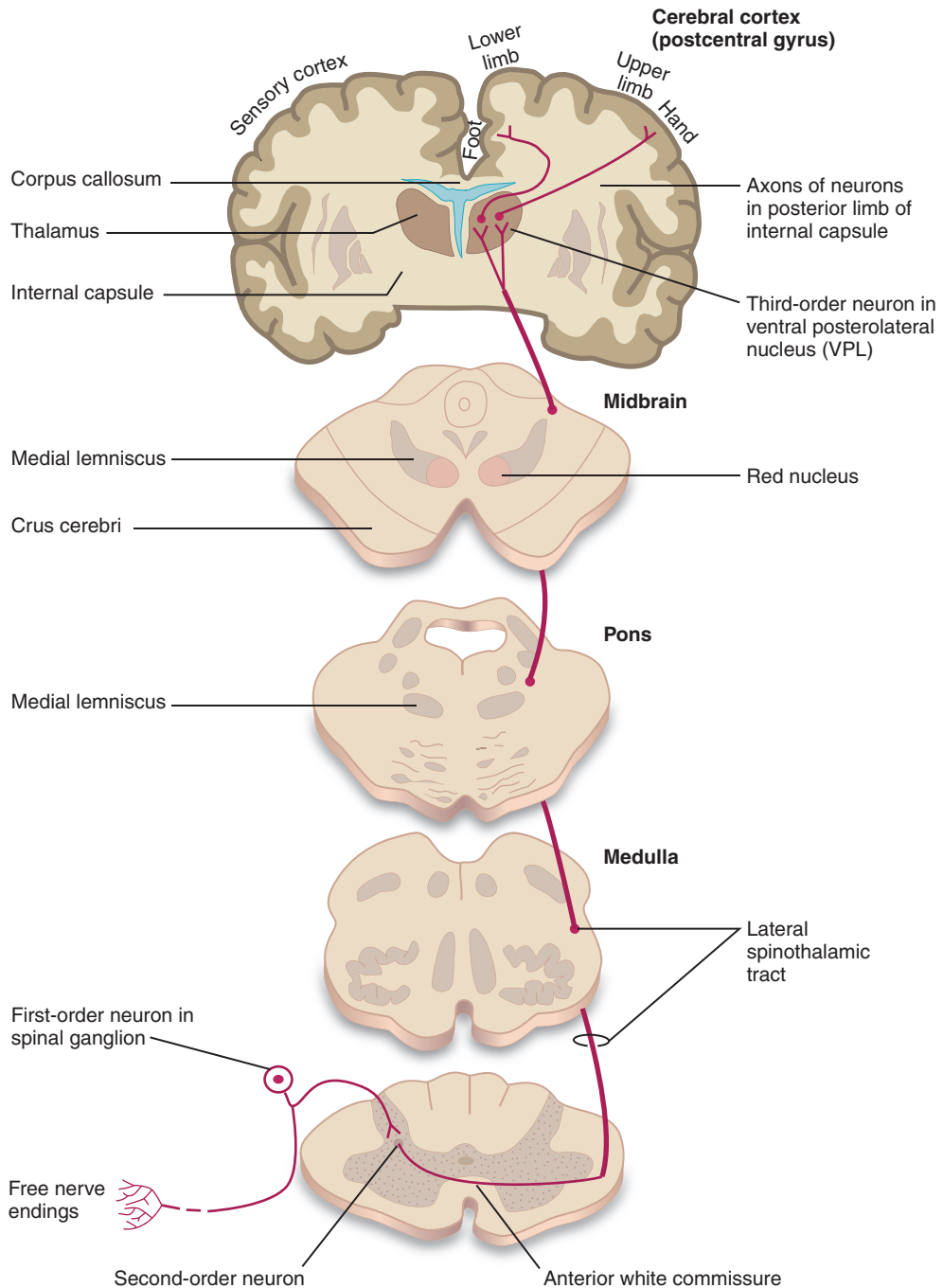


FIGURE 7.2. The lateral spinothalamic tract. Numerous collaterals are distributed to the brainstem reticular formation. (Adapted with permission from Carpenter MB, Sutin J. *Human Neuroanatomy*. 8th ed. Baltimore, MD: Williams & Wilkins; 1983:274.)

b. Second-order neurons

- found in the posterior thoracic nucleus (C8–L3).
- give rise to axons that ascend in the lateral funiculus and reach the cerebellum via the inferior cerebellar peduncle.
- contain axons that terminate ipsilaterally as mossy fibers in the cortex of the rostral and caudal cerebellar vermis.

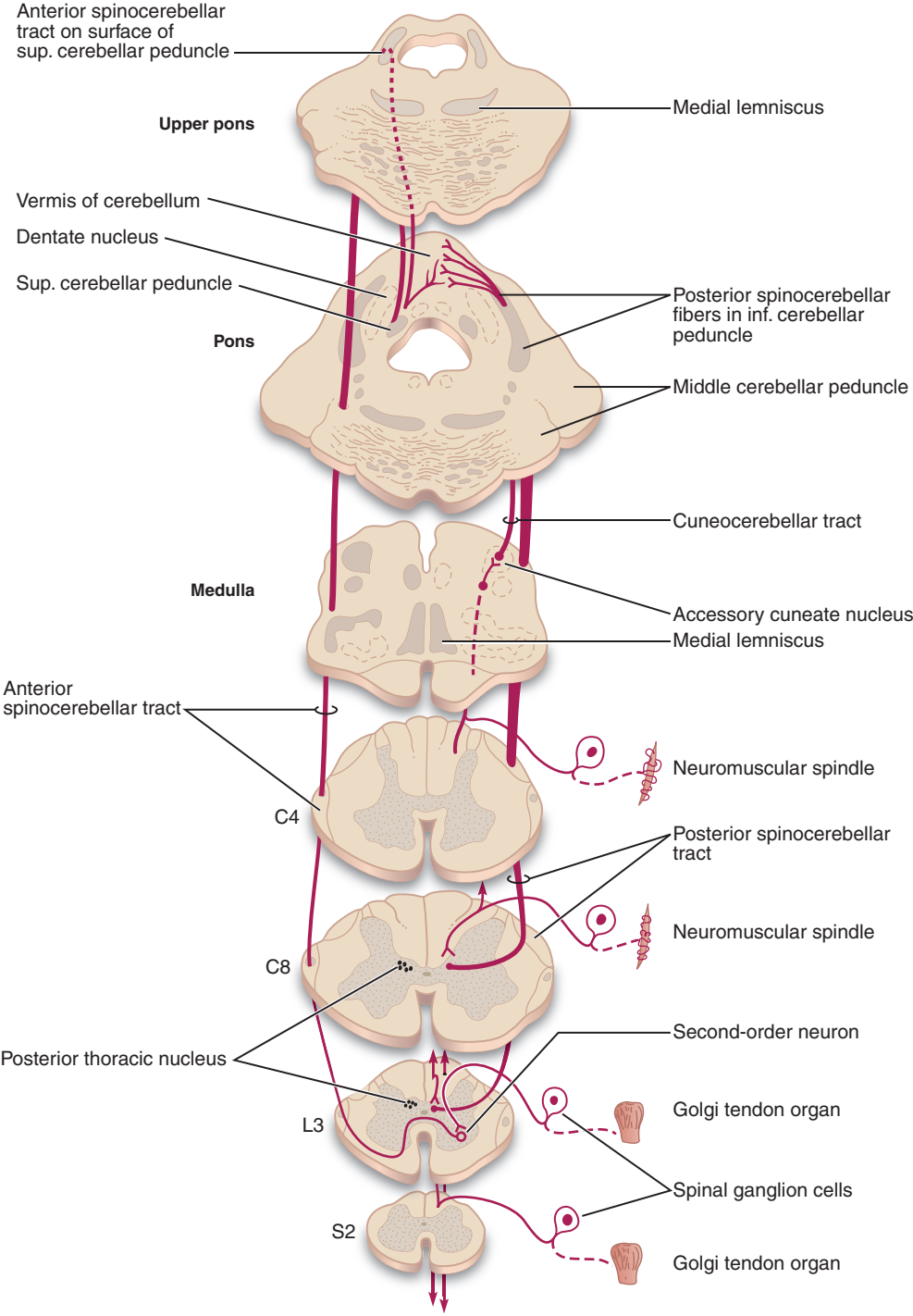


FIGURE 7.3. Schematic diagram of the anterior and posterior spinocerebellar tracts and the cuneocerebellar tract. (Adapted with permission from Carpenter MB, Sutin J. *Human Neuroanatomy*. 8th ed. Baltimore, MD: Williams & Wilkins; 1983:277.)

2. Anterior spinocerebellar tract (see Figure 7.3)

- transmits unconscious proprioceptive information to the cerebellum.
- concerned with coordinated movement and posture of the entire lower extremity.
- receives input from muscle spindles, GTOs, and pressure receptors.
- a crossed tract.
 - First-order neurons**
 - found in the spinal ganglia from L1 to S2.
 - synapse on **spinal border cells**.
 - Second-order neurons**
 - spinal border cells found in the anterior horns (L1–S2).
 - give rise to axons that decussate in the anterior white commissure and ascend lateral to the lateral spinothalamic tract in the lateral funiculus.
 - give rise to axons that enter the cerebellum via the **superior cerebellar peduncle** and terminate contralaterally as mossy fibers in the cortex of the rostral cerebellar vermis.

3. Cuneocerebellar tract (see Figure 7.3)

- the upper-extremity equivalent of the posterior spinocerebellar tract.
 - First-order neurons**
 - found in the spinal ganglia from C2 to T7.
 - project their axons via the fasciculus cuneatus to the caudal medulla, where they synapse in the **accessory cuneate nucleus**—a homolog of the posterior thoracic nucleus.
 - Second-order neurons**
 - located in the accessory cuneate nucleus of the medulla.
 - give rise to axons that project ipsilaterally to the cerebellum via the **inferior cerebellar peduncle**.

II. DESCENDING TRACTS (FIGURES 7.4 AND 7.5)

- concerned with somatic and visceral motor activities.
- have their cells of origin in the cerebral cortex or in the brainstem.

A. Lateral corticospinal (pyramidal) tract (see Figure 7.4)

- not fully myelinated until the end of the second year.
- concerned with **volitional skilled motor activity**, primarily of the digits of the upper limb.
- receives input from the **paracentral lobule**, a medial continuation of the motor and sensory cortices, and subserves the muscles of the contralateral leg and foot.
- arises from lamina V of the cerebral cortex from three cortical areas: the **premotor cortex** (area 6); the **precentral motor cortex** (area 4); and the **postcentral sensory cortex** (areas 3, 1, and 2).
- terminates via interneurons on anterior horn motor neurons and sensory neurons of the posterior horn.
- the axons of the **giant cells of Betz** contribute large diameter fibers to the tract.
- passes through the posterior limb of the internal capsule.
- passes through the middle three-fifths of the **crus cerebri** (basis pedunculi) of the midbrain through the base of the pons.
- constitutes the pyramid of the medulla.
- undergoes a 90% decussation in the caudal medulla.
- lies in the posterior quadrant of the lateral funiculus of the spinal cord.
- transection results in spastic hemiparesis with positive Babinski sign.

B. Anterior corticospinal tract (see Figure 7.4)

- a small uncrossed tract that decussates at spinal cord levels in the anterior white commissure.
- concerned with the control of axial muscles.

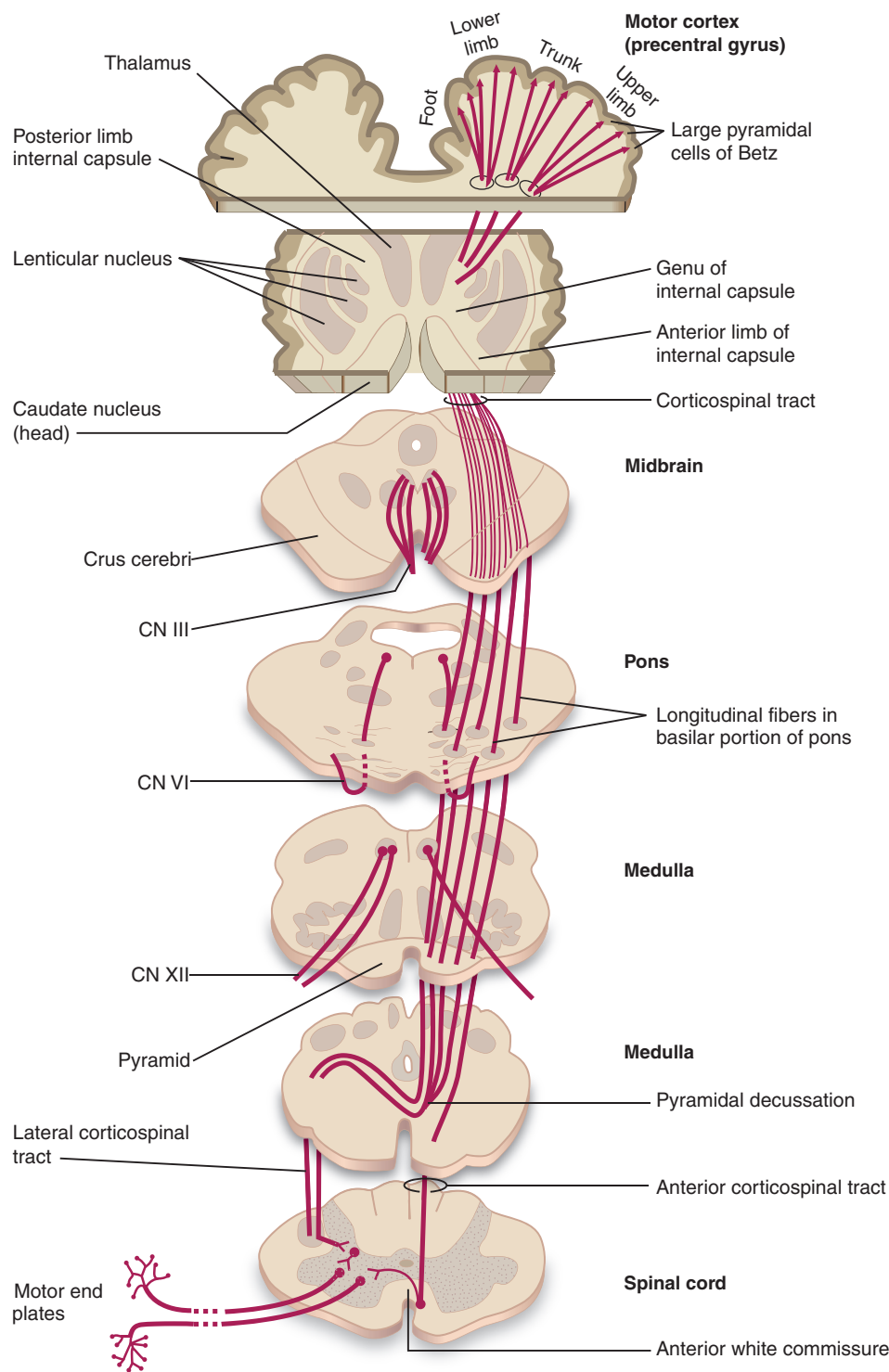


FIGURE 7.4. The lateral and anterior corticospinal tracts (the pyramidal tracts). (Adapted with permission from Carpenter MB, Sutin J. *Human Neuroanatomy*. 8th ed. Baltimore, MD: Williams & Wilkins; 1983:285.)

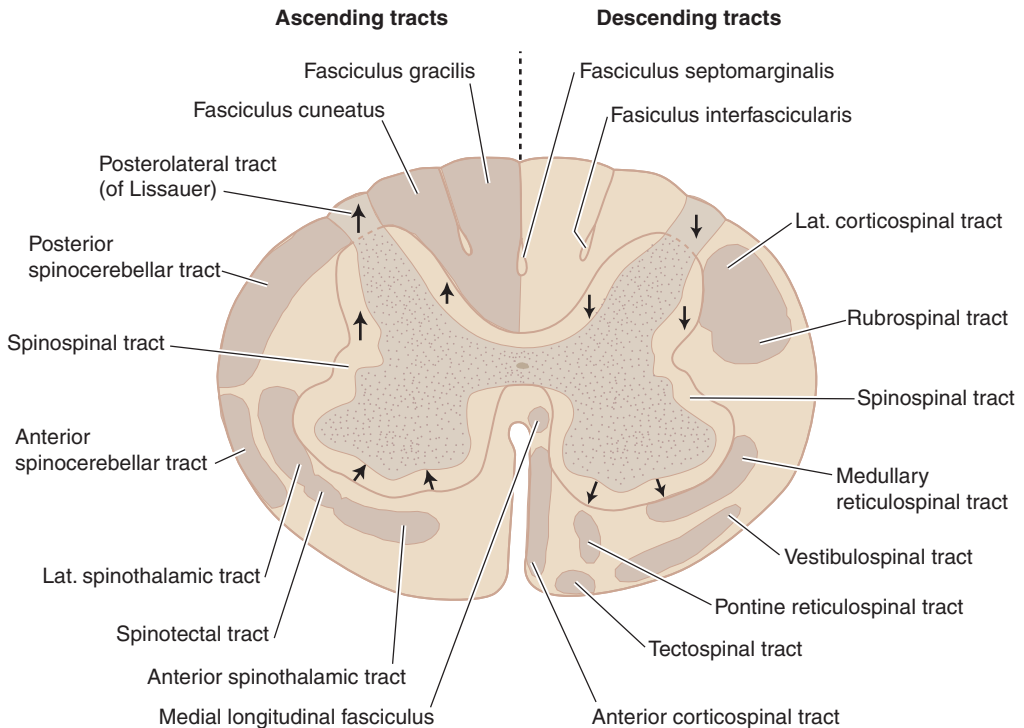


FIGURE 7.5. Schematic diagram of the major ascending and descending pathways of the spinal cord. (Adapted with permission from Carpenter MB. *Core Text of Neuroanatomy*. 3rd. ed. Baltimore, MD: Williams & Wilkins; 1985:97.)

C. Rubrospinal tract (see Figure 7.5)

- arises in the contralateral red nucleus of the midbrain.
- plays a role in the control of flexor tone.
- anterior to the lateral corticospinal tract.

D. Vestibulospinal tract (see Figure 7.5)

- arises from the giant cells of Deiters in the ipsilateral lateral vestibular nucleus.
- plays a role in the control of extensor tone.
- located in the anterior funiculus.

E. Descending autonomic tracts (Figure 7.6)

- project to sympathetic (T1–L2) and parasympathetic (S2–S4) centers in the spinal cord.
- innervate the ciliospinal center (T1–T2), a pupillary center; interruption of this hypothalamospinal tract (found in the posterior quadrant of the lateral funiculus) results in **Horner syndrome**.

III. INTEGRATIVE PATHWAYS

A. Ascending pain pathways

- pain ascends in all three funiculi.
- tracts that carry pain include the lateral spinothalamic and the following:
 1. spinoreticular—ascend as part of the anterolateral system, originate in the contralateral posterior horn, and terminate diffusely throughout the reticular formation;
 2. spinomesencephalic—ascend as part of the anterolateral system, originate in the contralateral posterior horn, and terminate on multiple nuclei of the midbrain;

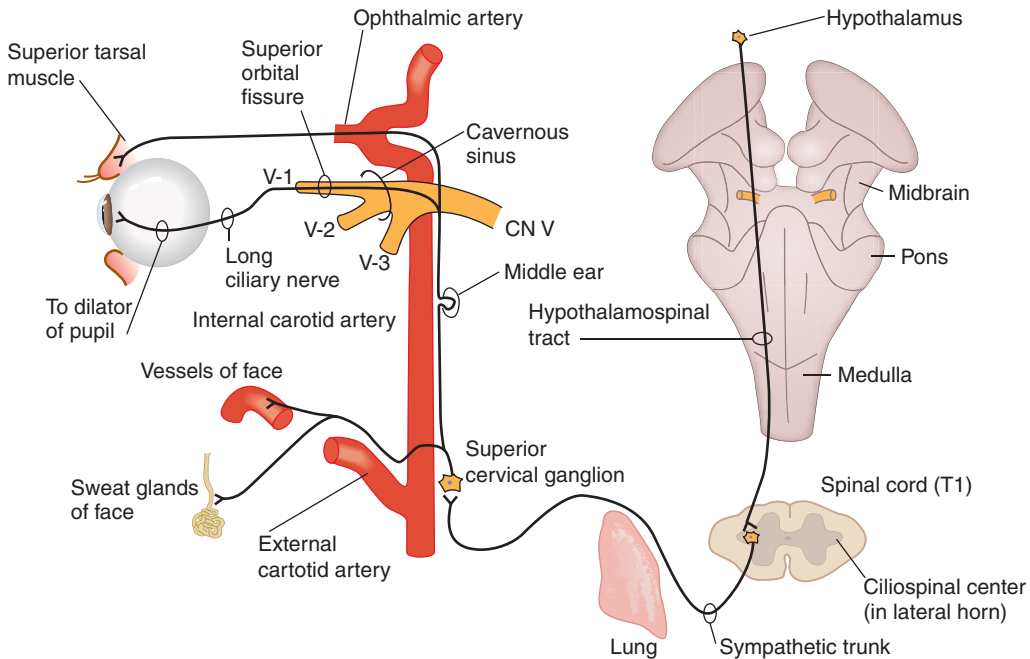


FIGURE 7.6. The oculosympathetic pathway. Hypothalamic fibers project to the ipsilateral ciliospinal center of the intermediolateral cell column at T1. The ciliospinal center projects preganglionic sympathetic fibers to the superior cervical ganglion. The superior cervical ganglion projects perivascular postganglionic sympathetic fibers through the tympanic cavity, cavernous sinus, and superior orbital fissure to the dilator pupillae. Interruption of this pathway at any level results in Horner syndrome. CN = cranial nerve. (Modified from Fix, JD. *High-Yield Neuroanatomy*. 3rd ed. Philadelphia, PA: Lippincott Williams & Wilkins; 2005:67.)

3. spinocervical—travel in the posterior aspect of the lateral funiculus, originate in the nucleus proprius, and terminate in the cervical spinal cord;
4. postsynaptic fibers in the posterior columns

B. Posterolateral tract (of Lissauer)

- (predominantly) white matter tract capping the posterior horn.
- mainly pain and temperature fibers ascending or descending a few spinal cord segments before synapsing.
- serves to provide central overlap of pain and temperature.

C. Fasciculus proprius

- white matter tract surrounding the margins of gray matter at all spinal cord levels.
- contains fibers ascending or descending multiple levels, which then re-enter the gray matter.
- serves as an intersegmental connection between adjacent cord levels.

IV. CLINICAL CORRELATIONS

A. Upper motor neurons (UMNs)

- cortical neurons that give rise to corticobulbar or corticospinal tracts.
- found in brainstem nuclei that influence lower motor neurons (LMNs) (e.g., lateral vestibular nucleus, red nucleus).
- terminate directly or via interneurons on LMNs.

B. UMN lesions

- caused by damage to the neurons (or their axons) that innervate LMNs.
 1. **Acute-stage lesions**
 - result in transient spinal shock, including
 - a. **Flaccid paralysis**
 - b. **Areflexia**
 - c. **Hypotonia**
 2. **Chronic-stage lesions**
 - result in
 - a. **Spastic paresis**
 - b. **Hypertonia**
 - occurs with increased tone in antigravity muscles (i.e., flexors of arms and extensors of legs).
 - c. **Reduction or loss of superficial abdominal and cremasteric reflexes**
 - d. **Extensor toe response (Babinski sign)**
 - e. **Clonus**
 - a repetitive and sustained MSR (e.g., ankle clonus).

C. LMNs

- neurons that directly innervate skeletal muscles.
- found in the anterior horns of the spinal cord.
- found in the motor nuclei of CN III, CN IV to CN VII, and CN IX to CN XII.

D. LMN lesions

- result from damage to motor neurons or their peripheral axons.
- result in
 1. **Flaccid paralysis**
 2. **Areflexia**
 3. **Muscle atrophy**
 4. **Fasciculations and fibrillations**

Review Test

1. The ability to recognize an unseen familiar object placed in the hand depends on the integrity of ____.

- (A) Posterior column
- (B) Posterior spinocerebellar tract
- (C) Spino-olivary tract
- (D) Spinothalamic tract
- (E) Spinothalamic tract

2. The spinal tract involved with the control of trunk muscles is:

- (A) anterior corticospinal.
- (B) anterior spinocerebellar.
- (C) cuneocerebellar.
- (D) lateral corticospinal.
- (E) vestibulospinal.

3. The sensation produced by a wisp of cotton on one's fingertip is mediated by the:

- (A) anterior corticospinal tract.
- (B) anterior spinocerebellar tract.
- (C) anterior spinothalamic tract.
- (D) cuneocerebellar tract.
- (E) posterior column–medial lemniscus pathway.

4. First-order neurons of the anterior spinocerebellar tract:

- (A) are found in spinal ganglia at all levels.
- (B) give rise to the fasciculus cuneatus.
- (C) project axons into the medial root entry zone.
- (D) project axons via the posterolateral tract (of Lissauer).
- (E) provide the afferent limb for muscle stretch reflexes.

5. Acute-stage upper motor neuron lesions result in:

- (A) hypertonia.
- (B) extensor toe response.
- (C) clonus.
- (D) flaccid paralysis.
- (E) spastic paresis.

Questions 6 to 10

The response options for items 6 to 10 are the same. Select one answer for each item in the set.

- (A) Cuneocerebellar tract
- (B) Cuneate fasciculus
- (C) Lateral corticospinal tract
- (D) Lateral spinothalamic tract
- (E) Posterior spinocerebellar tract
- (F) Posterolateral tract
- (G) Vestibulospinal tract

Match each statement below with the appropriate spinal cord tract.

6. Contains axons from the giant cells of Deiters

7. Is the upper limb equivalent of a tract that arises from the cells of the dorsal nucleus (of Clarke)

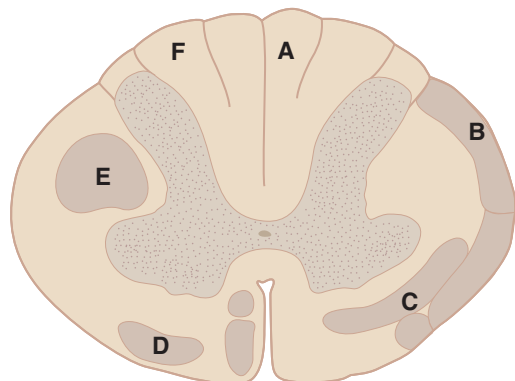
8. Conveys nociceptive input from the contralateral side of the body

9. Contains axons from the giant cells of Betz

10. Contains ipsilateral pain fibers that have their second-order neurons in the posterior horn

Questions 11 to 18

Match the description of a spinal cord tract in items 11 to 18 with the appropriate lettered structure shown in the figure.



- 11.** Projects to the cerebellum via the inferior cerebellar peduncle
- 12.** Mediates pain and temperature sensation
- 13.** Cells of origin are found in the precentral gyrus
- 14.** Mediates two-point tactile discrimination from the hand
- 15.** Myelination is not fully achieved until the end of the second year
- 16.** Transection results in spasticity
- 17.** Plays a role in regulating extensor tone
- 18.** Transmits vibration sensation from the ankle

Answers and Explanations

- 1–A.** The ability to recognize the form and texture of an unseen familiar object is called stereognosis. This is an important function of the posterior column–medial lemniscus system.
- 2–A.** The anterior corticospinal tract is concerned with the control of axial muscles, including the muscles of the trunk and head.
- 3–C.** The anterior spinothalamic tract is concerned with light touch, the sensation produced by stroking glabrous skin with a wisp of cotton.
- 4–E.** First-order neurons of the anterior spinocerebellar tract provide the afferent limb for muscle stretch reflexes. They are found in the spinal ganglia from L1 to S2 and synapse on spinal border cells. First-order neurons of the anterior spinothalamic and posterior spinocerebellar tracts project axons into the medial root entry zone; first-order neurons of the posterior column–medial lemniscus pathway give rise to the fasciculus gracilis and cuneatus; and first-order neurons of the lateral spinothalamic tract project axons via the posterolateral tract (of Lissauer).
- 5–D.** Acute-stage upper motor neuron lesions result in transient spinal shock, which includes flaccid paralysis, areflexia, and hypotonia. Chronic-stage lesions result in spastic paresis, hypertonia, reduction or loss of superficial abdominal and cremasteric reflexes and extensor toe response, and clonus.
- 6–G.** The vestibulospinal tract arises from the giant cells of Deiters found in the ipsilateral lateral vestibular nucleus of the pons. The vestibulospinal tract facilitates extensor muscle tone.
- 7–A.** The cuneocerebellar tract is the upper extremity equivalent of the posterior spinocerebellar tract, which arises from the cells of the dorsal nucleus (of Clarke). The cuneocerebellar tract arises from cells of the accessory cuneate nucleus, a homolog of the dorsal nucleus.
- 8–D.** The anterolateral system conveys nociceptive input from the contralateral side of the body.
- 9–C.** The lateral corticospinal tract contains axons from the giant cells of Betz. The giant pyramidal cells of Betz are found in the precentral gyrus and in the anterior paracentral lobule.
- 10–F.** The posterolateral tract (of Lissauer) contains ipsilateral pain fibers that have their second-order neurons in the posterior horn.
- 11–B.** The posterior spinocerebellar tract projects unconscious proprioceptive information (muscle spindles and GTOs) to the cerebellum via the inferior cerebellar peduncle.
- 12–C.** The anterolateral tract lies between the anterior spinocerebellar tract and the anterior horn. It mediates pain and temperature sensation.
- 13–E.** The lateral corticospinal tract has its cells of origin in the premotor, motor, and sensory cortices. The precentral gyrus and the anterior paracentral lobule are motor cortices and contain the motor homunculus. The lateral corticospinal gives rise to one-third of the fibers of the corticospinal (pyramidal) tract.
- 14–F.** The fasciculus cuneatus mediates two-point tactile discrimination from the hand.
- 15–E.** The corticospinal (pyramidal) tracts are not fully myelinated until the end of the second year. For this reason, the Babinski sign may be elicited in young children.
- 16–E.** Transection of the lateral corticospinal tract results in spastic paresis (exaggerated MSRs and clonus).
- 17–D.** The vestibulospinal (lateral) tract, found anterior to the anterior horn, plays a role in regulating extensor tone.
- 18–A.** The fasciculus gracilis transmits vibratory sensation (pallesthesia) from the lower extremities.

Objectives

- Describe the difference between upper and lower motor neuron lesions and include examples of each.
- Give examples of sensory versus motor pathway lesions, peripheral nervous system lesions, and combined lesions.

I. LOWER MOTOR NEURON LESIONS (FIGURE 8.1A)

- result from damage to motor neurons of the anterior horns or motor neurons of the cranial nerve nuclei.
- result from interruption of the final common pathway connecting the neuron via its axon with the muscle fibers it innervates (the motor unit).

A. Neurologic deficits resulting from lower motor neuron (LMN) lesions

1. **Flaccid paralysis**
2. **Muscle atrophy (amyotrophy)**
3. **Hypotonia**
4. **Areflexia**
 - consists of loss of muscle stretch reflexes (MSRs) (knee and ankle jerks) and loss of superficial reflexes (abdominal and cremasteric reflexes).
5. **Fasciculations** (visible muscle twitches)
6. **Fibrillations** (on electromyogram)

B. Diseases of LMNs (see Figure 8.1A)

1. **Poliomyelitis**
 - an acute inflammatory viral infection affecting the LMNs caused by an enterovirus.
 - results in a flaccid paralysis.
2. **Progressive infantile muscular atrophy (Werdnig–Hoffmann disease)**
 - a hereditary degenerative disease of infants that affects LMNs.
3. **Kugelberg–Wielander disease** (juvenile hereditary LMN disease)
 - appears at 3–20 years of age.
 - affects girdle muscles first and then distal muscles.

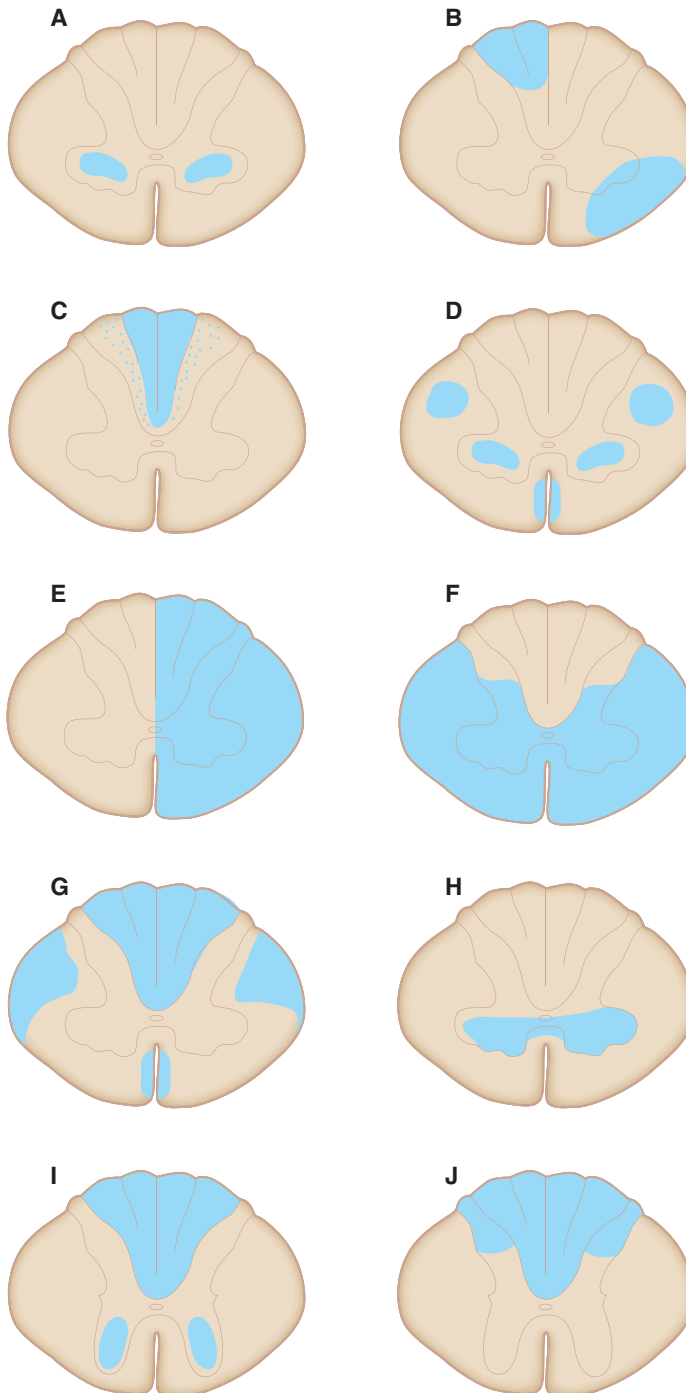


FIGURE 8.1. Lesions of the spinal cord: **(A)** poliomyelitis and progressive infantile muscular atrophy (Werdnig–Hoffmann disease); **(B)** multiple sclerosis; **(C)** posterior column disease (tabes dorsalis); **(D)** amyotrophic lateral sclerosis; **(E)** hemisection of the spinal cord (Brown–Séquard syndrome); **(F)** complete anterior spinal artery occlusion of the spinal cord; **(G)** subacute combined degeneration (vitamin B₁₂ neuropathy); **(H)** syringomyelia; **(I)** Charcot–Marie–Tooth disease (hereditary motor–sensory neuropathy type 1); and **(J)** complete posterior spinal artery occlusion. (Modified from Fix JD. *High-Yield Neuroanatomy*. 3rd ed. Philadelphia, PA: Lippincott Williams & Wilkins; 2005:70, with permission.)

II. UPPER MOTOR NEURON LESIONS (UMNs)

- lesions of the corticospinal and corticobulbar tracts are called **pyramidal tract lesions**.
- may occur at all levels of the neuraxis from the cerebral cortex to the spinal cord.
- When rostral to the pyramidal decussation, they result in deficits below the lesion, on the contralateral side.
- When caudal to the pyramidal decussation, they result in deficits below the lesion, on the ipsilateral side.

A. Lateral corticospinal tract lesion

- results in the following ipsilateral motor deficits found below the lesion:
 1. **Spastic hemiparesis with muscle weakness**
 2. **Hyperreflexia (exaggerated MSRs)**
 3. **Clasp-knife spasticity**
 - When a joint is moved briskly, resistance occurs initially and then fades (like the opening of a pocketknife).
 4. **Loss of superficial (abdominal and cremasteric) reflexes**
 5. **Clonus**
 - rhythmic contractions of muscles in response to sudden, passive movements (wrist, patellar, or ankle clonus).
 6. **Babinski sign**
 - plantar reflex response that is extensor (dorsiflexion of big toe).

B. Anterior corticospinal tract lesion

- results in **mild contralateral motor deficit**. Anterior corticospinal tract fibers decussate at spinal levels via the anterior white commissure.

C. Hereditary spastic paraplegia or diplegia

- caused by bilateral degeneration of the corticospinal tracts.
- gradual development of spastic weakness of the lower limbs with increased difficulty in walking.

III. SENSORY PATHWAY LESIONS

A. Posterior column syndrome (see Figure 8.1C)

- includes the fasciculi gracilis (T6–S5) and cuneatus (C2–T6) and the posterior roots.
- seen in subacute combined degeneration (vitamin B₁₂ neuropathy).
- seen in neurosyphilis as **tabes dorsalis** and in nonsyphilitic sensory neuropathies.
- results in the following **ipsilateral sensory deficits** found below the lesion:
 1. **Loss of tactile discrimination**
 2. **Loss of position (joint) and vibratory sensation**
 3. **Stereoanesthesia** (astereognosis)
 4. **Sensory (posterior column) dystaxia**
 5. **Paresthesias and pain** (posterior root irritation)
 6. **Hyporeflexia or areflexia** (posterior root deafferentation)
 7. **Urinary incontinence, constipation, and impotence** (posterior root deafferentation)
 8. **Romberg sign** (sensory dystaxia) (standing patient is more unsteady with eyes closed)

B. Lateral spinothalamic tract lesion

- contralateral loss of pain and temperature sensation one segment below the level of the lesion.

C. Anterior spinothalamic tract lesion

- contralateral loss of crude touch sensation three or four segments below the level of the lesion.
- does not appreciably reduce touch sensation if the posterior columns are intact.

D. Posterior spinocerebellar tract lesion

- ipsilateral lower limb dystaxia; patient has difficulty performing the heel-to-shin test.

E. Anterior spinocerebellar tract lesion

- contralateral lower limb dystaxia; patient has difficulty performing the heel-to-shin test.

IV. PERIPHERAL NERVOUS SYSTEM LESIONS

- may be sensory, motor, or combined.
- affect spinal roots, spinal ganglia, and peripheral nerves.

A. Herpes zoster (shingles)

- a common **viral infection** of the nervous system.
- an acute inflammatory reaction in the posterior root or cranial nerve ganglia.
- usually limited to the territory of one dermatome; the most common sites are from **T5 to T10**.
- causes irritation of spinal ganglion cells, resulting in pain, itching, and burning sensations in the involved dermatomes.
- produces a characteristic vesicular eruption in the affected dermatome.

B. Acute idiopathic polyneuritis (Guillain–Barré syndrome)

- also called **postinfectious polyneuritis**.
- usually follows an infectious illness.
- results from a cell-mediated immunologic reaction directed at peripheral nerves.
- affects primarily motor fibers and causes segmental demyelination and wallerian degeneration.
- produces **LMN symptoms** (muscle weakness, flaccid paralysis, and areflexia).
- results in symmetric paralysis that begins in the lower extremities and ascends to involve the trunk and upper extremities; the facial nerve frequently is involved bilaterally.
- elevates cerebrospinal fluid (CSF) protein; however, the CSF cell count remains normal (**albuminocytologic dissociation**).

V. COMBINED UPPER AND LOWER MOTOR NEURON LESIONS

A. Characteristics

- muscle weakness and wasting without sensory deficits.

B. Prototypic disease—amyotrophic lateral sclerosis (ALS) (see Figure 8.1D)

- also called **Lou Gehrig disease**, motor neuron disease, or motor system disease.
- usually occurs in persons of 50–70 years.
- affects twice as many men as women.
- involves both LMNs and UMNs.
- progressive (spinal) muscular atrophy or progressive bulbar palsy refers to an LMN component.
- pseudobulbar palsy or primary lateral sclerosis refers to a UMN component.

VI. COMBINED MOTOR AND SENSORY LESIONS

A. Spinal cord hemisection (Brown–Séquard syndrome) (Figures 8.2 and 8.3; see Figure 8.1E)

1. Posterior column transection

- results in ipsilateral loss of tactile discrimination, form perception, and position and vibration sensation below the lesion.

2. Lateral spinothalamic tract transection

- results in contralateral loss of pain and temperature sensation, starting one segment below the lesion.

3. Anterior spinothalamic tract transection

- results in contralateral loss of crude touch sensation starting three or four segments below the lesion.

4. Posterior spinocerebellar tract transection

- results in ipsilateral lower limb dystaxia.

5. Anterior spinocerebellar tract transection

- results in contralateral lower limb dystaxia.

6. Hypothalamospinal tract transection rostral to T2

- results in Horner syndrome.

7. Lateral corticospinal tract transection

- results in ipsilateral spastic paresis below the UMN lesion with Babinski sign.

8. Anterior corticospinal tract transection

- results in minor contralateral muscle weakness below the lesion.

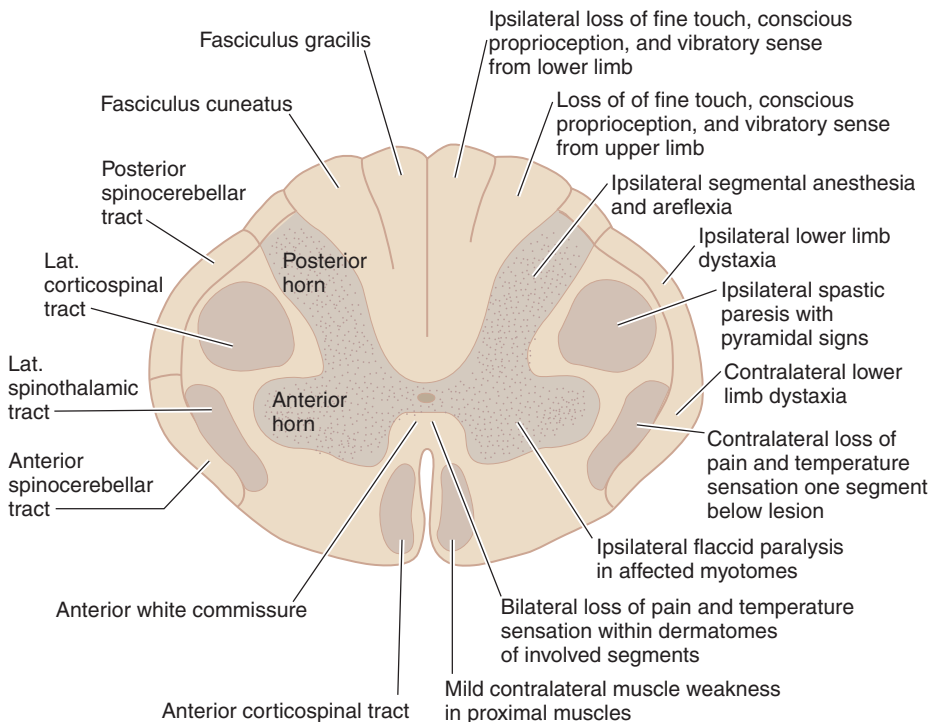


FIGURE 8.2. Transverse section of the cervical spinal cord. Clinically important pathways are shown on the left side; clinical deficits resulting from the interruption of these pathways are shown on the right side. Destructive lesions of the posterior horns result in anesthesia and areflexia, and destructive lesions of the anterior horns result in LMN lesions and areflexia. Destruction of the anterior white commissure interrupts the central transmission of pain and temperature impulses bilaterally via the anterolateral system.

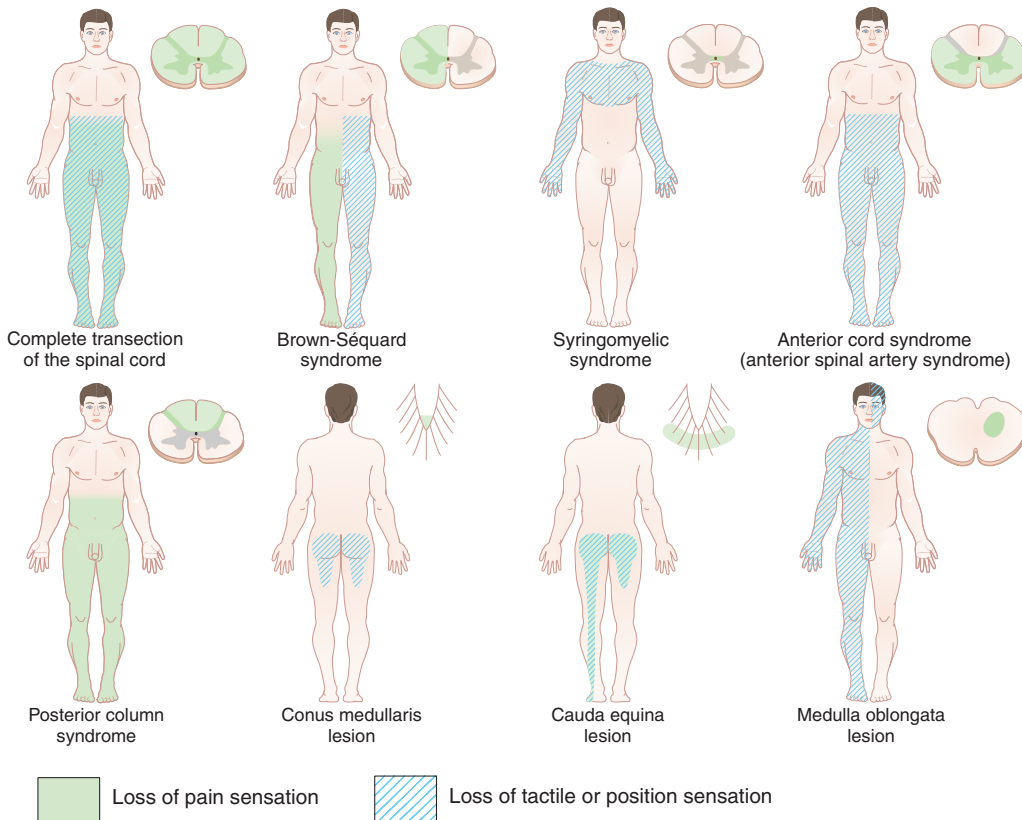


FIGURE 8.3. Localization of sensory disorders.

9. Anterior horn destruction

- results in ipsilateral flaccid paralysis of somatic muscles (LMN lesion).

10. Posterior horn destruction

- results in ipsilateral dermatomic anesthesia and areflexia.

B. Complete transection of the spinal cord

- results in the following conditions:
 1. **Exitus lethalis** if between C1 and C3
 2. **Quadriplegia** if between C4 and C5
 3. **Paraplegia** if below T1
 4. **Spastic paralysis** of all voluntary movements below the lesion
 5. **Complete anesthesia** below the lesion
 6. **Urinary and fecal incontinence** (although reflex emptying may occur)
 7. **Anhidrosis and loss of vasomotor tone**
 8. **Paralysis of volitional and automatic breathing**, if the transection is above C5 (the phrenic nucleus is found at C3–C5)

C. Anterior spinal artery occlusion (see Figure 8.1F)

- causes infarction of the anterior two-thirds of the spinal cord.
- usually spares the posterior columns and posterior horns.
- paralysis of voluntary and automatic respiration in cervical segments; it also results in bilateral Horner syndrome.
- loss of voluntary bladder and bowel control, with preservation of reflex emptying.
- anhidrosis and loss of vasomotor tone.
 1. **Anterior horn destruction**
 - complete flaccid paralysis and areflexia at the level of the lesion.

2. Corticospinal tract transection

- results in a spastic paresis below the lesion.

3. Spinothalamic tract transection

- results in loss of pain and temperature sensations, starting one segment below the lesion.

4. Posterior spinocerebellar tract and anterior spinocerebellar tract transection

- results in cerebellar incoordination, which is masked by LMN and UMN paralysis.

D. Conus medullaris and epiconus syndromes

- include neurologic deficits and signs that are mostly bilateral.
- often presents as a mixture of UMN and LMN deficits.

1. Conus medullaris syndrome

- involves segments S3–Co.
- usually caused by small intramedullary tumor metastases or hemorrhagic infarcts.
- results in destruction of the sacral parasympathetic nucleus, which causes paralytic bladder, fecal incontinence, and impotence.
- causes perianogenital sensory loss in dermatomes S3–Co (saddle anesthesia).
- shows an absence of motor deficits in the lower limbs.

2. Epiconus syndrome

- involves segments L4–S2.
- results in reflex functioning of the bladder and rectum but loss of voluntary control.
- characterized by considerable **motor disability** (external rotation and extension of the thigh are most affected).
- affects the anterior horns and longitudinal spinal cord tracts.
- associated with absent Achilles tendon reflex.

E. Cauda equina syndrome

- classically involves spinal roots L3–Co.
- produces neurologic deficits similar to those seen in conus or epiconus lesions.
- results in signs that frequently predominate on one side.
- may result from intervertebral disk herniation.
- commonly results in severe spontaneous radicular pain (pain that radiates along a dermatome).

F. Filum terminale (tethered cord) syndrome

- results from a thickened, shortened filum terminale that adheres to the sacrum and causes traction on the conus medullaris.
- characterized by sphincter dysfunction, gait disorders, and deformities of the feet.

G. Subacute combined degeneration (vitamin B₁₂ neuropathy) (see Figure 8.1G)

- a spinal cord disease associated with pernicious anemia.
- consists of demyelination of posterior columns, resulting in loss of vibration and position sensation.
- consists of demyelination of spinocerebellar tracts, resulting in arm and leg dystaxia.
- consists of demyelination of corticospinal tracts resulting in spastic paresis (UMN signs).

H. Friedreich hereditary ataxia (see Figure 8.1G)

- the commonest hereditary ataxia with autosomal recessive inheritance.
- results in spinal cord pathology and spinal cord symptoms that are similar to subacute combined degeneration with posterior column, spinocerebellar, and corticospinal tract involvement.
- cerebellar involvement (Purkinje cells and dentate nucleus) is frequent with progressive ataxia.
- commonly leads to cardiomyopathy, pes cavus, and kyphoscoliosis.

I. Syringomyelia (see Figures 8.1H and 8.3)

- a central cavitation of the spinal cord of unknown etiology.
- results in destruction of the anterior white commissure and interruption of decussating spinothalamic fibers, causing bilateral loss of pain and temperature sensation.

- may result in extension of the syrinx into the anterior horn, causing a LMN lesion with muscle wasting and hyporeflexia. Atrophy of lumbricals and interosseous muscles of the hand is a common finding.
- may result in extension of the syrinx into the lateral funiculus, affecting the lateral corticospinal tract and resulting in spastic paresis (UMN lesion).
- may result in caudal extension of the syrinx into the lateral horn at T1 or lateral extension into the lateral funiculus (interruption of descending autonomic pathways), resulting in Horner syndrome.
- may be associated with the Chiari malformation.

J. Multiple sclerosis (see Figure 8.1B)

- the commonest form of demyelinating disease.
- has asymmetric lesions and may affect all tracts of the spinal cord. Lesions occur most frequently in the cervical segments.

K. Charcot–Marie–Tooth disease (hereditary motor–sensory neuropathy type I) (see Figure 8.1I)

- also called peroneal (fibular) muscular atrophy.
- the commonest inherited neuropathy.
- affects the posterior columns, resulting in a loss of conscious proprioception.
- affects the anterior horn motor neurons, resulting in muscle weakness (atrophy) below the knee.

VII. INTERVERTEBRAL DISK HERNIATION

A. Overview

- consists of prolapse or herniation of the **nucleus pulposus** through the defective **annulus fibrosus** into the vertebral canal. The nucleus pulposus impinges on spinal roots, resulting in root pain (radiculopathy) or muscle weakness.
- may compress the spinal cord with a large central protrusion.
- recognized as the major cause of severe and chronic low back and lower limb pain.
- appears in 90% of cases at the L4–L5 or L5–S1 interspaces; usually a single nerve root is compressed but several may be involved at the L5–S1 interspace (cauda equina).
- appears in 10% of cases in the cervical region, usually at the C5–C6 or C6–C7 interspaces.
- characterized by **spinal root symptoms** that include paresthesias, pain, sensory loss, hyporeflexia, and muscle weakness.

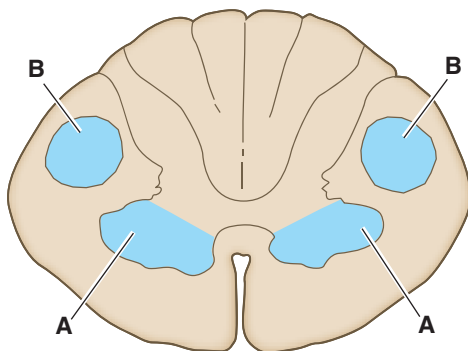
B. Cervical spondylosis with myelopathy

- the most commonly observed myelopathy.
- consists of spinal cord or spinal cord root compression by calcified disk material extruded into the spinal vertebral canal.
- presents as painful stiff neck, upper limb pain and weakness, and spastic lower limb weakness with dystaxia; sensory disorders are frequent.

Review Test

Questions 1 to 3

Questions 1 to 3 relate to the figure.



Neuropathologic examination of the spinal cord reveals two lesions labeled A and B. Lesion A is restricted to five segments.

1. The result of lesion A is best described as:

- (A) bilateral upper limb dystaxia with dysidiadochokinesia.
- (B) flaccid paralysis of the upper limbs.
- (C) loss of pain and temperature sensation below the lesion.
- (D) urinary and fecal incontinence.
- (E) spastic paresis of the lower limbs.

2. The result of lesion B is best described as:

- (A) bilateral apallesthesia.
- (B) dyssynergia of movements affecting both upper and lower limbs.
- (C) flaccid paralysis of the upper limbs.
- (D) impaired two-point tactile discrimination in both upper limbs.
- (E) spastic paresis affecting primarily the muscles distal to the knee joint.

3. Lesions A and B result from:

- (A) ALS.
- (B) an extramedullary tumor.
- (C) an intramedullary tumor.
- (D) multiple sclerosis.
- (E) thrombosis of a spinal artery.

4. Neurologic examination reveals an extensor plantar reflex and hyperreflexia on the left side, a loss of pain and temperature sensation on

the right side, and ptosis and miosis on the left side. A lesion that causes this constellation of deficits would most likely be found in the:

- (A) cervical spinal cord.
- (B) crus cerebri, right side.
- (C) lumbar spinal cord.
- (D) paracentral lobule, left side.
- (E) posterolateral medulla, left side.

5. A 50-year-old woman complains of clumsiness in her hands while working in the kitchen: She recently burned her hands on the stove without experiencing any pain. Neurologic examination reveals bilateral weakness of the shoulder girdles, arms, and hands as well as a loss of pain and temperature sensation covering the shoulder and upper limb in a cape-like distribution. Severe atrophy is present in the intrinsic muscles of the hands. The most likely diagnosis is:

- (A) ALS.
- (B) subacute combined degeneration.
- (C) syringomyelia.
- (D) tabes dorsalis.
- (E) Werdnig-Hoffmann disease.

6. A 50-year-old man has a 2-year history of progressive muscle weakness in all limbs, with severe muscle atrophy and reduced MSRs in both lower limbs. In his upper limbs, the muscle atrophy is less pronounced and the MSRs are exaggerated. Which of the following types of neuronal degeneration would postmortem examination most likely show?

- (A) Demyelination of axons in the posterior and lateral columns
- (B) Demyelination of axons in the posterior limb of the internal capsule
- (C) Loss of neurons from the globus pallidus
- (D) Loss of neurons from the paracentral lobule and from the anterior horns of the spinal cord
- (E) Loss of Purkinje cells

7. Transection of the anterolateral tract results in:

- (A) areflexia.
- (B) cerebellar incoordination.
- (C) complete flaccid paralysis.
- (D) loss of pain and temperature sensation.
- (E) spastic paresis.

8. Which of the following is a characteristic of Lou Gehrig disease?

- (A) Loss of tactile discrimination
- (B) Loss of vibratory sensation
- (C) Posterior root irritation
- (D) Progressive bulbar palsy
- (E) Stereoaesthesia

9. Clasp-knife spasticity results from a lesion in the:

- (A) anterior corticospinal tract.
- (B) anterior spinothalamic tract.
- (C) lateral corticospinal tract.
- (D) lateral spinothalamic tract.
- (E) posterior spinocerebellar tract.

10. Which of the following syndromes is associated with an absent Achilles tendon reflex?

- (A) Cauda equina
- (B) Conus medullaris
- (C) Epidural abscess
- (D) Filum terminale
- (E) Syringomyelia

11. An example of a peripheral nervous system lesion is:

- (A) Brown-Séquard syndrome.
- (B) Charcot-Marie-Tooth disease.
- (C) Friedreich ataxia.
- (D) Guillain-Barré syndrome.
- (E) Lou Gehrig disease.

12. A patient has the ability to stand with open eyes but falls with closed eyes. A lesion of which pathway is likely responsible for this symptom?

- (A) Anterior spinocerebellar tract
- (B) Anterior spinothalamic tract
- (C) Lateral spinothalamic tract
- (D) Posterior column syndrome
- (E) Posterior spinocerebellar tract

Questions 13 to 18

The response options for items 13 to 18 are the same. Select one answer for each item in the set.

- (A) ALS
- (B) Cauda equina syndrome
- (C) Cervical spondylosis
- (D) Friedreich ataxia
- (E) Guillain-Barré syndrome
- (F) Multiple sclerosis
- (G) Subacute combined degeneration
- (H) Tabes dorsalis
- (I) Werdnig-Hoffmann disease

Match each statement below with the syndrome that corresponds best to it.

13. A pure LMN disease

14. Elevated CSF protein with a normal CSF cell count

15. Characterized by asymmetric lesions found in the white matter of cervical segments

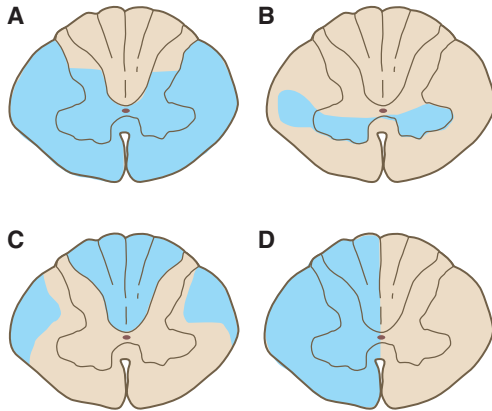
16. May result from intervertebral disk herniation

17. Symptoms include a painful stiff neck, arm pain and weakness, spastic leg weakness with dystaxia; sensory disorders are frequent

18. Associated with a loss of Purkinje cells

Questions 19 to 26

Match the statement in items 19 to 26 with the lesion shown in the figure that corresponds best to it.



19. Neurologic manifestation of vitamin B₁₂ deficiency

20. Lesion owing to vascular occlusion

21. Loss of vibration sensation on the right side; loss of pain and temperature sensation on the left side

22. Bilateral loss of pain and temperature sensation in the lower limbs

23. Bilateral loss of pain and temperature sensation in the hands; muscle atrophy in both hands; spastic paresis on the right side only

24. Urinary incontinence and quadriplegia

25. No muscle atrophy or fasciculations

26. Demyelinating disease

Answers and Explanations

1-B. Lesion A involves degeneration of the anterior horns bilaterally at midcervical levels and results in flaccid paralysis in the upper extremities.

2-E. Lesion B involves degeneration of the lateral corticospinal tracts bilaterally, resulting in spastic paresis of the lower extremities and primarily affecting the muscles distal to the knee. Spastic paresis of the upper extremities is masked by flaccid paralysis resulting from lesion A. Apallesthesia is the inability to perceive a vibrating tuning fork.

3-A. Lesions A and B are the result of ALS, a pure motor disease.

4-A. A lesion of the cervical spinal cord could result in ipsilateral Horner syndrome, ipsilateral spastic paresis, and contralateral loss of pain and temperature sensation. Horner syndrome is always manifested on the ipsilateral side. This lesion produces a classic Brown-Séquard syndrome.

5-C. Syringomyelia is a cavitation of the spinal cord most commonly seen in the cervicothoracic segments. This condition results in bilateral loss of pain and temperature sensation in a cape-like distribution as well as wasting of the intrinsic muscles of the hands. ALS is a pure motor syndrome; subacute combined degeneration includes both sensory and motor deficits; Werdnig-Hoffmann disease is a pure motor disease; and tabes dorsalis is a pure sensory syndrome (neurosyphilis).

6-D. ALS affects both the upper and LMNs. It is also referred to as motor systems disease. A loss of Purkinje cells as seen in cerebellar cortical atrophy (cerebello-olivary atrophy) results in cerebellar signs. Cell loss in the globus pallidus and putamen is seen in Wilson disease (hepatolenticular degeneration). Demyelination of axons in the posterior and lateral columns is seen in subacute combined degeneration. Demyelination of axons in the posterior limb of the internal capsule results in contralateral spastic hemiparesis.

7-D. Transection of the anterolateral tract results in loss of pain and temperature sensations, starting one segment below the lesion. Anterior horn destruction results in complete flaccid paralysis and areflexia at the level of the lesion. Corticospinal tract transection results in spastic paresis below the lesion. Posterior spinocerebellar tract and ventral spinocerebellar tract transection results in cerebellar incoordination.

8-D. Progressive bulbar palsy is a LMN component of ALS, or Lou Gehrig disease. Disease characteristics are muscle weakness and wasting without sensory deficits. Loss of tactile discrimination, loss of vibratory sensation, stereoaesthesia, and dorsal root irritation are all sensory deficits found in posterior column syndrome.

9-C. Clasp-knife spasticity is an ipsilateral motor deficit found below a lesion of the lateral corticospinal tract. It is characterized by initial but fading resistance of a briskly moved joint.

10-C. Epicomus syndrome involves segments L4-S2 and results in loss of voluntary control of the bladder and rectum, motor disability, and an absent Achilles tendon reflex.

11-D. Acute idiopathic polyneuritis, or Guillain-Barré syndrome, is a peripheral nervous system lesion. It typically follows an infectious illness and results from a cell-mediated immunologic reaction.

12-D. Posterior column syndrome results in a sensory deficit known as sensory dystaxia or Romberg sign. Patients are Romberg positive when they are able to stand with the eyes open but fall with the eyes closed.

13-I. Werdnig-Hoffmann disease is a hereditary degenerative disease of infants that affects only LMNs.

14–E. Guillain–Barré syndrome is characterized by elevated CSF protein with normal CSF cell count (albuminocytologic dissociation).

15–F. Multiple sclerosis is characterized by asymmetric lesions frequently found in the white matter of cervical segments.

16–B. Cauda equina syndrome frequently results from intervertebral disk herniation; severe spontaneous radicular pain is common.

17–C. Cervical spondylosis is the most commonly observed myelopathy. Its symptoms include a painful stiff neck, arm pain and weakness, and spastic leg weakness with dystaxia; sensory disorders are frequent.

18–D. Friedreich ataxia is the most common hereditary ataxia with autosomal recessive inheritance. Posterior columns, spinocerebellar tracts, and the corticospinal tracts show demyelination. Friedreich ataxia results in a loss of Purkinje cells in the cerebellar cortex and a loss of neurons in the dentate nucleus.

19–C. A neurologic manifestation of vitamin B₁₂ deficiency is subacute combined degeneration. There is no involvement of LMNs.

20–A. Lesion A shows the territory of infarction resulting from occlusion of the anterior spinal artery.

21–D. A spinal cord hemisection (Brown–Séquard syndrome) on the right side results in a loss of vibration sensation on the right side and a loss of pain and temperature sensation on the left side (dissociated sensory loss).

22–A. Total occlusion of the anterior spinal artery that involves five cervical segments and results in infarction of the anterior two-thirds of the spinal cord and interrupts the anterolateral system. The patient will have a loss of pain and temperature sensation caudal to the lesion.

23–B. Lesion B shows a cervical syringomyelic lesion involving the anterior white commissure, both anterior horns, and the right corticospinal tract. The patient will have a bilateral loss of pain and temperature sensation in the hands, muscle wasting in both hands, and a spastic paresis on the right side.

24–A. In lesion A, both lateral and anterior funiculi have been infarcted by arterial occlusion. Bilateral destruction of the lateral corticospinal tracts at upper cervical levels results in quadriplegia (spastic paresis in upper and lower extremities). Bilateral destruction of the anterolateral quadrants results in urinary and fecal incontinence.

25–C. In lesion C, subacute combined degeneration, there is no involvement of LMNs, hence no flaccid paralysis, muscle atrophy, or fasciculations.

26–C. In lesion C, subacute combined degeneration, there is symmetric degeneration of the white matter, both in the posterior columns (fasciculi gracilis) and in the lateral funiculi (corticospinal tracts). In this degenerative disease, both the myelin sheaths and the axis cylinders are involved. Subacute combined degeneration is classified under nutritional diseases (in this case a vitamin B₁₂ neuropathy). In true demyelinating diseases (e.g., multiple sclerosis) the myelin sheaths are involved but the axis cylinders and nerve cells are relatively spared.

Objectives

- List the parts of the brainstem and external characteristics of each part.
- List the major pathways (ascending and descending) and nuclei found in the medulla, pons, and midbrain and include a general description of the significance of each.
- Identify the components of representative brainstem sections based on the diagrams provided in the text.

I. INTRODUCTION (FIGURE 9.1)

- includes the **medulla**, **pons**, and **mesencephalon** (midbrain).
- extends from the pyramidal decussation to the posterior commissure.
- gives rise to cranial nerves—CN III to CN XII.
- receives blood supply from the verteobasilar system.
- contains the **reticular formation** as its central core: phylogenetically old—functions as the core integrating structure of the central nervous system (CNS) as it receives collaterals from most afferent and efferent systems.

II. MEDULLA OBLONGATA (MYELENCEPHALON)**A. Overview: the medulla**

- contains autonomic centers that regulate respiration, circulation, and gastrointestinal motility.
- extends from the pyramidal decussation to the inferior pontine sulcus.
- gives rise to cranial nerves—CN IX to CN XII. The nuclei of CN V and CN VIII extend caudally into the medulla.
- connected to the cerebellum by the inferior cerebellar peduncle.

B. Internal structures of the medulla (Figures 9.2 through 9.5)**1. Ascending sensory pathways and relay nuclei**

- **Fasciculus gracilis and fasciculus cuneatus**
 - a. convey posterior column modalities.
 - b. terminate in the nucleus gracilis and nucleus cuneatus.
- **Nucleus gracilis and nucleus cuneatus**
 - a. contain second-order neurons of the posterior column–medial lemniscus pathway.
 - b. give rise to internal arcuate fibers.
 - c. project via the medial lemniscus to the ventral posterolateral nucleus of the thalamus.

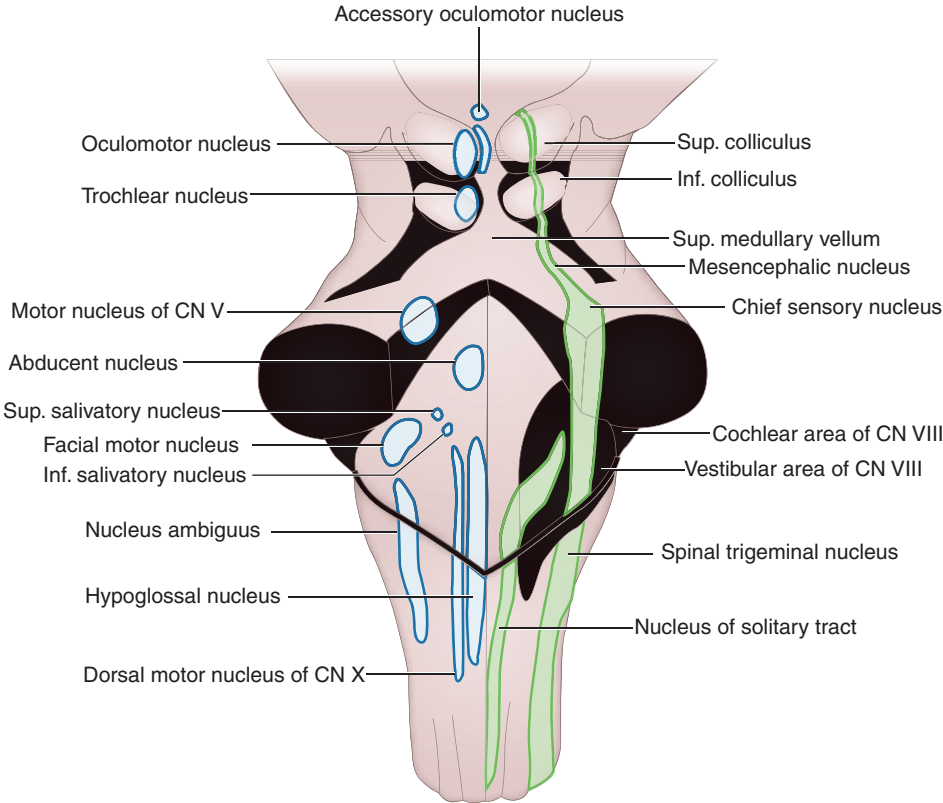


FIGURE 9.1. Outline of the brainstem showing the location of motor and sensory cranial nerve nuclei. Motor nuclei are shown on the *left* side of the figure, and sensory nuclei are shown on the *right* side.

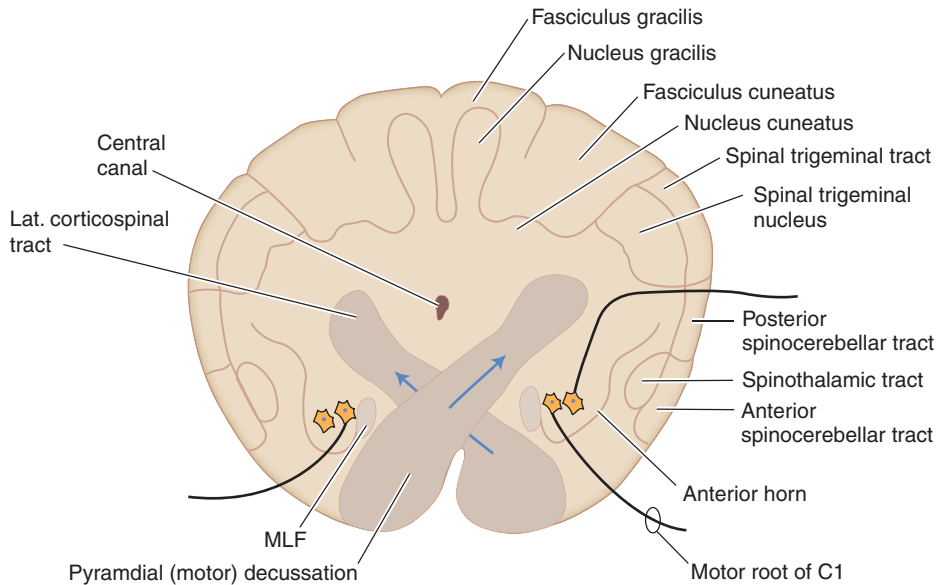


FIGURE 9.2. Transverse section of the caudal medulla at the level of the pyramidal (motor) decussation.

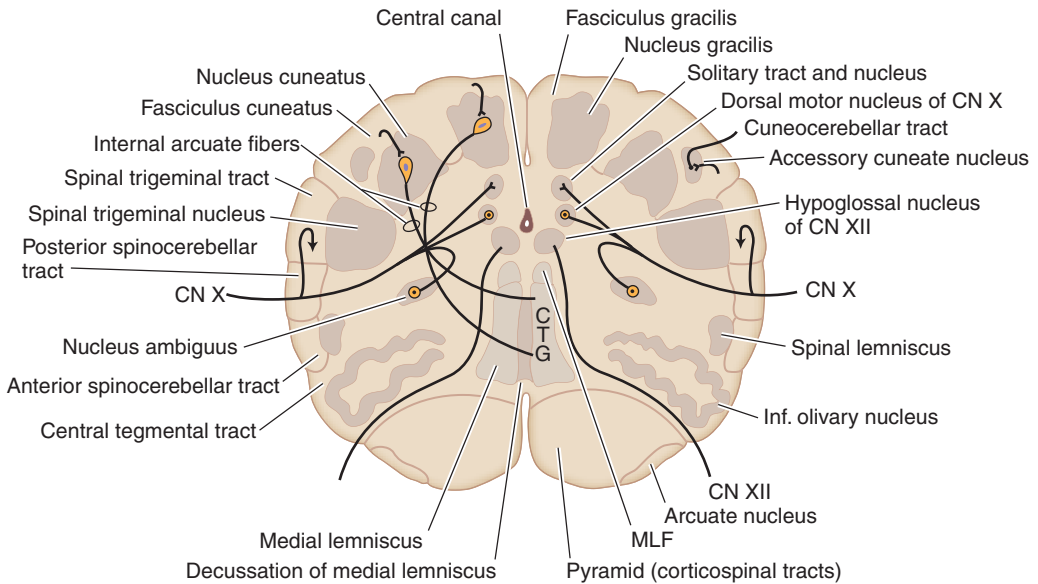


FIGURE 9.3. Transverse section of the caudal medulla at the level of the decussation of the medial lemniscus. The internal arcuate fibers decussate and form the medial lemniscus. GSA fibers of the vagal nerve (CN X) enter the spinal trigeminal tract of CN V (arrow). CTG = cuneate (arm), trunk, and gracile (leg) components of the medial lemniscus; GSA = general somatic afferent.

- **Internal arcuate fibers**

- a. arise from the nucleus gracilis and nucleus cuneatus and form the contralateral medial lemniscus.

- **Decussation of the medial lemniscus** (see Figure 9.3)

- a. formed by decussating internal arcuate fibers.

- **Medial lemniscus**

- a. conveys posterior column modalities to the ventral posterolateral nucleus.

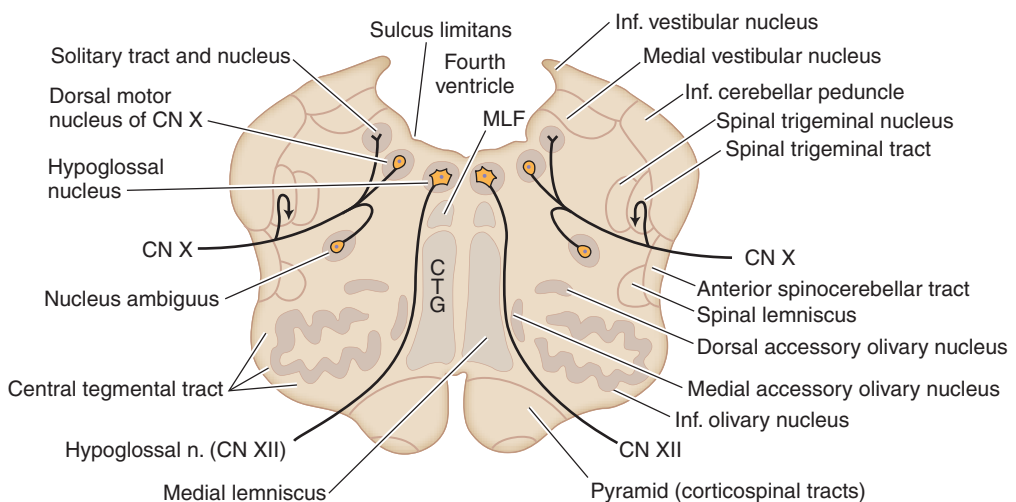


FIGURE 9.4. Transverse section of the medulla at the midolivary level. The vagal (CN X), hypoglossal (CN XII), and vestibular (CN VIII) nerves are prominent in this section. The nucleus ambiguus gives rise to SVE fibers in CN IX and CN X. The posterior spinocerebellar tract is in the inferior cerebellar peduncle. SVE = special visceral efferent.

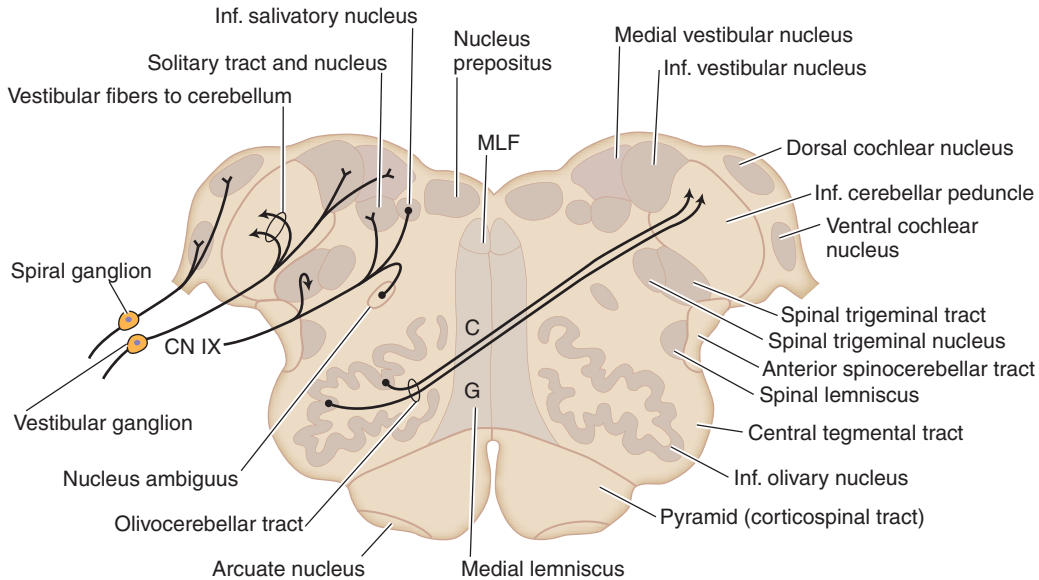


FIGURE 9.5. Rostral medulla at the level of the dorsal and ventral cochlear nuclei (of CN VIII). The glossopharyngeal nerve (CN IX) is also found at this level. The hypoglossal nucleus (of CN XII) has been replaced by the nucleus prepositus. GSA fibers of the glossopharyngeal nerve (CN IX) enter the spinal trigeminal tract of CN V (arrow). GSA = general somatic afferent.

- **Spinal lemniscus**
 - a. contains the lateral and anterior spinothalamic tracts and the spinotectal tract.
- 2. **Descending motor pathways**
 - **Pyramidal decussation** (see Figure 9.2)
 - a. located at the spinomedullary junction.
 - b. consists of crossing corticospinal fibers.
 - **Pyramids** (see Figures 9.4 and 9.5)
 - a. constitute the base of the medulla.
 - b. contain uncrossed corticospinal fibers.
- 3. **Cerebellar pathways and relay nuclei**
 - **Accessory (lateral) cuneate nucleus**
 - a. contains second-order neurons of the cuneocerebellar tract.
 - b. projects to the cerebellum via the inferior cerebellar peduncle.
 - **Inferior olivary nucleus**
 - a. cerebellar relay nucleus that projects olivocerebellar fibers via the inferior cerebellar peduncle to the contralateral cerebellar cortex and cerebellar nuclei.
 - b. receives input from the red nucleus.
 - **Central tegmental tract**
 - a. well-defined tract within the reticular formation.
 - b. extends from the midbrain to the inferior olivary nucleus.
 - c. contains rubro-olivary and reticulothalamic fibers.
 - d. contains taste fibers.
 - **Lateral reticular nucleus**
 - a. a cerebellar relay nucleus that projects via the inferior cerebellar peduncle to the cerebellum.
 - **Arcuate nucleus**
 - a. located on the anterior surface of the pyramids.

- b. gives rise to arcuatocerebellar fibers that become the striae medullares of the rhomboid fossa.
- **Posterior spinocerebellar tract**
 - a. mediates unconscious proprioception from the lower limbs to the cerebellum via the inferior cerebellar peduncle.
- **Anterior spinocerebellar tract**
 - a. mediates unconscious proprioception from the lower limbs to the cerebellum via the superior cerebellar peduncle.
- **Inferior cerebellar peduncle**
 - a. connects the medulla to the cerebellum.
- 4. **Cranial nerve nuclei and associated tracts**
 - **Medial longitudinal fasciculus (MLF)**
 - a. yokes together cranial nerve nuclei, particularly important for coordination of eye movement.
 - b. contains vestibular fibers of CN VIII that coordinate eye movements via CN III, CN IV, and CN VI.
 - c. mediates nystagmus and lateral conjugate gaze.
 - **Solitary tract**
 - a. receives general visceral afferent (GVA) input from CN IX and CN X.
 - b. receives special visceral afferent (SVA) (taste) input from CN VII, CN IX, and CN X.
 - **Solitary nucleus**
 - a. projects GVA and SVA input ipsilaterally via the central tegmental tract to the parabrachial nucleus of the pons and to the posteromedial nucleus of the thalamus.
 - **Dorsal motor nucleus of CN X** (see Figures 9.1, 9.3, and 9.4)
 - a. gives rise to vagal preganglionic parasympathetic general visceral efferent (GVE) fibers that synapse in the terminal (intramural) ganglia of the thoracic and abdominal viscera.
 - **Inferior salivatory nucleus of CN IX**
 - a. gives rise to preganglionic parasympathetic (GVE) fibers that synapse in the otic ganglion.
 - **Hypoglossal nucleus of CN XII** (see Figures 9.1, 9.3, and 9.4)
 - a. gives rise to general somatic efferent (GSE) fibers that innervate the intrinsic and extrinsic muscles of the tongue.
 - **Nucleus ambiguus of CN IX and CN X**, (see Figures 9.1 and 9.3 through 9.5)
 - a. represents a special visceral efferent (SVE) cell column whose axons innervate pharyngeal arch muscles of the larynx and pharynx. These fibers contribute to parts of CN IX and CN X; they exit the medulla via the postolivary sulcus.
 - **Spinal trigeminal tract** (Figure 9.6; see Figures 9.2 through 9.4)
 - a. replaces the posterolateral tract (of Lissauer).
 - b. contains first-order neuron general somatic afferent (GSA) fibers that mediate pain, temperature, and light touch sensations from the face via CN V, CN VII, CN IX, and CN X.
 - c. projects to the spinal trigeminal nucleus.
 - **Spinal trigeminal nucleus** (see Figures 9.1 through 9.6)
 - a. replaces the substantia gelatinosa of the spinal cord.
 - b. gives rise to decussating axons that form the anterior trigeminothalamic tract. This tract terminates in the ventral posteromedial nucleus of the thalamus.
 - **Inferior and medial vestibular nuclei of CN VIII**
 - a. receives proprioceptive (special somatic afferent [SSA]) input from the semicircular ducts, utricle, saccule, and cerebellum.
 - b. project to the cerebellum and MLF.
- 5. **Area postrema**
 - lies rostral to the obex in the floor of the fourth ventricle.
 - a circumventricular organ with no blood-brain barrier.

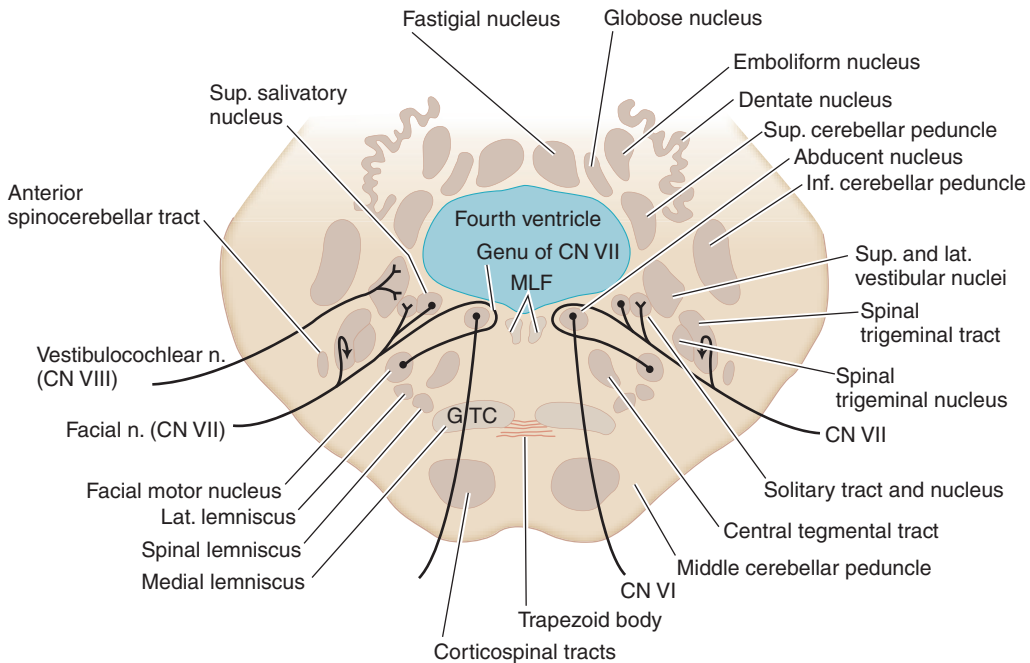


FIGURE 9.6. Caudal pons at the level of the abducent (CN VI) and facial (CN VII) nuclei. The intra-axial abducent fibers pass through the medial lemniscus and the descending corticospinal fibers. Note the looping course of the intra-axial facial nerve fibers that exit the brainstem in the cerebellopontine angle. The four cerebellar nuclei overlie the fourth ventricle. Note also the looping course of the facial nerve fibers.

III. PONS

A. Overview

- extends from the inferior pontine sulcus to the superior pontine sulcus.
- consists of the **base** that contains corticobulbar, corticospinal, and corticopontine tracts and pontine nuclei and the **tegmentum** that contains cranial nerve nuclei, reticular nuclei, and the major ascending sensory pathways.
- connected to the cerebellum by the middle cerebellar peduncle.
- contains auditory relay nuclei and vestibular nuclei; the latter regulate postural mechanisms and vestibulo-ocular reflexes.
- contains, in its caudal portion, the facial motor nucleus of CN VII, which innervates the muscles of facial expression.
- contains, in the mid pons, the trigeminal motor nucleus of CN V; its axons innervate the muscles of mastication.
- contains a center for lateral gaze.
- gives rise to cranial nerves from CN V to CN VIII.

B. Internal structures of the pons (Figure 9.7; see Figure 9.6)

1. Ascending sensory pathways and relay nuclei

- **Dorsal and ventral cochlear nuclei** (see Figure 9.5)
 - a. receive auditory input from the cochlea through SSA fibers via the cochlear branch of CN VIII.
 - b. are auditory relay nuclei that give rise to the lateral lemnisci.
- **Trapezoid body**
 - a. formed by decussating fibers of the ventral cochlear nuclei.
 - b. contains the acoustic striae, medial lemnisci, exiting abducent (CN VI) fibers, and aberrant corticobulbar fibers.

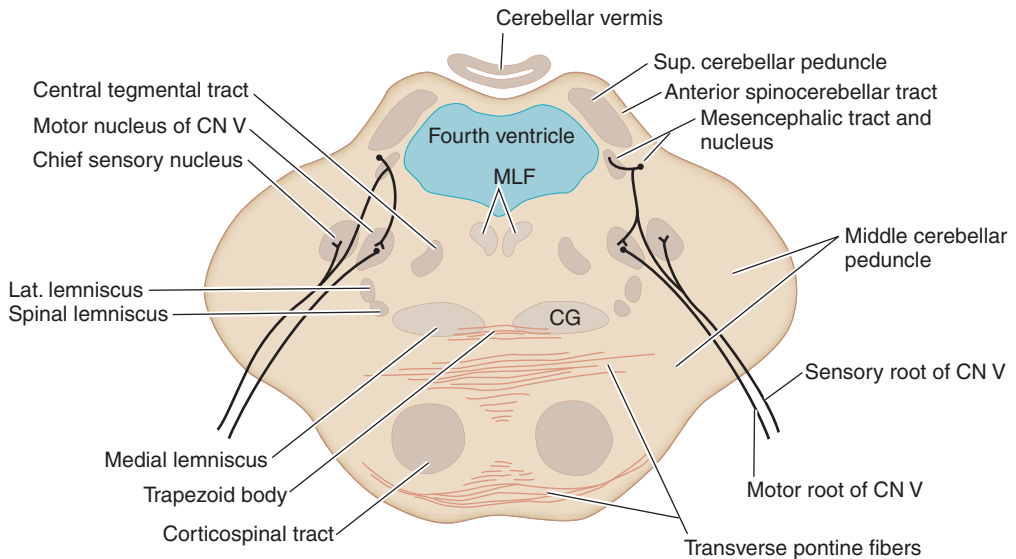


FIGURE 9.7. Mid pons at the level of the motor and chief sensory nuclei of the trigeminal nerve (CN V). The mesencephalic tract and nucleus provide the afferent limb of the myotatic jaw jerk reflex; the trigeminal motor nucleus is the efferent limb.

- **Superior olivary nucleus**
 - a. an auditory relay nucleus at the level of the trapezoid body.
 - b. receives input from the cochlear nuclei.
 - c. contributes bilaterally to the lateral lemniscus.
- **Lateral lemniscus**
 - a. a pontine auditory pathway extending from the trapezoid body to the nucleus of the inferior colliculus.
 - b. conducts a preponderance of contralateral cochlear input.
- **Medial lemniscus**
 - a. mediates contralateral posterior column modalities to the ventral posterolateral nucleus of the thalamus.
- **Spinal lemniscus**
 - a. contains lateral and anterior spinothalamic tracts and the spinotectal tract.
- 2. **Descending motor pathways (base of the pons)**
 - **Corticobulbar tract**
 - a. synapses in the motor nuclei of the cranial nerves except in the ocular motor nuclei of CN III, CN IV, and CN VI.
 - **Corticospinal tract (pyramidal tract)**
 - a. synapses in the anterior horn of the spinal cord.
 - **Corticopontine tract**
 - a. synapses in the pontine nuclei.
- 3. **Cerebellar pathways and relay nuclei**
 - **Central tegmental tract**
 - a. extends from the midbrain to the inferior olivary nucleus.
 - b. contains rubro-olivary and reticulothalamic fibers.
 - **Juxtarestiform body**
 - a. forms part of the inferior cerebellar peduncle.
 - b. contains vestibulocerebellar, cerebellovestibular, and cerebelloreticular fibers.
 - **Middle cerebellar peduncle**
 - a. contains pontocerebellar fibers.
 - b. connects the pons to the cerebellum.
 - **Superior cerebellar peduncle**
 - a. connects the cerebellum to the pons and midbrain.
 - b. contains the dentatorubrothalamic fibers and the anterior spinocerebellar tract.

- **Pontine nuclei**
 - a. cerebellar relay nuclei in the base of the pons.
 - b. give rise to pontocerebellar fibers that constitute the middle cerebellar peduncle.
- 4. **Cranial nerve nuclei and associated tracts**
 - **Dorsal and ventral cochlear nuclei of CN VIII**
 - a. found at the medullopontine junction.
 - **Medial, lateral, and superior vestibular nuclei of CN VIII** (see Figure 9.6)
 - a. receive proprioceptive (SSA) input from the semicircular ducts, utricle, saccule, and cerebellum.
 - b. project into the cerebellum and the MLF.
 - c. The lateral vestibular nucleus gives rise to the lateral vestibulospinal tract.
 - **Medial longitudinal fasciculus**
 - a. contains vestibular fibers of CN VIII that coordinate eye movements via CN III, CN IV, and CN VI.
 - b. mediates nystagmus and lateral conjugate gaze.
 - **Abducent nucleus of CN VI** (see Figure 9.6)
 - a. underlies, in the caudal medial pontine tegmentum, the facial colliculus of the rhomboid fossa.
 - b. projects exiting fibers through the trapezoid body and through the corticospinal tract of the base of the pons.
 - c. gives rise to GSE fibers that innervate the lateral rectus muscle.
 - d. gives rise to fibers that project via the MLF to the contralateral oculomotor nucleus of CN III.
 - e. near the **pontine center for lateral conjugate gaze**, which receives commands from the contralateral frontal eye field (area 8). It innervates (via the MLF) the contralateral medial rectus muscle and via abducent fibers the ipsilateral lateral rectus muscle to execute conjugate lateral gaze.
 - **Facial nucleus of CN VII** (see Figure 9.6)
 - a. gives rise to SVE fibers that innervate the muscles of facial expression.
 - b. receives bilateral input for upper facial muscles and contralateral input for lower facial muscles.
 - c. contains neurons that project axons dorsomedially, encircle the abducent nucleus as a genu, and pass anterolaterally between the facial nucleus and spinal trigeminal nucleus to exit the brainstem in the cerebellopontine angle.
 - **Superior salivatory nucleus of CN VII**
 - a. gives rise to GVE preganglionic parasympathetic fibers that synapse in the pterygo-palatine and submandibular ganglia.
 - **Spinal trigeminal tract and nucleus of CN V**
 - **Trigeminal motor nucleus**
 - a. lies in the lateral midpontine tegmentum at the level of the trigeminal nerve.
 - b. lies medial to the principal sensory nucleus of the trigeminal nerve.
 - c. receives bilateral corticobulbar input.
 - d. gives rise to SVE fibers that innervate muscles of mastication, anterior belly of digastric, mylohyoid, tensor palati and tensor tympani.
 - **Chief sensory nucleus of CN V**
 - a. lies lateral to the trigeminal motor nucleus.
 - b. receives discriminative tactile and pressure input from the face.
 - c. gives rise to trigeminothalamic fibers that join the contralateral anterior trigeminothalamic tract.
 - d. gives rise to the uncrossed posterior trigeminothalamic tract, which terminates in the ventral posteromedial nucleus of the thalamus.
 - **Mesencephalic nucleus and tract of CN V** (Figures 9.8 and 9.9; see Figure 9.7)
 - a. extend from the upper pons to the upper midbrain.
 - b. contain the only population of pseudounipolar neurons in the CNS.
 - c. receive input from muscle spindles and pressure receptors (muscles of mastication and extraocular muscles).

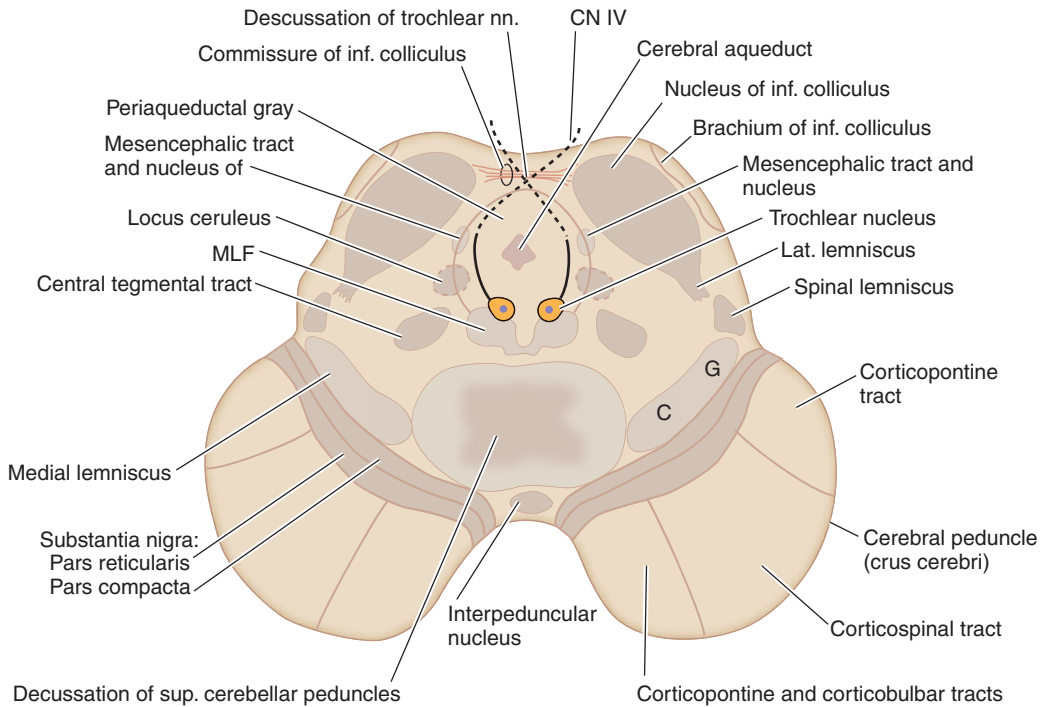


FIGURE 9.8. Midbrain at the level of the inferior colliculus, the decussation of the superior cerebellar peduncles, and the trochlear nucleus (of CN IV).

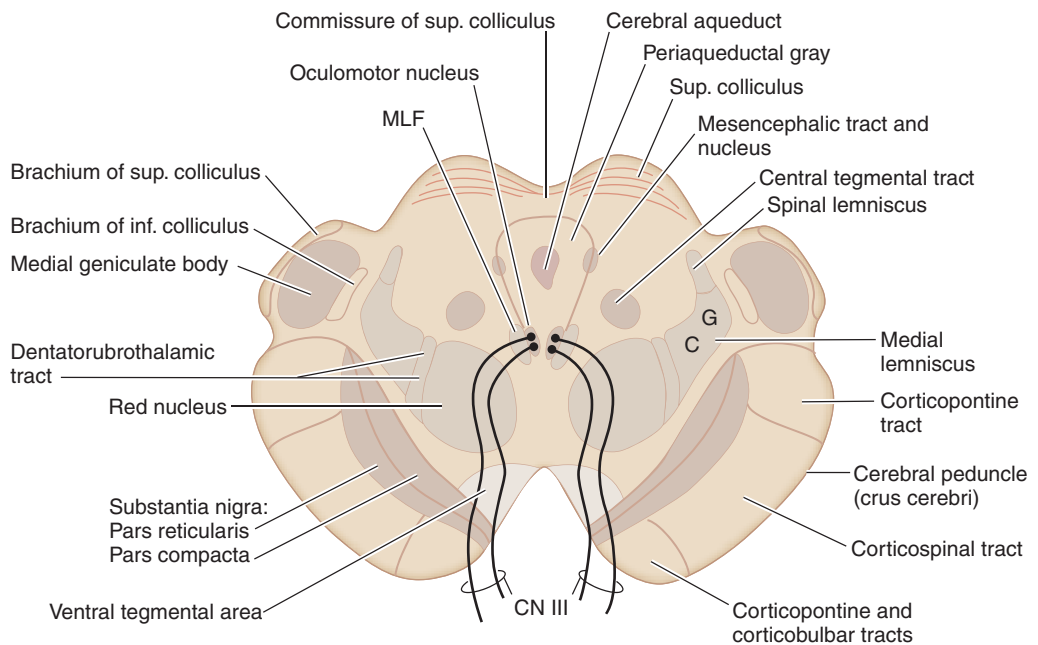


FIGURE 9.9. Midbrain at the level of the superior colliculus, the oculomotor nucleus, and the red nucleus. Oculomotor fibers pass laterally through the red nucleus and basis pedunculi and exit in the interpeduncular fossa.

5. Locus ceruleus

- a melanin-containing nucleus in the pons and midbrain.
- an important nucleus of the monamine system that projects noradrenergic axons to all parts of the CNS.

IV. MESENCEPHALON (MIDBRAIN) (SEE FIGURES 9.8 AND 9.9)

A. Overview

- mediates auditory and visual reflexes.
- contains the oculomotor nerve (CN III) and the trochlear nerve (CN IV), which innervate the extraocular muscles of the eye.
- contains a center for vertical conjugate gaze in its rostral extent.
- contains the **substantia nigra**, the largest nucleus of the midbrain; degeneration of this extrapyramidal motor nucleus results in Parkinson disease.
- contains the **paramedian reticular formation**; lesions of this formation result in coma.
- extends from the superior medullary velum to the posterior commissure.
- gives rise to two cranial nerves: **CN III** (oculomotor) and **CN IV** (trochlear).
- consists of three parts: the **tectum**, the **tegmentum**, and the **base (basis pedunculi)**.

B. Structures of the midbrain

1. Tectum

- located posterior to the cerebral aqueduct.
- forms the roof of the midbrain, including the superior and inferior colliculi.

2. Tegmentum

- located between the tectum and the base.
- contains cranial nerve nuclei and sensory pathways.

3. Basis pedunculi (crus cerebri)

- forms the base of the midbrain and contains corticospinal, corticobulbar, and corticopontine tracts.

4. Pedunculus cerebri (cerebral peduncle)

- includes the tegmentum and basis pedunculi.

5. Pretectum (pretectal area)

- located between the superior colliculus and the habenular trigone.

C. Inferior collicular level of the midbrain (see Figure 9.8)

1. Inferior colliculus

- contains the nucleus of the inferior colliculus.

2. Nucleus of the inferior colliculus

- an auditory relay nucleus that receives binaural input from the lateral lemniscus.
- projects to the medial geniculate body via the brachium of the inferior colliculus.

3. Lateral lemniscus

- projects binaural auditory information to the inferior collicular nucleus.

4. Commissure of the inferior colliculus

- interconnects the inferior collicular nucleus and its opposite partner.

5. Brachium of the inferior colliculus

- conducts auditory information from the inferior collicular nucleus to the medial geniculate body.

6. Cerebral aqueduct

- located between the tectum and tegmentum.
- surrounded by the periaqueductal gray matter.
- interconnects the third and fourth ventricles.
- blockage (aqueductal stenosis) results in **hydrocephalus**.

7. **Periaqueductal gray matter**
 - the central gray matter that surrounds the cerebral aqueduct.
 - contains several nuclear groups.
 - a. **Locus ceruleus**
 - b. **Mesencephalic nucleus and tract**
 - c. **Dorsal tegmental nucleus**
 - contains enkephalinergic neurons that play a role in endogenous pain control.
 - d. **Raphe nuclei**
 - contains serotonergic neurons.
8. **Trochlear nucleus of CN IV** (see Figure 9.8)
 - gives rise to GSE fibers that encircle the periaqueductal gray matter, decussate in the superior medullary velum, and exit the midbrain from its posterior aspect to innervate the superior oblique.
9. **Medial longitudinal fasciculus**
 - contains vestibular fibers that coordinate eye movements.
 - interconnects the motor nuclei of CN III, CN IV, and CN VI.
10. **Decussation of the superior cerebellar peduncles** (see Figure 9.8)
 - most conspicuous structure of this level.
11. **Interpeduncular nucleus**
 - receives input from the habenular nuclei via the habenulointerpeduncular tract (fasciculus retroflexus of Meynert).
12. **Substantia nigra** (see Figures 9.8 and 9.9)
 - divided into the posterior pars compacta containing large pigmented (melanin) cells and the anterior pars reticularis.
 - receives gamma-aminobutyric acid-ergic (GABA-ergic) input from the caudatoputamen (striatonigral fibers).
 - projects dopaminergic fibers to the caudatoputamen (nigrostriatal fibers).
 - projects nondopaminergic fibers to the ventral anterior nucleus, ventral lateral nucleus, and mediodorsal nucleus of the thalamus (nigrothalamic fibers).
13. **Medial lemniscus**
 - mediates posterior column modalities to the ventral posterolateral nucleus.
14. **Spinal lemniscus**
 - contains the lateral and anterior spinothalamic tracts and the spinotectal tract.
15. **Central tegmental tract**
 - contains rubro-olivary and reticulothalamic fibers.
16. **Basis pedunculi (crus cerebri)** (see Figures 9.8 and 9.9)

D. Superior collicular level of the midbrain (see Figure 9.9)

1. **Superior colliculus**
 - receives visual input from the retina and from frontal (area 8) and occipital (area 19) eye fields.
 - receives auditory input from the inferior colliculus to mediate audiovisual reflexes.
 - concerned with detection of movement in visual fields, thus facilitating visual orientation, searching, and tracking.
2. **Commissure of the superior colliculus**
 - interconnects the two superior colliculi.
3. **Brachium of the superior colliculus**
 - conducts retinal and corticotectal fibers to the superior colliculus and to the pretectum, thus mediating optic and pupillary reflexes.
4. **Cerebral aqueduct and periaqueductal gray matter**
5. **Oculomotor nucleus of CN III** (see Figure 9.9)
 - gives rise to GSE fibers that innervate four extraocular muscles (medial, inferior, superior recti, and inferior oblique) and the levator palpebrae superioris.
 - projects crossed fibers to the superior rectus.
 - projects crossed and uncrossed fibers to the levator palpebrae superioris.

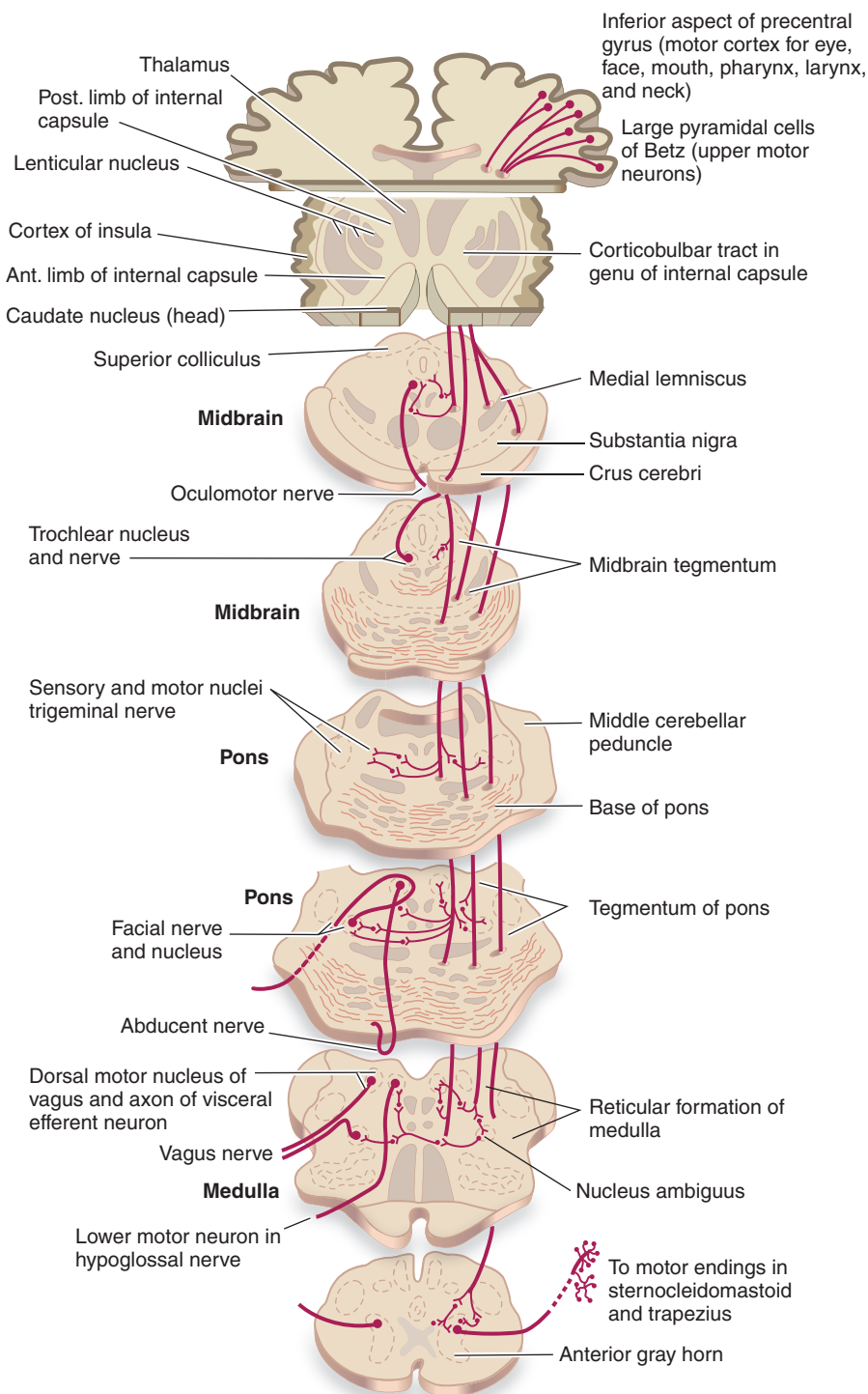


FIGURE 9.10. Corticobulbar pathways of the brainstem. Corticobulbar fibers arise from the facial area of the motor cortex and innervate motor (GSE) and (SVE) cranial nerve nuclei of CN V, CN VII, CN IX, CN X, CN XI, and CN XII. Direct corticobulbar fibers to the ocular motor nerves, CN III, CN IV, and CN VI, have not been demonstrated. Interruption of the corticobulbar fibers results in a UMN lesion. *GSE* = general somatic efferent; *SVE* = special visceral efferent; *UMN* = upper motor neuron. (Adapted from Carpenter MC. *Core Text of Neuroanatomy*. 3rd ed. Baltimore, MD: Williams & Wilkins; 1985:129 with permission.)

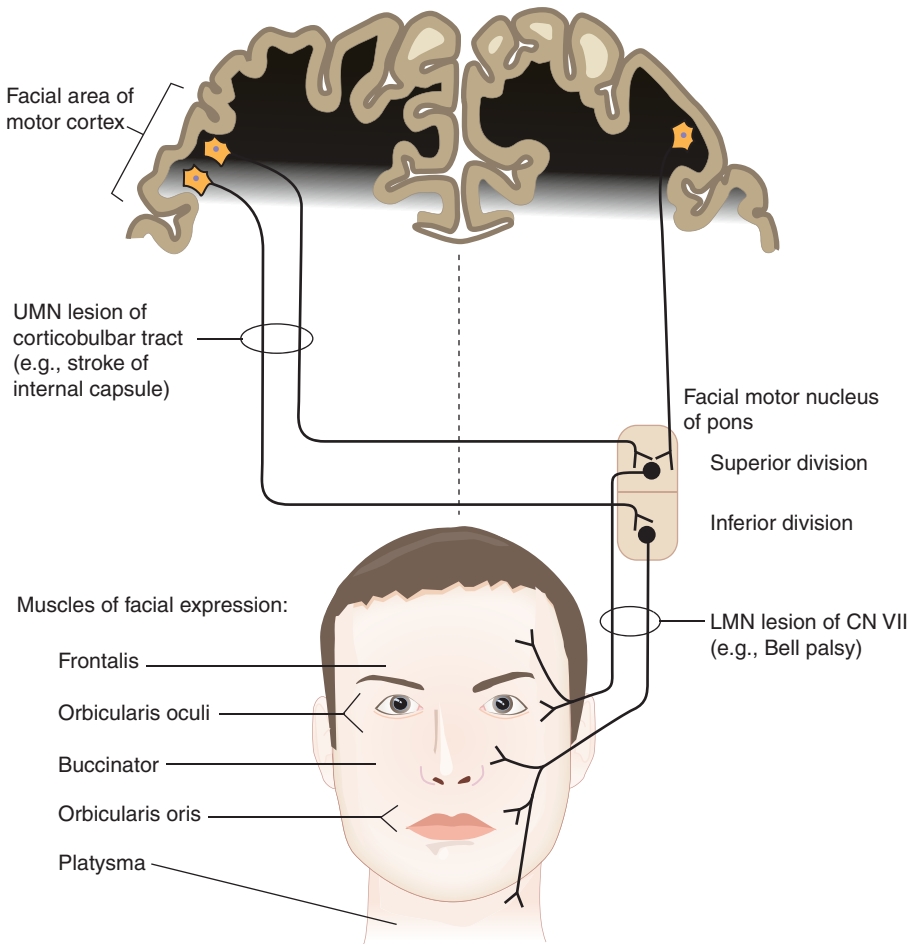


FIGURE 9.11. Corticobulbar innervation of the facial motor nucleus. An UMN lesion (e.g., a stroke involving the internal capsule) results in contralateral weakness of the inferior face and spares in the superior face. A LMN lesion (e.g., Bell palsy) results in paralysis of facial muscles in both the superior and inferior face. *UMN* = upper motor neuron; *LMN* = lower motor neuron.

6. Accessory oculomotor (Edinger–Westphal) nucleus of CN III

- gives rise to GVE preganglionic parasympathetic fibers that terminate in the ciliary ganglion.
- Postganglionic fibers from the ciliary ganglion innervate the ciliary body (accommodation) and sphincter pupillae.

7. Medial longitudinal fasciculus

- contains vestibular fibers that coordinate eye movements.
- interconnects the ocular motor cranial nerves (CN III, CN IV, and CN VI).

8. Central tegmental tract

- contains rubro-olivary and reticulothalamic fibers.

9. Red nucleus (see Figure 9.9)

- located in the tegmentum at the level of the oculomotor nucleus (the level of the superior colliculus).
- receives bilateral input from the cerebral cortex.
- receives contralateral input from the cerebellar nuclei.
- gives rise to the crossed rubrospinal tract.
- gives rise to the uncrossed rubro-olivary tract.
- exerts facilitatory influence on flexor muscles.

10. Medial lemniscus

- mediates posterior column modalities to the ventral posterolateral nucleus of the thalamus.

11. Spinal lemniscus

- contains the lateral and anterior spinothalamic tracts.

12. Substantia nigra

- basis pedunculi (crus cerebri)

E. Posterior commissural level (pretectal region)

- a transition area between the mesencephalon and the diencephalon.

1. Posterior commissure

- marks the caudal extent of the third ventricle.
- marks the rostral extent of the cerebral aqueduct.
- interconnects pretectal nuclei, thus mediating consensual pupillary light reflexes.

2. Pretectal nucleus

- receives retinal input via the brachium of the superior colliculus.
- projects to the ipsilateral and contralateral accessory oculomotor nuclei, thus mediating the pupillary light reflexes.

V. CORTICOBULBAR (CORTICONUCLEAR) FIBERS (FIGURE 9.10; SEE FIGURE 10.5)

- arise from precentral and postcentral gyri.
- may synapse directly on motor neurons or indirectly via interneurons (corticoreticular fibers).
- innervate sensory nuclei (gracile, cuneate, solitary, and trigeminal).
- innervate cranial nerve motor nuclei bilaterally, with the exception of part of the facial nucleus (CN VII). The upper face division of the facial nucleus receives bilateral input; the lower face division of the facial nucleus receives only contralateral input (Figure 9.11)
- innervate the ipsilateral spinal nucleus of CN XI that supplies the sternocleidomastoid and the contralateral spinal nucleus of CN XI that innervates the trapezius.
- the orbicularis oculi receives a variable number of crossed and uncrossed fibers; the paresis therefore varies from patient to patient.

Review Test

1. A 40-year-old female librarian is brought to the emergency department. Neurologic examination reveals the following: blood pressure 160/90 mm Hg, numbness on the right side of her inferior face, no weakness in upper or lower limbs, tongue deviating to right side on protrusion, and uvula deviating to the left side when patient says “ah.” In which of the following loci is the lesion causing these symptoms found?

- (A) Anterior limb of internal capsule
- (B) Claustrum
- (C) Genu of internal capsule, left side
- (D) Paracentral lobule, right side
- (E) Posterior limb internal capsule

2. In which part of the brain is the cerebral aqueduct found?

- (A) Diencephalon
- (B) Mesencephalon
- (C) Metencephalon
- (D) Myelencephalon
- (E) Telencephalon

Questions 3 to 10

The response options for items 3 to 10 are the same. Select one answer for each item in the set.

- (A) Base of pons
- (B) Midbrain, at level of superior colliculus
- (C) Midbrain, at level of inferior colliculus
- (D) Medial medulla
- (E) Lateral medulla
- (F) Tegmentum of pons

Match the following structures with the appropriate brainstem division.

3. Decussation of the superior cerebellar peduncle

4. Inferior olivary nucleus

5. Nucleus ambiguus

6. Abducent nucleus

7. Facial motor nucleus

8. Oculomotor nucleus

9. Red nucleus

10. Trochlear nucleus

Answers and Explanations

1–C. A lesion of the genu of the internal capsule destroys corticobulbar fibers. The facial nucleus receives bilateral corticobulbar input, the upper face division receives bilateral input, and the lower face division receives only contralateral input. The hypoglossal nucleus receives only contralateral corticobulbar input. When the tongue is protruded, it deviates to the weak side owing to the unopposed activity of the intact genioglossus. The uvula deviates to the intact side when the patient says “ah.” The muscles of the uvula and palatal arches are innervated by the vagal nerve (CN X).

2–B. The cerebral aqueduct is found in the mesencephalon; it connects the third ventricle to the fourth ventricle.

3–C. The decussation of the superior cerebellar peduncle is diagnostic of midbrain division at the level of the inferior colliculus.

4–E. The inferior olivary nucleus, a cerebellar relay nucleus, is the most prominent nucleus in the lateral medulla.

5–E. The nucleus ambiguus is found in the lateral medulla; it gives rise to the SVE components of cranial nerves IX and X.

6–F. The abducent nucleus (CN VI) is located in the dorsomedial tegmentum of the pons. All brainstem cranial nerve nuclei are found in the tegmentum.

7–F. The facial nucleus (CN VII) is located in the lateral tegmentum of the pons.

8–B The oculomotor nucleus (CN III) lies in the dorsomedial tegmentum of the midbrain at the level of the superior colliculus; it lies medial to the medial longitudinal fasciculus.

9–B. The red nucleus is diagnostic of midbrain division at the level of the superior colliculus; it lies between the oculomotor nucleus (CN III) and the substantia nigra.

10–C. The trochlear nerve (CN IV) is located in the dorsomedial tegmentum of the midbrain at the level of the inferior colliculus.

Objectives

- List the cranial nerves.
- Describe the general characteristics, components, and functions of each cranial nerve.
- Describe the effects of lesion of each cranial nerve.
- Refer to Table A-1 in the Appendix for a table of cranial nerve components.

I. INTRODUCTION

- the pairs of nerves that arise from the brain.(Figures 10.1 through 10.3; see Figures 1.1 and 1.7).

II. NERVUS TERMINALIS (NT; CRANIAL NERVE 0)

- first identified in humans approximately 100 years ago, often not included in texts because of difficulty in identifying the nerve, its function and its origin.
- located anteromedial to the filia olfactoria, pierces the cribriform plate with CN I.
- most likely a special visceral afferent (SVA) nerve that mediates the perception of pheromones and functions in reproductive systems.
- consists of unmyelinated nerve fibers associated with gyrus rectus.
- projects posteriorly to the medial and lateral septal nuclei and the preoptic area of the diencephalon.

III. OLFACTORY NERVE (CN I) (SEE CHAPTER 17 I AND APPENDIX)**A. General characteristics of CN I**

- an **SVA** nerve that mediates the **sense of smell** (olfaction).
- consists of a collection of unmyelinated axons—the filia olfactoria—of bipolar neurons located in the nasal mucosa, the olfactory epithelium.

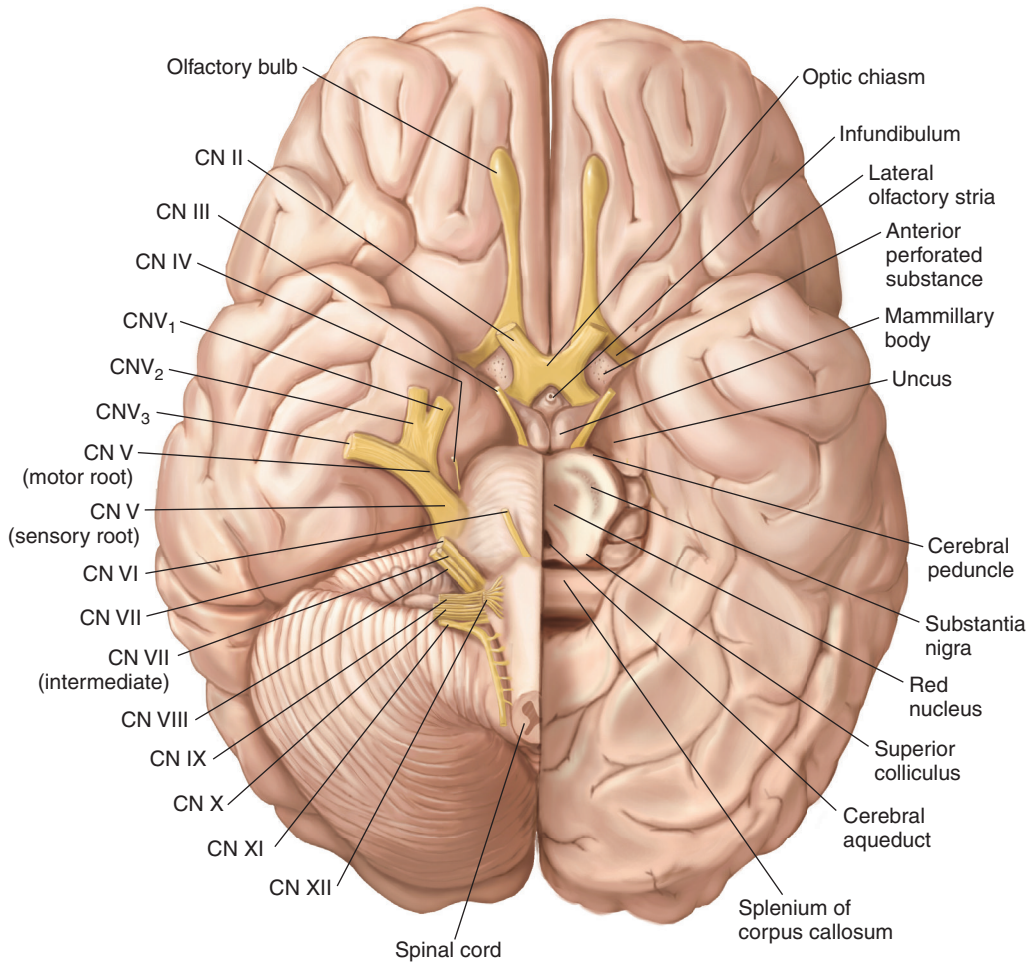


FIGURE 10.1. The base of the brain with attached cranial nerves (CN). (Modified from Truex RC, Kellner CE. *Detailed Atlas of the Head and Neck*. New York, NY: Oxford University Press; 1958:34.)

- enters the skull via the foramina of the cribriform plate of the ethmoid bone.
- projects directly to the telencephalon.
- synapses with mitral and tufted cells found in the olfactory bulb, an outgrowth of the telencephalon.
- the only cranial nerve that projects directly to the forebrain.

B. Clinical correlation: CN I damage

- results in **anosmia**, loss of olfactory sensation (e.g., ethmoid bone fracture).
- the olfactory epithelium is capable of regeneration after injury.

IV. OPTIC NERVE (CN II) (SEE FIGURES 1.2, 16.2, AND 16.4; SEE CHAPTER 16 III B)

A. General characteristics of CN II

- a special somatic afferent (**SSA**) nerve that subserves **vision** and **pupillary light reflexes**.
- consists of axons of neurons located in the ganglion cell layer of the retina.

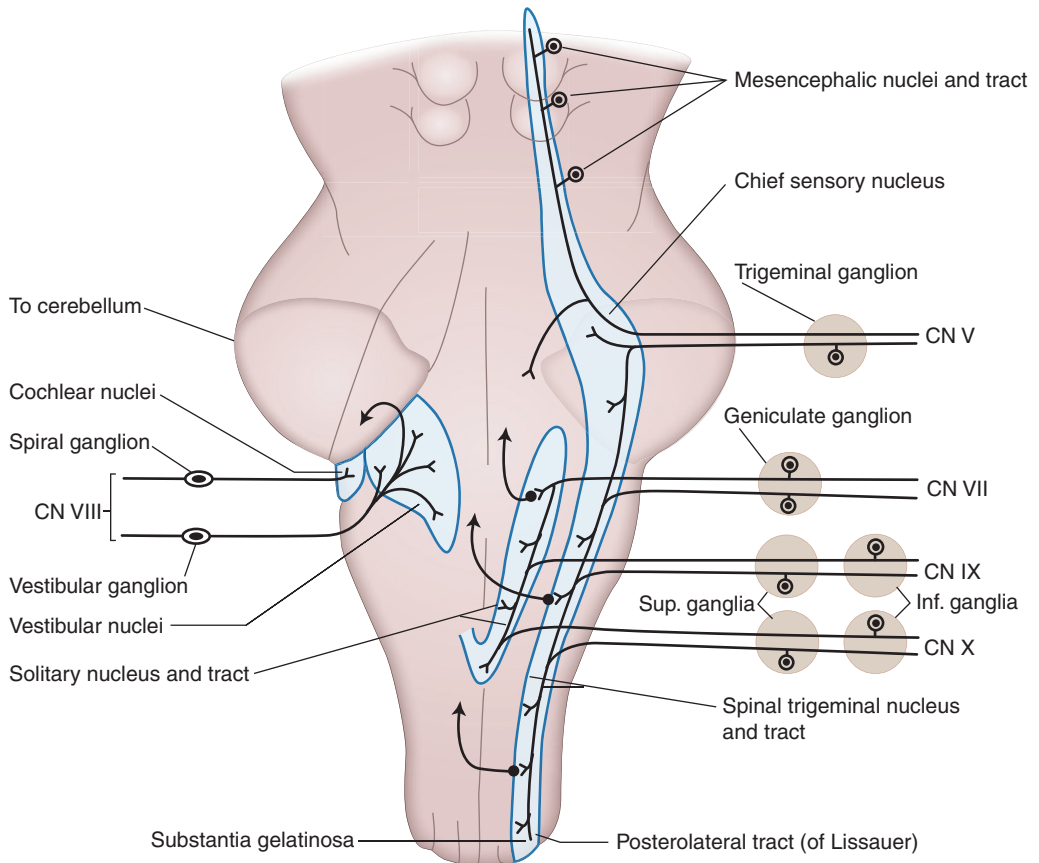


FIGURE 10.2. Location of the sensory cranial nerve nuclei within the brainstem. The spinal trigeminal tract and nucleus extend into the cervical cord (C3). Three sensory areas are prominent: the special somatic afferent (SSA) area, including the cochlear and vestibular nuclei of CN VIII; the combined general visceral afferent (GVA) and special visceral afferent (SVA) column, the solitary nucleus of CN VII, CN IX, and CN X; and the general somatic afferent (GSA) column, including the spinal trigeminal, chief sensory, and mesencephalic nuclei of CN V, CN VII, CN IX, and CN X. (Modified from Noback CR, Demarest RJ. *The Human Nervous System*. Baltimore, MD: Williams & Wilkins; 1991:222.)

- enters the skull via the optic canal of the sphenoid bone.
- has axons that continue via the optic chiasm and optic tracts to the lateral geniculate body, a thalamic relay nucleus that projects to the visual cortex (area 17) of the occipital lobe.
- **not a true peripheral nerve** but a tract of the diencephalon.
- contains fibers from the nasal retina that decussate in the optic chiasm.
- contains fibers from the temporal retina that continue ipsilaterally through the optic chiasm.
- contains myelinated axons.
- invested by the dura and pia-arachnoid membranes and lies within the subarachnoid space.

B. Clinical correlations: CN II

- When it is transected, **ipsilateral blindness** and **loss of direct pupillary light reflex** result; regeneration of the optic nerve does not occur.
- When subjected to increased intracranial pressure (e.g., tumor), **papilledema**, a choked optic disk results.
- When it is constricted, **optic atrophy** (i.e., axonal degeneration) results.

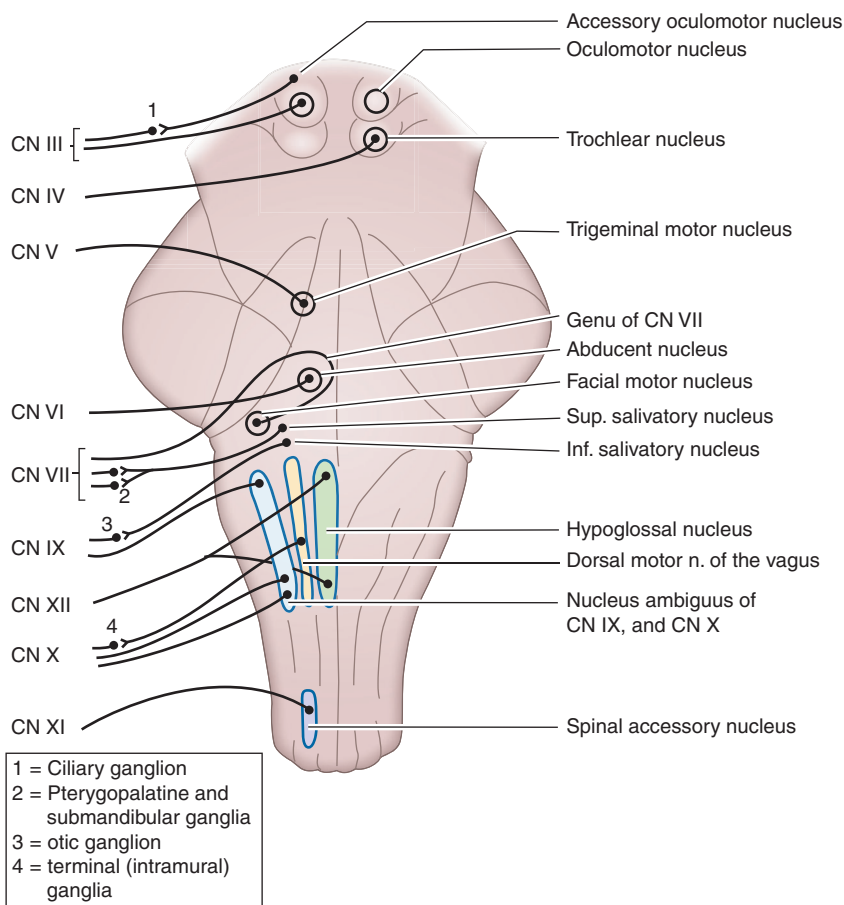


FIGURE 10.3. Location of motor cranial nerve nuclei within the brainstem. Three functional cell columns are visible from medial to lateral; the general somatic efferent (GSE) column of CN III, CN IV, CN VI, and CN XII; the GVE column of CN III, CN VII, CN IX, and CN X; and the special visceral efferent (SVE) column of CN V, CN VII, CN IX, CN X, and CN XI. (Modified from Noback CR, Demarest RJ. *The Human Nervous System*. Baltimore, MD: Williams & Wilkins; 1991:223.)

V. OCULOMOTOR NERVE (CN III) (SEE FIGURES 1.1, 1.7, AND 10.3; CHAPTER 16)

A. General characteristics of CN III

- contains general somatic efferent (GSE) and general visceral efferent (GVE) fibers.
- a purely motor nerve that **moves the eye, constricts the pupil, accommodates, and converges**.
- exits the brainstem from the interpeduncular fossa of the midbrain, passes through the lateral wall of the cavernous sinus, and enters the orbit via the superior orbital fissure.

1. GSE component

- arises from the oculomotor nucleus of the midbrain.
- innervates four extraocular muscles and the levator palpebrae superioris.
 - a. **Medial rectus**
 - adducts the eye.
 - with its opposite partner, converges the eyes.

- b. **Superior rectus**
 - elevates, intorts, and adducts the eye.
 - c. **Inferior rectus**
 - depresses, extorts, and adducts the eye.
 - d. **Inferior oblique**
 - elevates, extorts, and abducts the eye.
 - e. **Levator palpebrae**
 - elevates the upper eyelid.
2. **GVE component**
- **Composition**
 - a. consists of preganglionic parasympathetic fibers.
 - **Pathway**
 - a. arises from the accessory oculomotor nucleus (Edinger–Westphal nucleus) of the midbrain.
 - **Accessory oculomotor nucleus**
 - (1) projects to the ciliary ganglion of the orbit via CN III.
 - **Ciliary ganglion**
 - (1) projects postganglionic parasympathetic fibers via branches of CN V₁ to the sphincter pupillae (miosis) and to the ciliaris (accommodation).

B. Clinical correlations: CN III

1. Oculomotor paralysis

- Seen frequently with **transtentorial herniation** (subdural or epidural hematoma).
- Results in **diplopia** (double vision) when the patient looks in the direction of the paretic muscle.
- Denervation of the levator palpebrae superioris results in **ptosis** (drooping of the upper eyelid).
- Denervation of the extraocular muscles causes the affected eye to **look down and out** because the action of the lateral rectus and superior oblique is unopposed. The superior oblique and lateral rectus are innervated by CN IV and CN VI.
- Interruption of parasympathetic innervation results in a **dilated and fixed pupil** and **paralysis of accommodation (cycloplegia)**.

2. Other conditions associated with CN III impairment

- **Transtentorial (uncal) herniation**
 - a. Increased supratentorial pressure (tumor) forces the uncus through the tentorial notch and compresses the oculomotor nerve. Pupilloconstrictor fibers are affected first, resulting in a dilated and fixed pupil; somatic efferent fibers are affected later, resulting in an external strabismus (exotropia).
- **Aneurysms (carotid and posterior communicating arteries)**
 - a. frequently compress the oculomotor nerve within the cavernous sinus or the interpeduncular cistern.
 - b. usually affect the peripheral pupilloconstrictor fibers first, as in uncal herniation.
- **Diabetes mellitus (diabetic oculomotor palsy)**
 - a. frequently affects the oculomotor nerve, damaging the central fibers and sparing the pupilloconstrictor fibers

VI. TROCHLEAR NERVE (CN IV) (SEE FIGURES 1.7 AND 10.3)

A. General characteristics of CN IV

- a pure **GSE** nerve that **innervates the superior oblique**, which **depresses, intorts, and abducts** the eye.
- arises from the contralateral trochlear nucleus of the midbrain.

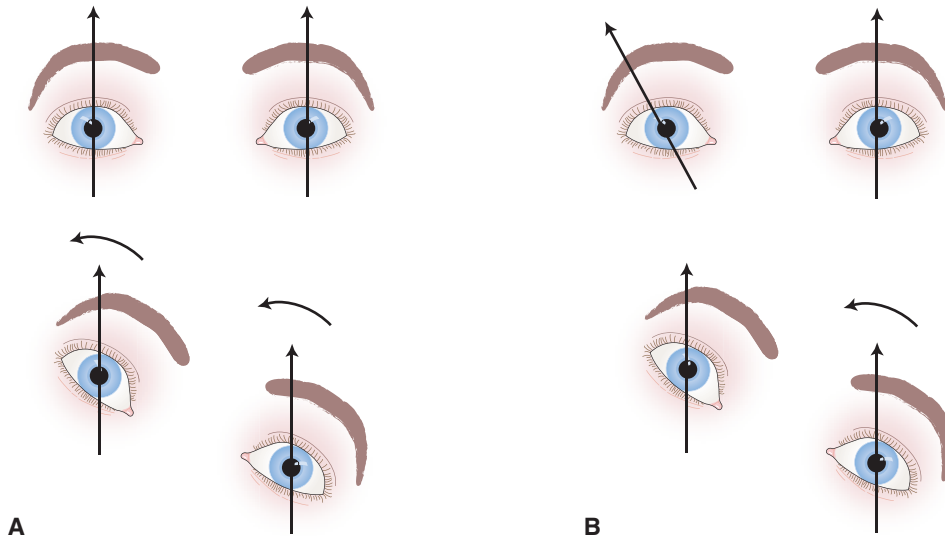


FIGURE 10.4. Paralysis of the right superior oblique. **(A)** A pair of eyes with normal extorsion and intorsion movements. Tilting the chin to the right side results in compensatory intorsion of the left eye and extorsion of the right eye. **(B)** Paralysis of the right superior oblique results in extorsion of the right eye, causing diplopia. Tilting the chin to the right side results in compensatory intorsion of the left eye, thus permitting binocular alignment.

- decussates within the midbrain and exits the brainstem on its posterior surface, caudal to the inferior colliculus.
- encircles the midbrain in the subarachnoid space, passes through the lateral wall of the cavernous sinus, and enters the orbit via the superior orbital fissure.

B. Clinical correlations: CN IV paralysis (Figure 10.4)

- results in the following conditions:
 1. **Extorsion of the eye and weakness of downward gaze**
 2. **Vertical diplopia**, which increases when looking down
 3. **Head tilting**, to compensate for extorsion

VII. TRIGEMINAL NERVE (CN V) (SEE FIGURES 1.1, 1.7, 10.4, 10.2, AND 10.3; SEE CHAPTER 11)

A. General characteristics of CN V

- contains general somatic afferent (**GSA**) and special visceral efferent (**SVE**) fibers.
- innervates the **muscles of mastication** and mediates **general sensation** from the face, eye, and nasal and oral cavities.
- the nerve of the first pharyngeal arch (mandibular).
- exits the brainstem from the pons.
- contains first-order sensory neurons in the trigeminal ganglion and in the mesencephalic nucleus.
- contains motor neurons in the trigeminal motor nucleus of the rostral pons.
- three divisions: **ophthalmic** (CN V₁), **maxillary** (CN V₂), and **mandibular** (CN V₃) (see Figures 11.1 and 11.2; see Chapter 11 I A 1–3).
 1. **GSA component** (see Figure 11-1)
 - provides **sensory innervation** to the face, mucous membranes of the nasal and oral cavities and frontal sinus, teeth, hard palate, soft palate, and deep structures of the head (proprioception from muscles and the temporomandibular joint).

- innervates the dura of the anterior and middle cranial fossae.
 - innervates the external ear with CN VII, CN IX, and CN X.
2. **SVE component**
- innervates the **muscles of mastication** (temporalis, masseter, lateral and medial pterygoids), the **tensor tympani** and **tensor palati**, the **mylohyoid**, and the **anterior belly of the digastric**.

B. Clinical correlations: lesions of CN V

- result in the following conditions:
 1. **Loss of general sensation** from the face and mucous membranes of the oral and nasal cavities
 2. **Loss of the corneal reflex** (afferent limb, CN V₁)
 3. **Flaccid paralysis of the muscles of mastication**
 4. **Deviation of the jaw to the weak side** due to the unopposed action of the opposite lateral pterygoid
 5. **Paralysis of the tensor tympani**, leading to hypacusis (partial deafness to low-pitched sounds)

VIII. ABDUCENT NERVE (CN VI) (SEE FIGURES 1.1, 1.7, AND 10.3)

A. General characteristics of CN VI

- a pure **GSE** nerve that innervates the lateral rectus, which **abducts the eye**.
- arises from the abducent nucleus of the caudal pons.
- exits the brainstem from the inferior pontine sulcus.
- passes through Dorello's canal and the cavernous sinus to enter the orbit via the superior orbital fissure.

B. Clinical correlations: CN VI paralysis

- results in the following conditions:
 1. **Convergent strabismus (esotropia)**, with inability to abduct the eye because of the unopposed action of the medial rectus.
 2. **Horizontal diplopia**, with maximum separation of the double images when looking toward the paretic lateral rectus.

IX. FACIAL NERVE (CN VII) (SEE FIGURES 1.1, 1.7, 10.2, 10.3, AND 10.5)

A. General characteristics of CN VII

- contains **GSA**, **SVA**, **SVE**, and **GVE** fibers.
- mediates **facial movements**, **taste**, **salivation**, and **lacrimation**.
- the nerve of the second pharyngeal arch.
- includes the **facial nerve proper** (motor division), which contains the SVE fibers that innervate the muscles of facial expression.
- includes the **intermediate nerve** (sensory division), which contains GSA, SVA, and GVE fibers. All first-order sensory neurons are found in the geniculate ganglion within the temporal bone.
- exits the brainstem in the cerebellopontine (CP) angle.
- enters the internal auditory meatus and the facial canal.
- exits the facial canal and skull via the **stylomastoid foramen**.

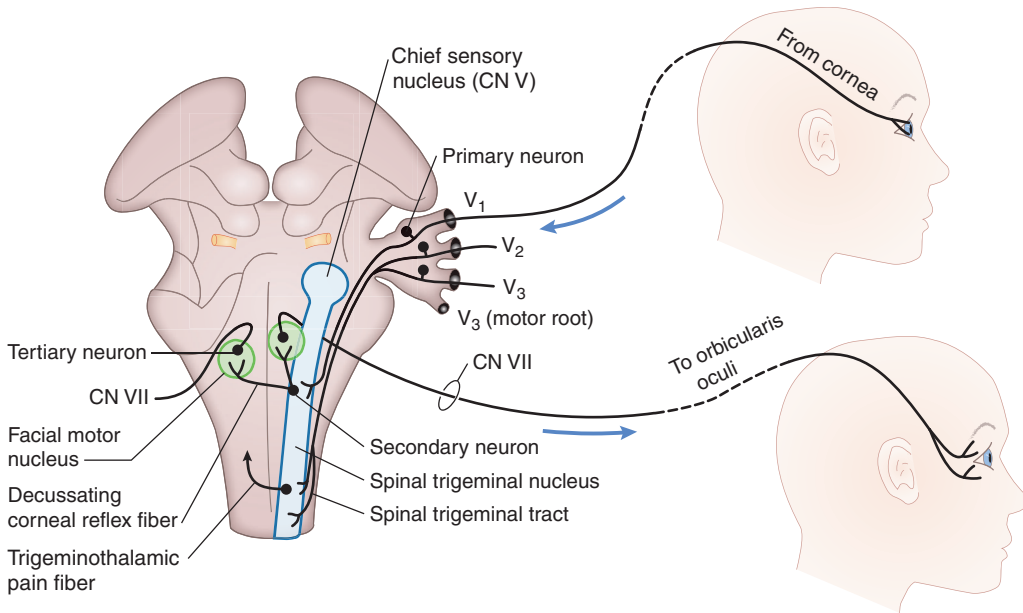


FIGURE 10.5. The corneal reflex pathway showing the three neurons and decussation. This reflex is consensual, like the pupillary light reflex. Second-order pain neurons are found in the caudal division of the spinal trigeminal nucleus. Second-order corneal reflex neurons are found at more rostral levels. (Modified from Fix JD. *High-Yield Neuroanatomy*. 3rd ed. Philadelphia, PA: Lippincott Williams & Wilkins; 2005:93.)

1. GSA component

- has cell bodies in the geniculate ganglion.
- innervates the **posterior surface of the external ear** via the posterior auricular branch of the facial nerve.
- projects centrally to the spinal trigeminal tract and nucleus.

2. SVA component

- has cell bodies in the geniculate ganglion.
- projects centrally to the solitary tract and nucleus.
- innervates the **taste buds** from the anterior two-thirds of the tongue via:

3. Chorda tympani (Figure 10.6)

- located in the tympanic cavity medial to the tympanic membrane and lateral to the malleus.
- contains **SVA** and **general visceral afferent (GVA)** fibers.
- joins the lingual nerve (a branch of CN V₃).

4. GVE component

- a parasympathetic component that innervates the **lacrimal, submandibular, and sublingual glands**.

- contains preganglionic neurons in the superior salivatory nucleus of the caudal pons.

a. Lacrimal pathway (see Figure 10.6)

- begins in the superior salivatory nucleus, which projects via the intermediate nerve, the greater petrosal nerve, and the nerve of the pterygoid canal to the pterygopalatine ganglion.
- continues as the postganglionic neurons of the pterygopalatine ganglion project through the inferior orbital fissure and via the zygomatic nerve (a branch of CN V₂) and the lacrimal nerve (a branch of CN V₁) to innervate the lacrimal gland.

b. Submandibular pathway (see Figure 10.6)

- begins in the superior salivatory nucleus, which projects via the intermediate nerve and chorda tympani to the submandibular ganglion.

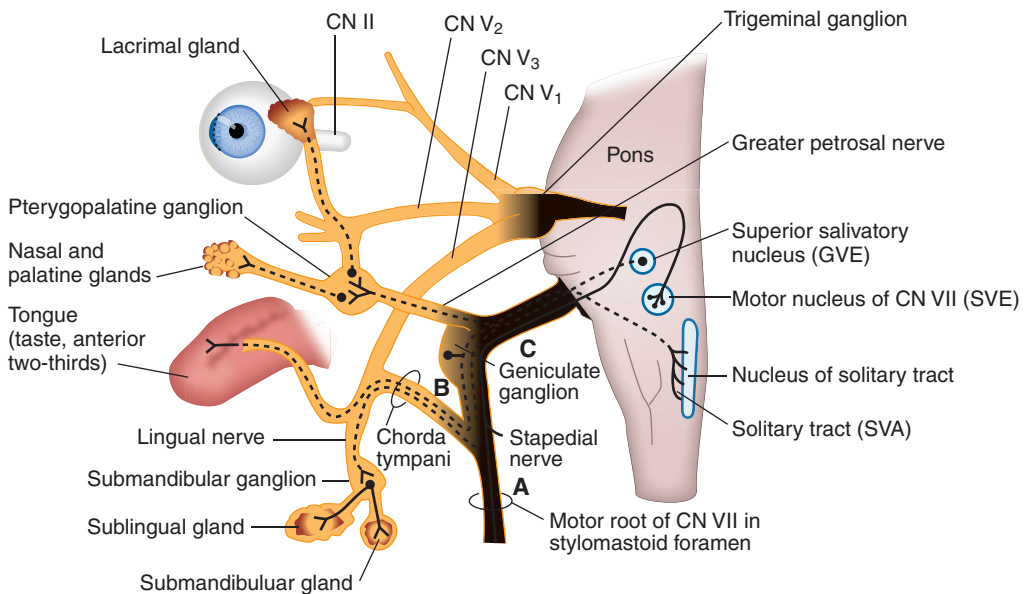


FIGURE 10.6. Functional components of the facial nerve (CN VII). The intermediate nerve is the sensory and visceromotor division of the seventh nerve. **A**, **B**, and **C** indicate three lesions of the nerve. Lesion **A** is at the stylomastoid foramen and spares lacrimation, nasal and palatine secretion, taste to the anterior two-thirds of the tongue, salivation, and the stapedial reflex; the patient has a lower motor neuron lesion involving the muscles of facial expression. Lesion **B** is between the geniculate ganglion and the chorda tympani and spares lacrimation and secretion from the nasal palatine glands. Lesion **C** is proximal to the geniculate ganglion and is total. *GVE* = general visceral efferent; *SVA* = special visceral afferent; *SVE* = special visceral efferent.

- continues as the postganglionic neurons of the submandibular ganglion, which project to and innervate the submandibular and sublingual glands via the lingual nerve (a branch of CN V₃).

5. SVE component

- arises from the facial motor nucleus of the caudal pons and exits the brainstem in the CP angle.
- enters the internal auditory meatus, traverses the facial canal, sends a branch to the stapedius, and exits the skull via the stylomastoid foramen.
- innervates the **muscles of facial expression**, the **stylohyoid**, the **posterior belly of the digastric**, and **stapedius**.

B. Clinical correlations: lesions of CN VII (see Figure 10.6)

- result in the following conditions:
 1. **Flaccid paralysis** of the muscles of facial expression (upper and lower face)
 2. **Loss of the corneal (blink) reflex** (efferent limb), which may lead to corneal ulceration (keratitis paralytica)
 3. **Loss of taste** (ageusia) from the anterior two-thirds of the tongue
 4. **Hyperacusis** (increased acuity to sounds), due to stapedius paralysis
 5. **Bell's palsy** (see Figure 9.11)
 - caused by trauma to the nerve within the facial canal.
 - a lower motor neuron (LMN) lesion with paralysis of all muscles of facial expression.
 6. **Bell phenomenon**
 - normally seen in about 75% of population.
 - occurs when trying to close the eyes—the affected eye looks up and out.
 - observable because of failure of orbicularis oculi to close eyelids.

7. **Central facial palsy** (supranuclear palsy)
 - results from transection of corticobulbar fibers in the internal capsule.
 - results in contralateral facial weakness below the orbit.
 - an upper motor neuron (UMN) lesion affecting the muscles of the lower face.
8. **Crocodile tears syndrome** (lacrimation during eating)
 - caused by a facial nerve lesion proximal to the geniculate ganglion. Regenerating preganglionic salivatory fibers are misdirected to the pterygopalatine ganglion, which projects to the lacrimal gland.

X. VESTIBULOCOCHLEAR NERVE (CN VIII) (SEE FIGURES 1.1, 1.7, AND 10.2)

- maintains balance and mediates hearing.
- consists of two functional divisions: the vestibular nerve and the cochlear nerve.
- a pure SSA nerve.
- exits the brainstem at the CP angle.
- enters the internal auditory meatus and is confined to the temporal bone.

A. Vestibular nerve (see Chapters 14 II C 6 and 15 I)

1. **General characteristics of the vestibular nerve**
 - plays a role in **equilibrium** and **balance**.
 - associated functionally with the cerebellum (flocculonodular lobe).
 - regulates **compensatory eye movements**.
 - has first-order sensory bipolar neurons in the vestibular ganglion of the internal auditory meatus.
 - projects peripheral processes to the hair cells of the cristae ampullares of the semi-circular ducts and into hair cells of the utricular and saccular maculae.
 - projects central processes to the four vestibular nuclei of the brainstem and to the flocculonodular lobe of the cerebellum.
 - conducts efferent fibers to hair cells from the brainstem.
2. **Clinical correlation: lesions of the vestibular nerve**
 - result in disequilibrium, vertigo, and nystagmus.

B. Cochlear nerve (see Chapter 14 III C)

1. **General characteristics of the cochlear nerve**
 - serves **audition** (hearing).
 - has first-order sensory bipolar neurons in the spiral (cochlear) ganglion of the modiolus of the cochlea, within the temporal bone.
 - projects peripheral processes to the hair cells of the organ of Corti.
 - projects central processes to the dorsal and ventral cochlear nuclei of the brainstem.
 - conducts efferent fibers to the hair cells from the brainstem.
2. **Clinical correlations: lesions of the cochlear nerve** (see Chapter 14 V B 2)
 - result in **hearing loss** (sensorineural deafness) (destructive lesions).
 - cause **tinnitus** (irritative lesions).

XI. GLOSSOPHARYNGEAL NERVE (CN IX) (SEE FIGURES 1.1, 1.7, 10.2, AND 10.3)

A. General characteristics of CN IX

- contains **GSA**, **GVA**, **SVA**, **SVE**, and **GVE** components.
- mediates **taste** (gustation), **salivation**, and (with CN X and CN XII) **swallowing**.

- mediates **input from the carotid sinus**, which contains baroreceptors that monitor arterial blood pressure.
 - mediates **input from the carotid body**, which contains chemoreceptors that monitor the carbon dioxide and oxygen concentration of the blood.
 - the nerve of the third pharyngeal arch.
 - predominantly a sensory nerve.
 - exits the brainstem (medulla) from the postolivary sulcus with CN X.
 - exits the skull via the jugular foramen with CN X and CN XI.
1. **GSA component**
 - innervates the middle ear cavity and part of the external auditory meatus.
 - has cell bodies in the superior glossopharyngeal ganglion.
 - projects its central processes to the spinal trigeminal tract and nucleus.
 2. **GVA component**
 - innervates structures derived from endoderm (e.g., foregut).
 - innervates the mucous membranes of the posterior third of the tongue, tonsil, upper pharynx (soft palate), tympanic cavity, and auditory tube.
 - innervates the carotid sinus (baroreceptors) and the carotid body (chemoreceptors).
 - has cell bodies in the inferior (petrosal) ganglion.
 - the afferent limb of the gag reflex and the carotid sinus reflex.
 3. **SVA component**
 - innervates the **taste buds** of the posterior third of the tongue.
 - has cell bodies in the inferior (petrosal) ganglion.
 - projects its central processes to the solitary tract and nucleus.
 4. **SVE component**
 - innervates the stylopharyngeus.
 - arises from the nucleus ambiguus of the lateral medulla.
 5. **GVE component**
 - a parasympathetic component that innervates the **parotid gland**.
 - consists of preganglionic neurons in the inferior salivatory nucleus of the medulla that project, via the tympanic nerve and the lesser petrosal nerve to the otic ganglion; postganglionic fibers from the otic ganglion project to the parotid gland via the auriculotemporal nerve (CN V₃).

B. Clinical correlations: lesions of CN IX

1. Loss of the gag (pharyngeal) reflex (interruption of afferent limb)
2. Loss of the carotid sinus reflex (interruption of the sinus nerve)
3. Loss of taste from the posterior third of the tongue
4. Glossopharyngeal neuralgia

XII. VAGAL NERVE (CN X) (SEE FIGURES 1.1, 1.7, 10.2, AND 10.3)

A. General characteristics of CN X

- contains **GSA, GVA, SVA, SVE, and GVE** components.
 - mediates **phonation, swallowing** (with CN IX and CN XII), **elevation of the palate**, and **taste**.
 - innervates **viscera of the neck, thorax, and abdomen**.
 - the nerve of the fourth and sixth branchial arches.
 - exits the brainstem (medulla) from the postolivary sulcus.
 - exits the skull via the jugular foramen with CN IX and CN XI.
1. **GSA component**
 - innervates the infratentorial dura (with C2 and C3) posterior surface of the external ear, external auditory meatus, and tympanic membrane.

- has cell bodies in the superior (jugular) ganglion.
- projects its central processes to the spinal trigeminal tract and nucleus.
- 2. **GVA component**
 - innervates the mucous membranes of the pharynx, larynx, esophagus, trachea, and thoracic and abdominal viscera (to the mid-transverse colon).
 - has cell bodies in the inferior (nodose) ganglion.
 - projects its central processes to the solitary tract and nucleus.
- 3. **SVA component**
 - innervates the **taste buds** over the **epiglottis** and soft palate.
 - has cell bodies in the inferior (nodose) ganglion.
 - projects its central processes to the solitary tract and nucleus.
- 4. **SVE component**
 - innervates the pharyngeal arch muscles of the larynx and pharynx, striated muscle of the upper esophagus, musculus uvulae, and levator palati and palatoglossus.
 - arises from the nucleus ambiguus in the lateral medulla.
 - provides the efferent limb of the gag reflex.
- 5. **GVE component** (see Figure 20.2)
 - innervates the **viscera of the neck** and the **thoracic and abdominal cavities** as far as the mid-transverse colon.
 - consists of preganglionic parasympathetic neurons in the dorsal motor nucleus of the vagus, which project to the intramural ganglia of the viscera.

B. Clinical correlations: lesions of CN X (Figure 10.7)

- result in the following conditions:
 1. **Ipsilateral paralysis** of the soft palate, pharynx, and larynx leading to **dysphonia** (hoarseness), **dyspnea**, **dysarthria**, and **dysphagia**
 2. Loss of the gag (palatal) reflex (efferent limb)
 3. Anesthesia of the pharynx and larynx, leading to unilateral loss of the cough reflex
 4. Aortic aneurysms and tumors of the neck and thorax
 - frequently compress the vagal nerve.

XIII. ACCESSORY NERVE (CN XI) (SEE FIGURES 1.1, 1.7, AND 10.3)

A. General characteristics of CN XI

- not actually a cranial nerve, as it originates in the spinal cord.
- contains the **SVE** component.
- mediates **head and shoulder movement**.
- arises from the anterior horn of cervical segments C1 to C6.
- spinal roots exit the spinal cord laterally between the anterior and posterior roots, ascend through the foramen magnum, and exit the skull via the jugular foramen.
- innervates the **sternocleidomastoid** (with C2) and **trapezius** (with C3 and C4).

B. Clinical correlations: lesions of CN XI

- result in the following conditions:
 1. **Paralysis of the sternocleidomastoid muscle**
 - results in difficulty in turning the head to the side opposite the lesion.
 2. **Paralysis of the trapezius muscle**
 - results in a shoulder droop.
 - results in the inability to shrug the ipsilateral shoulder.

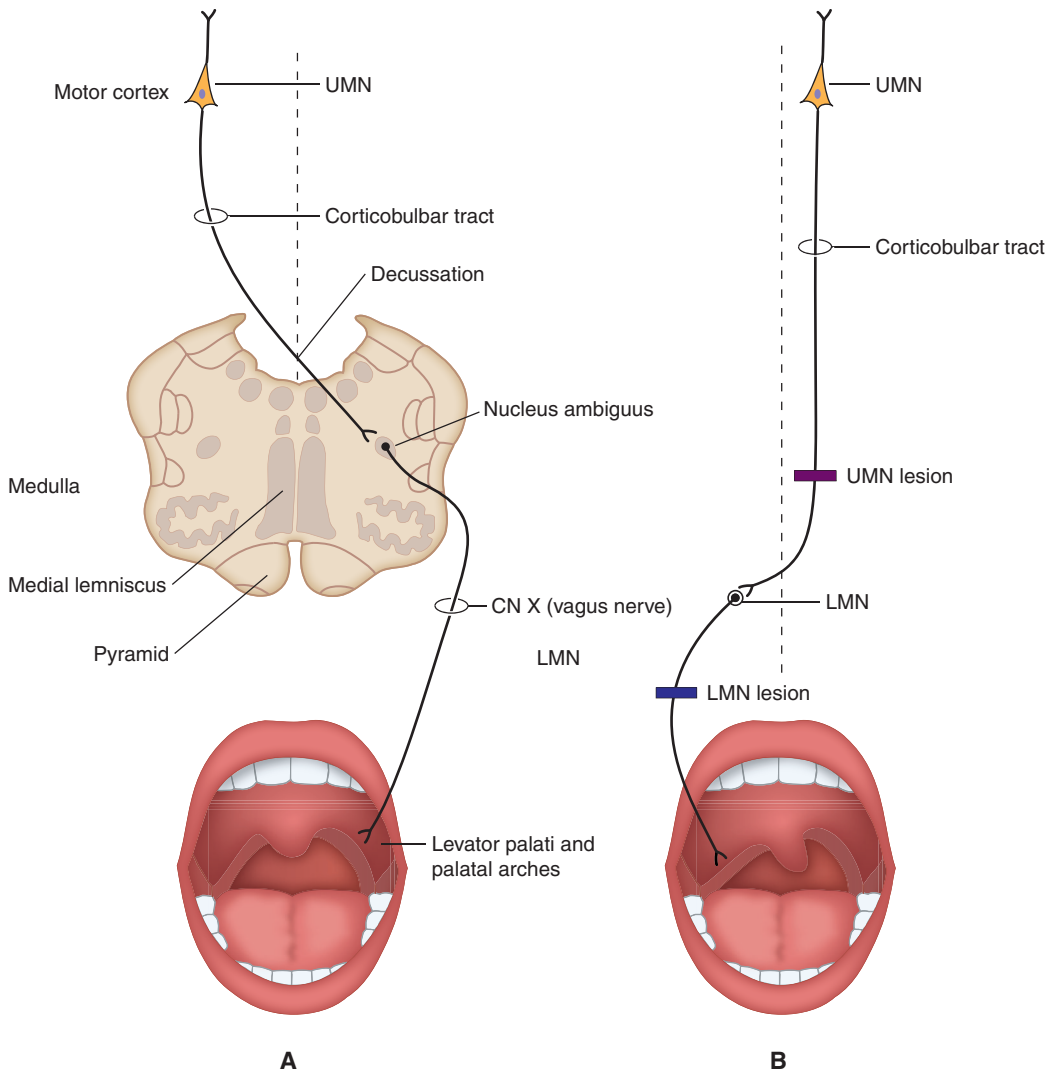


FIGURE 10.7. Innervation of the palatal arches and uvula. Sensory innervation is mediated by the glossopharyngeal nerve (CN IX). Motor innervation of the palatal arches and uvula is mediated by the vagus nerve (CN X). **(A)** A normal palate and uvula in a person saying “ah.” **(B)** A patient with an upper motor neuron (UMN) lesion (left) and a lower motor neuron (LMN) lesion (right). When this patient says “ah,” the palatal arches sag. The uvula deviates toward the intact (left) side. (Modified from DeMyer WE. *Technique of the Neurological Examination; A Programmed Text*. 4th ed. New York, NY: McGraw-Hill; 1994:6–9, 191.)

XIV. HYPOGLOSSAL NERVE (CN XII) (SEE FIGURES 1.1, 1.7, AND 10.3)

A. General characteristics of CN XII

- mediates **tongue movement**.
- a pure **GSE** nerve.
- arises from the hypoglossal motor nucleus of the medulla.
- exits the medulla in the preolivary sulcus.

- exits the skull via the hypoglossal canal.
- innervates **intrinsic and extrinsic muscles of the tongue.**

B. Clinical correlations: CN XII (Figure 10.8)

- When it is transected, **hemiparalysis of the tongue** results.
- The tongue points toward the weak side due to the unopposed action of the opposite genioglossus upon protrusion.

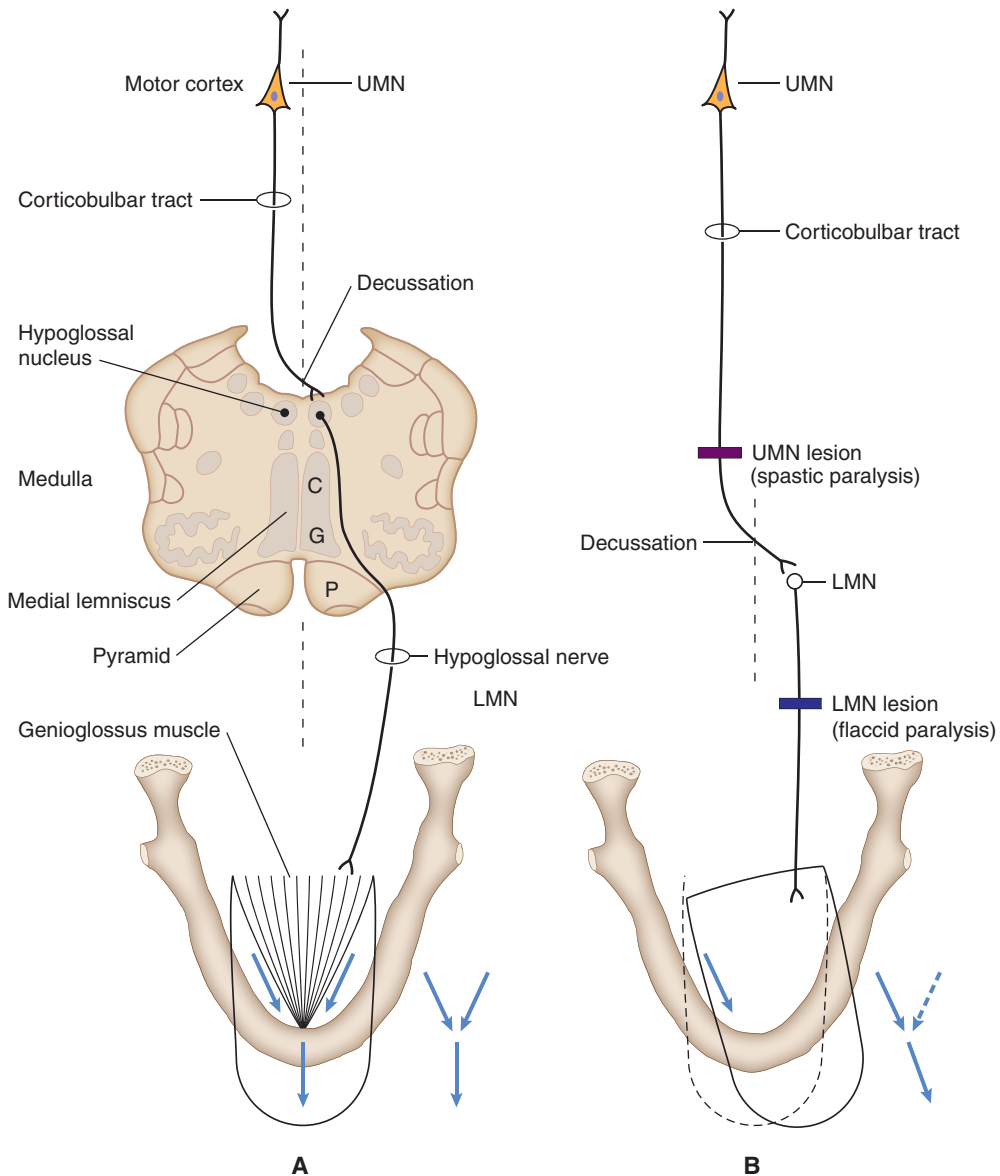


FIGURE 10.8. Motor innervation of the tongue. Corticobulbar fibers project predominantly to the contralateral hypoglossal nucleus. An upper motor neuron (UMN) lesion causes deviation of the protruded tongue to the weak (contralateral) side. A lower motor neuron (LMN) lesion causes deviation of the protruded tongue to the weak (ipsilateral) side. (A) Normal tongue. (B) Tongue with UMN and LMN lesions. (Modified from DeMyer WE. *Technique of the Neurological Examination; A Programmed Text*. 4th ed. New York, NY: McGraw-Hill; 1994:6–11, 195.)

Review Test

1. A 50-year-old family physician has vertical diplopia; the man feels unsure when descending stairs. He can eliminate the double vision by tilting his chin toward the paretic side. Which of the following extraocular muscles is responsible for the ocular malalignment?

- (A) Inferior rectus
- (B) Inferior oblique
- (C) Lateral rectus
- (D) Superior oblique
- (E) Superior rectus

2. Which cranial nerve's damage result in anosmia?

- (A) I
- (B) II
- (C) III
- (D) IV
- (E) V

3. A 50-year-old retired army major complained of severe pain in the ear and throat. Pain was episodic and triggered by swallowing, chewing, coughing, and laughing. Symptoms included loss of gag (pharyngeal) reflex; analgesia and anesthesia in the region of the tonsils; and dysphagia. Which cranial nerve's lesion produces these neurologic deficits?

- (A) Facial
- (B) Glossopharyngeal
- (C) Hypoglossal
- (D) Trigeminal
- (E) Vagal

4. Which cranial nerve's fibers are myelinated by oligodendrocytes?

- (A) I
- (B) II
- (C) III
- (D) VII
- (E) X

5. A 25-year-old woman's neck was injured in an automobile accident. At examination, she reports difficulty in turning her head away from the side of her neck that was injured. She also has a visible shoulder droop. Which nerve was likely damaged?

- (A) VIII
- (B) IX
- (C) X
- (D) XI
- (E) XII

Questions 6 to 10

The response options for items 6 to 10 are the same. Select one answer for each item in the set.

- (A) Accessory nerve
- (B) Facial nerve
- (C) Glossopharyngeal nerve
- (D) Trigeminal nerve
- (E) Vagal nerve

Match each description with the appropriate nerve.

- 6. Innervates the parotid gland
- 7. Is the efferent limb of the corneal reflex
- 8. Is the efferent limb of the gag reflex
- 9. Innervates the infratentorial dura
- 10. Is a pure motor nerve

Questions 11 to 16

The response options for items 11 to 16 are the same. Select one answer for each item in the set.

- (A) Foramen magnum
- (B) Foramen ovale
- (C) Foramen rotundum
- (D) Foramen spinosum
- (E) Innominate canal

- (F) Jugular foramen
- (G) Stylomastoid foramen
- (H) Superior orbital fissure

Match the anatomic structure(s) below with the foramen or fissure through which it passes.

- 11. A branch of the maxillary artery
- 12. The nerve that innervates the buccinator muscle
- 13. The nerve that innervates the skin of the upper lip
- 14. CN IX, CN X, and CN XI
- 15. The nerve that projects to the otic ganglion
- 16. Four cranial nerves traverse this orifice

Answers and Explanations

1–D. The superior oblique depresses, abducts, and intorts the eye. Paralysis of this muscle results in extorsion and weakness of downward gaze. Head tilting compensates for extorsion.

2–A. Anosmia, a loss of olfactory sensation, results from damage to the olfactory nerve, CN I.

3–B. Glossopharyngeal neuralgia has the following neurologic deficits: excruciating, paroxysmal pain that comes from the tonsillar area and radiates into the ear; loss of taste sensation from the posterior third of the tongue; and loss of palatal and gag reflexes. Potential causes of glossopharyngeal impairment include fractures of the skull base, thrombosis of the sigmoid sinus, tumors, and aneurysms of the posterior fossa. Pain may be triggered by a blood vessel pressing on the nonmyelinated root of the glossopharyngeal nerve, and relocation of the vessel may alleviate symptoms. Treatment is with carbamazepine and other antiepileptic drugs.

4–B. The fibers of the optic nerve (CN II) are myelinated by oligodendrocytes. This is an important distinction from the other cranial nerves, whose fibers are myelinated by Schwann cells because the optic nerve is considered a tract of the central nervous system and thus incapable of regeneration.

5–D. The accessory nerve (CN XI) mediates head and shoulder movement. Lesions result in paralysis of the sternocleidomastoid, making it difficult to turn the head to the side opposite the lesion, and paralysis of the trapezius, resulting in a shoulder droop and inability to shrug the shoulder on the side of the lesion.

6–C. The glossopharyngeal nerve (CN IX) innervates the parotid gland via the tympanic and lesser petrosal nerves, the otic ganglion, and the auriculotemporal nerve.

7–B. The facial nerve (CN VII) provides the efferent limb of the corneal reflex (orbicularis oculi muscle).

8–E. The vagus nerve (CN X) provides the efferent limb of the gag reflex (muscles of the soft palate). The glossopharyngeal nerve provides the afferent limb of the gag reflex.

9–E. The vagus nerve (CN X) innervates, via the recurrent meningeal ramus, the infratentorial dura (the dura of the posterior cranial fossa).

10–A. The accessory nerve (CN XI) is a pure SVE motor nerve. It innervates the sternocleidomastoid and upper parts of the trapezius.

11–D. The middle meningeal artery, a branch of the maxillary artery, traverses the foramen spinosum.

12–G. The facial nerve (CN VII) exits the base of the skull via the stylomastoid foramen; CN VII innervates the muscles of facial expression.

13–C. The maxillary nerve (CN V₂) exits the skull via the foramen rotundum.

14–F. CN IX, CN X, and CN XI exit the posterior cranial fossa via the jugular foramen.

15–E. The lesser petrosal nerve of CN IX passes through the innominate canal to synapse with postganglionic neurons of the otic ganglion. The innominate canal lies between the foramen ovale and the foramen spinosum.

16–H. CN III, CN IV, CN VI, and CN V₁ pass through the superior orbital fissure.

Objectives

- List the components of the trigeminal system.
- List the divisions of the trigeminal nerve and the contents of each.
- Describe the ascending trigeminothalamic pathways, include a description of the location of their primary, secondary and tertiary neurons, the modalities each is concerned with and the nerves that send fibers into the system.
- List the nuclei associated with the trigeminal system, include a description of the location and function of each.
- Recognize the unique characteristics of the mesencephalic nucleus.
- Recognize the spinal cord homologs for each component of the trigeminal system.

I. TRIGEMINAL NERVE (CN V) (FIGURE 11.1; SEE FIGURES 1.1, 9.1, AND 9.7)

- the largest cranial nerve.
- connects to the brainstem at the pons.
- the nerve of the first branchial arch (mandibular nerve).
- contains sensory (general somatic afferent [GSA]) and motor (special visceral efferent [SVE]) fibers.
- provides sensory innervation to the face and oral cavity.
- innervates the dura mater of the anterior and middle cranial fossae.
- innervates the muscles of mastication.
- consists of a large ganglion that gives rise to three major divisions: **ophthalmic**, **maxillary**, and **mandibular**.

A. Trigeminal (or semilunar or gasserian) ganglion

- located in the trigeminal fossa of the temporal bone in the middle cranial fossa.
- covered by dura mater—forms the trigeminal cave.
- contains pseudounipolar neurons, which are first-order neurons for the trigeminothalamic tracts.

1. Ophthalmic nerve (CN V₁)

- lies in the lateral wall of the **cavernous sinus**.
- enters the orbit via the **superior orbital fissure**.
- innervates the forehead, dorsum of the nose, upper eyelid, orbit (cornea and conjunctiva), mucous membranes of the nasal vestibule and frontal sinus, and the cranial dura.
- mediates the afferent limb of the **corneal blink reflex**.

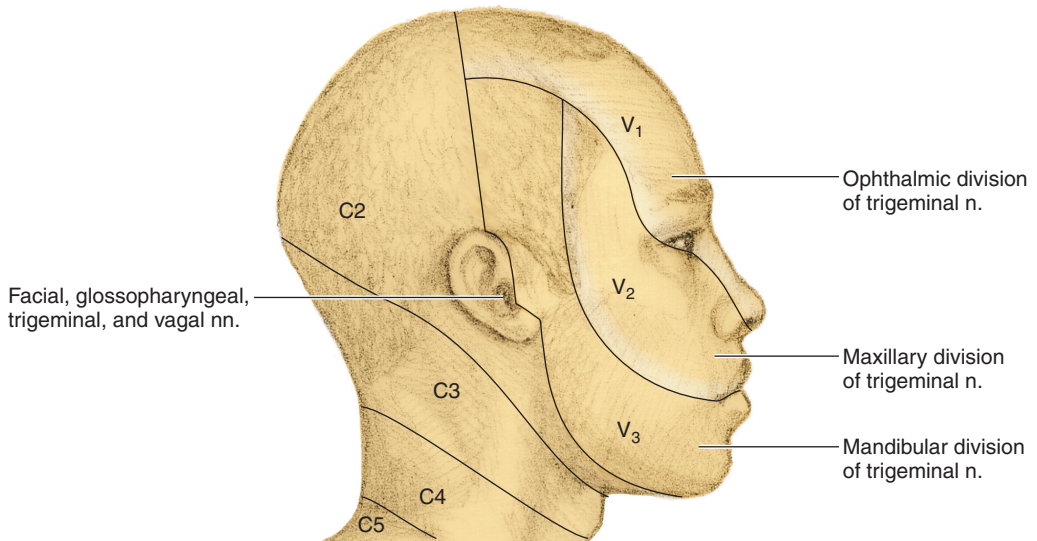


FIGURE 11.1. The cutaneous innervation of the head and neck. There is very little overlap between the three dermatomes of the trigeminal nerve (CN V).

2. Maxillary nerve (CN V₂)

- lies in the lateral wall of the **cavernous sinus**.
- exits the cranial vault via the **foramen rotundum**.
- innervates the upper lip and cheek, lower eyelid, anterior portion of the temple, paranasal sinuses, oral mucosa of the upper mouth, nose, pharynx, gums, teeth, hard palate, soft palate, and cranial dura.

3. Mandibular nerve (CN V₃)

- exits the cranial vault via the **foramen ovale**.
- consists of a motor component that innervates the **muscles of mastication** (temporalis, masseter, and lateral and medial pterygoids); two suprahyoid muscles, the **mylohyoid** and the **anterior belly of the digastric**; and the **tensor tympani** and **tensor palati**.
- consists of a sensory component that innervates the lower lip and chin, posterior portion of the temple, external auditory meatus and tympanic membrane, external ear, teeth of the lower jaw, oral mucosa of the cheeks and the floor of the mouth, anterior two-thirds of the tongue, temporomandibular joint, and cranial dura.

B. Cranial nerves V, VII, IX, and X

- contribute GSA fibers from the ear to the trigeminal system.
- use the spinal trigeminal tract and nucleus.

C. Spinal trigeminal tract

- extends from C3 to the level of the trigeminal nerve in the mid pons.
- a homolog of the posterolateral tract.
- receives pain, temperature, and light touch inputs from CN V, CN VII, CN IX, and CN X.
- transection (**tractotomy**) results in ipsilateral facial anesthesia.
- projects to the spinal trigeminal nucleus as follows:
 1. **Pain fibers** terminate in the caudal third of the spinal trigeminal nucleus.
 2. **Corneal reflex fibers** terminate in the rostral two-thirds of the spinal trigeminal nucleus.

II. ASCENDING TRIGEMINOTHALAMIC TRACTS

- convey GSA information from the face, oral cavity, and dura mater to the thalamus.
- consist of a three-neuron chain.

- have their first-order neurons, which are pseudounipolar ganglion cells, in the trigeminal ganglion and in the sensory ganglia of CN VII, CN IX, and CN X.

A. Anterior trigeminothalamic tract (Figure 11.2)

- serves as a pain, temperature, and light touch pathway from the face and oral cavity.
- contains GSA fibers from CN V, CN VII, CN IX, and CN X.
- receives input from free nerve endings and Merkel tactile disks.
- receives discriminative tactile and pressure input from the contralateral chief sensory nucleus of CN V, which terminates in the ventral posteromedial (VPM) nucleus of the thalamus.
- ascends to the contralateral sensory cortex via three neurons.

1. First-order neurons

- located in peripheral ganglia associated with CNs V, VII, IX and X.
- mediate pain and temperature sensation and give rise to axons that descend in the spinal trigeminal tract.
- mediate light touch sensation and give rise to bifurcating axons that ascend and descend in the spinal trigeminal tract.
- synapse with second-order neurons in the spinal trigeminal nucleus.

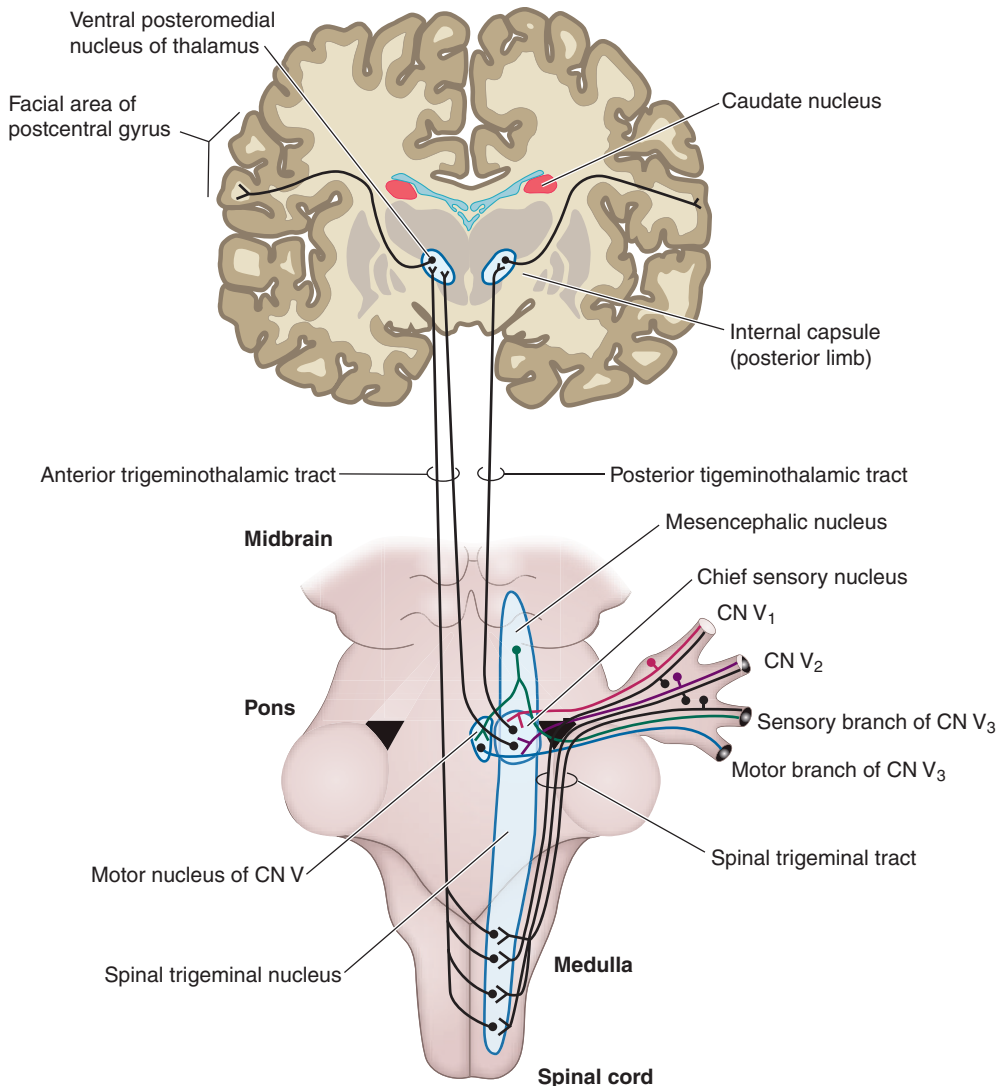


FIGURE 11.2. The anterior and posterior trigeminothalamic pathways. *CN* = cranial nerve. (Modified from Fix JD. *High-Yield Neuroanatomy*. 3rd ed. Philadelphia, PA: Lippincott Williams & Wilkins; 2005:79.)

2. Second-order neurons

- located in the spinal trigeminal nucleus.
- give rise to decussating axons that terminate in the contralateral VPM nucleus of the thalamus.
- project axons to the reticular formation and to motor cranial nerve nuclei to mediate reflexes (e.g., tearing and corneal reflexes).
- mediate painful stimuli and are found in the caudal third of the spinal trigeminal nucleus.

3. Third-order neurons

- located in the VPM nucleus.
- project via the posterior limb of the internal capsule to the face area of the postcentral gyrus (areas 3, 1, and 2).

B. Posterior trigeminothalamic tract (see Figure 11.2)

- subserves discriminative tactile and pressure sensation primarily from the oral cavity via the GSA fibers of CN V.
- receives input from Meissner and Pacini corpuscles.
- an uncrossed tract.
- the rostral equivalent of the posterior column–medial lemniscus system.
- ascends to the sensory cortex via three neurons.

1. First-order neurons

- located in the trigeminal ganglion.
- synapse in the principal sensory nucleus of CN V.

2. Second-order neurons

- located in the principal sensory nucleus of CN V.
- project to the ipsilateral VPM nucleus of the thalamus.

3. Third-order neurons

- located in the VPM nucleus.
- project via the posterior limb of the internal capsule to the face area of the postcentral gyrus (areas 3, 1, and 2).

III. TRIGEMINAL SENSORY NUCLEI (SEE FIGURES 9.1, 9.7 THROUGH 9.9, AND 11.2)

A. Chief (principal) sensory nucleus

- located in the rostral pontine tegmentum at the level of the trigeminal motor nucleus.
- receives discriminative tactile input from the face.
- projects via the uncrossed posterior trigeminothalamic tract to the VPM nucleus of the thalamus.
- projects via the crossed anterior trigeminothalamic tract to the VPM nucleus of the thalamus.
- a homolog of the posterior column nuclei of the medulla.

B. Spinal trigeminal nucleus

- located in the spinal cord (C1–C3), medulla, and pons.
- receives pain and temperature inputs from the face and oral cavity.
- projects via the crossed anterior trigeminothalamic tract to the VPM nucleus of the thalamus.

C. Mesencephalic nucleus (see Figures 9.1, 9.7 through 9.9, and 11.2)

- subserves **GSA proprioception** from the head.
- contains pseudounipolar neurons.
- receives inputs from muscle spindles and pressure and joint receptors.
- receives inputs from the muscles of mastication and extraocular muscles, the teeth and hard palate, and the temporomandibular joint.
- projects to the trigeminal motor nucleus to mediate the muscle stretch (jaw jerk) reflex and regulate the force of bite.

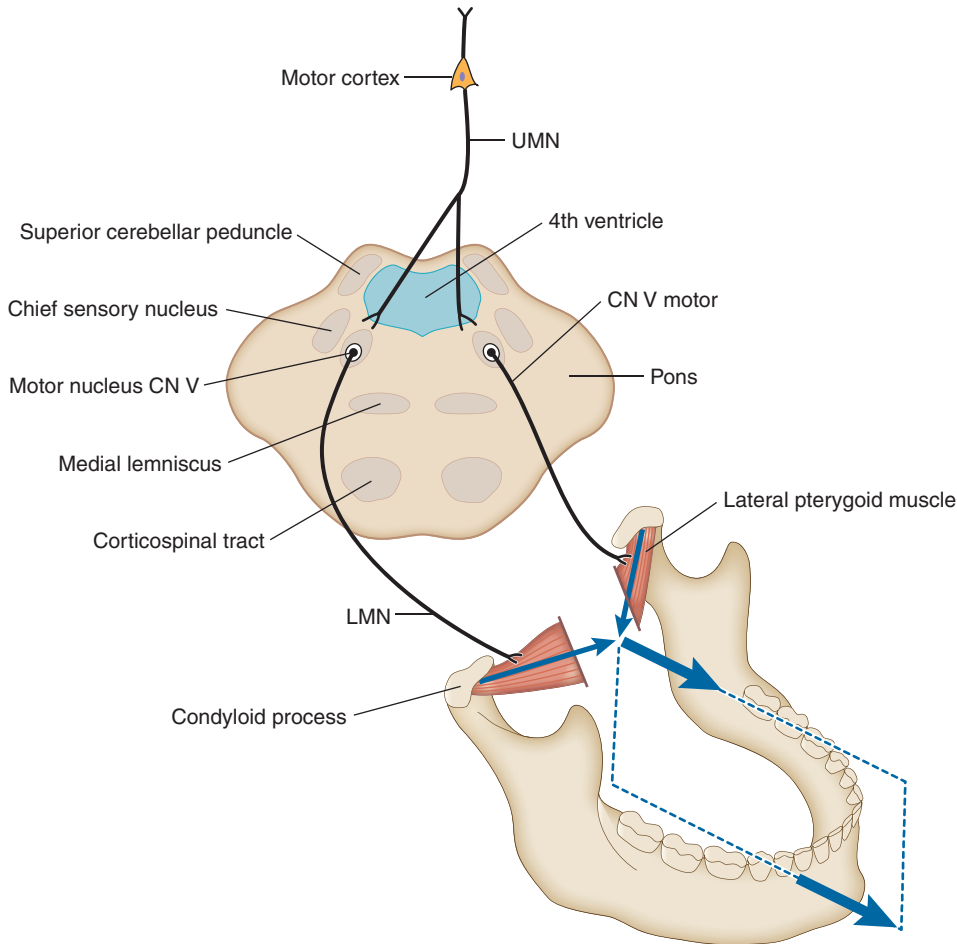


FIGURE 11.3. Function and innervation of the lateral pterygoids (LPMs). The LPM receives its innervation from the motor nucleus of the trigeminal nerve found in the rostral pons. Bilateral innervation of the LPMs results in protrusion of the mandible. The LPMs also open the jaw. Denervation of an LPM results in deviation of the mandible to the ipsilateral, or weak, side. The trigeminal motor nucleus receives bilateral corticobulbar input. *CN* = cranial nerve; *LMN* = lower motor neuron; *UMN* = upper motor neuron. (Adapted from DeMyer WE. *Technique of the Neurological Examination; A Programmed Text*. 4th ed. New York, NY: McGraw Hill; 1994:6-1, 174 with permission.)

D. Trigeminal motor nucleus (SVE) (Figure 11.3; see Figures 9.1, 9.7, and 11.2)

- located in the rostral pontine tegmentum at the level of the chief sensory nucleus.
- innervates the muscles of mastication.
- receives bilateral corticobulbar input.
- receives input from the mesencephalic nucleus.

IV. TRIGEMINOCEREBELLAR FIBERS

- project from the mesencephalic nucleus via the superior cerebellar peduncle to the dentate nucleus of the cerebellum.
- project from the chief sensory and spinal trigeminal nuclei via the inferior cerebellar peduncle to the cerebellar vermis.

V. TRIGEMINAL REFLEXES

A. Jaw jerk (masseter) reflex (Figure 11.4)

- a monosynaptic myotatic reflex.
 1. The **afferent limb** is the mandibular nerve (**CN V₃**).
 2. The **efferent limb** is the mandibular nerve (**CN V₃**).

B. Corneal reflex

- a consensual and disynaptic reflex.
- has its first-order neuron (afferent limb) in the trigeminal ganglion.
- has its second-order neuron in the rostral two-thirds of the spinal trigeminal nucleus.
- has its third-order neuron (efferent limb) in the facial motor nucleus.
 1. The **afferent limb** is the ophthalmic nerve (**CN V₁ motor**).
 2. The **efferent limb** is the facial nerve (**CN VII**).

C. Lacrimal (tearing) reflex

1. The **afferent limb** is the ophthalmic nerve (**CN V₁**); it receives impulses from the cornea and conjunctiva.
2. The **efferent limb** is the facial nerve (**CN VII**). It transmits impulses via the superior salivatory nucleus, greater petrosal nerve, pterygopalatine ganglion, and the zygomatic (CN V₂) and lacrimal (CN V₁) nerves to the lacrimal gland (see Figure 10.5).

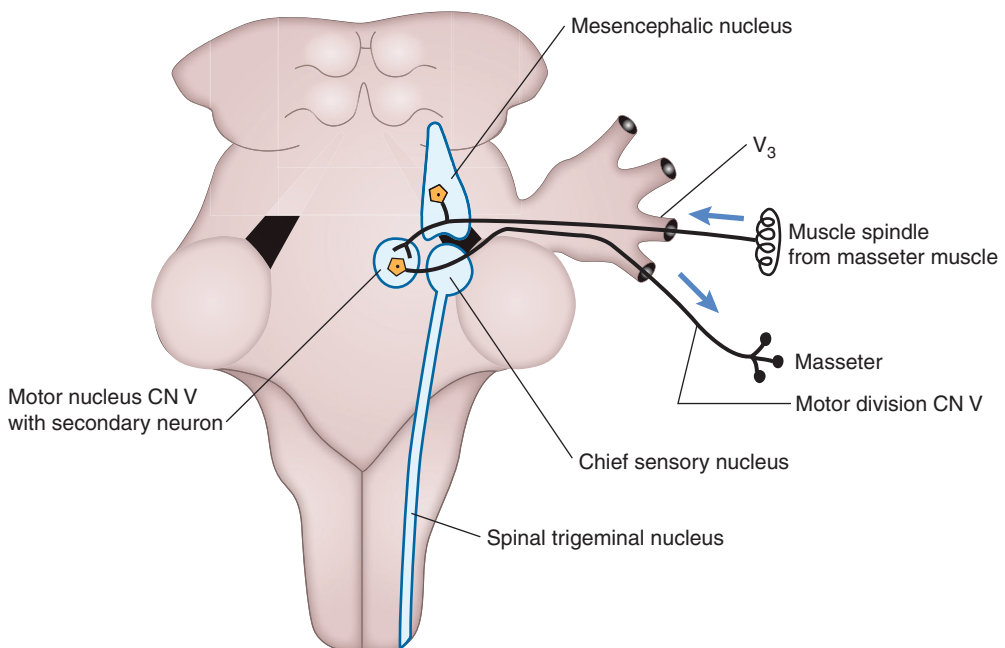


FIGURE 11.4. The jaw jerk (masseteric) reflex. The afferent limb is V₃, and the efferent limb is the motor root that accompanies V₃. First-order sensory neurons are located in the mesencephalic nucleus. The jaw jerk reflex, like all muscle stretch reflexes, is a monosynaptic myotactic reflex. CN = cranial nerve. (Modified from Fix JD. *High-Yield Neuroanatomy*. 3rd ed. Philadelphia, PA: Lippincott Williams & Wilkins; 2005:80.)

VI. CLINICAL CORRELATIONS

A. Trigeminal neuralgia (tic douloureux)

- characterized by recurrent paroxysms of **sharp, stabbing pain** in one or more branches of the trigeminal nerve on one side of the face.
- usually occurs after 50 years of age and is more common in women than in men.
- can result from a redundant loop of the superior cerebellar artery that impinges on the trigeminal root. Surgery is the treatment of choice.
- **Carbamazepine**, a **tricyclic compound** related to **imipramine**, is the drug of choice for treatment of idiopathic trigeminal neuralgia.

B. Herpes zoster ophthalmicus

- a viral infection affecting the ophthalmic nerve (CN V₁).
- corneal ulceration with infection may result in blindness.

C. Paratrigeminal (Raeder) syndrome

- occurs as a result of lesions of the trigeminal ganglion and sympathetic fibers; the lesion is usually in the parasellar region.
- results in miosis, ptosis, facial pain (similar to trigeminal neuralgia), and trigeminal palsy.
- may involve CN III, CN IV, and CN VI.

D. Central lesions of the spinal trigeminal tract and nucleus

- Can result in a **loss of sensation**, occurring in an **onion-skin distribution**.
- The face is represented somatotopically in the spinal trigeminal nucleus as a number of semi-circular territories that extend from the perioral region to the ear.
- Fibers innervating the mouth area terminate near the obex; fibers innervating the back of the head terminate in the upper cervical levels.

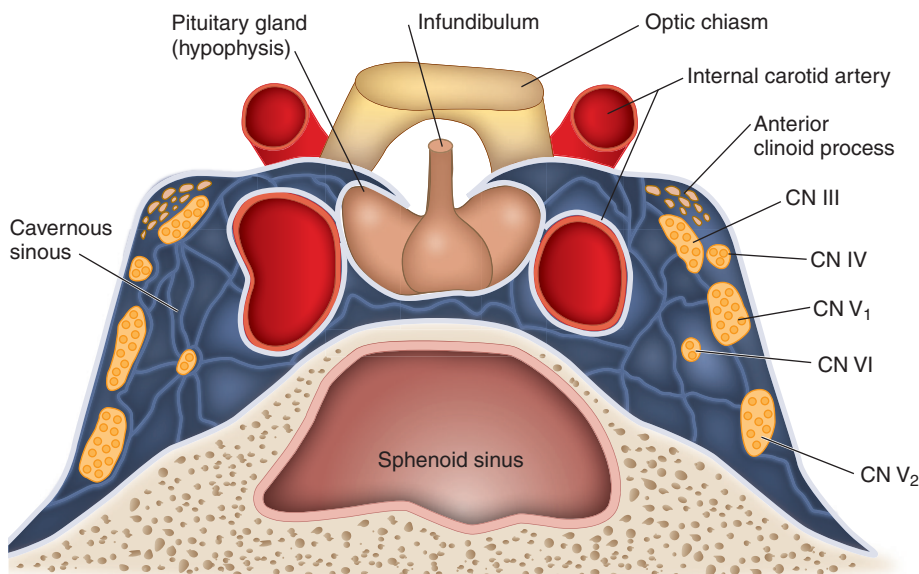


FIGURE 11.5. Diagram of the contents of the cavernous sinus. The wall of the cavernous sinus contains the ophthalmic (CN V₁) and maxillary (CN V₂) divisions of the trigeminal nerve (CN V) and the trochlear (CN IV) and oculomotor (CN III) nerves. The siphon of the internal carotid artery and the abducent nerve (CN VI) along with postganglionic sympathetic fibers lie within the cavernous sinus. (Modified from Fix JD. *High-Yield Neuroanatomy*. 3rd ed. Philadelphia, PA: Lippincott Williams & Wilkins; 2005:81.)

E. Acoustic neuroma (schwannoma)

- an extramedullary tumor of the vestibulocochlear nerve (CN VIII) that is found in the cerebellopontine angle or in the internal acoustic meatus.
- results in initial symptoms that include unilateral **tinnitus** and unilateral **hearing loss** as a result of a CN VIII lesion.
- results in symptoms that include **facial weakness** and **loss of corneal blink reflex** (efferent limb) owing to facial nerve (CN VII) involvement.
- affects the spinal trigeminal tract as the tumor expands and leads to ipsilateral **loss of pain and temperature sensation** and **loss of the corneal blink reflex**.

F. Cavernous sinus syndrome (Figure 11.5)

- may be caused by an aneurysm of the cavernous sinus.
- may involve any one or all of the following cranial nerves:
 1. **Ocular motor nerves CN III, CN IV, and CN VI**
 - Destruction of CN III results in complete **internal ophthalmoplegia** (parasympathetic paresis).
 2. **Trigeminal nerve branches of CN V₁ and CN V₂**
 3. **Postganglionic sympathetic fibers to the orbit**
 - Interruption results in **Horner syndrome**.

Review Test

1. A 55-year-old patient with idiopathic trigeminal neuralgia reports sharp, stabbing pain in the upper lip and nose. Which branch of the trigeminal nerve is affected?

- (A) Corneal
- (B) Mandibular
- (C) Maxillary
- (D) Lacrimal
- (E) Ophthalmic

2. What is the treatment drug of choice for the patient in question 1?

- (A) Carbamazepine
- (B) Clobazam
- (C) Clonazepam
- (D) Gabapentin
- (E) Lamotrigine

3. For which type of sensation does the posterior trigeminothalamic tract act as a pathway?

- (A) Cold temperature
- (B) Discriminative tactile
- (C) Extreme pain
- (D) Hot temperature
- (E) Light touch

4. Which of the following muscles opens the jaw?

- (A) Buccinator
- (B) Lateral pterygoid

- (C) Masseter
- (D) Medial pterygoid
- (E) Temporalis

5. Which one of the following nerves innervates the auricle (pinna) of the external ear?

- (A) V₁
- (B) V₂
- (C) V₃
- (D) III
- (E) VIII

6. Which pair of the following cranial nerves is likely to show problems owing to absence of lacrimal reflex?

- (A) II, V
- (B) III, VII
- (C) V, VII
- (D) V, VIII
- (E) VII, X

7. Destruction of which cranial nerve results in complete internal ophthalmoplegia?

- (A) I
- (B) II
- (C) III
- (D) IV
- (E) V

Answers and Explanations

- 1–C.** The affected part is the maxillary branch of the trigeminal nerve (CN V₂) that innervates the upper lip and cheek, inferior eyelid, anterior portion of the temple, paranasal sinuses, oral mucosa, nose, pharynx, gums, teeth hard palate, soft palate, and cranial dura.
- 2–A.** Carbamazepine is the drug of choice for treatment of idiopathic trigeminal neuralgia. It, along with lamotrigine, clonazepam, gabapentin, and clobazam, is also used to treat seizure disorders.
- 3–B.** The posterior trigeminothalamic tract subserves discriminative tactile and pressure sensation from the face and oral cavity via the GSA fibers of the trigeminal nerve (CN V). Pain, temperature, and light touch sensations are conveyed via the anterior trigeminothalamic tract.
- 4–B.** The lateral pterygoid is one of four muscles of mastication. Unlike the other muscles, it opens the mouth by depressing the jaw. It also helps the medial pterygoids in moving the jaw from side to side. The temporalis, medial pterygoid, and masseter work to close the jaw. The muscles of mastication are innervated by the trigeminal motor nucleus (SVE).
- 5–C.** The mandibular nerve, CN V₃, is a division of the trigeminal nerve (CN V) and innervates the external ear, external auditory meatus and tympanic membrane, lower lip and chin, posterior portion of the temple, teeth of the lower jaw, oral mucosa of the cheeks, floor of the mouth, anterior two-thirds of the tongue, temporomandibular joint and cranial dura.
- 6–C.** The lacrimal reflex involves the first branch of the trigeminal nerve, the ophthalmic nerve (CN V₁), and the facial nerve (CN VII). The afferent limb is CN V₁, receives impulses from the cornea and conjunctiva. The efferent limb CN VII, transmits impulses via the superior salivatory nucleus, greater petrosal nerve, pterygopalatine ganglion, and the zygomatic and lacrimal nerves to the lacrimal gland (see Figure 10.5).
- 7–C.** Destruction of CN III results in complete internal ophthalmoplegia—paralysis of the sphincter pupillae and ciliaris.

Objectives

- Describe common vascular lesions of the medulla, pons, and midbrain.
- List structures affected in the various vascular lesions of parts of the brainstem and predict the functional/clinical manifestation of each.
- Describe the characteristics of an acoustic neuroma and jugular foramen syndrome.

I. INTRODUCTION

- most frequently syndromes of arterial occlusion or circulatory insufficiency that involve the verte-brobasilar system.

II. VASCULAR LESIONS OF THE MEDULLA

- result from occlusion of the vertebral artery or its branches (i.e., the anterior and posterior spinal arteries and the posterior inferior cerebellar artery [PICA]).

A. Medial medullary syndrome (Figure 12.1A)

- results from occlusion of the anterior spinal artery.
- includes the following affected **structures** and resultant **deficits**:
 1. **Corticospinal tract**
 - contralateral hemiparesis of the trunk and extremities
 2. **Medial lemniscus**
 - contralateral loss of proprioception, discriminative tactile sensation, and vibratory sensation from the trunk and extremities
 3. **Hypoglossal nerve roots (intra-axial fibers)**
 - ipsilateral flaccid paralysis of the tongue

B. Lateral medullary syndrome (PICA syndrome; Wallenberg syndrome) (see Figure 12.1B)

- results from occlusion of the vertebral artery or one of its medullary branches (e.g., PICA).
- includes the following affected **structures** and resultant **deficits**:
 1. **Vestibular nuclei (medial and inferior)**
 - nystagmus, nausea, vomiting, and vertigo
 2. **Inferior cerebellar peduncle**
 - ipsilateral cerebellar signs (dystaxia, dysmetria, and dysdiadochokinesia)

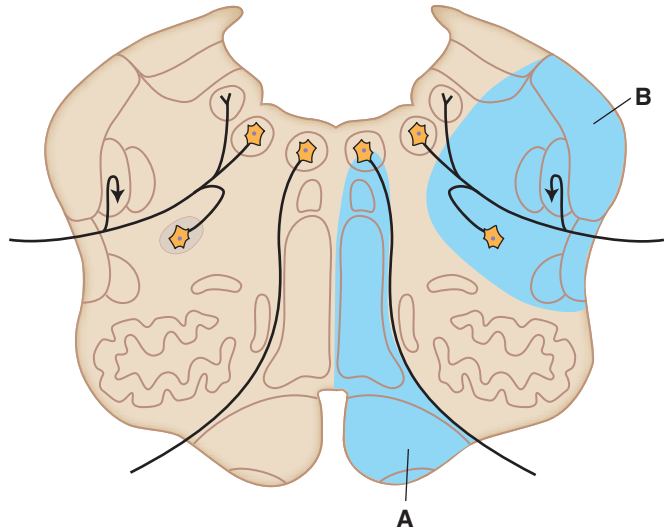


FIGURE 12.1. Vascular lesions of the caudal medulla at the level of the hypoglossal nucleus and the dorsal motor nucleus of CN X. **(A)** Medial medullary syndrome (anterior spinal artery). **(B)** Lateral medullary syndrome (PICA syndrome); *PICA* = posterior inferior cerebellar artery.

3. Nucleus ambiguus of CNs IX and X

- ipsilateral laryngeal, pharyngeal, and palatal paralysis (loss of the gag reflex [efferent limb], dysarthria, dysphagia, and dysphonia [hoarseness])

4. Glossopharyngeal nerve roots (intra-axial fibers)

- loss of the gag reflex (afferent limb)

5. Vagal nerve roots (intra-axial fibers)

- neurologic deficits same as those seen in lesion of the nucleus ambiguus

6. Spinothalamic tracts

- contralateral loss of pain and temperature sensation from the trunk and extremities

7. Spinal trigeminal nucleus and tract

- ipsilateral loss of pain and temperature sensation from the face

8. Descending sympathetic tract

- ipsilateral Horner syndrome (ptosis, miosis, hemianhidrosis, vasodilation, and apparent enophthalmos)

III. VASCULAR LESIONS OF THE PONS

- result from occlusion of the basilar artery or its branches (the anterior inferior cerebellar artery [AICA], transverse pontine arteries, and superior cerebellar artery).

A. Medial inferior pontine syndrome (Figure 12.2A)

- results from occlusion of the paramedian branches of the basilar artery.
- includes the following affected **structures** and resultant **deficits**:
 1. **Abducent nerve roots (intra-axial fibers)**
 - ipsilateral lateral rectus paralysis
 2. **Corticobulbar tracts**
 - contralateral weakness of the lower face
 3. **Corticospinal tracts**
 - contralateral hemiparesis of the trunk and extremities
 4. **Base of the pons (middle cerebellar peduncle)**
 - ipsilateral limb and gait ataxia
 5. **Medial lemniscus**
 - contralateral loss of proprioception, discriminative tactile sensation, and vibration sensation from the trunk and extremities

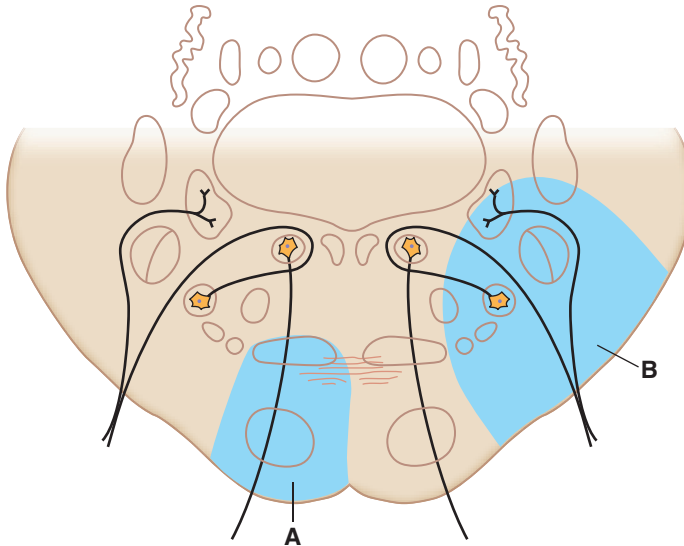


FIGURE 12.2. Vascular lesions of the caudal pons at the level of the abducent nucleus and the facial motor nucleus. **(A)** Medial inferior pontine syndrome. **(B)** Lateral inferior pontine syndrome (AICA syndrome); *AICA* = anterior inferior cerebellar artery.

B. Lateral inferior pontine syndrome (AICA syndrome) (see Figure 12.2B)

- results from occlusion of a branch of the basilar artery, AICA.
- includes the following affected **structures** and resultant **deficits**:
 1. **Facial motor nucleus and intra-axial nerve fibers**
 - ipsilateral facial nerve paralysis
 - loss of taste from the anterior two-thirds of the tongue
 - loss of the corneal and stapedial reflexes
 2. **Cochlear nuclei and intra-axial nerve fibers**
 - unilateral central nerve deafness
 3. **Vestibular nuclei and intra-axial nerve fibers**
 - nystagmus, nausea, vomiting, and vertigo
 4. **Spinal trigeminal nucleus and tract**
 - ipsilateral loss of pain and temperature sensation from the face
 5. **Middle and inferior cerebellar peduncles**
 - ipsilateral limb and gait dystaxia
 6. **Spinothalamic tracts**
 - contralateral loss of pain and temperature sensation from the trunk and extremities
 7. **Descending sympathetic tract**
 - ipsilateral Horner syndrome (ptosis, miosis, hemianhidrosis, vasodilation, and enophthalmos)

C. Lateral midpontine syndrome

- results from occlusion of a circumferential branch of the basilar artery.
- includes the following affected **structures** and resultant **deficits**:
 1. **Trigeminal nuclei and nerve root (motor and principal sensory nuclei)**
 - complete ipsilateral trigeminal paralysis, including:
 - a. **Paralysis of the muscles of mastication**
 - b. **Jaw deviation to the paretic side** (owing to unopposed action of the intact lateral pterygoid)
 - c. **Facial hemianesthesia** (pain, temperature, touch, and proprioception)
 - d. **Loss of the corneal reflex** (afferent limb of CN V₁)

2. Middle cerebellar peduncle (base of the pons)

- ipsilateral limb and gait dystaxia

D. Lateral superior pontine syndrome

- results from occlusion of a circumferential branch of the basilar artery, the **superior cerebellar artery**.
- includes the following affected **structures** and resultant **deficits**:
 1. **Superior and middle cerebellar peduncles**
 - ipsilateral limb and trunk dystaxia
 2. **Dentate nucleus**
 - signs similar to those seen with damage to the superior cerebellar peduncle (dystaxia, dysmetria, and intention tremor)
 3. **Spinothalamic and trigeminothalamic tracts**
 - contralateral loss of pain and temperature sensation from the trunk, extremities, and face
 4. **Descending sympathetic tract**
 - ipsilateral Horner syndrome (ptosis, miosis, hemihidrosis, and apparent enophthalmos)
 5. **Medial lemniscus (lateral division [gracilis])**
 - contralateral loss of proprioception, discriminative tactile sensation, and vibration sensation from the trunk and lower extremity

E. Locked-in syndrome (pseudocoma)

- results from infarction of the base of the superior pons; infarcted structures include the corticobulbar and corticospinal tracts, resulting in quadriplegia and paralysis of the lower cranial nerves.
- may also result from **central pontine myelinolysis**.
- communication occurs only by blinking or moving the eyes vertically.

IV. LESIONS OF THE MIDBRAIN

- result from vascular occlusion of the mesencephalic branches of the posterior cerebral artery.
- may be the outcome of aneurysms of the posterior cerebral arterial circle.
- may result from tumors of the pineal region.
- may occur owing to hydrocephalus.

A. Posterior midbrain (Parinaud) syndrome (Figure 12.3A)

- frequently the result of a **pinealoma** or **germinoma** of the pineal region.
- includes the following affected **structures** and resultant **deficits**:
 1. **Superior colliculus and pretectal area**
 - paralysis of upward and downward gaze, pupillary disturbances, and absence of convergence
 2. **Cerebral aqueduct**
 - noncommunicating hydrocephalus (as a result of compression from a pineal tumor)

B. Paramedian midbrain (Benedikt) syndrome (see Figure 12.3B)

- results from occlusion or hemorrhage of the paramedian midbrain branches of the posterior cerebral artery.
- includes the following affected **structures** and resultant **deficits**:
 1. **Oculomotor nerve roots (intra-axial fibers)**
 - complete **ipsilateral oculomotor nerve paralysis**
 - **eye abduction and depression** because of the unopposed action of the lateral rectus (CN VI) and the superior oblique (CN IV)
 - severe ptosis (paralysis of the levator palpebrae)
 - ipsilateral **fixed and dilated pupil** (complete internal ophthalmoplegia)

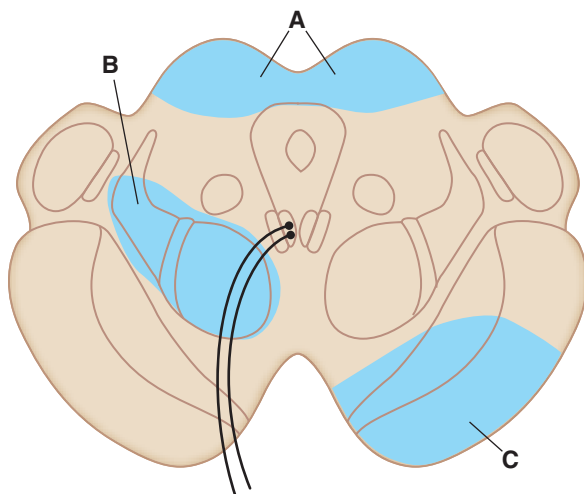


FIGURE 12.3. Lesions of the rostral midbrain at the level of the superior colliculus and oculomotor nucleus. **(A)** Dorsal midbrain (Parinaud) syndrome. **(B)** Paramedian midbrain (Benedikt) syndrome. **(C)** Medial midbrain (Weber) syndrome.

2. Red nucleus and dentatorubrothalamic tract

- contralateral cerebellar dystaxia with intention tremor

3. Medial lemniscus

- contralateral loss of proprioception, discriminative tactile sensation, and vibration sensation from trunk and extremities

C. Medial midbrain (Weber) syndrome (see Figure 12.3C)

- results from occlusion of midbrain branches of the posterior cerebral artery and aneurysms of the circle of Willis.
- includes the following **structures** and resultant **deficits**:
 1. **Oculomotor nerve roots (intra-axial fibers)** (see IV B 1)
 2. **Corticobulbar tracts**
 - contralateral weakness of the lower face (CN VII), tongue (CN XII), and palate (CN X)
 3. **Corticospinal tracts**
 - contralateral hemiparesis of the trunk and limbs

V. ACOUSTIC NEUROMA (SCHWANNOMA) (FIGURE 12.4)

- a benign tumor of the Schwann cells affecting the vestibulocochlear nerve.
- a posterior fossa tumor of the internal auditory meatus and the cerebellopontine (CP) angle.
- frequently compresses the facial nerve, which accompanies CN VIII in the CP angle and internal auditory meatus.
- may impinge on the pons and affect the spinal trigeminal tract (CN V).
- includes the following affected **structures** and resultant **deficits**:

A. Cochlear nerve of CN VIII

- unilateral nerve deafness and tinnitus

B. Vestibular nerve of CN VIII

- vertigo, nystagmus, nausea, vomiting, and unsteadiness of gait

C. Facial nerve (CN VII)

- facial weakness and loss of corneal reflex (efferent limb)

D. Spinal trigeminal tract (CN V)

- paresthesias and anesthesia of ipsilateral face
- loss of the corneal reflex (afferent limb)

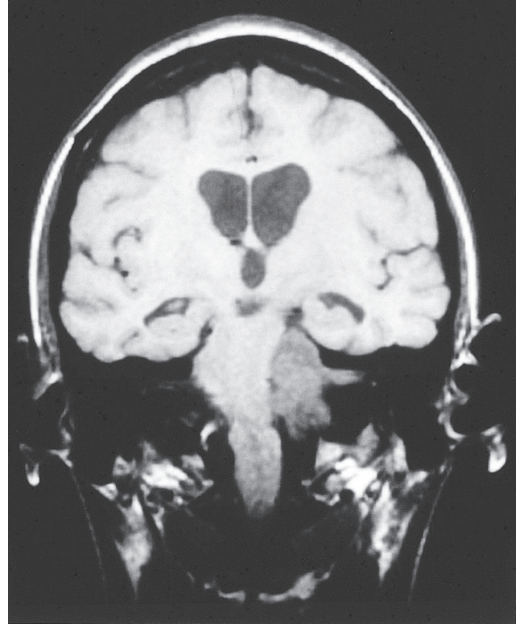


FIGURE 12.4. T₁-weighted magnetic resonance image of an acoustic neuroma. This coronal section shows dilation of the ventricles. The vestibulocochlear nerve is visible in the left internal auditory meatus. The tumor indents the lateral pons. Cranial nerve palsies include CNs V, VII, and VIII. Symptoms include unilateral deafness, facial anesthesia and weakness, and an absent corneal reflex. (Modified from Fix JD. *High-Yield Neuroanatomy*. 3rd ed. Philadelphia, PA: Lippincott Williams & Wilkins; 2005:108.)

E. Abducent nerve (CN VI) (in advanced cases with large tumors)

- diplopia

F. Corticospinal tract (in advanced cases with large tumors)

- contralateral spastic paresis

VI. INTERNUCLEAR OPHTHALMOPLEGIA

- also known as medial longitudinal fasciculus (MLF) syndrome, which results from a lesion of the MLF. Lesions occur in the dorsomedial pontine tegmentum and may affect one or both MLFs.
- a frequent sign of multiple sclerosis.
- results in medial rectus palsy on attempted lateral gaze and monocular nystagmus in the abducting eye with normal convergence.
- lesions of the abducent nucleus of CN VI result in all MLF signs and a lateral rectus paralysis with internal strabismus.

VII. JUGULAR FORAMEN (VERNET) SYNDROME

- affects CN IX, CN X, and CN XI.
- includes the following affected **structures** and resultant **deficits**:

A. Glossopharyngeal nerve (CN IX)

- loss of the gag reflex (afferent limb)
- loss of taste sensation in the posterior third of the tongue
- unilateral loss of the carotid sinus reflex

B. Vagal nerve (CN X)

- laryngeal paralysis with dysarthria, dysphagia, and dysphonia (hoarseness)
- palatal paralysis with loss of the gag reflex (efferent limb)

C. Accessory nerve (CN XI)

- weakness of the sternocleidomastoid and trapezius (shoulder droop)

VIII. SUBCLAVIAN STEAL SYNDROME

- results from thrombosis of the left subclavian artery proximal to the vertebral artery. Blood is shunted retrogradely down the vertebral artery and into the left subclavian artery.
- leads to the following clinical signs: transient weakness and claudication of the left upper limb on exercise and vertebrobasilar insufficiency (vertigo, dizziness).

Review Test

1. During a fight, a 16-year-old man is shot with a 22-caliber bullet in the occiput. Computed tomography (CT) shows that the bullet is lodged in the left medullary pyramid. The most prominent neurologic deficit is:

- (A) apallesthesia, right side.
- (B) exaggerated muscle stretch reflexes, left side.
- (C) fasciculations, right side.
- (D) hyperreflexia, left side.
- (E) plantar reflex extensor, right side.

2. A 70-year-old woman has right-sided hemiparesis. Which of the following signs best localizes the lesion to the brainstem?

- (A) Exaggerated muscle stretch reflexes, right side
- (B) Lateral strabismus
- (C) Loss of kinesthetic and pallesthetic sensation, right side
- (D) Lower facial weakness (numbness), right side
- (E) Tonic deviation of eyes to the right

3. A 10-year-old boy has right arm and leg dys-taxia, nystagmus, hoarseness, along with miosis and ptosis on the right. Bronchoscopy reveals a paretic vocal cord on the right. The lesion site responsible is most likely the:

- (A) dorsolateral medulla.
- (B) dorsolateral pons.
- (C) internal capsule.
- (D) left red nucleus.
- (E) right dorsal motor nucleus of CN X.

4. Neurologic examination reveals miosis, ptosis, hemianhidrosis, left side; laryngeal and palatal paralysis, left side; facial anesthesia, left side; and loss of pain and temperature sensation from the trunk and extremities, right side.

The lesion is in the:

- (A) caudal medulla, ventral median zone, right side.
- (B) caudal pontine tegmentum, lateral zone, right side.
- (C) rostral medulla, lateral zone, left side.
- (D) rostral pontine base, left side.
- (E) rostral pontine tegmentum, dorsal median zone, left side.

5. Neurologic examination reveals severe ptosis, eye looks down and out, right side; fixed, dilated pupil, right side; spastic hemiparesis, left side; and lower facial weakness, left side.

The lesion is in the:

- (A) caudal pontine tegmentum, dorsal median zone, left side.
- (B) pontine isthmus, dorsal lateral tegmen-tum, left side.
- (C) rostral midbrain, medial basis pedunculi, right side.
- (D) rostral midbrain, medial tegmentum, left side.
- (E) rostral pontine tegmentum, dorsal lateral zone, right side.

6. Neurologic examination reveals sixth nerve palsy, right side; facial weakness, left side; hemiparesis, left side; and limb and gait dystaxia, right side. The lesion is in the:

- (A) caudal medulla, ventral median zone, right side.
- (B) caudal pontine base, median zone, right side.
- (C) caudal pontine tegmentum, dorsal median zone, left side.
- (D) caudal pontine tegmentum, lateral zone, right side.
- (E) rostral pontine tegmentum, lateral zone, left side.

7. Neurologic examination reveals paralysis of upward and downward gaze, absence of convergence, and absence of pupillary reaction to light. The lesion is in the:

- (A) caudal midbrain tectum.
- (B) caudal midbrain tegmentum.
- (C) caudal pontine tegmentum.
- (D) rostral midbrain tectum.
- (E) rostral pontine tegmentum.

8. Neurologic examination reveals bilateral medial rectus paresis on attempted lateral gaze, monocular horizontal nystagmus in the abducting eye, and unimpaired convergence. The lesion is in the:

- (A) caudal midbrain tectum.
- (B) caudal pontine base.
- (C) midpontine tegmentum, dorsomedial zones, bilateral.

- (D) rostral midbrain, bases pedunculorum.
- (E) rostral midbrain tectum.

9. Neurologic examination reveals ptosis, miosis, and hemianhidrosis, left side; loss of vibration sensation in the right leg; loss of pain and temperature sensation from the trunk, extremities, and face, right side; and severe dystaxia and intention tremor, left arm. The lesion is in the:

- (A) caudal medulla, lateral zone, right side.
- (B) pontine isthmus, dorsal lateral zone, left side.
- (C) rostral medulla, lateral zone, left side.
- (D) rostral midbrain tegmentum, right side.
- (E) rostral pontine tegmentum, dorsal medial zone, left side.

10. Neurologic examination reveals weakness of the pterygoid and masseter, left side; corneal reflex absent, left side; and facial hemianesthesia, left side. The lesion is in the:

- (A) caudal pontine tegmentum, dorsal medial zone, left side.
- (B) caudal pontine tegmentum, lateral zone, left side.
- (C) foramen ovale, left side.
- (D) midpontine base, medial zone, left side.
- (E) midpontine tegmentum, lateral zone, left side.

11. Neurologic examination reveals loss of the stapedial reflex, loss of the corneal reflex, inability to purse the lips, and loss of taste sensation on the apex of the tongue. The lesion is in the:

- (A) basis pedunculi of the midbrain.
- (B) caudal lateral pontine tegmentum.
- (C) rostral lateral pontine tegmentum.
- (D) rostral medulla.
- (E) stylomastoid foramen.

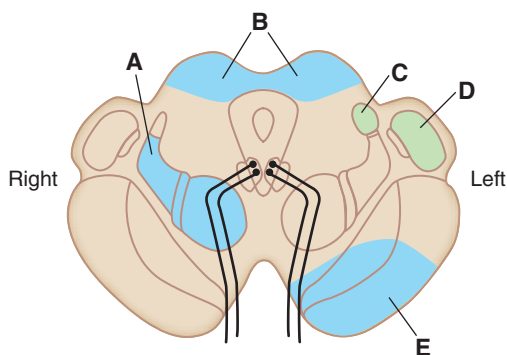
12. Which of the following structures is involved in the paramedian infarction of the base of the pons?

- (A) Anterior spinocerebellar tract
- (B) Descending trigeminal tract
- (C) Pyramidal tract

- (D) Rubrospinal tract
- (E) Trapezoid body

Questions 13 to 20

Match the description in items 13 to 20 with the appropriate lettered structure shown in the figure.



- 13.** Paralysis of upward gaze
- 14.** Loss of pain and temperature on the left side of the body
- 15.** Deviation of the tongue to the left side and the uvula to the right side
- 16.** Intention tremor on the right side
- 17.** Complete third nerve palsy on the right side
- 18.** Loss of vibration sensation in the right extremities
- 19.** Babinski sign on the left side
- 20.** Lesion leads to terminal axonal degeneration in the right superior temporal gyrus (transverse gyrus of Heschl)

Answers and Explanations

1-E. The bullet transected the left medullary pyramid, which contains the uncrossed corticospinal tract. This upper motor neuron (UMN) lesion has produced a right contralateral spastic paresis with all pyramidal signs.

2-B. Lateral strabismus (exotropia) is seen in midbrain lesions (e.g., Weber syndrome) that transect intra-axial fibers of the oculomotor nerve. The intact lateral rectus pulls the globe laterally.

3-A. The lateral medullary syndrome is also called PICA syndrome. The dorsolateral medulla contains the nucleus ambiguus (larynx), hypothalamospinal tract (Horner syndrome), inferior cerebellar peduncle (dystaxia), and vestibular nuclei (nystagmus).

4-C. The lesion is a classic Wallenberg syndrome (PICA syndrome) of the lateral medullary zone. Interruption of the descending sympathetic tract produces ipsilateral Horner syndrome. Involvement of the nucleus ambiguus or its exiting intra-axial fibers accounts for lower motor neuron (LMN) paralysis of the larynx and soft palate. The ipsilateral facial anesthesia results from the interruption of the spinal trigeminal tract; the contralateral loss of pain and temperature sensation from the trunk and extremities is the result of transection of the spinothalamic tracts of the anterolateral system. The combination of ipsilateral and contralateral sensory loss is called alternating hemianesthesia. Singultus (hiccup) is frequently seen in this syndrome and is thought to result from irritation of the reticulophrenic pathway.

5-C. This constellation of deficits constitutes Weber syndrome, which affects the basis pedunculi and the exiting intra-axial oculomotor fibers. Severe ptosis, the abducted and depressed eyeball, and the internal ophthalmoplegia (fixed, dilated pupil) are third nerve signs. The contralateral hemiparesis results from interruption of the corticospinal tracts; lower facial weakness is because of the interruption of the corticobulbar tracts. The combination of ipsilateral and contralateral motor deficits is called alternating hemiplegia.

The corticospinal tract is closely related to three cranial nerves (CN III, CN VI, and CN XII); third nerve signs put the lesion in the midbrain, sixth nerve signs put the lesion in the pons, and twelfth nerve signs put the lesion in the medulla. All cranial nerves have ipsilateral signs (the trochlear exhibits contralateral signs if lesioned prior to the decussation of its fibers). Transection of the corticospinal tract rostral to the decussation results in a contralateral spastic hemiparesis. The trochlear nucleus, an exception, gives rise to intra-axial axons that cross the midline and exit just caudal to the frenulum of the superior medullary velum. A lesion of the trochlear nucleus results in a contralateral superior oblique palsy.

6-B. These signs point to the base of the pons (medial inferior pontine syndrome) on the right side and include involvement of the exiting intra-axial abducent fibers that pass through the uncrossed corticospinal fibers; this results in an ipsilateral lateral rectus paralysis (LMN lesion) and contralateral hemiparesis. Contralateral facial weakness results from damage to the corticobulbar fibers prior to their decussation. Involvement of the transverse pontine fibers destined for the middle cerebellar peduncle results in cerebellar signs. Furthermore, the involved cranial nerve and pyramidal tract indicate where the lesion must be to account for the deficits. An ipsilateral sixth nerve paralysis and crossed hemiplegia is called the Millard-Gubler syndrome.

7-D. These deficits indicate the Parinaud syndrome, dorsal midbrain syndrome. This condition frequently is the result of a tumor in the pineal region (e.g., germinoma or pinealoma). A pinealoma compresses the superior colliculus and the underlying accessory oculomotor nuclei that are responsible for upward and downward vertical conjugate gaze. Patients usually have pupillary disturbances and absence of convergence.

8-C. The MLF is located in the dorsomedial midpontine tegmentum. MLF syndrome is frequently seen in multiple sclerosis and less often in vascular lesions. Another pontine lesion results in one-and-a-half syndrome; it includes the MLF syndrome and a lesion of the abducent nucleus (see Chapter 16).

9-B. These deficits correspond to a lesion in the dorsolateral zone of the pontine isthmus, lateral superior pontine syndrome. Interruption of the descending sympathetic pathway to the ciliospinal center of Budge (T1–T2) results in Horner syndrome (always ipsilateral). Involvement of the lateral aspect (includes the lower limb fibers) of the medial lemniscus results in a loss of vibratory sensation and other posterior column modalities. Damage to the trigeminothalamic and the anterolateral system at this level results in contralateral hemianesthesia of the face and body. Infarction of the superior cerebellar peduncle leads to severe cerebellar dystaxia on the same side.

10-E. These signs indicate the lateral midpontine syndrome. This lesion involves the motor and chief sensory nuclei and the intra-axial root fibers of the trigeminal nerve as it passes through the base of the pons. All signs are ipsilateral and refer to CN V. The afferent limb of the corneal reflex has been interrupted. This syndrome results from occlusion of the trigeminal artery—a short circumferential branch of the basilar artery.

11-B. These signs constitute the lateral inferior pontine syndrome (AICA syndrome). The neurologic findings are all signs of a lesion involving the facial nerve. The facial motor nerve nucleus and intra-axial fibers are found in the caudal lateral pontine tegmentum. A lesion of the stylomastoid foramen does not include the absence of the stapedial reflex or the loss of taste sensation from the anterior two-thirds of the tongue. The stapedial nerve and the chorda tympani exit the facial canal proximal to the stylomastoid foramen.

12-C. The base of the pons includes the corticospinal (pyramidal), corticobulbar, and corticopontine tracts, pontine nuclei, and transverse pontine fibers. At caudal levels, intra-axial abducent fibers pass through the lateral pyramidal fascicles.

13-B. Paralysis of upward gaze results from compression of the mesencephalic tectum by a tumor in the pineal region known as Parinaud syndrome.

14-C. Loss of pain and temperature on the left side of the body is the result of a lesion on the right side of the anterolateral system.

15-E. Deviation of the tongue to the left side results from transection of the right corticobulbar fibers (CN XII) in the medial aspect of the crus cerebri. Deviation of the uvula to the right side results from transection of the right corticobulbar fibers (CN X) in the medial aspect of the crus cerebri.

16-A. Transection of the left dentatothalamic tract results in an intention tremor on the right side. The dentatothalamic tract decussates in the caudal midbrain, below the level of this lesion.

17-E. Complete third nerve palsy on the right side results from transection of the oculomotor nerve fibers as they pass through the right side of the crus cerebri.

18-A. A loss of vibration sensation in the right extremities results from destruction of the left medial lemniscus.

19-E. A Babinski sign on the left side results from transection of the corticospinal tract within the middle three-fifths of the crus cerebri.

20-D. Destruction of the right medial geniculate body results in terminal axonal degeneration of the auditory radiation in the right superior temporal gyrus.

Diencephalon: Thalamus and Hypothalamus

Objectives

Thalamus

- List the boundaries of the thalamus.
- List the thalamic nuclei and their primary functions and connections.
- Describe the blood supply to the thalamus.
- Describe the internal capsule.

Hypothalamus

- List the boundaries of the hypothalamus.
- List the regions and nuclei of the hypothalamus and their primary functions and connections.
- List the major fiber pathways associated with the hypothalamus and include a description of what they connect and the clinical implications if they are damaged.

I. INTRODUCTION: THE THALAMUS

- largest division of the diencephalon.
- receives precortical input from all sensory systems except the olfactory system.
- largest input received from the cerebral cortex.
- projects primarily to the cerebral cortex and to a lesser degree to the basal nuclei and hypothalamus.
- plays an important role in sensory and motor system integration.

II. BOUNDARIES OF THE THALAMUS

- A. Anterior: interventricular foramen
- B. Posterior: free pole of the pulvinar
- C. Dorsal: free surface underlying the fornix and the lateral ventricle
- D. Ventral: plane connecting the hypothalamic sulci
- E. Medial: third ventricle
- F. Lateral: posterior limb of the internal capsule

III. PRIMARY THALAMIC NUCLEI AND THEIR MAJOR CONNECTIONS (FIGURES 13.1 AND 13.2)

A. Anterior nucleus

- receives hypothalamic input from the mammillary nucleus via the mammillothalamic tract.
- receives hippocampal input via the fornix.
- projects to the cingulate gyrus.
- part of the Papez circuit of emotion (the limbic system).

B. Dorsomedial nucleus (mediodorsal nucleus)

- reciprocally connected to the prefrontal cortex.
- has abundant connections with the intralaminar nuclei.
- receives input from the amygdala, the temporal neocortex, and the substantia nigra.
- part of the limbic and striatal systems.
- when destroyed results in memory loss (Wernicke–Korsakoff syndrome).
- plays a role in the expression of affect, emotion, and behavior (limbic function).

C. Intralaminar nuclei

- receive input from the brainstem reticular formation, the ascending reticular system, and other thalamic nuclei.
- receive spinothalamic and trigeminothalamic input.
- project diffusely to the neocortex.
- projects to the dorsomedial nucleus.

1. Centromedian nucleus

- largest of the intralaminar nuclei
- reciprocally connected to the motor cortex (area 4)
- receives input from the globus pallidus
- projects to the striatum
- projects diffusely to the neocortex

2. Parafascicular nucleus

- projects to the striatum and the supplementary motor cortex (area 6)

D. Dorsal tier nuclei

1. Lateral dorsal nucleus

- a posterior extension of the anterior nuclear complex
- receives mammillothalamic input
- projects to the cingulate gyrus
- has reciprocal connections with the limbic system

2. Lateral posterior nucleus

- located between the lateral dorsal nucleus and the pulvinar
- has reciprocal connections with the superior parietal cortex (areas 5 and 7)

3. Pulvinar

- the largest thalamic nucleus
- has reciprocal connections with the association cortex of the occipital, parietal, and posterior temporal lobes
- receives input from the lateral and medial geniculate bodies and the superior colliculus
- concerned with the integration of visual, auditory, and somesthetic input
- lesions of the dominant side can result in sensory aphasia

E. Ventral tier nuclei

- include primarily specific relay nuclei:

1. Ventral anterior nucleus

- receives input from the globus pallidus and the substantia nigra
- projects diffusely to the prefrontal and orbital cortices
- projects to the premotor cortex (area 6)

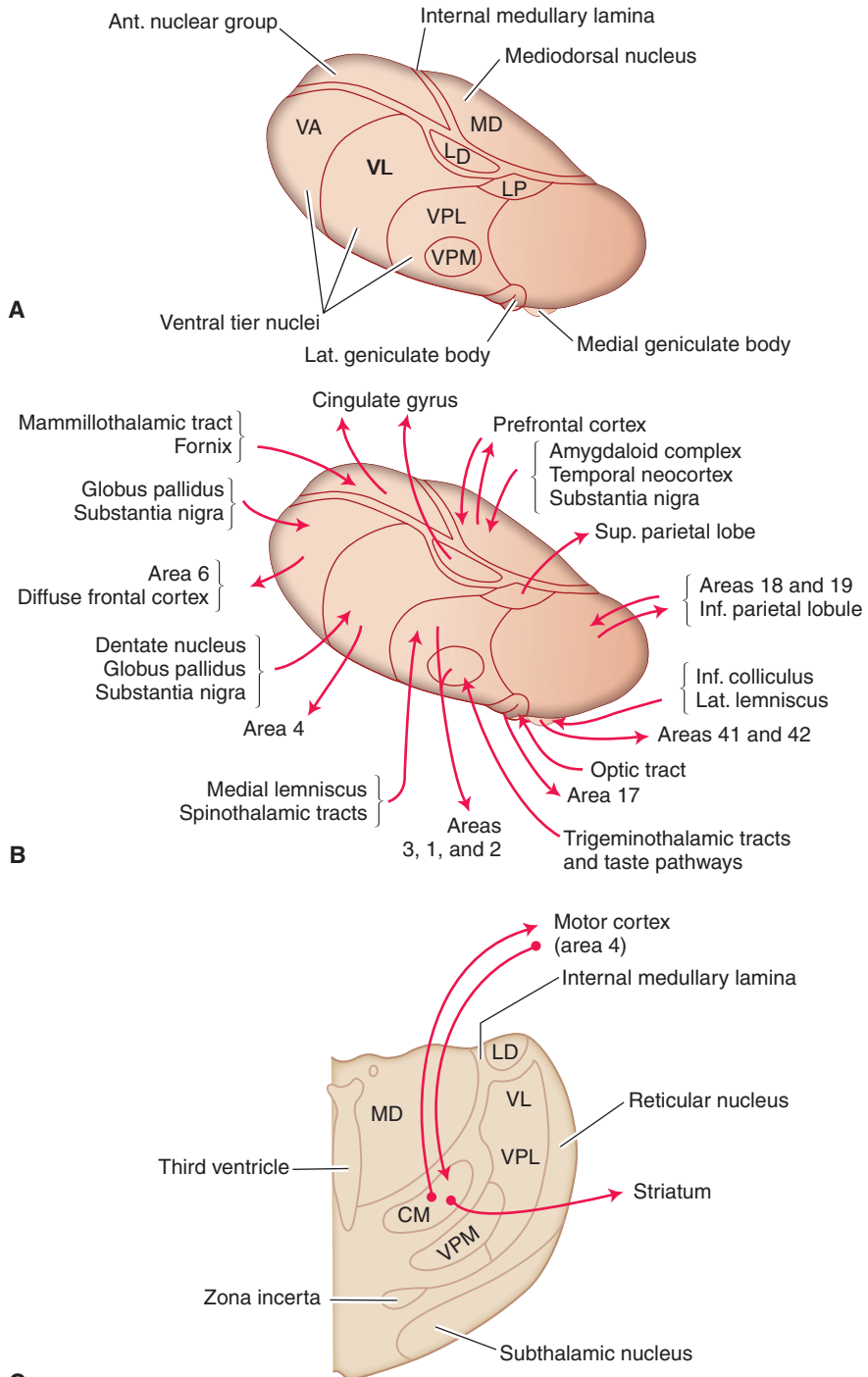


FIGURE 13.1. Major thalamic nuclei and their afferent connections. **(A)** Oblique dorsolateral aspect of the thalamus and major nuclei. **(B)** The major afferent and efferent connections of the thalamus. **(C)** The transverse section of the thalamus at the level of the arrows in **(A)**, showing the major connections of the centromedian nucleus. CM = centromedian nucleus; MD = mediodorsal nucleus; LD = lateral dorsal nucleus; LP = lateral posterior nucleus; VA = ventral anterior nucleus; VL = ventral lateral nucleus; VPL = ventral posterolateral nucleus; and VPM = ventral posteromedial nucleus.

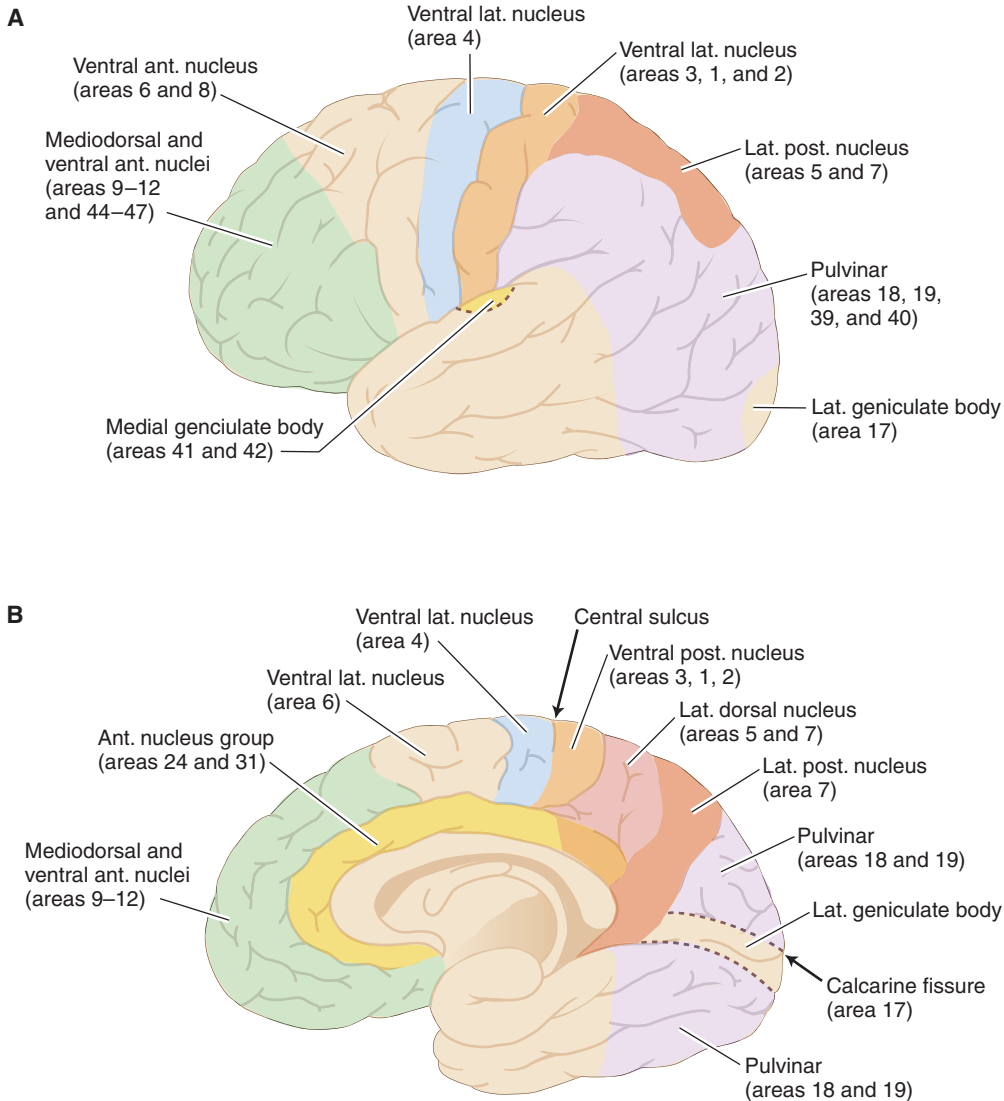


FIGURE 13.2. (A) Lateral and (B) medial views of the cerebral hemisphere showing the cortical projection areas of the major thalamic nuclei.

2. Ventral lateral nucleus

- receives input from the globus pallidus, substantia nigra, and the cerebellum (dentate nucleus)
- projects to the motor cortex (area 4) and to the supplementary motor area (area 6)
- influences somatic motor mechanisms via the striatal motor system and the cerebellum
- Stereotactic destruction reduces Parkinsonian tremor

3. Ventral posterior nucleus

- the nucleus of termination of general somatic afferent (GSA; pain and temperature) and special visceral afferent (SVA; taste) pathways
- contains **three subnuclei**:

a. Ventral posterolateral (VPL) nucleus

- receives the spinothalamic tracts and the medial lemniscus.
- projects to the somesthetic (sensory) cortex (areas 3, 1, and 2).
- lesion results in contralateral loss of pain and temperature sensation as well as loss of tactile discrimination in the trunk and extremities.

b. Ventral posteromedial (VPM) nucleus

- receives the trigeminothalamic tracts.
- receives the taste pathway via the solitary nucleus and the parabrachial nucleus.
- projects to the somesthetic cortex (areas 3, 1, and 2).
- lesion results in contralateral loss of pain and temperature sensation, and loss of tactile discrimination in the head; results in ipsilateral loss of taste.

c. Ventral posteroinferior (VPI) nucleus

- receives vestibulothalamic fibers from the vestibular nuclei.
- projects to the vestibular area of the somesthetic cortex.

F. Lateral geniculate body (LGB)

- a visual relay nucleus.
- receives retinal input via the optic tract.
- projects to the primary visual cortex (area 17, the lingual gyrus and the cuneus) via the optic radiation.

G. Medial geniculate body (MGB)

- an auditory relay nucleus.
- receives auditory input via the brachium of the inferior colliculus.
- projects to the primary auditory cortex (areas 41 and 42) via the auditory radiation.

IV. BLOOD SUPPLY OF THE THALAMUS

A. Posterior communicating artery

- gives rise to the anterior thalamoperforating arteries.

B. Posterior cerebral artery

- gives rise to the posterior choroidal arteries.
- gives rise to the posterior thalamoperforating arteries.

C. Anterior choroidal artery (LGB)

V. INTERNAL CAPSULE (FIGURE 13.3; SEE FIGURES 1.14 THROUGH 1.16)

- a layer of white matter (myelinated axons) that separates the caudate nucleus and thalamus medially from the lentiform nucleus laterally.
- consists of three divisions:

A. Anterior limb

- located between the caudate nucleus and the lentiform nucleus.

B. Genu

- contains corticobulbar fibers.

C. Posterior limb

- located between the thalamus and the lentiform nucleus.
- contains the sensory radiations (pain, temperature, and touch).
- contains the corticospinal fibers.
- contains the visual and auditory radiations.

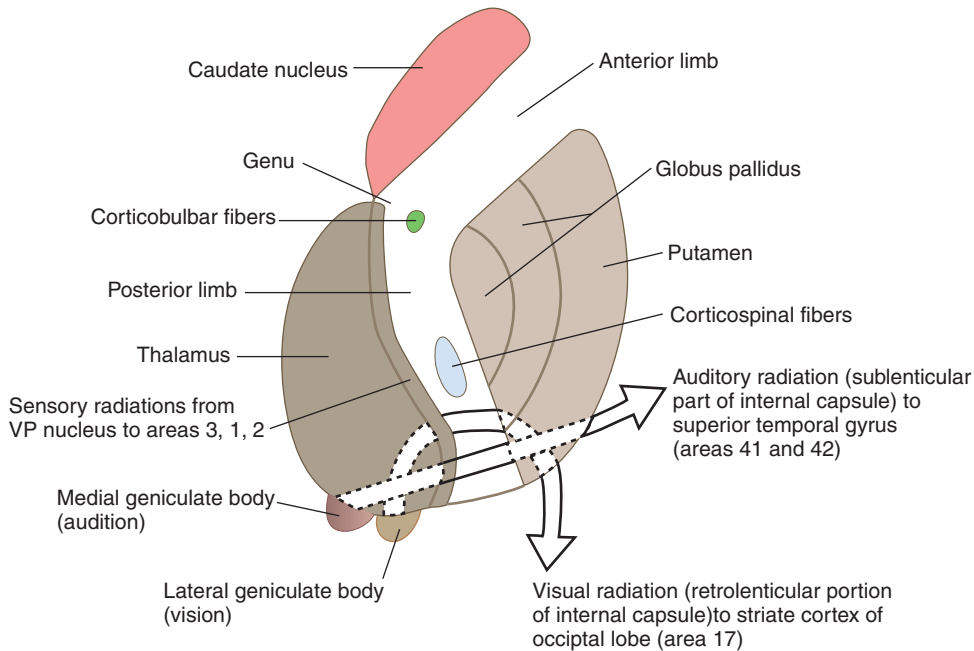


FIGURE 13.3. Horizontal section of the right internal capsule showing the major fiber projections. Lesions of the internal capsule result in contralateral hemiparesis and contralateral hemianopia. (Modified from Fix JD. *High-Yield Neuroanatomy*. 3rd ed. Philadelphia, PA: Lippincott Williams & Wilkins; 2005:118.)

VI. BLOOD SUPPLY OF THE INTERNAL CAPSULE (SEE FIGURE 3.6)

A. Anterior limb

- irrigated by the medial striate branches of the anterior cerebral artery and by the lateral striate branches (lenticulostriate) of the middle cerebral artery.

B. Genu

- perfused either by direct branches from the internal carotid artery or by pallidal branches of the anterior choroidal artery.

C. Posterior limb

- supplied by branches of the anterior choroidal artery and lenticulostriate branches of the middle cerebral arteries.

VII. CLINICAL CORRELATIONS

A. Infarction of the internal capsule

- most frequently results from occlusion of the lenticulostriate branches of the middle cerebral artery and results in the following contralateral conditions:
 1. **Tactile hypesthesia**
 2. **Anesthesia**
 3. **Hemiparesis (with the Babinski sign)**
 4. **Lower facial weakness**
 5. **Homonymous hemianopia**

B. Thalamic syndrome (Dejerine and Roussy)

- usually caused by occlusion of a posterior thalamoperforating artery.
- classic signs: contralateral hemiparesis; contralateral hemianesthesia; elevated pain threshold; spontaneous, agonizing, burning pain (hyperpathia); and athetotic posturing of the hand (thalamic hand).

VIII. OVERVIEW: THE HYPOTHALAMUS

- a division of the diencephalon.
- lies within the floor and ventral part of the walls of the third ventricle.
- functions primarily in the **maintenance of homeostasis**.
- subserves three systems: the **autonomic nervous system (ANS)**, the **endocrine system**, and the **limbic system**.

IX. SURFACE ANATOMY OF THE HYPOTHALAMUS (SEE FIGURES 1.2 AND 1.5)

- visible only from the inferior aspect of the brain.
- lies between the optic chiasm and the interpeduncular fossa (posterior perforated substance).
- hypothalamic sulcus forms superior border.
- includes the following **ventral surface structures**:

A. Infundibulum

- the stalk of the hypophysis.
- contains the hypophyseal portal vessels.
- contains the supraoptohypophyseal and tuberohypophyseal tracts.

B. Tuber cinereum

- the prominence between the infundibulum and the mammillary bodies.
- includes the **median eminence**, which contains the **arcuate nucleus**.

C. Mammillary bodies

- contain the mammillary nuclei.

D. Cerebral arterial circle

- surrounds the inferior surface of the hypothalamus and provides its blood supply.

X. HYPOTHALAMIC REGIONS AND NUCLEI

- The hypothalamus is divided into a lateral area and a medial area separated by the fornix and the mammillothalamic tract.

A. Lateral hypothalamic area

- traversed by the medial forebrain bundle.
- includes two major nuclei:
 1. **Lateral preoptic nucleus**
 - the anterior telencephalic portion.

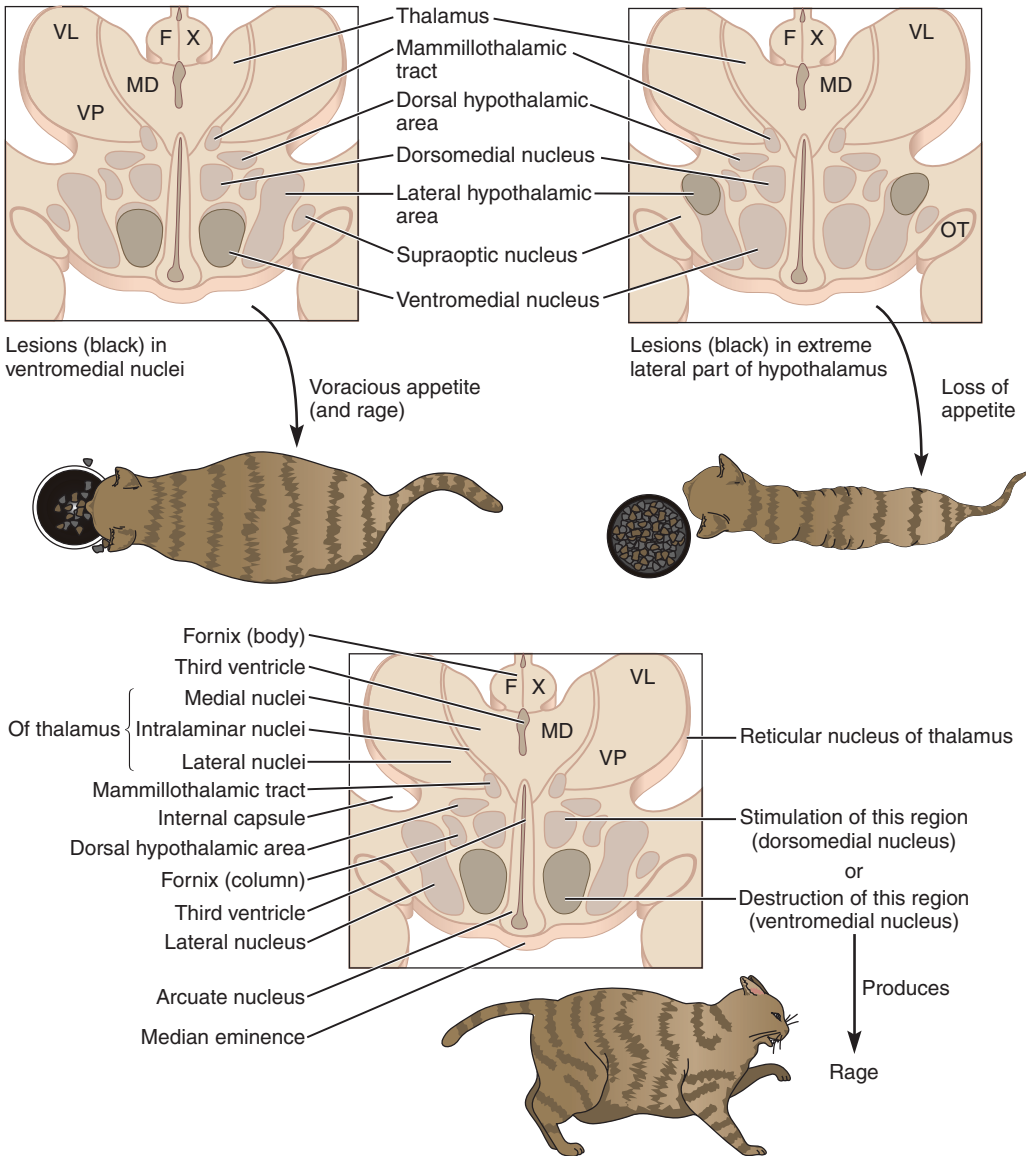


FIGURE 13.4. Coronal section through the hypothalamus at the level of the dorsomedial, ventromedial, and lateral hypothalamic nuclei. The column of the fornix separates the medial from the lateral hypothalamic zones. *FX* = fornix; *MD* = medial dorsal nucleus of thalamus; *OT* = optic tract; *VL* = ventral lateral nucleus of thalamus; and *VP* = ventral posterior nucleus of thalamus.

2. Lateral hypothalamic nucleus (Figure 13.4)

- when stimulated, induces eating.
- lesions cause anorexia and starvation.

B. Medial hypothalamic area (Figure 13.5)

- includes the periventricular area that borders the third ventricle.
- divided into four regions, from anterior to posterior:

1. Preoptic region

- the anterior telencephalic portion.

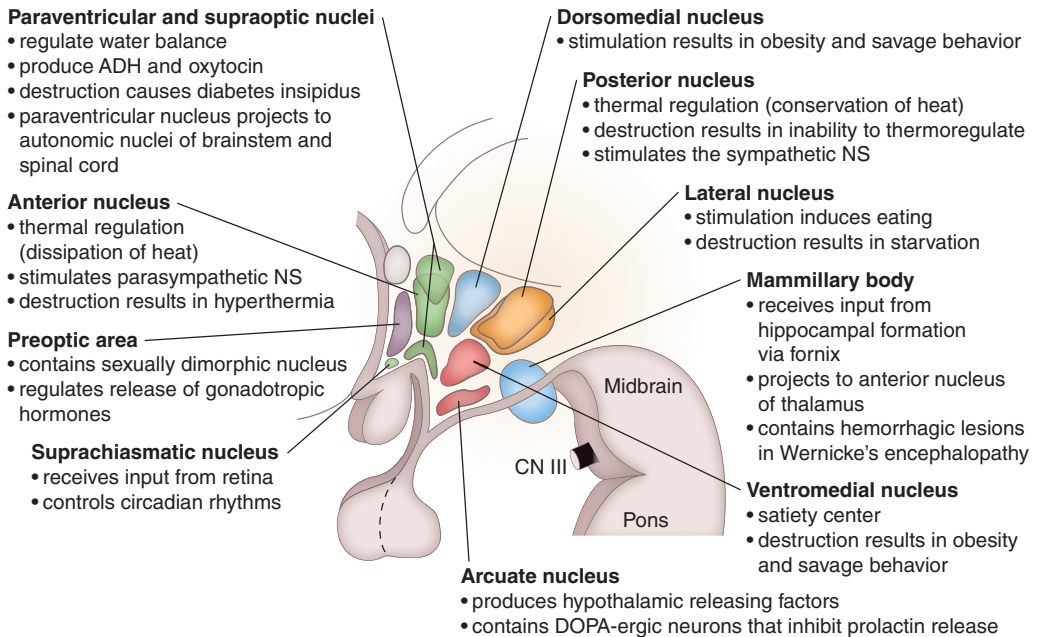


FIGURE 13.5. Major hypothalamic nuclei and their functions. NS = nervous system. (Modified from Fix JD. *High-Yield Neuroanatomy*. 3rd ed. Philadelphia, PA: Lippincott Williams & Wilkins; 2005:132.)

- contains the **medial preoptic nucleus**, which regulates the release of gonadotropic hormones from the adenohypophysis. The medial preoptic nucleus contains the sexually dimorphic nucleus, whose development is dependent on testosterone levels.

2. Supraoptic region

- lies superior to the optic chiasm
 - Suprachiasmatic nucleus**
 - receives direct input from the retina.
 - plays a role in the **control of circadian rhythms**.
 - Anterior nucleus**
 - plays a role in temperature regulation.
 - stimulates the parasympathetic nervous system.
 - destruction results in hyperthermia.
 - Paraventricular nucleus**
 - Neurosecretory cells synthesize and release antidiuretic hormone (**ADH**), **oxytocin**, and corticotropin-releasing hormone (**CRH**).
 - regulates water balance (conservation of water).
 - gives rise to the supraopticohypophyseal tract, which projects to the neurohypophysis.
 - destruction results in **diabetes insipidus**.
 - Supraoptic nucleus**
 - synthesizes **ADH** and **oxytocin**.
 - projects to the neurohypophysis via the supraopticohypophyseal tract.

3. Tuberal region

- lies superior to the tuber cinereum.
 - Dorsomedial nucleus** (see Figure 13.4)
 - when stimulated in animals, results in savage behavior.
 - Ventromedial nucleus** (see Figure 13.4)
 - a **satiety center**.
 - when stimulated, inhibits the urge to eat.
 - Bilateral destruction results in hyperphagia, obesity, and savage behavior.

- c. **Arcuate (infundibular) nucleus**
 - located in the tuber cinereum.
 - a periventricular nucleus.
 - contains neurons that produce **hypothalamic-releasing factors** and gives rise to the tuberohypophyseal tract, which terminates in the hypophyseal portal system of the infundibulum.
 - effects, via hypothalamic-releasing factors, the release or nonrelease of adenohypophyseal hormones into the systemic circulation.
 - contains dopaminergic neurons; **dopamine** is the **prolactin-inhibiting factor (PIF)**.
- 4. **Mammillary region**
 - lies superior to the mammillary bodies.
 - a. **Mammillary nuclei**
 - receive input from the **hippocampal formation** via the **fornix**.
 - receive input from the dorsal and ventral tegmental nuclei and the raphe nuclei via the mammillary peduncle.
 - project to the anterior nucleus of the thalamus via the mamillothalamic tract.
 - contain hemorrhagic lesions in Wernicke encephalopathy.
 - b. **Posterior nucleus**
 - plays a role in **thermal regulation** (i.e., conservation and increased production of heat).
 - Lesions result in **poikilothermia**, the inability to thermoregulate.

XI. MAJOR HYPOTHALAMIC CONNECTIONS (FIGURES 13.6 AND 13.7)

- characterized by mostly reciprocal connections

A. Afferent connections to the hypothalamus

- **derive** from the following structures:
 1. **Septal area and nuclei and orbitofrontal cortex**
 - via the medial forebrain bundle
 2. **Hippocampal formation**
 - primarily from the subiculum via the fornix
 3. **Amygdaloid complex**
 - via the stria terminalis and ventral amygdalofugal pathway
 4. **Primary olfactory cortex (area 34)**
 - via the medial forebrain bundle
 5. **Mediodorsal nucleus of the thalamus**
 - via the inferior thalamic peduncle
 6. **Brainstem nuclei**
 - Tegmental nuclei (dorsal and ventral)
 - a. project via the mammillary peduncle.
 - Raphe nuclei (dorsal and superior central)
 - a. project serotonergic fibers via the medial forebrain bundle and the mammillary peduncle (see Figure 21.4).
 - Locus ceruleus
 - a. projects noradrenergic fibers via the medial forebrain bundle (see Figure 21.4).

B. Efferent connections from the hypothalamus

- **project** to the following structures:
 1. **Septal area and nuclei**
 - via the medial forebrain bundle

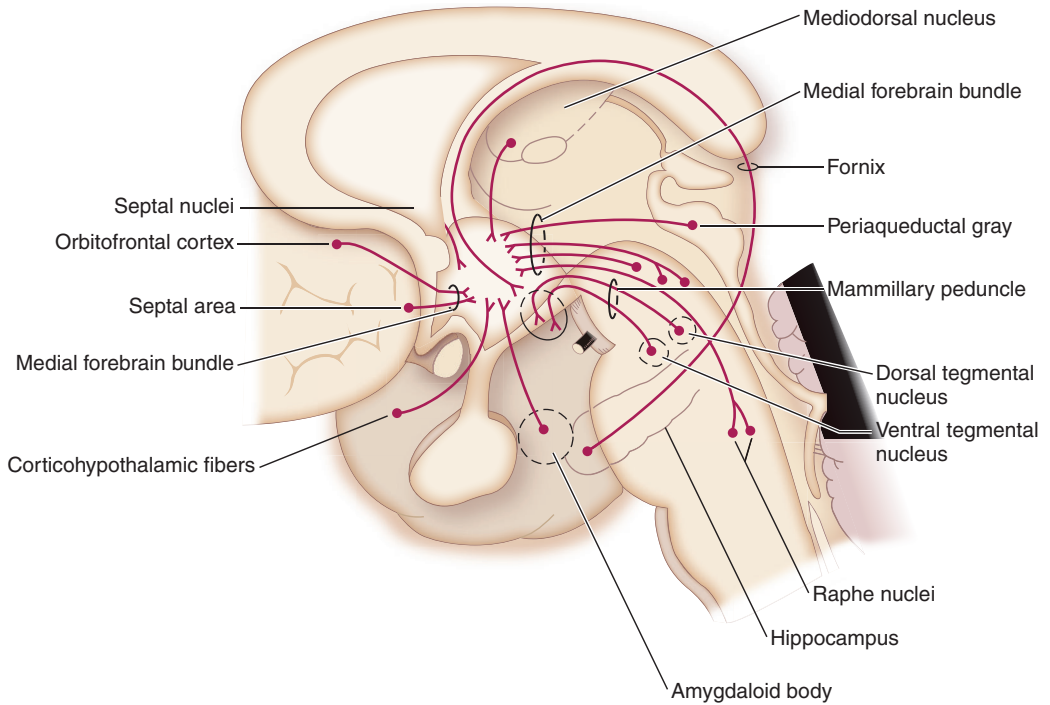


FIGURE 13.6. Major afferent (input) connections of the hypothalamus. The fornix projects from the hippocampal formation to the mammillary bodies. The medial forebrain bundle conducts both afferent and efferent fibers.

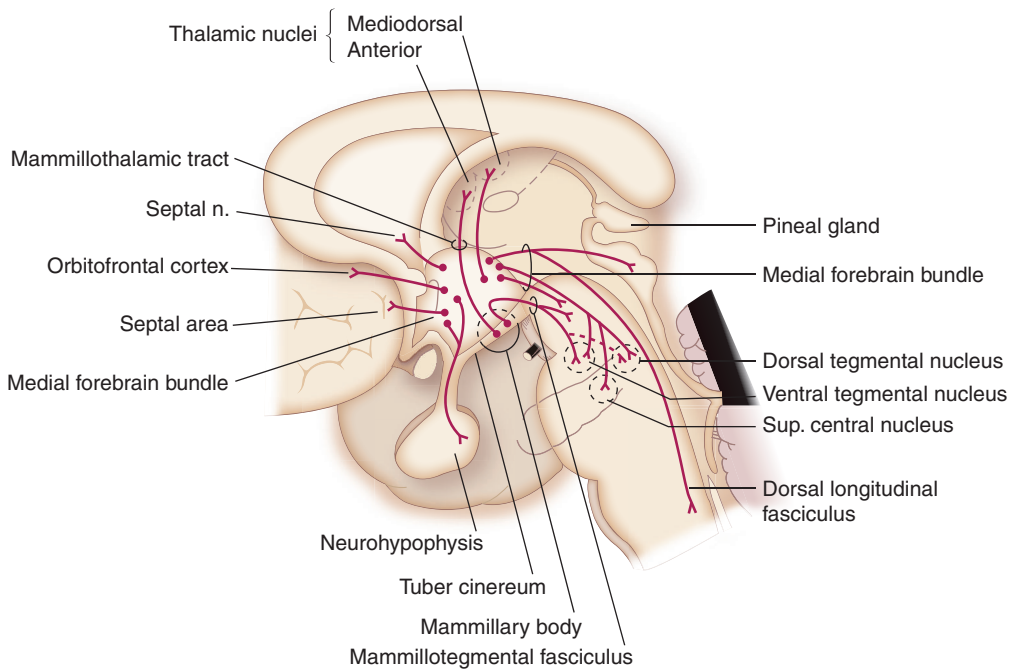


FIGURE 13.7. Major efferent (output) connections of the hypothalamus. The medial forebrain bundle conducts afferent and efferent fibers. The hypothalamus projects directly to the autonomic visceral nuclei of the brainstem and spinal cord.

2. **Anterior nucleus of the thalamus**
 - via the mammillothalamic tract
3. **Mediodorsal nucleus of the thalamus**
 - via the inferior thalamic peduncle
4. **Amygdaloid complex**
 - via the stria terminalis and the ventral amygdalopetal pathway
5. **Brainstem nuclei and spinal cord**
 - via the dorsal longitudinal fasciculus and the medial forebrain bundle
6. **Adenohypophysis**
 - via the tuberohypophyseal tract and hypophyseal portal system
7. **Neurohypophysis**
 - via the supraopticohypophyseal tract

XII. MAJOR FIBER SYSTEMS

A. Fornix (see Figures 1.4, 1.5, 13.5, 17.3, and 17.6)

- has five parts: the **alveus**, **fimbria**, **crus**, **body**, and **columns**.
- projects from the hippocampal formation to the mammillary nucleus, anterior nucleus of the thalamus, and septal area.
- the largest projection to the hypothalamus.
- Bilateral transection results in an acute amnesic syndrome.

B. Medial forebrain bundle (see Figures 13.6 and 13.7)

- traverses the entire lateral hypothalamic area.
- interconnects the septal area and nuclei, the hypothalamus, and the midbrain tegmentum.

C. Mammillothalamic tract (see Figure 17.3)

- projects from the mammillary nuclei to the anterior nucleus of the thalamus.

D. Mammillary peduncle (see Figure 13.6)

- conducts fibers from the dorsal and ventral tegmental nuclei and the raphe nuclei to the mammillary body.

E. Mammillotegmental tract (see Figure 13.7)

- conducts fibers from the mammillary nuclei to the dorsal and ventral tegmental nuclei.

F. Stria terminalis (see Figure 17.3)

- the most prominent pathway from the amygdaloid complex.
- interconnects the septal area, the hypothalamus, and the amygdaloid complex.
- lies in the sulcus terminalis between the caudate nucleus and the thalamus.

G. Ventral amygdalofugal pathway (see Figure 17.3)

- interconnects the amygdaloid complex and the hypothalamus.

H. Supraopticohypophyseal tract (Figure 13.8)

- conducts fibers from the supraoptic and paraventricular nuclei to the **neurohypophysis**.

I. Tuberohypophyseal (tuberoinfundibular) tract (see Figure 13.8)

- conducts fibers from the arcuate nucleus to the hypophyseal portal system of the infundibulum.

J. Dorsal longitudinal fasciculus (see Figure 13.7)

- extends from the hypothalamus to the caudal medulla.
- projects to the parasympathetic nuclei of the brainstem.

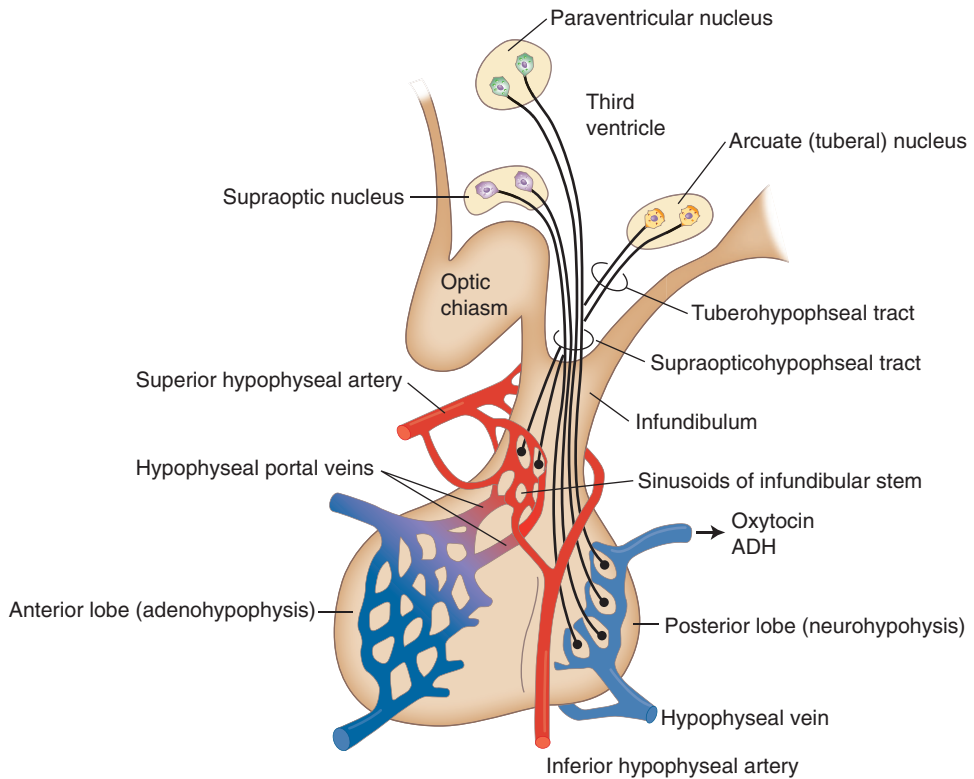


FIGURE 13.8. Hypophyseal portal system. The paraventricular and supraoptic nuclei produce ADH and oxytocin and transport the substances via the supraopticohypophyseal tract to the capillary bed of the neurohypophysis. The arcuate nucleus of the infundibulum transports releasing hormones via the tuberohypophyseal tract to the sinusoids of the infundibular stem, which drain into the secondary capillary plexus in the adenohypophysis. *ADH* = antidiuretic hormone. (Modified from Fix JD. *High-Yield Neuroanatomy*. 3rd ed. Philadelphia, PA: Lippincott Williams & Wilkins; 2005:133.)

K. Hypothalamospinal tract

- contains direct descending autonomic fibers that influence preganglionic sympathetic neurons of the intermediolateral cell column and preganglionic neurons of the sacral parasympathetic nucleus.
- interruption above T1 results in Horner syndrome.

XIII. FUNCTIONAL CONSIDERATIONS

A. Autonomic function

- The ANS is regulated by hypothalamic nuclei.
 - 1. Anterior hypothalamus**
 - has an excitatory effect on the parasympathetic nervous system.
 - 2. Posterior hypothalamus**
 - has an excitatory effect on the sympathetic nervous system.

B. Temperature regulation

- 1. Anterior hypothalamus**
 - helps regulate and maintain body temperature.
 - Destruction causes hyperthermia.

2. Posterior hypothalamus

- helps produce and conserve heat.
- Destruction causes the inability to thermoregulate.

C. Water balance regulation

- ADH controls water excretion by the kidneys.

D. Food intake regulation

- Two hypothalamic nuclei play roles in the control of appetite:
 1. **Ventromedial nucleus** (see III B 3 b)
 2. **Lateral hypothalamic nucleus**
 - the **hunger** or **feeding center**.
 - Destruction causes **starvation** and **emaciation**.

E. Hypothalamic-releasing and release-inhibiting factors

- produced in the **arcuate nucleus** of the median eminence.
- transported via the tuberohypophyseal tract to the hypophyseal portal system.
- effect the release or nonrelease of adenohypophyseal hormones.
- with the exception of dopamine, they are all **peptides**, which include
 1. Thyrotropin-releasing hormone (**TRH**)
 2. Gonadotropin-releasing hormone (**GnRH**)
 3. **Somatostatin** (growth hormone-inhibiting hormone)
 4. Growth hormone-releasing hormone (**GHRH**)
 5. **CRH (corticotropin-releasing hormone)**
 6. **PIF** and prolactin-releasing factor (**PRF**)

XIV. CLINICAL CORRELATIONS

A. Craniopharyngioma

- a congenital epidermoid tumor thought to originate from remnants of Rathke pouch.
- usually calcified.
- the most common **supratentorial tumor** found in children.
- Pressure on the chiasm results in a **bitemporal hemianopia**. Pressure on the hypothalamus causes **hypothalamic syndrome**, with adiposity, diabetes insipidus, disturbance of temperature regulation, and somnolence.

B. Pituitary adenoma

- constitutes 15% of cases of clinically symptomatic **intracranial tumors**.
- seen seldom in children.
- Pressure on the chiasm results in a **bitemporal hemianopia** (most cases show asymmetry of field defects). Pressure on the hypothalamus may cause **hypothalamic syndrome**.

C. Wernicke encephalopathy

- results from thiamine (vitamin **B₁**) deficiency.
- characterized by the triad: **ocular palsies**, **ataxic gait**, and **mental confusion**.
- lesions are found in the hypothalamus (primarily in the mammillary bodies) and in the periaqueductal gray of the midbrain.

Review Test

1. Which of the following thalamic nuclei has a motor function?

- (A) Lateral dorsal nucleus
- (B) Lateral posterior nucleus
- (C) Mediodorsal nucleus
- (D) Ventral lateral nucleus
- (E) Ventral posterior nucleus

2. To which of the following thalamic nuclei do the spinothalamic fibers project?

- (A) Anterior nucleus
- (B) Pulvinar
- (C) Ventral anterior nucleus
- (D) VPL nucleus
- (E) VPM nucleus

3. To which of the following thalamic nuclei do the cerebellar fibers project?

- (A) Anterior nucleus
- (B) Lateral dorsal nucleus
- (C) Lateral posterior nucleus
- (D) Ventral lateral nucleus
- (E) VPM nucleus

4. To which set of thalamic nuclei does the globus pallidus project?

- (A) Centromedian, lateral dorsal, and lateral ventral nuclei
- (B) Centromedian, ventral anterior, and ventral lateral nuclei
- (C) Mediodorsal, VPL, and VPM nuclei
- (D) Ventral anterior, ventral lateral, and anterior nuclei
- (E) Ventral lateral, lateral dorsal, and lateral posterior nuclei

5. Tritiated leucine [^3H -leucine] is injected into the medial mammillary nucleus for anterograde transport; radioactive label would be found in the:

- (A) anterior nucleus thalami.
- (B) arcuate nucleus hypothalami.
- (C) dorsomedial nucleus thalami.
- (D) supraoptic nucleus.
- (E) ventral anterior nucleus thalami.

6. Which structure's infarction can give rise to left hypesthesia, left homonymous hemianopia, left facial weakness, tongue deviation to the left side, and plantar extensor on the left side?

- (A) Left internal capsule
- (B) Left pulvinar
- (C) MGB
- (D) Right internal capsule
- (E) Right pulvinar

7. A capsular stroke is most commonly caused by occlusion of the following artery/arteries

- (A) Anterior cerebral artery
- (B) Direct branches of the internal carotid artery
- (C) Lateral striate arteries
- (D) Posterior communicating artery
- (E) Recurrent artery of Heubner

Questions 8 to 13

The response options for items 8 to 13 are the same. Select one answer for each item in the set.

- (A) Anterior nucleus
- (B) Centromedian nucleus
- (C) Lateral geniculate nucleus
- (D) Mediodorsal nucleus
- (E) Pulvinar
- (F) Ventral anterior nucleus
- (G) Ventral lateral nucleus
- (H) VPL nucleus
- (I) VPM nucleus

Match each of the following descriptions with the appropriate thalamic nucleus.

8. Receives input from the ipsilateral central tegmental tract

9. Has reciprocal connections with the inferior parietal lobule

10. Receives input from the contralateral lateral spinothalamic tract

11. Projects to the putamen

- 12.** Receives the dentatohalamic tract
- 13.** Plays a role in the expression of affect, emotion, and behavior (limbic function)

Questions 14 to 18

The response options for items 14 to 18 are the same. Select one answer for each item in the set.

- (A) Anterior nucleus
- (B) Medial geniculate (nucleus) body
- (C) VPL nucleus
- (D) VPM nucleus
- (E) Ventral lateral nucleus

Match each pathway with the appropriate nucleus to which it gives input.

- 14.** Brachium of the inferior colliculus
- 15.** Thalamic fasciculus (H_1)
- 16.** Mammillothalamic tract
- 17.** Dentatohalamic tract
- 18.** Gustatory (taste) pathway
- 19.** The sexually dimorphic nucleus is located in the:
 - (A) anterior nucleus.
 - (B) arcuate nucleus.
 - (C) medial preoptic nucleus.
 - (D) posterior nucleus.
 - (E) ventromedial nucleus.
- 20.** A 40-year-old woman who has taken birth control pills has a 4-month history of amenorrhea and a bitemporal hemianopia that began as a bitemporal quadrantanopia. What is the most likely cause of these deficits?
 - (A) Aneurysm of the anterior communicating artery
 - (B) Cavernous sinus meningioma
 - (C) Optic glioma
 - (D) Pituitary adenoma
 - (E) Sella turcica meningioma

21. Which of the following statements concerning the hypothalamus is correct?

- (A) It is a division of the subthalamus
- (B) It contains the tuberculum cinereum
- (C) Its suprachiasmatic nucleus receives input from retina

- (D) It is not related to the limbic system
- (E) Its dorsomedial and the ventromedial nuclei are separated by the striae medullares

22. Which of the following is a hypothalamic structure?

- (A) Alveus
- (B) Arcuate
- (C) Column
- (D) Crus
- (E) Fimbria

Questions 23 to 29

The response options for items 23 to 29 are the same. Select one answer for each item in the set.

- (A) Dorsal longitudinal fasciculus
- (B) Fornix
- (C) Medial forebrain bundle
- (D) Mammillary peduncle
- (E) Stria terminalis

Match each description below with the structure it best describes.

- 23.** Extends from the posterior hypothalamic nucleus to the caudal medulla
- 24.** Interconnects the hypothalamus and the amygdaloid complex
- 25.** Is the largest projection to the hypothalamus
- 26.** Connects the septal area to the midbrain tegmentum
- 27.** Conducts fibers from the hippocampal formation to the mammillary nucleus
- 28.** Lies between the caudate nucleus and the thalamus
- 29.** Separates the medial hypothalamus from the lateral hypothalamus

Questions 30 to 38

The response options for items 30 to 38 are the same. Select one answer for each item in the set.

- (A) Anorexia
- (B) Craniopharyngioma
- (C) Diabetes insipidus
- (D) Hyperthermia
- (E) Inability to thermoregulate
- (F) Obesity and savage behavior

- (G) Pituitary adenoma
(H) Wernicke encephalopathy

Match each description below with the appropriate clinical condition.

30. Amenorrhea and galactorrhea
31. Hemorrhagic lesions in the mammillary bodies
32. Associated with the Rathke pouch
33. Destruction of the anterior hypothalamic nuclei

34. Stimulation of the ventromedial nuclei
35. Bilateral lesions of the ventromedial hypothalamic nuclei
36. Bilateral lesions of the posterior hypothalamic nuclei
37. Destruction of the supraoptic and paraventricular nuclei
38. Results from thiamine (vitamin B₁) deficiency

Answers and Explanations

1–D. The ventral lateral nucleus receives motor input from the extrapyramidal (striatal) motor system (globus pallidus and substantia nigra) and from the cerebellum (dentate nucleus).

2–D. Spinothalamic fibers project to the VPL nucleus, which receives the medial lemniscus.

3–D. Cerebellar fibers (dentatocerebellar) project to the ventral lateral and VPL nuclei, which in turn project to the motor cortex (area 4).

4–B. The globus pallidus, a nucleus of the extrapyramidal (striatal) motor system, projects to three thalamic nuclei: the centromedian, the ventral anterior, and the ventral lateral nuclei of the thalamus.

5–A. Radioactive label is found in the anterior nucleus of the thalamus, which receives input from the mammillary nucleus via the mammillothalamic tract. The arcuate nucleus of the hypothalamus projects to the portal vessels of the infundibulum via the tuberohypophyseal (tuberoinfundibular) pathway; the ventral anterior nucleus of the thalamus receives input from the globus pallidus and the substantia nigra; the dorsomedial nucleus of the thalamus receives input from the amygdala, temporal neocortex and substantia nigra; and the supraoptic nucleus of the hypothalamus synthesizes vasopressin and oxytocin and projects to the pituitary.

6–D. Infarction of the internal capsule gives rise to contralateral symptoms. Thus, infarction to the right internal capsule would result in left-sided symptoms, including tactile hypesthesia, contralateral anesthesia, contralateral hemiparesis (with the Babinski sign), contralateral lower facial weakness, and contralateral homonymous hemianopia.

7–C. A capsular stroke is most commonly caused by occlusion of the lateral striate branches of the middle cerebral artery.

8–I. The VPM nucleus receives taste input via the ipsilateral central tegmental tract. The VPM nucleus receives sensory input from the head and oral cavity.

9–E. The pulvinar, the largest thalamic nucleus, has reciprocal connections with the inferior parietal lobule.

10–H. The VPL nucleus receives input from the contralateral lateral spinothalamic tract.

11–B. The centromedian nucleus projects to the putamen; this thalamic nucleus also has reciprocal connections with the motor cortex.

12–G. The ventral lateral nucleus receives contralateral cerebellar input via the dentatothalamic tract.

13–D. The mediodorsal nucleus plays a role in the expression of affect, emotion, and behavior (limbic function). It receives input from the amygdala and has reciprocal connections with the prefrontal cortex. Lesions of the mediodorsal nucleus are found in patients with the Korsakoff amnesic state.

14–B. The medial geniculate body receives auditory input via the brachium of the inferior colliculus.

15–E. The ventral lateral nucleus receives input from the globus pallidus via the thalamic fasciculus (H_1).

16–A. The anterior nucleus receives input from the mammillary nuclei via the mammillothalamic tract. This is a major link in the Papez circuit.

17–E. The ventral lateral nucleus receives cerebellar input from the dentate nucleus via the dentatothalamic tract.

- 18–D.** The VPM nucleus receives SVA (taste) fibers from the central tegmental tract.
- 19–C.** The sexually dimorphic nucleus is located in the medial preoptic nucleus of the preoptic region.
- 20–D.** A pituitary adenoma is characterized by amenorrhea and visual field defects, specifically a bitemporal hemianopia. The amenorrhea–galactorrhea syndrome includes visual abnormalities, amenorrhea, galactorrhea, and elevated serum prolactin.
- 21–C.** The suprachiasmatic nucleus of the hypothalamus receives direct input from the retina and plays a role in the control of circadian rhythms. The tuberculum cinereum overlies the spinal trigonal nucleus. The limbic system has reciprocal connections with the hypothalamus. The striae medullares separate the dorsal aspect of the pons from the dorsal aspect of the medulla.
- 22–B.** The arcuate nucleus is a periventricular nucleus in the tuber cinereum. It contains neurons that produce hypothalamic-releasing factors and gives rise to the tuberohypophyseal tract. The alveus, fimbria, crus, and column are components of the fornix.
- 23–A.** The dorsal longitudinal fasciculus extends from the posterior hypothalamic nucleus to the caudal medulla and projects to autonomic centers of the brainstem. It contains both ascending and descending fibers.
- 24–E.** The amygdaloid complex is interconnected with the hypothalamus via the stria terminalis and the ventral amygdalofugal pathway.
- 25–B.** The fornix contains 2.7 million fibers and is the largest projection to the hypothalamus.
- 26–C.** The medial forebrain bundle interconnects the septal area, the hypothalamus, and the midbrain tegmentum.
- 27–B.** The fornix projects from the subiculum of the hippocampal formation to the mammillary nucleus of the hypothalamus. The fornix projects to the anterior nucleus of the thalamus, septal nuclei, lateral preoptic region, and the nucleus of the diagonal band of Broca.
- 28–E.** The stria terminalis lies in the sulcus terminalis with the vena terminalis, separates the head of the caudate nucleus from the thalamus, and interconnects the amygdaloid nuclear complex with the hypothalamus.
- 29–B.** The column of the fornix lies between the medial and lateral hypothalamus.
- 30–G.** Amenorrhea and galactorrhea result from a prolactin-secreting pituitary adenoma, the most common type of pituitary adenoma.
- 31–H.** Hemorrhagic lesions in the mammillary bodies and in the periaqueductal gray of the midbrain are seen in Wernicke encephalopathy.
- 32–B.** Craniopharyngiomas—congenital epidermoid tumors—are derived from the Rathke pouch; they are the most common supratentorial tumors found in children.
- 33–D.** Destruction of the anterior hypothalamic nuclei results in hyperthermia.
- 34–A.** Stimulation of the ventromedial nuclei inhibits the urge to eat, resulting in emaciation (cachexia or anorexia). Destruction of these nuclei results in hyperphagia and savage behavior.
- 35–F.** Bilateral lesions of the ventromedial hypothalamic nuclei result in hyperphagia and savage behavior.
- 36–E.** Bilateral lesions of the posterior hypothalamic nuclei result in the inability to thermoregulate (poikilothermia). Bilateral destruction of only the posterior aspect of the lateral hypothalamic nucleus results in anorexia and emaciation.
- 37–C.** Destruction of the supraoptic and paraventricular nuclei or the supraopticohypophyseal tract results in diabetes insipidus with polydipsia and polyuria.
- 38–H.** Wernicke encephalopathy results from thiamine (vitamin B₁) deficiency.

Objectives

- List the three aspects of what human hear and how each is accomplished.
- Describe the components of the external, middle, and inner ears.
- Describe the Organ of Corti and the scalae.
- Differentiate between inner and outer hair cells.
- Differentiate between perilymph and endolymph.
- Describe the central auditory pathway, including a description of the bilateral nature of the information transmitted.
- Describe the tonotopic organization of the primary auditory cortex.
- Discriminate between conduction and nerve deafness.

I. INTRODUCTION

- an exteroceptive special somatic afferent (SSA) system.
- detects sound frequencies from 20 to 20,000 Hz.
- ordinary conversation ranges between 300 and 3000 Hz.
- functions over an intensity range of 120 decibels (dB) and can discriminate changes in intensity between 1 and 2 dB.
- characterized by tonotopic (pitch) localization at all levels of the neuraxis.
- there is a loss of high-frequency tones with advanced age.
- three aspects of what we hear:
 - location—a central nervous system comparison involving the superior olivary nuclei;
 - frequency—where along the basilar membrane vibration is the greatest;
 - amplitude—how many CN VIII fibers are recruited to fire.

II. OUTER, MIDDLE, AND INNER EAR**A. Outer ear**

- consists of an **auricle** and an external auditory **meatus**.
- separated from the middle ear by the **tympanic membrane**.
- conducts sound waves to the tympanic membrane and functions in sound localization.
- blockage (with wax) causes conduction deafness.

B. Middle ear (tympenic cavity)

- located within the temporal bone.
- serves as an amplifier and impedance-matching device.
- communicates with the nasopharynx via the auditory tube.
- receives sensory innervation from the glossopharyngeal nerve (CN IX).
- contains the **chorda tympani** of CN VII, which mediates taste sensation and parasympathetic input into the submandibular and sublingual glands.
- pathology results in conduction deafness.
- contains the following auditory structures:
 1. **Tympanic membrane**
 - receives airborne sound vibrations and transmits energy to the middle ear ossicles.
 2. **Middle ear ossicles**
 - consist of the **malleus**, **incus**, and **stapes**.
 - vibration of the tympanic membrane forces the footplate of the stapes into the oval window, creating a traveling wave in the perilymph-filled scala vestibuli.
 3. **Tensor tympani and stapedius**
 - innervated by the trigeminal and facial nerves (CN V and CN VII), respectively.
 - dampen vibrations of the ossicular chain, thus protecting the cochlea from loud low-frequency sounds (<1000 Hz).

C. Inner ear (membranous labyrinth) (Figure 14.1)

- derived from the otic placode of the rhombencephalon.
- located within the **bony labyrinth** of the temporal bone.
- receives its blood supply from the labyrinthine artery.
- contains the **cochlea**, which houses the following structures:
 1. **Scala vestibuli**
 - contains **perilymph**.
 - transmits traveling waves toward the **helicotrema**, **scala tympani**, and **round window**. Traveling waves spread throughout, but have the most effect on the portion of the basilar membrane that has the same resonant frequency, through the basilar membrane, and via the scala tympani to the round window.
 2. **Cochlear duct (scala media)**
 - contains the Organ of Corti.
 - contains **endolymph**.
 - lies between the scala vestibuli and scala tympani.
 3. **Organ of Corti**
 - contains hair cells and the tectorial membrane.
 - rests on and is supported by the basilar membrane.
 4. **Hair cells**
 - auditory receptor cells that have **stereocilia** (microvilli) and no kinocilium. The stereocilia of the outer hair cells are embedded in the overlying tectorial membrane.
 - mechanoreceptors transduce mechanical (sound) energy into generator potentials.
 - stimulated by vibrations of the basilar membrane.
 - innervated by bipolar neurons of the spiral ganglion.
 - receive efferent input via the olivocochlear bundle.
 5. **Basilar membrane**
 - separates the cochlear duct from the scala tympani.
 - pitch localization along its length: 20 Hz at the apex and 20,000 Hz at the base of the cochlea.
 - vibration results in deformation of the hair cell microvilli against the tectorial membrane; this action serves as the adequate stimulus.
 6. **Spiral ganglion (of CN VIII)**
 - located in the **bony modiolus** of the cochlea.
 - consists of bipolar neurons of the cochlear division of the vestibulocochlear nerve (CN VIII).

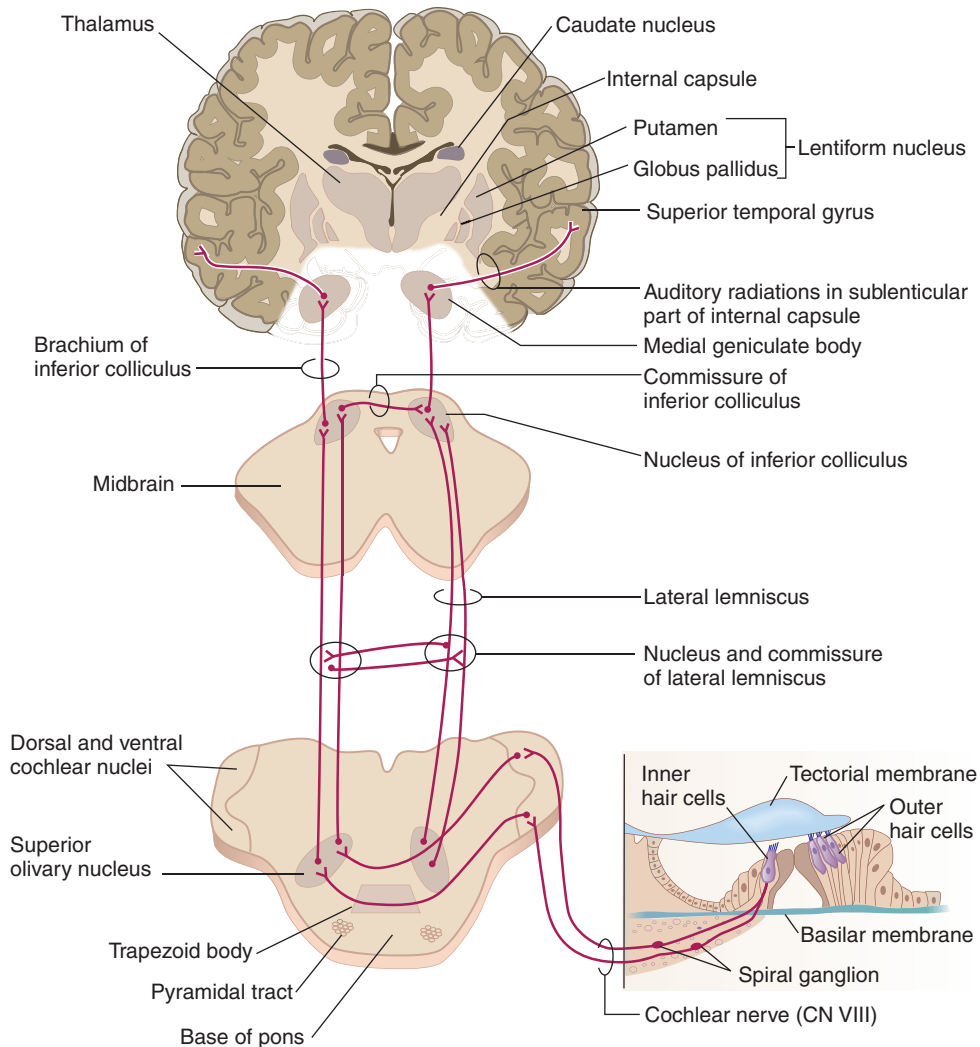


FIGURE 14.1. Peripheral and central connections of the auditory system. This system arises primarily from the inner hair cells of the Organ of Corti and terminates in the superior temporal gyrus. It is characterized by bilateral projections and tonotopic localization of pitch at all levels beyond the cochlear nuclei. *CN* = cranial nerve. (Modified from Fix JD. *High-Yield Neuroanatomy*. 3rd ed. Philadelphia, PA: Lippincott Williams & Wilkins; 2005:83.)

III. AUDITORY PATHWAY (SEE FIGURE 14.1)

- characterized by reciprocal connections throughout its caudorostral extent and by multiple decussations at all levels above the cochlear nuclei.
- consists of the following structures:

A. Hair cells of the Organ of Corti

- innervated by peripheral processes of bipolar cells of the spiral ganglion.
- consists of two types:
 1. **Inner hair cells**
 - synapse with numerous afferent fibers, each of which makes contact with only one hair cell; the majority of fibers in the cochlear nerve come from the inner hair cells.

2. Outer hair cells

- contractile and embedded in tectorial membrane.
- synapse with afferent fibers that contact numerous other outer hair cells.
- outnumber the inner hair cells in the ratio 3:1.
- vibration of the basilar membrane causes contraction leading to movement of the tectorial membrane which causes movement of endolymph that stimulates inner ear cells.

B. Bipolar cells of the spiral (cochlear) ganglion

- project peripherally to hair cells of the Organ of Corti.
- project centrally as the **cochlear nerve** to the dorsal and ventral cochlear nuclei of the medullo-pontine junction.

C. Cochlear nerve (CN VIII) (see Figures 1.1, 9.5, and 14.1)

- extends from the spiral ganglion to the cerebellopontine angle, where it enters the brainstem.

D. Cochlear nuclei

- the only auditory nuclei that do not receive binaural input.
- damage results in unilateral deafness.
 1. **Dorsal cochlear nucleus**
 - underlies the acoustic tubercle of the floor of the fourth ventricle.
 - receives input from the cochlear nerve (CN VIII).
 - projects to the contralateral cochlear nuclei.
 2. **Ventral cochlear nucleus**
 - receives input from the cochlear nerve (CN VIII).
 - projects bilaterally to the superior olivary nuclei.
 - projects lateral lemniscus.
 - gives rise to the trapezoid body.

E. Superior olivary nucleus

- located in the pons at the level of the facial motor nucleus.
- receives input from the ventral cochlear nuclei.
- projects bilaterally to the lateral lemniscus.
- plays a role in sound localization and binaural processing.
- gives rise to the efferent olivocochlear bundle, a cochlear feedback pathway.

F. Trapezoid body

- located in the caudal pontine tegmentum at the level of the abducent nucleus.
- transversed by intra-axial abducent fibers of CN VI.
- contains decussating fibers from the ventral cochlear nucleus.

G. Lateral lemniscus

- receives input from the contralateral cochlear nuclei.
- receives input from the superior olivary nuclei.
- connected to the contralateral lateral lemniscus via commissural fibers.
- projects to the nucleus of the inferior colliculus.

H. Nucleus of the inferior colliculus

- receives input from the lateral lemniscus.
- projects via the **brachium of the inferior colliculus** to the medial geniculate body of the thalamus.
- projects to the superior colliculus to mediate audiovisual reflexes.

I. Medial geniculate body (see Figures 1.6 and 14.1)

- receives input from the nucleus of the inferior colliculus.
- projects via the sublenticular portion of the internal capsule (**auditory radiation**) to the primary auditory cortex, the superior temporal gyrus (transverse gyri of Heschl) (areas 41 and 42).
- projects to the amygdala.

J. Superior temporal gyrus (transverse temporal gyri of Heschl) (see Figure 14.1)

- tonotopic arrangement mirrors basilar membrane.
- contain the primary auditory cortex (areas 41 and 42).
- receive auditory input via the auditory radiation.
- project to the auditory association cortex (area 22).

IV. EFFERENT COCHLEAR (OLIVOCOCHLEAR) BUNDLE

- a crossed and uncrossed tract that arises from the superior olivary nucleus and projects to the hair cells of the Organ of Corti.
- suppresses auditory nerve activity when stimulated.
- plays a role, through inhibition, in “auditory sharpening.”

V. HEARING DEFECTS

- may be classified as:

A. Conduction deafness

- caused by interruption of the passage of sound waves through the external or middle ear.
- includes the following causes:
 1. **Obstruction by wax (cerumen) or a foreign body** in the external auditory meatus
 2. **Otosclerosis**
 - produced by neogenesis of the labyrinthine spongy bone around the oval window, resulting in fixation of the stapes.
 - the most frequent cause of progressive conduction deafness.
 3. **Otitis media**
 - an **inflammation of the middle ear**.
 - the most common cause of meningitis (excluding meningococcus) and the most common cause of brain abscesses.

B. Nerve deafness (sensorineural or perceptive deafness)

- owing to **disease** of the cochlea, cochlear nerve, or central auditory pathway (acoustic neuroma).
- can result from the **action of drugs and toxins** (e.g., quinine, aspirin, streptomycin).
- can be the result from **prolonged exposure to loud noise**.
- can result from **rubella infection in utero**, cytomegalovirus, or syphilis.
- include the following:
 1. **Presbycusis**
 - **hearing loss occurring with aging**. It results from degenerative disease of the Organ of Corti in the first few millimeters of the basal coil of the cochlea (high-frequency loss of 4000–8000 Hz).
 - the most common cause of hearing loss.
 2. **Acoustic neuroma** (schwannoma or neurilemoma) (see Figure 12.4)
 - consists of a peripheral nerve tumor of the vestibulocochlear nerve (CN VIII).
 - located in the internal auditory meatus or in the cerebellopontine angle of the posterior cranial fossa.
 - includes symptoms such as **unilateral deafness** and **tinnitus** (ear ringing).

VI. TUNING FORK TESTS

- used to distinguish between conduction deafness and nerve deafness (sensorineural deafness).
- compare air conduction with bone conduction.

A. Weber test (Table 14.1)

- Performed by placing a vibrating tuning fork on the vertex of the skull.
- Normal subject hears equally on both sides.
- Patient with unilateral conduction deafness hears the vibration louder in the diseased ear.
- Patient with unilateral partial nerve deafness hears the vibration louder in the normal ear.

B. Rinne test (see Table 14.1)

- Compares air and bone conduction.
- Performed by placing a vibrating tuning fork on the mastoid process until it is no longer heard; then it is held in front of the ear.
- Normal subject hears vibration in the air after bone conduction is gone.
- Patient with unilateral conduction deafness fails to hear vibrations in the air after bone conduction is gone.
- Patient with unilateral partial nerve deafness hears vibrations in the air after bone conduction is gone.

C. Schwabach test

- compares bone conduction of a patient with that of a person with normal hearing.
- demonstrates bone conduction to be better than normal in cases of conduction deafness.
- demonstrates bone conduction to be less than normal in cases of nerve deafness.

VII. BRAINSTEM AUDITORY EVOKED RESPONSE (BAER) (FIGURE 14.2)

- A noninvasive method used to evaluate the integrity of the auditory pathways.
- Clicks are delivered to the ear and recorded via scalp electrodes.
- Seven waves (I–VII) correspond to the auditory nerve, cochlear nuclei, superior olivary nucleus, lateral lemniscus, inferior colliculus, medial geniculate body, and auditory radiations.
- Used to assess hearing in young children and to diagnose brainstem lesions (multiple sclerosis) and acoustic neuromas of the posterior fossa.

table 14.1 Tuning Fork Test Results

Otologic Finding	Weber Test	Rinne Test
Conduction deafness (left ear)	Lateralizes to left ear	BC > AC on left AC > BC on right
Conduction deafness (right ear)	Lateralizes to right ear	BC > AC on right AC > BC on left
Nerve deafness (left ear)	Lateralizes to right ear	AC > BC, both ears
Nerve deafness (right ear)	Lateralizes to left ear	AC > BC, both ears
Normal ears	No lateralization	AC > BC, both ears

Conduction deafness = middle ear deafness (e.g., otosclerosis, otitis media); nerve deafness = sensorineural deafness (e.g., presbycusis);
AC = air conduction; BC = bone conduction.

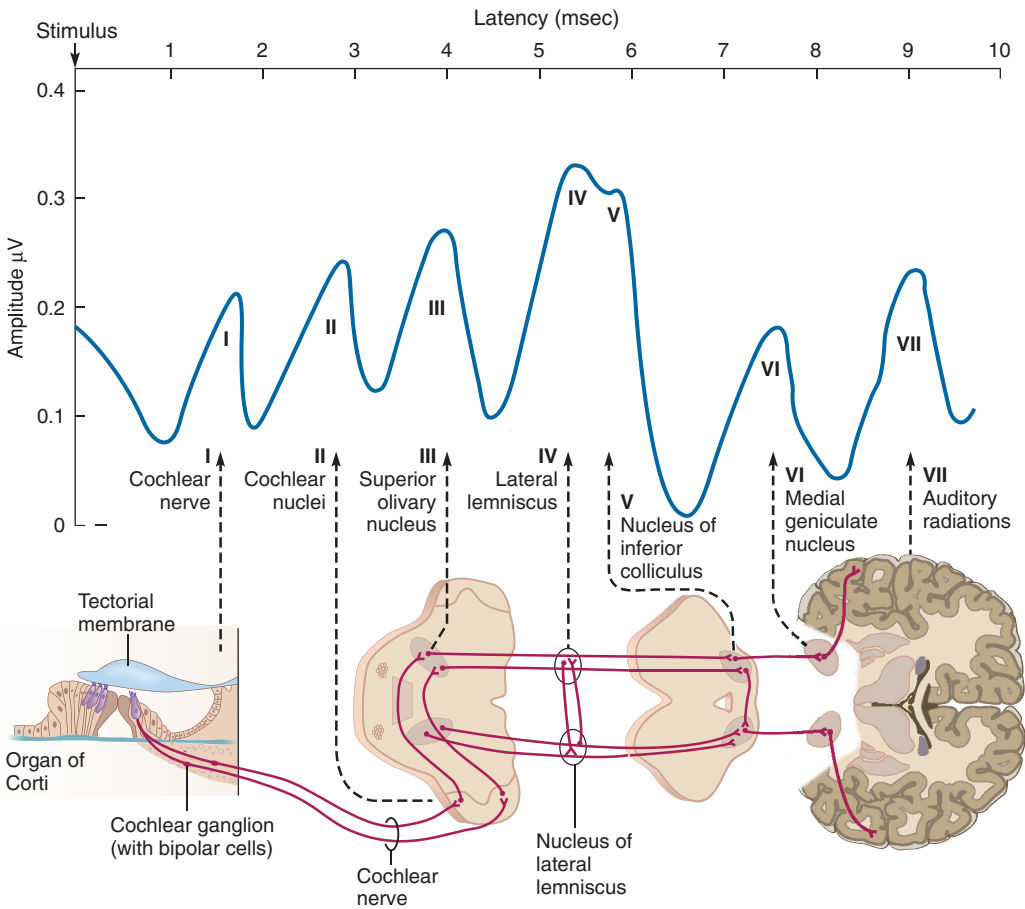


FIGURE 14.2. Graphic representation of brainstem auditory evoked responses. The seven waves (I–VII) correspond to way stations in the auditory pathway. (Adapted with permission from Stockard JJ, Stockard JE, Sharbrough FW. Detection and localization of occult lesions with brainstem auditory responses. *Mayo Clin Proc.* 1977;52:761–769. Modified from original drawing by Ellen Grass.)

Review Test

1. A 70-year-old woman has the following Weber and Rinne test results:

Test	Left Ear	Right Ear
Weber	No lateralization	Lateralization
Rinne	AC > BC	BC > AC

With which one of the following conditions are the patient's otologic findings most consistent?

- (A) Otosclerosis involving the left ear
- (B) Otosclerosis involving the right ear
- (C) Presbycusis involving the left ear
- (D) Presbycusis involving the right ear
- (E) A normal examination

2. Frequency is analyzed in the inner ear by the:

- (A) Organ of Corti.
- (B) scala vestibuli.
- (C) spiral ganglion.
- (D) stapes.
- (E) tensor tympani.

3. At what level of the auditory pathway does the abnormal latency of wave V of a BAER test correspond to a problem in sound transmission?

- (A) Cochlear nuclei
- (B) Lateral lemniscus
- (C) Medial geniculate nucleus
- (D) Nucleus of inferior colliculus
- (E) Superior olivary nucleus

4. A 2-year-old girl presents at the doctor's office with congestion and a fever of 102°F. Her mother reports that she has been coughing and

occasionally pulls at her right ear. What is the most likely diagnosis?

- (A) Acoustic neuroma
- (B) Otitis media
- (C) Otosclerosis
- (D) Presbycusis
- (E) Wax obstruction

5. A 35-year-old male drummer of a heavy metal band complains of hearing loss. He reports hearing the vibration from the Weber test louder in his right ear, and his Rinne test is normal. The most likely explanation for his hearing loss is:

- (A) conduction deafness caused by obstruction.
- (B) conduction deafness caused by otosclerosis.
- (C) nerve deafness caused by cochlear nerve disease.
- (D) nerve deafness caused by prolonged exposure to noise.
- (E) nonduction deafness caused by exposure to heavy metal drums.

6. Presbycusis results from degeneration of the:

- (A) bipolar cells of the cochlear ganglion.
- (B) cochlear nerve.
- (C) dorsal cochlear nucleus.
- (D) Organ of Corti.
- (E) ventral cochlear nucleus.

7. One component of the inner ear is the:

- (A) auricle.
- (B) incus.
- (C) meatus.
- (D) Organ of Corti.
- (E) scala vestibuli.

Answers and Explanations

1–B. The woman has otosclerosis involving the right ear. A patient with unilateral conduction deafness hears the vibration more loudly in the affected ear, and bone conduction is greater than air conduction. Otosclerosis is a conduction defect that involves the ossicles of the middle ear. The most common type of hearing loss in adults, it has a strong autosomal dominant inheritance pattern. Presbycusis, the most common cause of sensorineural hearing loss in adults, affects the cochlea or the cochlear nerve (CN VIII).

2–A. The Organ of Corti, or spiral organ, is a frequency analyzer of the inner ear. It contains hair cells and the tectorial membrane; it rests on and is supported by the basilar membrane. The Organ of Corti is contained within the cochlear duct.

3–D. Wave V corresponds to the nucleus of the inferior colliculus. Wave I, cochlear nerve; wave II, cochlear nuclei; wave III, superior olivary nucleus; wave IV, lateral lemniscus; wave VI, medial geniculate nucleus; and wave VII, auditory radiations.

4–B. The most likely diagnosis is otitis media, commonly known as an ear infection. Acute otitis media is often associated with upper respiratory tract infections. Children are more prone to ear infections because their eustachian tubes are shorter and more horizontal than those of adults and are therefore more easily blocked.

5–D. The most likely cause of nerve deafness, or sensorineural hearing loss, in this patient is prolonged exposure to loud noise. Because the Rinne test was normal and the Weber test lateralized to his right ear, this patient has nerve deafness in his left ear. Conduction deafness is caused by interruption of the passage of sound waves through the external or middle ear, such as wax obstruction, otosclerosis or otitis media.

6–D. Presbycusis results from degenerative disease of the Organ of Corti in the first few millimeters of the basal coil of the cochlea (high-frequency loss of 4000 to 8000 Hz). Presbycusis is hearing loss that occurs as a natural process of aging.

7–B. The middle ear contains the incus, which together with the stapes and malleus make up the three middle ear ossicles. The middle ear also contains the tensor tympani and stapedius. Its lateral border is the tympanic membrane.

Objectives

- Differentiate between static and dynamic equilibrium.
- Describe the function and structure of the semicircular canals; include a description of the structure of the crista ampullaris.
- Describe the function and structure of the maculae of the utricle and saccule.
- Describe the central vestibular pathway, including a description of the targets of the vestibular system projections.
- Describe the vestibule-ocular reflex and nystagmus, including nuclei and pathways involved in each.
- Differentiate between decerebrate and decorticate rigidity.
- Discuss various clinical correlates related to the vestibular system.

I. INTRODUCTION

- a special somatic afferent (**SSA**) proprioceptive system.
- maintains **posture** and **equilibrium** and coordinates **head** and **eye movements**.
- functions in concert with the cerebellum and the visual system.
- contains receptors (hair cells) in the labyrinth of the temporal bone.

II. LABYRINTH (FIGURE 15.1)

- constitutes the inner ear (**auris interna**) of the temporal bone.

A. Structure**1. Bony labyrinth**

- a series of cavities (cochlea, vestibule, and semicircular canals) that house the membranous labyrinth.
- contains **perilymph**, which fills the space between the bony labyrinth and the membranous labyrinth.

2. Membranous labyrinth

- suspended within the bony labyrinth.
- filled with **endolymph**.
- contains receptor (or hair) cells that are bathed in endolymph.

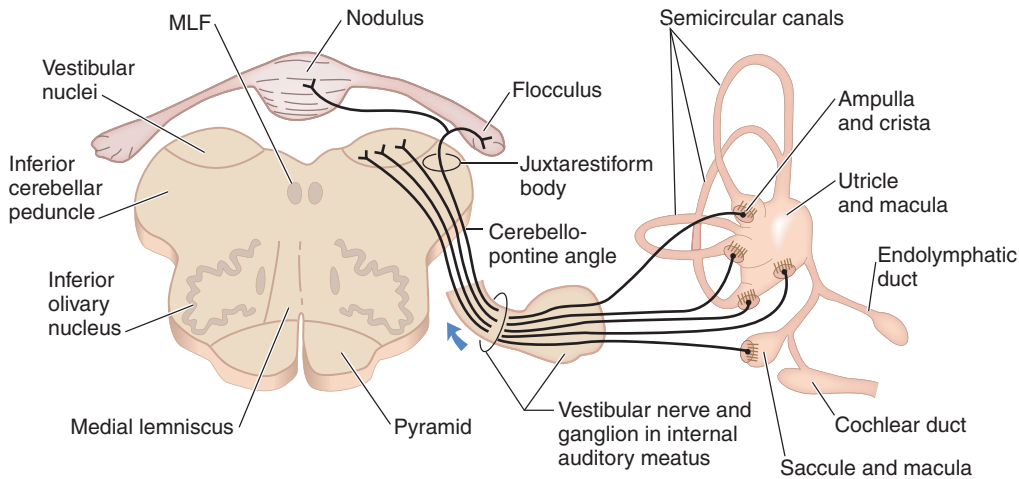


FIGURE 15.1. Connections of the vestibular system. The hair cells of the cristae ampullares and the maculae of the utricle and saccule project through the vestibular nerve to the vestibular nuclei of the medulla and pons and the flocculonodular lobe of the cerebellum (vestibulocerebellum). *MLF* = medial longitudinal fasciculus. (Modified from Fix JD. *High-Yield Neuroanatomy*. 3rd ed. Philadelphia, PA: Lippincott Williams & Wilkins; 2005:85.)

B. Function

1. Semicircular canal system (kinetic labyrinth)

- detects and responds to angular acceleration and deceleration of the head.
- consists of **three semicircular canals**.
- includes the following structures:
 - a. **Three semicircular ducts**
 - anterior, posterior, and lateral structures that lie in perpendicular planes; each membranous semicircular duct lies within a semicircular canal.
 - contain hair cells.
 - b. **Hair cells**
 - embedded in the cupulae of the cristae ampullares.
 - bathed in endolymph.
 - contain one kinocilium and many stereocilia.
 - innervated by bipolar cells of the vestibular ganglion (Scarpa ganglion).
 - receive inhibitory input from vestibular nuclei.
 - stimulated by endolymphatic flow. Flow toward the kinocilium is excitatory, whereas the flow away from the kinocilium is inhibitory.

2. Utricle and saccule (static labyrinth)

- detect and respond to the position of the head with respect to **linear acceleration** and pull of **gravity**.
- endolymph-containing dilations of the membranous labyrinth.
- located within the vestibule of the bony labyrinth.
- contain hair cells in the maculae of the utricle and the saccule. Both utricle and saccule respond to **head tilt**.
 - a. **Maculae of the utricle and saccule ("otolith organs")**
 - two patches of sensory epithelium.
 - consist of supporting cells and hair cells.
 - exert a tonic influence on the body musculature, reinforce muscle tone, and excite the muscle contractions necessary for the maintenance of equilibrium.
 - essential to the static, postural, tonic neck, and righting reflexes.
 - The utricular macula is disposed in the horizontal plane. It is maximally stimulated when the head is bent forward or backward or side to side.
 - The saccular macula is disposed in the vertical plane. It is maximally stimulated when the head is bent forward or backward or up-and-down.
 - b. **Hair cells**
 - structurally similar to those of the cristae ampullares.

- embedded in the gelatinous **otolithic membrane**, which contains calcareous otolith crystals.
- stimulated by the shearing effect of the otolithic membrane during head movements.
- receive an efferent innervation from the vestibular nuclei of the brainstem.

C. Fluids of the labyrinth

1. Perilymph

- resembles extracellular fluid, plasma, and cerebrospinal fluid and surrounds the membranous labyrinth (in the perilymphatic space).
- communicates with the subarachnoid space via the cochlear aqueduct.
- has an unknown site of production and absorption.

2. Endolymph

- resembles intracellular fluid and is found within the membranous labyrinth (endolymphatic space).
- secreted by the **stria vascularis** of the cochlear duct.

III. VESTIBULAR PATHWAYS (FIGURE 15.2; SEE FIGURE 15.1)

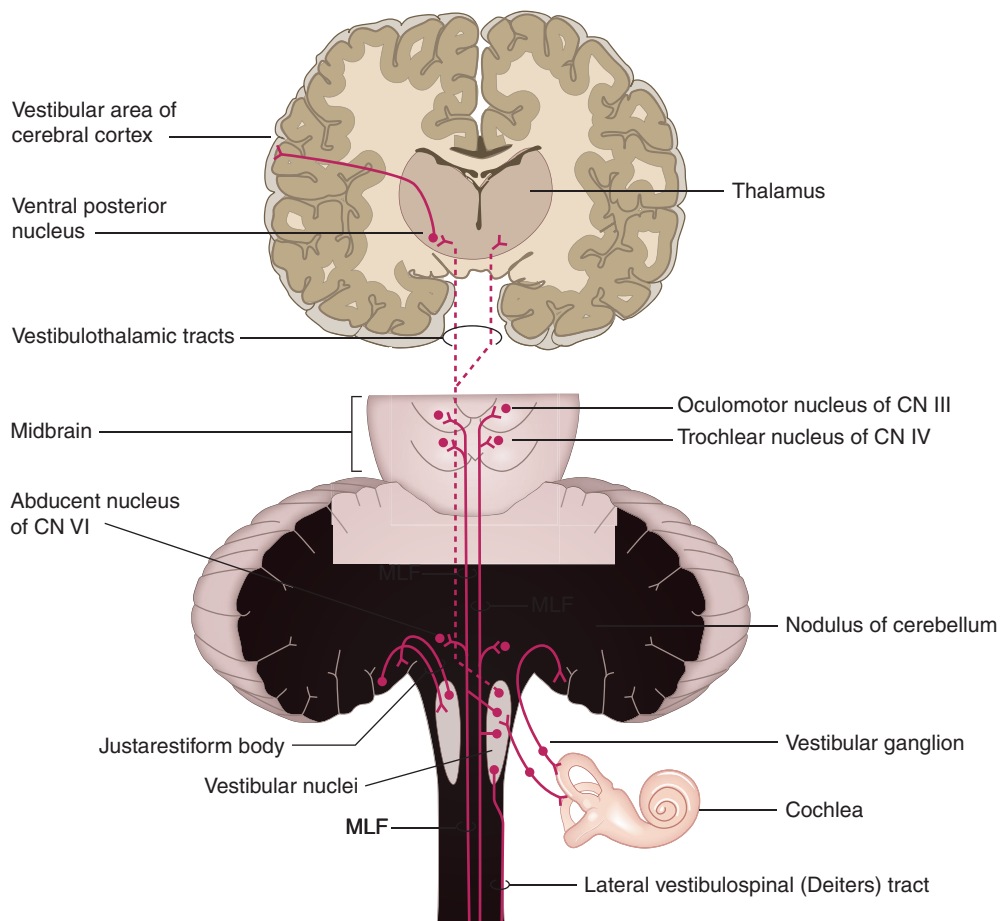


FIGURE 15.2. Major central connections of the vestibular system. Vestibular nuclei project through the ascending MLFs to the oculomotor nuclei and subserve vestibulo-ocular reflexes. Vestibular nuclei also project through the descending MLFs and the lateral vestibulospinal tracts to the anterior horn motor neurons of the spinal cord and mediate postural reflexes. *CN* = cranial nerve. (Modified from Fix JD. *High-Yield Neuroanatomy*. 3rd ed. Philadelphia, PA: Lippincott Williams & Wilkins; 2005:86.)

A. Hair cells (see II B)

B. Bipolar neurons of the vestibular ganglion (see Figure 15.1)

- located in the lateral end of the **internal auditory meatus**.
- project, via their peripheral processes, to hair cells.
- project their central processes, as the **vestibular nerve**, to the **vestibular nuclei** of the medulla and pons, and via the **juxtarestiform body** to the **flocculonodular lobe** of the cerebellum (vestibulocerebellum).

C. Vestibular nuclei (see Figures 9.4 through 9.6)

- include the inferior, medial, superior, and lateral nuclei.
 - 1. Receive input from the following structures:**
 - Bipolar neurons of the vestibular ganglion
 - Flocculonodular lobe and uvula of the cerebellum
 - Vermis of the anterior lobe of the cerebellum
 - Vestibular nuclei of the contralateral side
 - Fastigial nuclei of the cerebellum
 - 2. Project fibers to the following structures:**
 - **Flocculonodular lobe and uvula of the cerebellum**
 - **Vestibular nuclei of the contralateral side**
 - **Inferior olivary nucleus**
 - a. receives input via the vestibulo-olivary tract.
 - b. mediates vestibular influence to the caudal vermis of the cerebellum.
 - **Abducent, trochlear, and oculomotor nuclei**
 - a. receive input via the medial longitudinal fasciculus (**MLF**).
 - **Anterior horn motor neurons**
 - a. receive vestibular input from two descending pathways:
 - **MLF**
 - (1) contains fibers from the medial vestibular nucleus that terminate in cervical and upper thoracic levels.
 - (2) coordinates head, neck, and eye movements.
 - **Vestibulospinal tract**
 - (1) contains fibers from the ipsilateral lateral vestibular nucleus and is found at all spinal cord levels.
 - (2) facilitates extensor muscle tone in the antigravity muscles, thus maintaining upright posture.
 - **Ventral posterior nuclei of the thalamus**
 - a. receive bilateral input from the vestibular nuclei.

D. Ventral posterior nuclei of the thalamus

- project to the primary vestibular cortex of the parietal lobe.

IV. EFFERENT VESTIBULAR CONNECTIONS

- arise from neurons in the vestibular nuclei.
- exit the brainstem with the vestibular nerve and innervate hair cells in the cristae ampullares and maculae of the utricle and saccule.
- modulate the firing rate of vestibular nerve fibers.

V. MEDIAL LONGITUDINAL FASCICULUS

- extends from the spinal cord to the rostral midbrain.
- contains ascending vestibulo-ocular fibers to the ocular motor nuclei of CNs III, IV, and VI.

- contains a descending medial vestibulospinal tract that coordinates head and eye movements.
- mediates adduction of the eyeball in lateral conjugate gaze.
- mediates vestibular nystagmus.
- Transection results in medial rectus palsy on attempted lateral gaze.

VI. VESTIBULO-OCULAR REFLEXES

- consist of reflex movement of the eyes to compensate for head movement to keep objects of interest on the center of the retina.
- can be tested in conscious or unconscious subjects by stimulating the kinetic labyrinth.
- afferent limb is CN III.
- efferent limb is CNs III, IV, and VI.

A. Oculocephalic reflex (doll's head eye movements) (Figure 15.3)

- normally suppressed vestibulo-ocular reflex.
 - 1. Test method**
 - consists of rapid movement of the head in horizontal or vertical planes.
 - 2. Test results**
 - With intact proprioception and brainstem (vestibular nuclei), the eyes move conjugately in the opposite direction.
 - Doll's head eye movements are absent or abnormal when lesions of the vestibular nuclei and MLFs are present.

B. Vestibular nystagmus

- consists of involuntary to-and-fro, up-and-down, or rotary movements of one or both eyes.
- consists of a slow component, opposite the direction of rotation, and a fast compensatory component, in the direction of rotation.
- named after the fast component.
- results from the stimulation of hair cells within the semicircular ducts on rotation.

C. Postrotational nystagmus

- 1. Test method**
 - The subject is rotated several times in the same direction and then is suddenly stopped.
- 2. Test results**
 - The subject with normal labyrinths will have a horizontal nystagmus opposite the direction of rotation (fast phase).

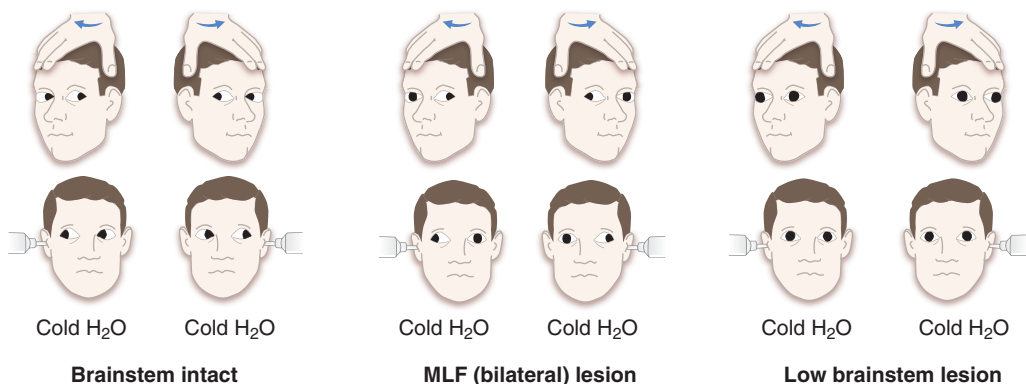


FIGURE 15.3. Ocular reflexes in comatose patients. The external auditory meatus is irrigated with cold water. If the brainstem is intact, the eyes deviate toward the irrigated side. If the MLFs are transected, the eyes deviate toward the side of the abducted eye only. With lower brainstem damage, the eyes do not deviate from the midline. (Adapted with permission from Plum F, Posner GB. *The Diagnosis of Stupor and Coma*. 3rd ed. Philadelphia, PA: FA Davis; 1982:55.)

- The subject will past-point and tend to fall in the direction of rotation, and experience a sensation of turning (vertigo) to the opposite side.

D. Caloric nystagmus (see Figure 15.3)

- induced with cold- or hot-water irrigation of the external auditory meatus.
- used to stimulate each labyrinth separately.
- used to evaluate unconscious patients.
- used to stimulate individual semicircular canals.
 1. **Test method (used to stimulate the horizontal semicircular canal)**
 - While sitting erect, the subject tilts the head back 60°, or the recumbent subject elevates the head 30° from a horizontal position.
 - Cold or hot water is syringed into the external auditory meatus.
 2. **Test results**
 - Cold-water irrigation results in nystagmus to the opposite side and past-pointing and falling to the same side.
 - Hot-water irrigation results in the reverse reactions.
 - Remember the mnemonic **COWS** = **C**old, **O**pposite; **W**arm, **S**ame.
 3. **Test results (in comatose subjects)**
 - No nystagmus is seen.
 - With the brainstem intact, the eyes deviate to the side of cold irrigation.
 - With bilateral MLF transection, the abducting eye deviates to the side of cold irrigation.
 - With lower brainstem damage to vestibular nuclei, the eyes do not deviate.

VII. DECEREBRATE AND DECORTICATE RIGIDITY

- Descending vestibulospinal and pontoreticulospinal pathways play an important role in the control of extensor muscle tone.
- Transection of the brainstem or decortication results in a tremendous increase in antigravity tone.

A. Decerebrate rigidity (posturing)

- caused by a lesion that transects the brainstem between the red nucleus and the vestibular nuclei.
- results from the tonic activity of the pontine reticular formation and the lateral vestibular nucleus, which activate motor neurons that innervate extensor muscles.
- characterized by **opisthotonos**, which is extension, adduction, and hyperpronation of the arms and extension of the feet with plantarflexion.
- also known as **gamma rigidity**.
- can be abolished by section of the vestibular nerve, destruction of vestibular nuclei or the vestibulospinal tract, and rhizotomy.

B. Decorticate rigidity (posturing)

- usually results from lesions of the internal capsule or the cerebral hemisphere.
- results in posture that consists of flexion of the arm, wrist, and fingers with adduction in the upper extremity; with extension, internal rotation, and plantarflexion in the lower extremity.
- characterized by a motor pattern that is typical of chronic spastic hemiplegia.
- known as **bilateral spastic hemiplegia**, in the form of bilateral decorticate rigidity.

VIII. CLINICAL CORRELATIONS

A. Vertigo

- a sensation of irregular or whirling motion; it is an **illusion of movement**.

B. Ménière disease

- an inner ear disease associated with an **increase in endolymphatic fluid pressure**.
- characterized by episodic attacks of vertigo, tinnitus, hearing loss, nausea, vomiting, and a sensation of fullness and pressure in the ear.
- characterized by the presence of horizontal nystagmus during the attack. The fast phase is to the opposite ear; past-pointing and falling occur to the affected side.

C. Labyrinthitis

- characterized by **inflammation of the labyrinth**, which may result from bacterial, viral, or toxic (e.g., alcohol, quinine, salicylates) causes.
- exhibits the same symptoms seen in Ménière disease (see VIII B).

D. Labyrinthectomy**1. Unilateral labyrinthectomy**

- results in predominantly horizontal nystagmus directed to the opposite side.

2. Bilateral simultaneous labyrinthectomy

- does not give rise to nystagmus.

E. Benign positional vertigo

- the most common cause of recurrent vertigo.
- elicited by certain head positions; the paroxysm of vertigo is accompanied by nystagmus.
- not associated with hearing loss or tinnitus.
- results presumably from **cuprolithiasis** of the posterior semicircular duct (dislocation of the utricular macular otoliths).

F. Internuclear ophthalmoplegia (INO)

- consists of medial rectus paresis on attempted lateral gaze.
- associated with monocular horizontal nystagmus in the abducting eye and intact convergence.
- usually the result of a demyelinating plaque.
- most commonly seen in **multiple sclerosis**.

G. Acoustic schwannoma (vestibular schwannoma)

- arises from the vestibular nerve of CN VIII within the internal auditory canal.
- usually involves CN V, CN VII, and CN VIII.
- found in the cerebellopontine (CP) angle.
- causes symptoms such as unilateral loss of hearing, tinnitus, and vertigo.
- marked by a lack of response to caloric stimulation—"dead labyrinth."

Review Test

1. A 40-year-old man complains of headaches and inability to control his walking (gait). His physician refers him to a neurologist for further evaluation. The man remembers that 10 years ago he noticed a noise in his right ear that sounded like frying bacon. Neurologic examination reveals the following: loss of hearing on the right side; tinnitus, vertigo, and nausea; wide-based ataxic gait with lurching to the right side; dysphagia; facial weakness on the right side; sensory loss over the face on the right side; loss of the corneal reflex on the right side; absent gag reflex; and diplopia. The lesion site responsible for these neurologic deficits is the:

- (A) CP angle.
- (B) lateral medulla.
- (C) lateral pons.
- (D) medial medulla.
- (E) medial pons.

2. Tilting the head forward would maximally stimulate the hair cells in the:

- (A) crista ampullaris of the anterior semicircular duct.
- (B) crista ampullaris of the lateral semicircular duct.
- (C) crista ampullaris of the posterior semicircular duct.
- (D) macula of the saccule.
- (E) macula of the utricle.

3. A comatose patient's head is elevated 30° from the horizontal. Cold water is injected

into the left external auditory meatus. If the brainstem is intact, which one of the following ocular reflexes do you expect to see?

- (A) Deviation of the eyes to the left
- (B) Deviation of the eyes to the right
- (C) Horizontal nystagmus to the left
- (D) Horizontal nystagmus to the right
- (E) Vertical upper nystagmus

Questions 4 to 8

The response options for items 4 to 8 are the same. Select one answer for each item in the set.

- (A) Acoustic schwannoma
- (B) Benign positional vertigo
- (C) Ménière disease
- (D) MLF syndrome
- (E) Multiple sclerosis

Match each characteristic with the condition it best describes.

4. Causes symptoms of CN V, CN VII, and CN VIII

5. Is an inner ear disease associated with increased endolymphatic fluid pressure

6. Is the most common cause of INO

7. Results in cuprolithiasis of the posterior semicircular duct

8. Consists of lateral gaze palsy and monocular nystagmus

Answers and Explanations

1-A. The acoustic neuroma (acoustic schwannoma), which represents 8% of primary intracranial neoplasms, is found in the CP angle. Each of the examination findings is evidence of a particular condition. The loss of hearing on the right side and the tinnitus indicate damage to cochlear nerve. The vertigo and nausea indicate damage to the vestibular nerve. The wide-based ataxic gait with lurching to the right indicates damage to the cerebellum. The dysphagia indicates damage to the glossopharyngeal and vagal nerves. The facial weakness on the right side indicates damage to the facial nerve. The sensory loss over the face on the right side indicates damage to the spinal trigeminal tract of CN V. The loss of the corneal reflex on the right side indicates damage to trigeminal (afferent limb) and to facial (efferent limb) nerves. The absent gag reflex indicates damage to glossopharyngeal (afferent limb) and vagal (efferent limb) nerves. The diplopia indicates damage to the abducent nerve. A large tumor can damage the pyramidal tract and the abducent nerve. The differential diagnosis should include other tumors of the CP angle (**S**chwannoma, **A**rachnoid, **M**eningioma, **E**pidermoid; remember SAME).

2-E. Tilting the head forward would maximally stimulate the hair cells in the utricle. Tilting the head to the side would maximally stimulate the hair cells in the saccule. The utricle and saccule both respond to linear acceleration and the force of gravity.

3-A. Nystagmus is not seen in comatose patients. In this case, the patient's eyes will deviate toward the side of cold-water injection.

4-A. The acoustic schwannoma, which is found in the CP angle of the posterior cranial fossa, impinges on CN V, CN VII, and CN VIII. CN V lesions result in loss of pain and temperature sensation on the ipsilateral face and loss of the corneal reflex. CN VII lesions result in a lower motor neuron paralysis of the ipsilateral muscles of facial expression and loss of the corneal reflex. CN VIII lesions result in loss of hearing, nystagmus, tinnitus, nausea, vertigo, and vomiting. (See Chapter 13, Cranial Nerves.)

5-C. Ménière disease (labyrinthine vertigo) is the most common cause of true vertigo. It is characterized by abrupt attacks of vertigo, nystagmus, nausea, vomiting, tinnitus, fullness in the ear, and hearing loss. This disease is caused by a distension of the endolymphatic system (labyrinthine hydrops). Drugs used to treat motion sickness may be helpful. Destruction (decompression) of the vestibule and an endolymphatic-subarachnoid shunt have proved useful.

6-E. The most common cause of INO is multiple sclerosis. Other causes of INO are vascular insults and intraparenchymal tumors (pontine gliomas). Multiple sclerosis, a demyelinating disease of the central nervous system is characterized by the following deficits: ocular signs (retrobulbar neuritis and INO); brainstem and cerebellar signs (deafness, vertigo, ataxia, and intention tremor); pyramidal tract signs (spastic paresis with Babinski sign); sensory disturbances (paresthesias or dysesthesias); and bladder and rectal incontinence.

7-B. Benign positional vertigo, which is more common than Ménière disease, is characterized by paroxysmal vertigo, oscillopsia, and nystagmus. It occurs as the result of assumption of certain positions of the head (i.e., lying down or rolling over in bed). Such vertigo results from cuprolithiasis of the posterior semicircular duct—a dislocation of the otoliths that move freely with movement of the head.

The following procedure is diagnostic. The patient is moved from a sitting to a recumbent position (on an examination table), and the head is tilted 30° down over the edge of the table, then 30° to one side, and then 30° to the other side. The patient has a paroxysm of vertigo (Hallpike maneuver).

8-D. MLF syndrome (INO) consists of medial rectus palsy on attempted lateral gaze. Nystagmus in the abducting eye is evident. Convergence is intact. This syndrome is seen frequently in multiple sclerosis.

Objectives

- Describe the structure of the retina and include a description of the optic disk, macula lutea, and the fovea centralis.
- List the layers of the retina and the cells found in each.
- Trace the central visual pathway and describe the result of lesions along its course.
- Describe pupillary reflexes—direct versus consensual, dilation, convergence, and accommodation.
- List cortical centers for control of the visual system.
- Describe the retinotopic organization of the visual system pathway.
- Discuss various clinical correlates related to the visual system.

I. INTRODUCTION

- served by the **optic nerve—CN II**—a special somatic afferent (**SSA**) nerve.

II. THE RETINA

- the innermost layer of the eye.
- derived from the optic vesicle of the diencephalon.
- contains efferent fibers that give rise to the optic nerve, which is actually a fiber tract of the diencephalon.
- sensitive to wavelengths from 400 to 700 nm.

A. Structures of the ocular fundus—retinal part opposite the pupil**1. Optic disk (optic papilla)**

- located 3.5 mm nasal to the fovea centralis.
- contains unmyelinated axons from the ganglion cell layer of the retina.
- the blind spot (contains no rods or cones).
- contains a central cup, a peripheral disk margin, and retinal vessels.

2. Macula lutea

- a yellow-pigmented area that surrounds the fovea centralis.

3. Fovea centralis

- located within the macula lutea.
- contains only cones and is the site of highest visual acuity.
- avascular and receives nutrients by diffusion via the choriocapillaris.
- subserves color or day (photopic) vision.

4. Retinal blood supply

- supplied by the **choriocapillaris** of the choroid layer and the **central retinal artery**, a branch of the ophthalmic artery.
- occlusion of the central retinal artery results in blindness, as it is an end artery.

B. Cells of the retina (Figure 16.1)

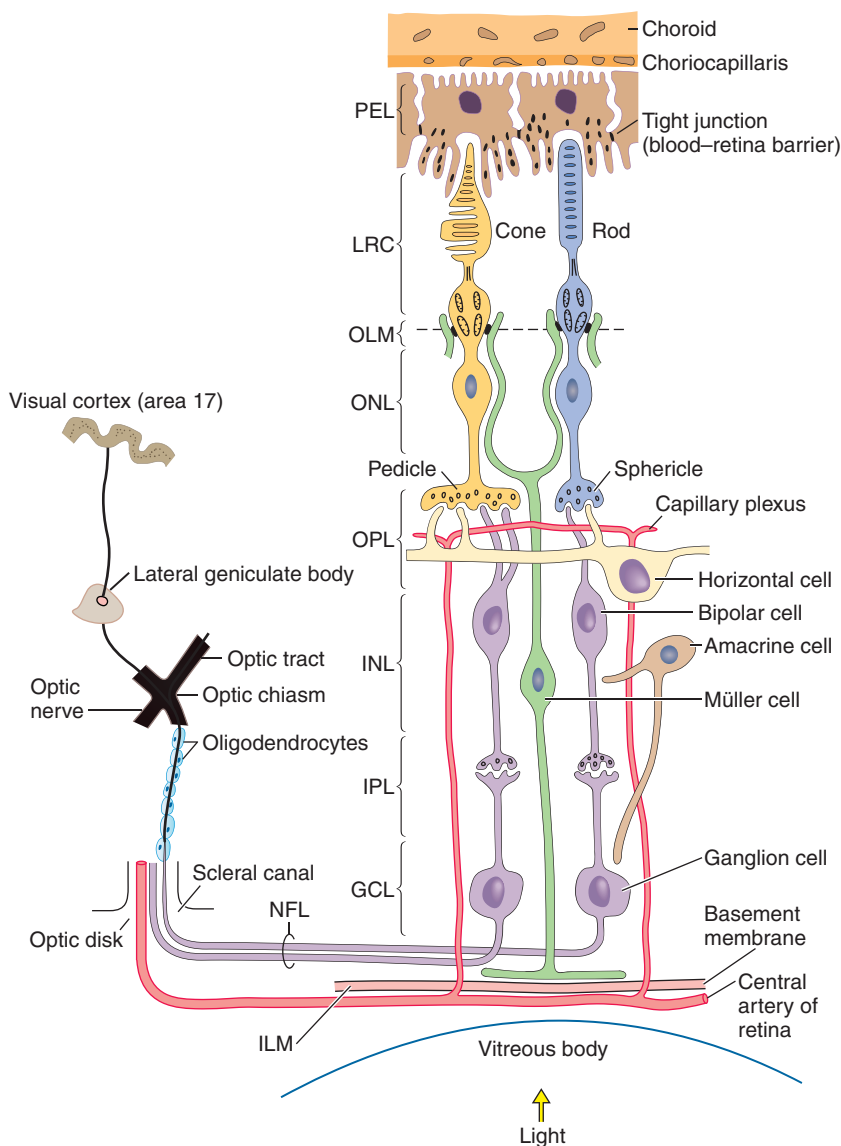


FIGURE 16.1. Histology of the retina. The retina has 10 layers: (1) pigment epithelium layer (PEL), (2) layer of rods and cones (LRC), (3) outer limiting membrane (OLM), (4) outer nuclear layer (ONL), (5) outer plexiform layer (OPL), (6) inner nuclear layer (INL), (7) inner plexiform layer (IPL), (8) ganglion cell layer (GCL), (9) nerve fiber layer (NFL), and (10) inner limiting membrane (ILM). The tight junctions binding the pigment epithelial cells make up the blood–retina barrier. The central artery of the retina perfuses the retina to the outer plexiform layer, and the choriocapillaris supplies the outer five layers of the retina. The Müller cells are radial glial cells that have a support function. (Adapted with permission from Dudek RW. *High-Yield Histology*. Baltimore, MD: Williams & Wilkins; 1997:64.)

- constitute a chain of three neurons that project visual impulses via the optic nerve and the lateral geniculate body (LGB) to the visual cortex.

1. Rods and cones

- first-order receptor cells that respond directly to light stimulation.
- generate graded potentials.
- utilize glutamate as a neurotransmitter.
 - a. Rods (100 million)**
 - contain **rhodopsin** (visual purple).
 - sensitive to low-intensity light.
 - subserve night (scotopic) vision.
 - b. Cones (7 million)**
 - contain the photopigment **iodopsin**.
 - operate only at high illumination levels.
 - concentrated in the fovea centralis.
 - responsible for day (photopic) vision, color vision, and high visual acuity.

2. Bipolar neurons

- second-order neurons that relay stimuli from the rods and cones to the ganglion cells.
- generate only graded potentials.
- utilize glutamate as a neurotransmitter.

3. Ganglion cells

- third-order neurons that form the optic nerve (CN II).
- retinal cells with voltage-gated sodium channels that generate action potentials.
- project directly to the hypothalamus, superior colliculus, pretectal nucleus, and LGB.
- utilize glutamate as a neurotransmitter.

4. Interneurons

- **Horizontal cells**
 - a.** interconnect photoreceptors and bipolar cells.
 - b.** inhibit neighboring photoreceptors (lateral inhibition).
 - c.** generate graded potentials.
 - d.** utilize gamma-aminobutyric acid (GABA) as a neurotransmitter.
 - e.** play a role in the differentiation of colors.
- **Amacrine cells**
 - a.** small cells that have no axons and few dendrites.
 - b.** receive input from bipolar cells and project inhibitory signals to ganglion cells.
 - c.** mediate lateral interactions at the bipolar-ganglion cell synapse.
 - d.** utilize GABA, glycine, dopamine, and acetylcholine (ACh) as neurotransmitters.

5. Müller cells

- radial glial cells that have a support function similar to that of astrocytes.
- extend from the inner limiting layer to the outer limiting layer.

C. Meridional divisions of the retina

1. The visual field illustrated in Figure 16.2 is the environment seen by one eye (**monocular field**) or by both eyes (**binocular field**).
2. The vertical meridian divides the retina into **nasal** and **temporal hemiretinae**; the horizontal meridian divides the retina into upper and lower hemiretinae.
 - **Temporal hemiretina**
 - a.** receives image input from the nasal visual field.
 - b.** has ganglion cells that project to the ipsilateral LGB layers 2, 3, and 5.
 - **Nasal hemiretina**
 - a.** receives image input from the temporal visual field.
 - b.** has ganglion cells that project to the contralateral LGB layers 1, 4, and 6.

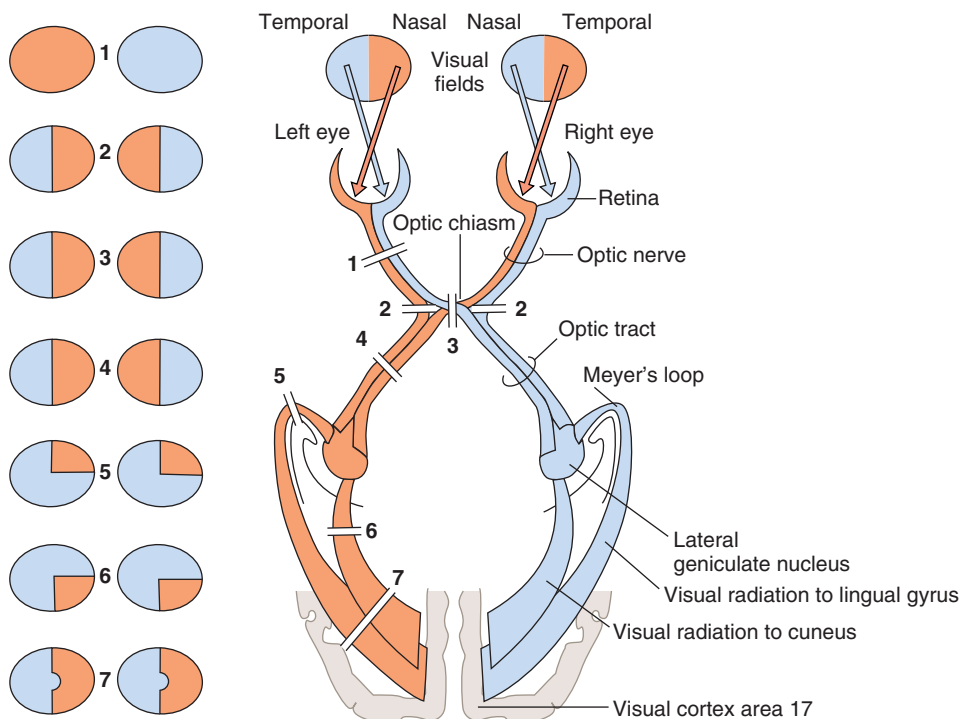


FIGURE 16.2. Visual pathway from the retina to the visual cortex showing visual field defects. (1) Ipsilateral blindness. (2) Binasal hemianopia. (3) Bitemporal hemianopia. (4) Right hemianopia. (5) Right upper quadrantanopia. (6) Right lower quadrantanopia. (7) Right hemianopia with macular sparing. (Modified from Fix JD. *High-Yield Neuroanatomy*. 3rd ed. Philadelphia, PA: Lippincott Williams & Wilkins; 2005:119.)

- **Upper retinal quadrants**

- a. receive image input from the lower visual fields.
- b. have ganglion cells that project via the LGB to the upper banks of the calcarine fissure.

- **Lower retinal quadrants**

- a. receive image input from the upper visual fields.
- b. have ganglion cells that project via the LGB to the lower banks of the calcarine fissure.

D. Concentric divisions of the retina and retinotopy

1. Macular area

- a small area surrounding the fovea centralis that serves central vision (high visual acuity).
- contains cones.
- predominantly projects to the posterior part of the visual cortex.

2. Paramacular area

- a large area surrounding the macular area that contains predominantly rods.
- projects to the visual cortex anterior to the macular representation.

3. Monocular area

- represents the peripheral monocular field.
- projects to the visual cortex anterior to the paramacular representation.
- lesions result in a contralateral crescentic defect.

III. VISUAL PATHWAY (SEE FIGURES 1.2 AND 16.2)

- transmits visual impulses from the retina to the LGB and from the LGB to the primary visual cortex (area 17) of the occipital lobe.
- consists of the following structures:

A. Ganglion cells

- constitute the ganglion cell layer of the retina, with axons that form the optic nerve, CN II.
- project from the nasal hemiretina to the contralateral LGB.
- project from the temporal hemiretina to the ipsilateral LGB.

B. Optic nerve (CN II)

- a myelinated tract of the central nervous system (CNS; diencephalon) and is **not a true nerve**.
- invested by the pia–arachnoid and dura mater and therefore surrounded by the subarachnoid space.
- receives its blood supply from the central retinal artery, pial arteries, posterior ciliary arteries, and the cerebral arterial circle (of Willis).
- compression results in **optic atrophy**.
- Transection at the chiasma results in **ipsilateral blindness** and a contralateral upper temporal scotoma (**junction scotoma**); inferior nasal fibers loop into the contralateral optic nerve (see Figure 16.1).

C. Optic chiasm

- part of the diencephalon.
- lies dorsal to the hypophysis and diaphragma sellae.
- contains decussating fibers from the two nasal hemiretinae.
- contains noncrossing fibers from the two temporal hemiretinae.
- receives its blood supply from the anterior cerebral and internal carotid arteries.
- midsagittal transection or pressure results in **bitemporal hemianopia** (pituitary tumor).
- bilateral lateral compression results in **binasal hemianopia** (calcified internal carotid arteries).

D. Optic tract

- contains fibers from the ipsilateral temporal hemiretina and the contralateral nasal hemiretina.
- projects to the LGB and via the brachium of the superior colliculus to the pretectal nuclei and superior colliculus.
- receives its blood supply from the posterior communicating artery and the anterior choroidal artery.
- Transection results in **contralateral homonymous hemianopia**.

E. Lateral geniculate body

- a thalamic relay nucleus subserving vision.
- receives fibers from the ipsilateral temporal hemiretina, which terminate in layers 2, 3, and 5.
- receives fibers from the contralateral nasal hemiretina, which terminate in layers 1, 4, and 6.
- projects, via the geniculocalcarine tract, the visual radiation to the primary visual cortex (area 17).
- irrigated by branches of the posterior cerebral artery and the anterior choroidal artery.
- destruction results in a **contralateral homonymous hemianopia**.

F. Geniculocalcarine tract (visual radiation; retrolenticular part of internal capsule) (Figure 16.3)

- extends from the LGB to the banks of the calcarine sulcus, the visual cortex (area 17).
- irrigated by branches of the middle cerebral artery, anterior choroidal artery, and calcarine artery (a branch of the posterior cerebral artery).
- Transection results in **contralateral homonymous hemianopia**.
- has two divisions (see Figure 16.3):

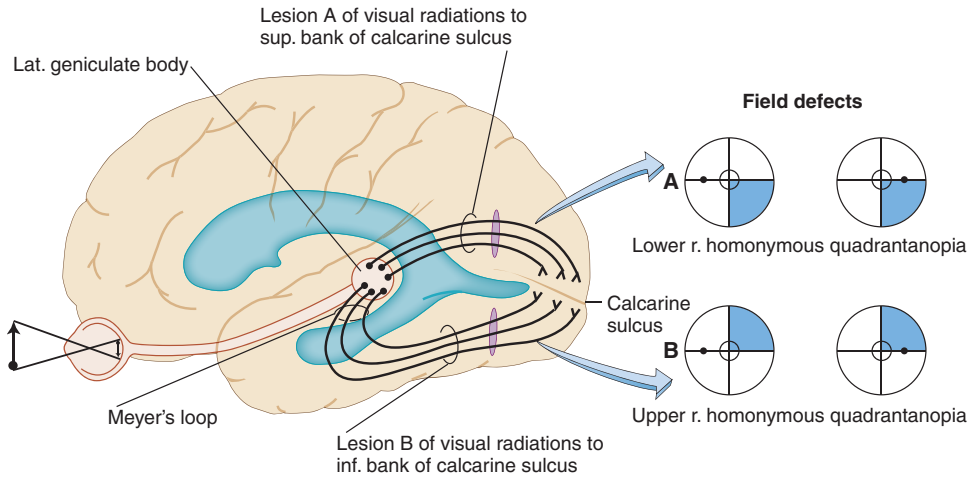


FIGURE 16.3. Relationships of the left upper and left lower divisions of the geniculocalcarine tract to the lateral ventricle and the calcarine sulcus. Transection of the upper division (**A**) results in right lower homonymous quadrantanopia; transection of the lower division (**B**) results in right upper homonymous quadrantanopia.

1. Upper division

- projects to the upper bank of the calcarine sulcus, the **cuneus**.
- contains input from the superior retinal quadrants, representing inferior visual field quadrants.
- Transection results in **contralateral lower homonymous quadrantanopia**.

2. Lower division

- loops from the LGB anteriorly (Meyer's loop), then posteriorly to terminate in the lower bank of the calcarine sulcus, the **lingual gyrus**.
- contains input from the inferior retinal quadrants, representing superior visual field quadrants.
- Transection of Meyer's loop results in a **contralateral upper homonymous quadrantanopia**.

G. Visual (striate) cortex (area 17)

- located on the banks of the calcarine sulcus.
- receives retinal input via the ipsilateral LGB.
- receives its blood supply from the calcarine artery, a branch of the posterior cerebral artery; anastomosis with the middle cerebral artery may be substantial (**macular sparing**).
- lesions result in a **contralateral homonymous hemianopia** with macular sparing. Bilateral destruction of both cuneus results in a **lower altitudinal hemianopia**, and bilateral destruction of the lingual gyri results in an **upper altitudinal hemianopia**.
- **Retinotopic organization** of the visual cortex includes
 1. **Posterior third of the visual cortex**
 - receives macular input (central vision).
 2. **Intermediate area of the visual cortex**
 - receives paramacular input (peripheral input).
 3. **Anterior area of the visual cortex**
 - receives monocular input.

IV. PUPILLARY LIGHT REFLEXES AND PATHWAY (FIGURE 16.4)

A. Pupillary light reflexes

- result when light shined into one eye causes both pupils to constrict.
 1. **Direct pupillary light reflex**
 - the response in the stimulated eye.

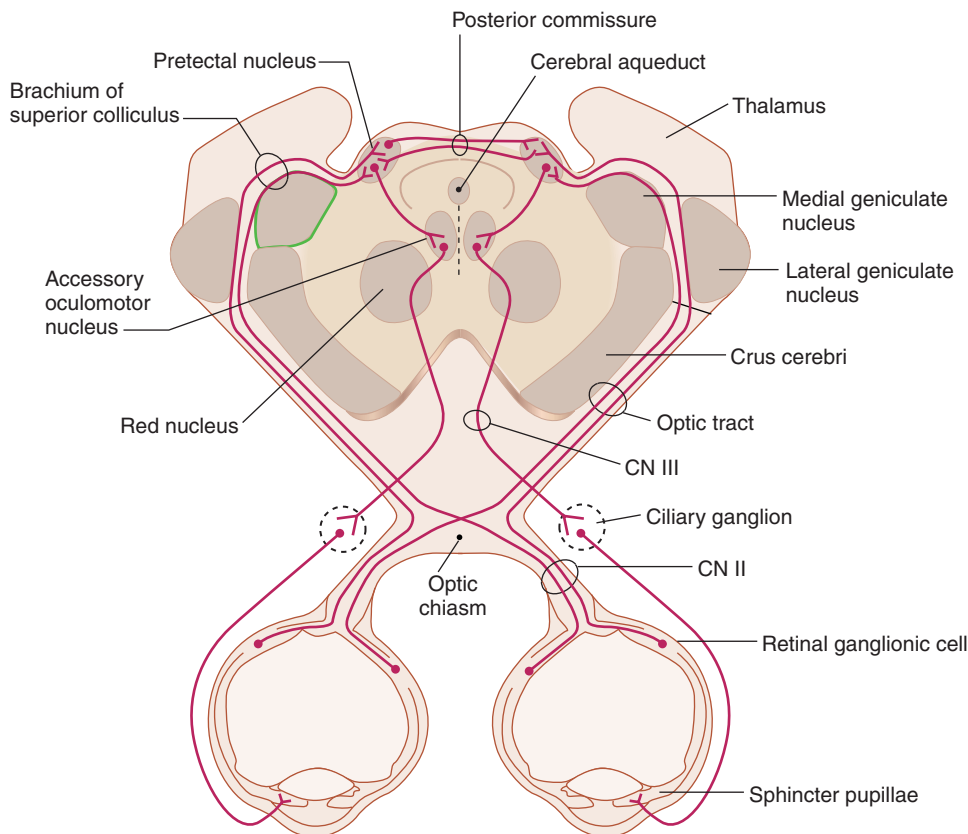


FIGURE 16.4. Diagram of the pupillary light pathway. Light shining into one eye causes both pupils to constrict. The response in the stimulated eye is called the direct pupillary light reflex; the response in the opposite eye is called the consensual pupillary light reflex. (Modified from Fix JD. *High-Yield Neuroanatomy*. 3rd ed. Philadelphia, PA: Lippincott Williams & Wilkins; 2005:123.)

2. Consensual pupillary light reflex

- the response in the unstimulated eye.

B. Pupillary light reflex pathway

- comprises an afferent limb, **CN II**, and an efferent limb, **CN III**.
- consists of the following structures:
 1. **Ganglion cells**
 - project bilaterally to the pretectal nuclei.
 2. **Pretectal nucleus**
 - projects crossed (in the posterior commissure) and uncrossed fibers to the rostral accessory nucleus.
 3. **Accessory oculomotor nucleus**
 - oculomotor
 - gives rise to preganglionic parasympathetic fibers, which exit the midbrain with the oculomotor nerve and synapse with postganglionic parasympathetic neurons of the ciliary ganglion.
 4. **Ciliary ganglion**
 - gives rise to postganglionic parasympathetic fibers, which innervate the sphincter muscle of the iris.

V. PUPILLARY DILATION PATHWAY

- mediated by the sympathetic division of the autonomic nervous system (ANS).
- interruption at any level results in **Horner syndrome**.
- consists of the following structures:

A. Hypothalamus

- has neurons that project directly to the ciliospinal center (T1–T2) of the intermediolateral cell column (Figure 16.5).

B. Ciliospinal center

- projects preganglionic sympathetic fibers via the sympathetic trunk to the superior cervical ganglion.

C. Superior cervical ganglion

- projects postganglionic sympathetic fibers via the perivascular plexus of the carotid system to the dilator of the iris and to the palpebral muscles of Müller. Postganglionic sympathetic fibers pass through the cavernous sinus and enter the orbit via the superior orbital fissure.

VI. THE CONVERGENCE–ACCOMMODATION REACTION (SEE FIGURE 16.5)

- essential for visual fixation and acuity at close range.
- initiated by conscious visual fixation on a near object or by a blurred retinal image.

A. Reflex changes

- with accommodative effort, three reflex changes are evoked:
 1. **Convergence**
 - occurs as the eyes focus on a near point.
 - mediated by medial recti innervation via the oculomotor nerve.
 2. **Accommodation**
 - adjustment of the eyes for various distances.
 - occurs as contraction of the ciliaris results in a thickening of the lens and an increase in refractive power.
 - mediated by the accessory oculomotor nucleus via CN III.
 3. **Pupillary constriction**
 - results in an increase in depth of field and depth of focus.
 - mediated by the accessory oculomotor nucleus via CN III.

B. The convergence–accommodation pathway (see Figure 16.5)

1. **Visual cortex (area 17)**
 - projects to the visual association cortex (area 19).
2. **Visual association cortex (area 19)**
 - projects via the corticotectal tract to the pretectal area of the midbrain.
3. **Pretectal area**
 - projects to the nucleus of Perlia.
4. **Nucleus of Perlia**
 - projects to the rostral and caudal accessory oculomotor nuclei and the medial rectus subnuclei of CN III.
 - **known as the convergence nucleus.**

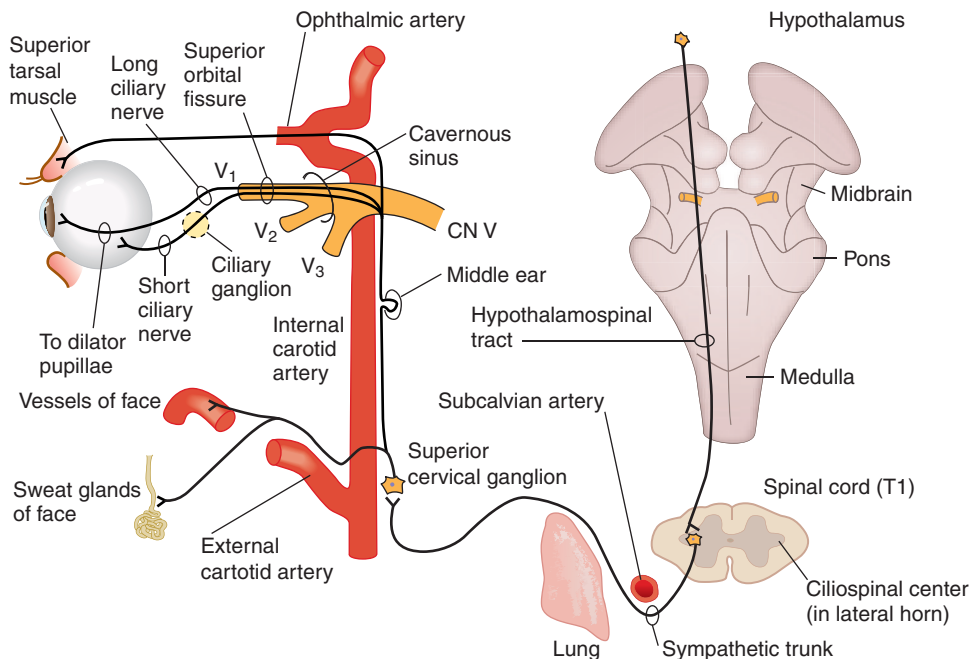


FIGURE 16.5. Pupillary dilation pathway (oculosympathetic pathway). Hypothalamic fibers project to the ipsilateral and ciliospinal center of the intermediolateral cell column at T1. The ciliospinal center projects preganglionic sympathetic fibers to the superior cervical ganglion. The superior cervical ganglion projects perivascular postganglionic sympathetic fibers via the tympanic cavity, cavernous sinus, and superior orbital fissure to the dilator pupillae. Interruption of this pathway at any level results in Horner syndrome. (Modified from Fix JD. *High-Yield Neuroanatomy*. 3rd ed. Philadelphia, PA: Lippincott Williams & Wilkins; 2005:67.)

VII. CENTERS FOR OCULAR MOTILITY

A. Frontal eye field

- located in the caudal part of the middle frontal gyrus (area 8).
- a cortical center for voluntary eye movements, which are fast, saccadic, searching movements.
- stimulation (irritative lesion) results in **contralateral conjugate deviation of the eyes**.
- destruction (destructive lesion) results in **transient ipsilateral conjugate deviation of the eyes**.

B. Occipital eye fields (areas 18 and 19)

- the cortical centers for involuntary pursuit or tracking movements.
- stimulation results in **contralateral conjugate deviation of the eyes**.
- lesions result in difficulty following a slow-moving object.

C. Subcortical center for vertical conjugate gaze

- located at the level of the posterior commissure.
- includes the **rostral interstitial nucleus of the medial longitudinal fasciculus (MLF)**, which projects to the oculomotor and trochlear nuclei.
- involved in **Parinaud syndrome** (see Chapter 12 IV A).

D. Subcortical center for lateral conjugate gaze (Figure 16.6)

- located in the paramedian pontine reticular formation (PPRF).
- receives input from the contralateral frontal eye field.
- projects via the contralateral MLF to the medial rectus subnucleus of the oculomotor complex.

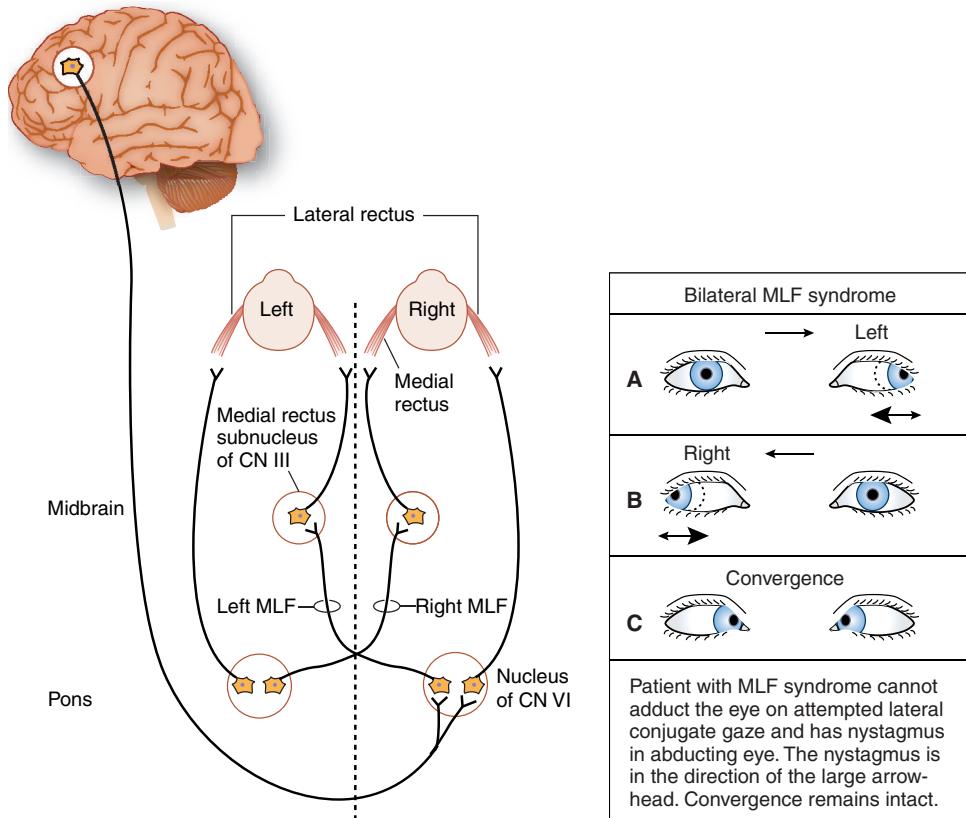


FIGURE 16.6. Connections of the pontine center for lateral conjugate gaze. Lesions of the medial longitudinal fasciculus (MLF) between the abducent and oculomotor nuclei result in a medial rectus palsy on attempted lateral conjugate gaze and horizontal nystagmus in the abducting eye. Convergence remains intact (*inset*). A unilateral MLF lesion would affect the ipsilateral medial rectus only. (Modified from Fix JD. *High-Yield Neuroanatomy*. 3rd ed. Philadelphia, PA: Lippincott Williams & Wilkins; 2005:125.)

- projects via abducent fibers to the ipsilateral lateral rectus muscle.
- damage to the MLF between the abducent and oculomotor nuclei results in **medial rectus palsy** (see VIII B).

VIII. CLINICAL CORRELATIONS

A. Anisocoria (unequal pupils)

- a condition where the two pupils are not equal.
- present in 10% of the population.
- seen in **Horner syndrome** and **third nerve palsies**.

B. MLF syndrome (internuclear ophthalmoplegia [INO]) (Figure 16.7; see Figure 16.6)

- a condition in which there is damage (demyelination) to the MLF between the abducent and oculomotor nuclei.
- results in **medial rectus palsy** on attempted lateral conjugate gaze and **monocular horizontal nystagmus** in the abducting eye (convergence is normal).

C. One-and-a-half syndrome

- consists of a bilateral MLF lesion and a unilateral lesion of the abducent nucleus.
- on attempted lateral conjugate gaze, the only muscle that functions is the intact lateral rectus.

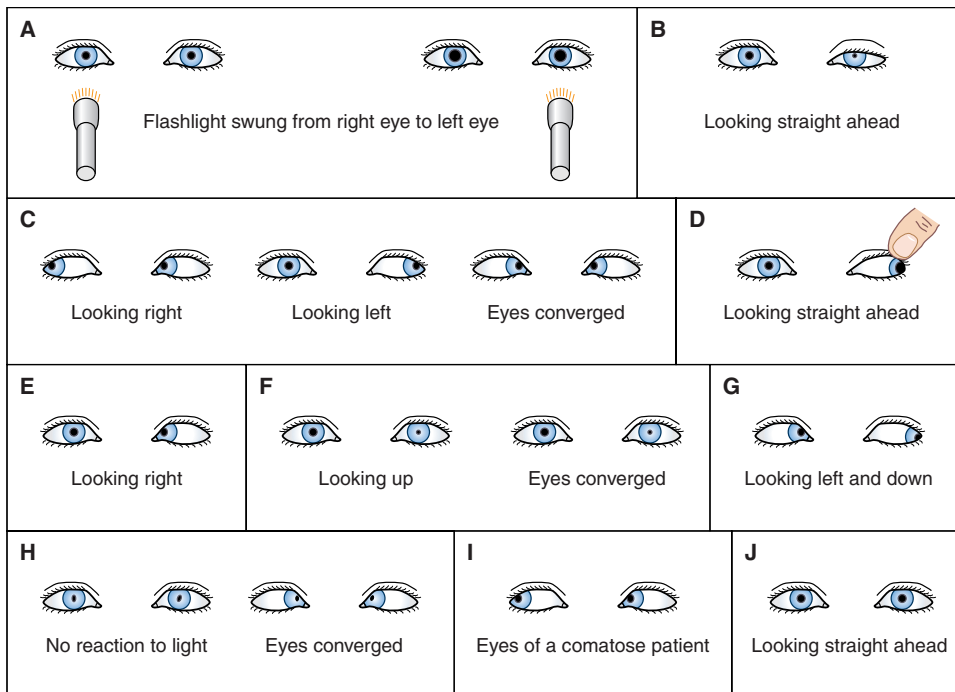


FIGURE 16.7. Ocular motor palsies and pupillary syndromes. (A) Relative afferent (Marcus Gunn) pupil, left eye. (B) Horner syndrome, left eye. (C) Internuclear ophthalmoplegia, right eye. (D) Third nerve palsy, left eye. (E) Sixth nerve palsy, right eye. (F) Paralysis of upward gaze and convergence (Parinaud syndrome). (G) Fourth nerve palsy, right eye. (H) Argyll Robertson pupil. (I) Destructive lesion of the right frontal eye field. (J) Third nerve palsy with ptosis, right eye. (Modified from Fix JD. *High-Yield Neuroanatomy*. 3rd ed. Philadelphia, PA: Lippincott Williams & Wilkins; 2005:124.)

D. Argyll Robertson pupil (pupillary light–near dissociation) (see Figure 16.7)

- the absence of a miotic reaction to light, both direct and consensual, with preservation of miotic reaction to near stimulus (accommodation–convergence).
- may be present in tertiary **syphilis**, **diabetes mellitus**, and **lupus erythematosus**.

E. Afferent pupil (Marcus Gunn pupil) (see Figure 16.7)

- results from a **lesion in the afferent limb of the pupillary light reflex** (e.g., **retrobulbar neuritis** of the optic nerve seen in **multiple sclerosis**).
- can be diagnosed by the **swinging flashlight test**.
 1. Light shined into the normal eye results in brisk **pupillary constriction** in both the normal eye and in the affected eye (consensual reaction).
 2. Light is then immediately shined into the affected eye with the afferent lesion, which results in **dilation of the afferent pupil**. The consensual stimulation of the constrictor pupillae muscle is much greater than the direct stimulation through a defective optic nerve.

F. Transtentorial herniation (uncal herniation) (see Figure 16.7)

- occurs as the result of **increased supratentorial pressure**, commonly owing to a brain tumor or a hematoma (subdural or epidural).
 1. The pressure cone forces the parahippocampal uncus through the tentorial incisura.
 2. The impacted parahippocampal uncus forces the contralateral crus cerebri against the tentorial edge and brings pressure to bear on the ipsilateral CN III and the posterior cerebral artery, resulting in the following neurologic deficits:
 - **ipsilateral hemiparesis** owing to pressure on the corticospinal tract in the crus cerebri

- **a fixed and dilated pupil, ptosis, and a down-and-out eye** resulting from pressure on the ipsilateral oculomotor nerve
- **contralateral homonymous hemianopia** owing to compression of the ipsilateral posterior cerebral artery, which irrigates the visual cortex

G. Papilledema (choked disk)

- a noninflammatory congestion of the optic disk caused by increased intracranial pressure.
- most commonly caused by **brain tumors, subdural hematoma, and hydrocephalus**.
- usually does not alter visual acuity or result in visual field defects.
- usually asymmetric and is greater on the side of the supratentorial pathology.

H. Adie pupil (Holmes–Adie pupil)

- a large tonic pupil that reacts slowly to light but does not react to near stimulus (light–near dissociation).
- associated with damage to the postganglionic innervation of sphincter pupillae.

I. Ptosis (see Figure 16.7)

- a drooping eyelid seen in many syndromes.
 1. **Oculomotor ptosis**
 - owing to paralysis of the levator palpebrae (e.g., transtentorial herniation).
 2. **Oculosympathetic ptosis**
 - owing to paralysis of the superior tarsal (Müller) muscle as seen in Horner syndrome. This is a very slight ptosis, or pseudoptosis (e.g., Pancoast tumor).
 3. **Myasthenic ptosis**
 - seen in myasthenia gravis.
 - usually increases with increasing fatigue.
 - immediately improves after an injection of a cholinesterase inhibitor.
 - is usually bilateral and asymmetric.

Review Test

1. Interruption of the MLF at pontine levels:

- (A) abolishes accommodation.
- (B) abolishes convergence.
- (C) results in miosis and ptosis.
- (D) results in paralysis of lateral gaze on command.
- (E) results in paralysis of upward gaze on command.

2. A 75-year-old coal miner complains of progressive loss of vision. Visual field examination shows visual loss in the upper right quadrant in both visual fields. The lesion would most likely be in the:

- (A) left cuneus.
- (B) left temporal lobe.
- (C) right angular gyrus.
- (D) right lingual gyrus.
- (E) right occipital pole.

Questions 3 to 10

The response options for items 3 to 10 are the same. Select one answer for each item in the set.

- (A) Binasal hemianopia
- (B) Bitemporal hemianopia
- (C) Left homonymous hemianopia
- (D) Left upper homonymous quadrantanopia
- (E) Right lower homonymous quadrantanopia

Match each defect below with the condition it causes.

- 3. Transection of the right optic tract
- 4. Transection of the right Meyer's loop
- 5. Midsagittal section of the optic chiasm
- 6. Tumor of the right LGB

7. Pituitary tumor

8. Tumor of the left cuneus

9. Trauma to the right lingual gyrus

10. Bilateral lateral constriction of the optic chiasm

Questions 11 to 17

The response options for items 11 to 17 are the same. Select one answer for each item in the set.

- (A) Anisocoria
- (B) Argyll Robertson pupil
- (C) Fixed, dilated pupil
- (D) Horner syndrome
- (E) Marcus Gunn pupil

Match each description below with the syndrome or defect most closely associated with it.

11. Results from interruption of the cervical sympathetic trunk

12. Is present in 10% of the population

13. Is characterized by uncal herniation

14. Is characterized by the absence of the miotic reaction to light but with the presence of the miotic reaction to near stimulus

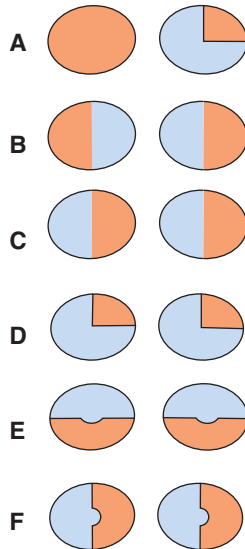
15. The pupil dilates when light is shined from the normal pupil into the afferent pupil

16. Is frequently seen in multiple sclerosis

17. Is associated with syphilis

Questions 18 to 23

The response options for items 18 to 23 are the same. Select one answer for each item in the set.

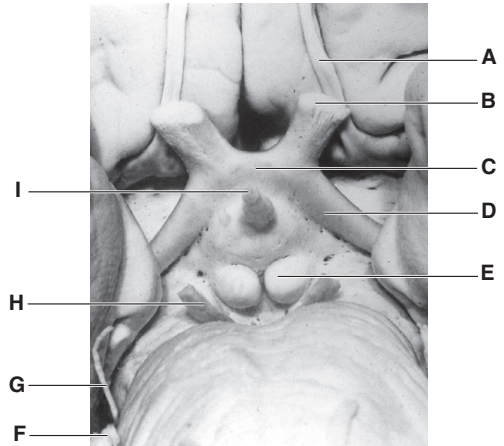


Match the description of the lesion sites in items 18 to 23 with the appropriate visual field defect shown in the figure.

- 18.** Occlusion of the left posterior cerebral artery
- 19.** Transection of the left optic nerve at the chiasm
- 20.** Craniopharyngioma
- 21.** Left temporal lobectomy
- 22.** Bilateral trauma to the cuneate gyri
- 23.** Transection of the left optic tract

Questions 24 to 32

The response options for items 24 to 32 are the same. Select one answer for each item in the set.



Match the description of the lesion sites in items 24 to 32 with the appropriate deficit or pathologic finding shown in the photograph of the base of the brain.

- 24.** Transection results in polyuria and polydipsia
- 25.** Transection results in ipsilateral ptosis
- 26.** Transection results in homolateral extorsion of the globe
- 27.** Destruction results in an absent corneal reflex on the side of testing
- 28.** Pathology is seen in Wernicke encephalopathy
- 29.** Transection results in a contralateral hemianopia
- 30.** Midsagittal section results in a bitemporal hemianopia
- 31.** Transection results in total blindness in the left eye
- 32.** Compression is seen in Foster Kennedy syndrome

Answers and Explanations

- 1–D.** Interruption of the pontine MLF results in a medial rectus palsy on attempted conjugate lateral gaze. Convergence remains intact. This syndrome, called INO or MLF syndrome, is commonly seen in multiple sclerosis.
- 2–B.** Ablation of the anterior temporal lobe destroys the optic radiations that project to the lower bank of the calcarine sulcus. The field deficit is an upper right homonymous quadrantanopia, which is also called Meyer's loop quadrantanopia.
- 3–C.** Transection of the right optic tract results in a left homonymous hemianopia.
- 4–D.** Transection of the Meyer's loop on the right side results in a left upper quadrantanopia ("pie in the sky"). The Meyer's loop is the inferior geniculocalcarine pathway, which conveys information from the inferior retinal quadrants to the inferior bank of the calcarine sulcus, the lingual gyrus.
- 5–B.** A midsagittal section of the optic chiasm interrupts the decussating fibers from the nasal hemiretinae and results in a bitemporal hemianopia.
- 6–C.** A lesion of the right LGB produces a left homonymous hemianopia. A lesion of the optic tract, the LGB, or the visual pathway all produce the same field deficit, a contralateral homonymous hemianopia.
- 7–B.** A pituitary tumor most commonly produces a bitemporal hemianopia. The pituitary (hypophysis) gland lies ventral to the optic chiasm.
- 8–E.** Destruction of the left cuneus produces a right lower homonymous quadrantanopia. Upper retinal quadrants project to the upper banks of the calcarine sulcus.
- 9–D.** Destruction of the right lingual gyrus produces a left upper homonymous quadrantanopia. Lower retinal quadrants project to the lower banks of the calcarine sulcus.
- 10–A.** Bilateral constriction of the optic chiasm damages the nondecussating fibers from the temporal hemiretinae and produces a binasal hemianopia.
- 11–D.** Horner syndrome results from interruption of the cervical sympathetic trunk.
- 12–A.** Anisocoria, unequal pupils, is present in 10% of the population.
- 13–C.** In transtentorial herniation, the hippocampal uncus is forced by increased pressure (brain tumor) through the tentorial incisure. Pressure on the oculomotor nerve (CN III) results in a fixed, dilated pupil and an eye that looks down and out. Pressure on the basis pedunculi, affecting the corticospinal tracts, results in a contralateral hemiparesis.
- 14–B.** The Argyll Robertson pupil is characterized by absence of the miotic reaction to light but with presence of the miotic reaction to near stimulus.
- 15–E.** The Marcus Gunn pupil is an afferent pupil, with a lesion in the afferent limb of the pupillary light pathway.
- 16–E.** The Marcus Gunn pupil is commonly seen in multiple sclerosis.
- 17–B.** The Argyll Robertson pupil is associated with neurosyphilis.
- 18–F.** Occlusion of the left posterior cerebral artery results in a right homonymous hemianopia with macular sparing; macular sparing results from a dual blood supply to the visual cortex.
- 19–A.** Transection of the left optic nerve at the chiasm results in total blindness on the left side and a scotoma in the right upper temporal quadrant. Fibers from the lower nasal quadrant loop into

the contralateral optic nerve before decussating in the optic chiasma. The field defect is called a junction scotoma.

20–B. Craniopharyngiomas and pituitary tumors put pressure on the decussating fibers of the optic chiasma, causing a bitemporal hemianopia.

21–D. A left temporal lobotomy transects Meyer's loop, which projects to the inferior bank of the calcarine fissure, resulting in a right upper quadrantanopia.

22–E. Bilateral trauma to the cuneate gyri results in a lower altitudinal hemianopia.

23–C. Transection of the left optic tract results in a right hemianopia with macular sparing.

24–I. Transection of the infundibulum interrupts the supraopticohypophyseal tract. This results in diabetes insipidus with polydipsia and polyuria (e.g., craniopharyngioma).

25–H. Destruction of the oculomotor nerve results in paralysis of the levator palpebrae with a severe ipsilateral ptosis.

26–G. The trochlear nerve intorts, elevates, and abducts the globe. In fourth nerve palsy, the ipsilateral eye is extorted. The patient's chin points to the side of the lesion. Remember, head tilt is associated with fourth nerve palsy.

27–F. The ophthalmic division of the trigeminal nerve mediates the afferent limb of the corneal reflex.

28–E. In Wernicke encephalopathy, petechial hemorrhages in the mamillary bodies are commonly found, along with capillary hyperplasia, and astrocytic gliosis. Wernicke encephalopathy results from a thiamine (vitamin B₁) deficiency.

29–D. Severance of the optic tract results in contralateral hemianopia.

30–C. A midsagittal section through the optic chiasm results in bitemporal hemianopia.

31–B. Transection of the optic nerve (fasciculus) results in total blindness of the ipsilateral eye.

32–A. Foster Kennedy syndrome involves the olfactory tract and the optic nerve. This disorder can result from a tumor (olfactory groove meningioma). The signs are ipsilateral anosmia, ipsilateral optic atrophy, and contralateral papilledema.

Olfactory, Gustatory, and Limbic Systems

Objectives

- Describe the olfactory pathway.
- Describe the gustatory pathway, including a description of the taste bud and the primary tastes humans perceive.
- Differentiate between taste and flavor and list all of the components of flavor.
- List the traditional/main components, connections, and fiber pathways of the limbic system.
- Describe the components and significance of Papez Circuit.
- Describe the results of damage to the hippocampus, amygdala, and mammillary bodies—include a description of Klüver–Bucy syndrome.

I. OLFACTORY SYSTEM

- mediates the special visceral afferent (SVA) modality of **smell** via the olfactory nerve (**CN I**).
- the only sensory system that has no precortical relay in the thalamus.
- projects to the thalamus, hypothalamus, amygdala, and hippocampal formation.

A. Olfactory pathway (Figure 17.1; see Figure 1.2)

1. Olfactory receptor cells (*filia olfactoria*)

- chemoreceptors
- number 25 million on each side
- replaced throughout life (capable of regeneration)
- found in the nasal mucosa
- **first-order neurons** in the olfactory pathway
- unmyelinated bipolar neurons whose central processes are CN I
- have axons that enter the olfactory bulb and synapse in the olfactory glomeruli with **mitral** and **tufted cells**

2. Olfactory bulb

- lies on the cribriform plate of the ethmoid bone and receives the olfactory nerve.
- contains **mitral** and **tufted cells** (second-order neurons) that project via the olfactory tract and the lateral olfactory stria to the primary olfactory cortex and the amygdala.

3. Olfactory tract

- contains the anterior olfactory nucleus.
- gives rise to the medial and lateral olfactory striae.
- projects to the contralateral olfactory tract via the anterior commissure.

4. Lateral olfactory stria

- projects to the primary olfactory cortex and the amygdala.

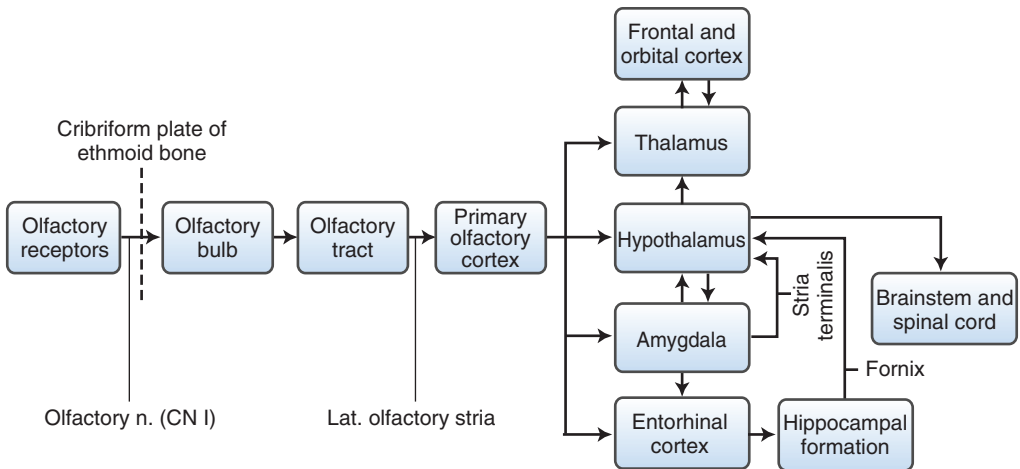


FIGURE 17.1. Pathways of the olfactory system. The olfactory nerve enters the olfactory bulb via the cribriform plate. Mitral and tufted cells of the olfactory bulb project via the lateral olfactory stria to the primary olfactory cortex (prepiriform and periamygdaloid cortices). The primary olfactory cortex projects to the hypothalamus, thalamus, amygdaloid nucleus, and entorhinal area. The olfactory system is the only sensory system that projects directly to the cortex of the telencephalon without a precortical relay in the thalamus.

5. Primary olfactory cortex

- overlies the **uncus** of the parahippocampal gyrus (area 34).
- receives input from the lateral olfactory stria.
- consists of **prepiriform** and **periamygdaloid cortices**.
- projects to the dorsomedial nucleus of the thalamus via the amygdala to the hypothalamus and via the entorhinal cortex (area 28) to the hippocampal formation.

6. Dorsomedial nucleus of the thalamus

- projects to the orbitofrontal cortex, where the conscious perception of smell takes place.

B. Clinical correlations

1. **Anosmia**, the loss of smell, may occur as a result of a lesion of the olfactory nerve.
2. Olfactory nerves may be damaged by **fractures of the cribriform plate**; by **meningitis**, **meningiomas**, or **gliomas**; or by abscesses of the frontal lobes.
3. **Olfactory hallucinations** may be a consequence of lesions of the parahippocampal uncus.
4. **Foster Kennedy syndrome**
 - results from a **meningioma of the olfactory groove**, which compresses the olfactory tract and the optic nerve.
 - results in ipsilateral anosmia, optic atrophy, and contralateral papilledema.
5. **Fracture of the cribriform plate of the ethmoid bone** may result in anosmia and cerebrospinal rhinorrhea.

II. GUSTATORY SYSTEM

- mediates the SVA modality of **taste**.
- mediates gustation, which, like smell, is a chemical sense.

A. Gustatory pathway (Figure 17.2)

1. Taste receptor cells

- chemoreceptors
- modified epithelial cells
- continuously regenerated

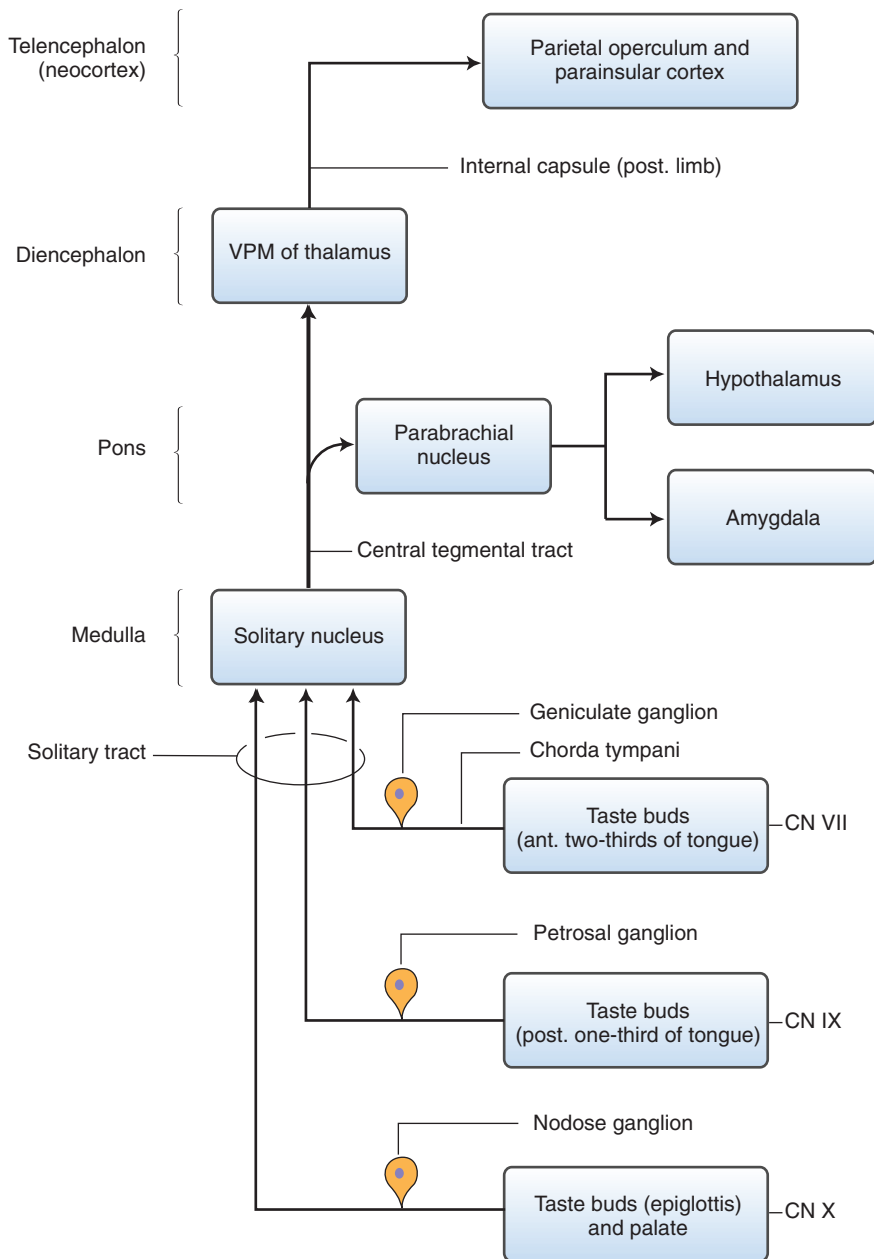


FIGURE 17.2. Gustatory pathway. CN VII, CN IX, and CN X transmit taste (SVA) information from the anterior two-thirds of the tongue, the posterior third of the tongue, the epiglottis, and the palate to the solitary tract and nucleus; from the solitary nucleus via the central tegmental tract to the medial parabrachial nucleus; and to the VPM nucleus of the thalamus, hypothalamus, and amygdaloid complex. The gustatory cortex is located in the parietal operculum and in the parainsular cortex. *SVA* = special visceral afferent.

- located in the taste buds of the tongue, epiglottis, and palate
 - innervated by SVA fibers of CN VII, CN IX, and CN X
- 2. First-order neurons**
- are **pseudounipolar cells** in the geniculate ganglion of CN VII, in the petrosal ganglion of CN IX, and in the nodose ganglion of CN X.
 - project centrally, via the solitary tract, to the solitary nucleus.

3. Solitary nucleus

- taste projects to rostral-most portion, the gustatory nucleus.
- receives taste input from the tongue and epiglottis.
- projects ipsilaterally via the **central tegmental tract** to the ventral posteromedial (VPM) nucleus of the thalamus.

4. Parabrachial nucleus of the pons

- receives taste input from the solitary nucleus.
- projects taste input to the hypothalamus and amygdala.

5. Ventral posteromedial nucleus

- projects to the gustatory cortex of the parietal operculum (area 43) and parainsular cortex.

6. Gustatory cortex of the insular area (area 43)

- projects via the entorhinal cortex (area 28) to the hippocampal formation.

B. Taste perception**1. The most commonly recognized tastes of the taste buds** are as follows:

- **sweetness** receptors concentrated on the apex of the tongue
- **saltiness** receptors concentrated posterolateral to the apex of the tongue
- **bitterness** receptors concentrated on the circumvallate papillae
- **sourness** receptors concentrated on the anterior two-thirds of the dorsal surface of the tongue

C. Clinical correlation: ageusia (gustatory anesthesia or lack of sense of taste)

- most frequently associated with peripheral lesions of CN VII (Bell's palsy and disease of the middle ear [chorda tympani]) and CN IX.

III. LIMBIC SYSTEM

- the anatomic substrate underlying behavioral and emotional expression.
- plays a role in feeling, feeding, fighting, fleeing, and mating.
- expresses itself through the hypothalamus via the autonomic nervous system (ANS).

A. Major components and connections (Figure 17.3)

- includes structures of the telencephalon, diencephalon, and midbrain.
 - 1. Orbitofrontal cortex** (see Figure 1.2)
 - mediates the conscious perception of **smell**.
 - has reciprocal connections with the dorsomedial nucleus of the thalamus.
 - interconnected via the medial forebrain bundle with the septal area and hypothalamic nuclei.
 - 2. Dorsomedial nucleus of the thalamus**
 - has reciprocal connections with the orbitofrontal and prefrontal cortices and the hypothalamus.
 - receives input from the amygdala.
 - plays a role in **affective behavior** and **memory**.
 - 3. Anterior nucleus of the thalamus**
 - receives input from the mamillary nucleus via the mamillothalamic tract and fornix.
 - projects to the cingulate gyrus.
 - a major link in the limbic **circuit of Papez**.
 - 4. Septal area** (see Figures 1.4 and 22.1B)
 - consists of a cortical septal area, including the paraterminal gyrus and the subcallosal area.

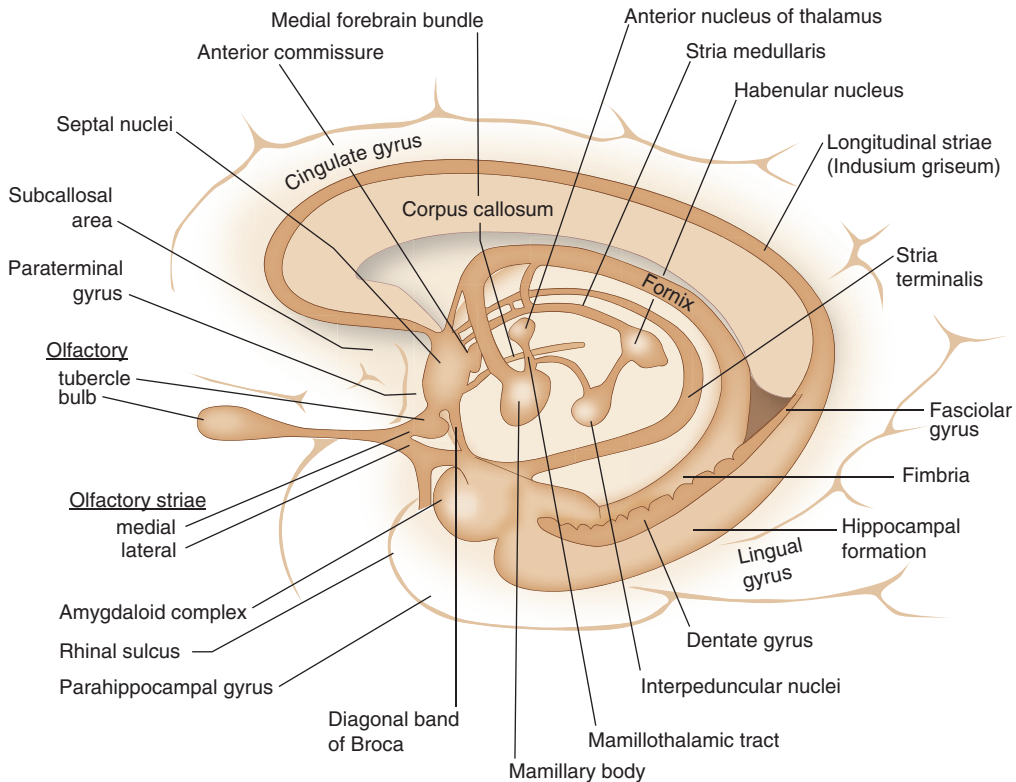


FIGURE 17.3. Major subcortical structures of the limbic system. The fornix projects from the hippocampal formation to the septal nuclei (precommissural fornix) and to the mamillary body (postcommissural fornix). The major pathway from the amygdaloid nucleus is the stria terminalis, which terminates in the septal nuclei and in the hypothalamus. The stria medullaris of the thalamus connects the septal nuclei to the habenular nucleus. (Modified from Carpenter MB, Sutlin J. *Human Neuroanatomy*. Baltimore, MD: Williams & Wilkins; 1983:618.)

- consists of a subcortical septal area (the septal nuclei), which lies between the septum pellucidum and the anterior commissure.
 - has reciprocal connections with the hippocampal formation via the fornix.
 - has reciprocal connections with the hypothalamus via the medial forebrain bundle.
 - projects via the **stria medullaris** (thalami) to the **habenular nucleus**.
- 5. Limbic lobe** (see Figure 22.1B)
- includes the **subcallosal area**, the **paraterminal gyrus**, the **cingulate gyrus** and **isthmus**, and the **parahippocampal gyrus**, which includes the **uncus** (see Figure 1.4).
 - contains, buried in the parahippocampal gyrus, the **hippocampal formation** and the **amygdaloid nuclear complex**.
- 6. Hippocampal formation** (Figure 17.4)
- functions in learning, memory, and recognition of novelty.
 - major input via the entorhinal cortex.
 - major output via the fornix.
- a. Major structures of the hippocampal formation**
- output via the fornix to the septal area and the mamillary nuclei.
 - input via the fornix from the septal area.
 - input via the entorhinal cortex (area 28) as the alveolar pathway to the hippocampus and the perforant pathway to the dentate gyrus.
- (1) Dentate gyrus** (see Figure 1.4)
- has a three-layered archicortex.
 - contains **granule cells** that receive hippocampal input and project it to the pyramidal cells of the hippocampus and subiculum.

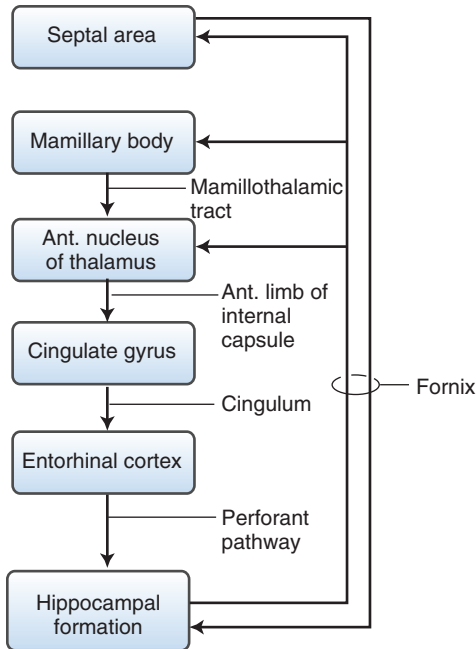


FIGURE 17.4. Limbic connections. Major afferent and efferent connections of the hippocampal formation. The circuit of Papez is hippocampal formation → mamillary nucleus → anterior thalamic nucleus → cingulate gyrus → hippocampal formation. The hippocampal formation consists of three components: the hippocampus proper (cornu ammonis), the subiculum, and the dentate gyrus. The hippocampus projects to the septal area, the subiculum projects to the mamillary nuclei, whereas the dentate gyrus does not project beyond the hippocampal formation.

(2) Hippocampus (cornu ammonis)

- has a three-layered archicortex.
- contains **pyramidal cells** that project via the fornix to the septal area and the hypothalamus.
- divided into four cytoarchitectural areas (CA1–CA4).

(3) Subiculum

- receives input via the hippocampal pyramidal cells.
- projects via the fornix to the mamillary nuclei and the anterior nucleus of the thalamus.

b. Major afferent connections to the hippocampal formation (see Figures 17.4 and 17.5)

- **cerebral association cortices** (areas 19, 22, and 7)
- **septal area**
- **anterior nucleus of the thalamus** via the cingulate gyrus, cingulum, and entorhinal cortex

c. Major efferent connections from the hippocampal formation (see Figures 17.4 and 17.5)

- **mamillary nucleus of the hypothalamus**
- **septal area**
- **anterior nucleus of the thalamus**

7. Amygdala (Figure 17.6)

- produces activities associated with feeding and nutrition when stimulated.
- may cause rage and aggressive behavior when stimulated.
- divided into a corticomedial group and a basolateral group. The corticomedial group receives olfactory input, and the basolateral receives cortical input.

a. Major afferent connections to the amygdala (see Figure 17.6)

- from the following structures:
 - (1) **olfactory bulb and olfactory cortex**
 - (2) **cerebral cortex** (limbic and sensory association cortices)
 - (3) **hypothalamus**

b. Major efferent connections from the amygdala (see Figure 17.6)

- to the following structures:
 - (1) **cerebral cortex** (limbic and sensory association cortices)
 - (2) **hypothalamus**
 - (3) **brainstem and spinal cord**

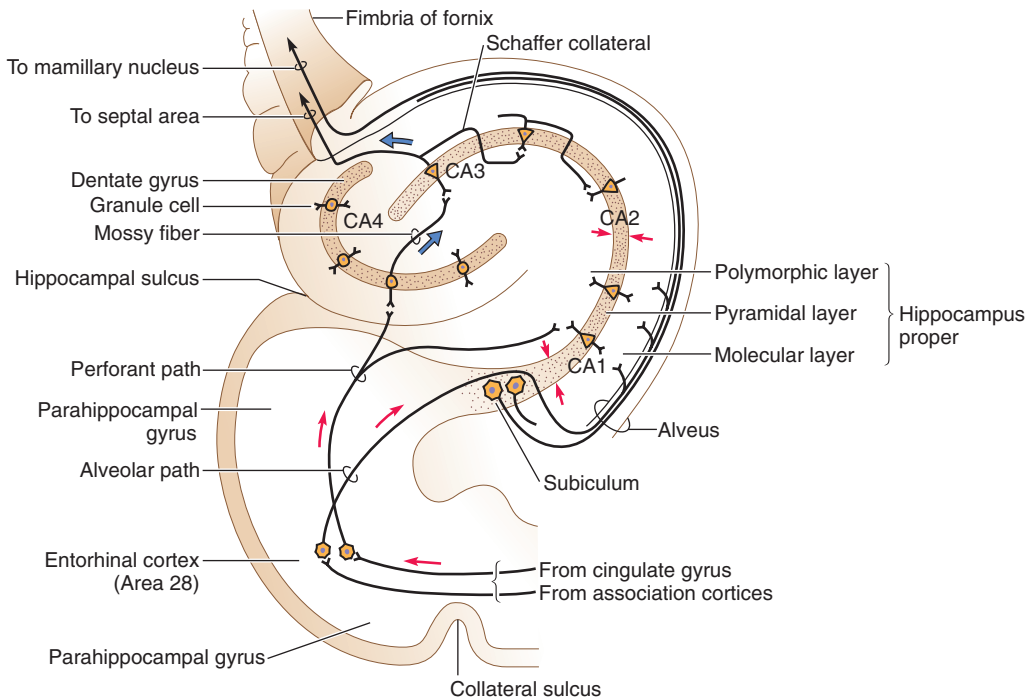


FIGURE 17.5. Major connections of the hippocampal formation. The two major hypothalamic output pathways are (1) granule cell via mossy fiber to pyramidal cell via precommissural fornix to septal nuclei and (2) subicular neuron via postcommissural fornix to the medial mamillary nucleus. The HF plays an important role in learning and memory, and lesions of the HF result in short-term memory defects. In Alzheimer's disease, loss of cells in the HF and entorhinal cortex leads to loss of memory and cognitive function. *HF* = hippocampal formation; *CA* = cornu ammonis.

8. Hypothalamus

- functions with the limbic system that projects to the brainstem and spinal cord (see Chapter 13).

9. Limbic midbrain nuclei

- **ventral tegmental area** (see Figure 21.2)
 - a. projects dopaminergic fibers to all limbic structures.
- **raphe nuclei of the midbrain** (see Figure 21.4)
 - a. project serotonergic fibers to all limbic structures.
- **locus ceruleus** (see Figure 21.3)
 - a. projects noradrenergic fibers to all limbic structures.

B. Major limbic fiber systems (see Figures 17.3, 17.4, and 17.6)

1. Fornix (see Figures 1.4, 1.5, and 17.3)

- projects from the hippocampal formation to the hypothalamus (mamillary nucleus), the anterior nucleus of the thalamus, and the septal area.
- projects from the septal area to the hippocampal formation.

2. Stria terminalis

- lies between the thalamus and the caudate nucleus.
- projects from the amygdala to the hypothalamus and the septal area.

3. Ventral amygdalofugal pathway

- projects from the amygdala to the hypothalamus, thalamus, brainstem, and spinal cord.

4. Stria medullaris (thalami)

- projects from the septal area to the habenular nucleus.

5. Diagonal band of Broca

- forms the medial border of the anterior perforated substance.
- interconnects the amygdala and the septal area.

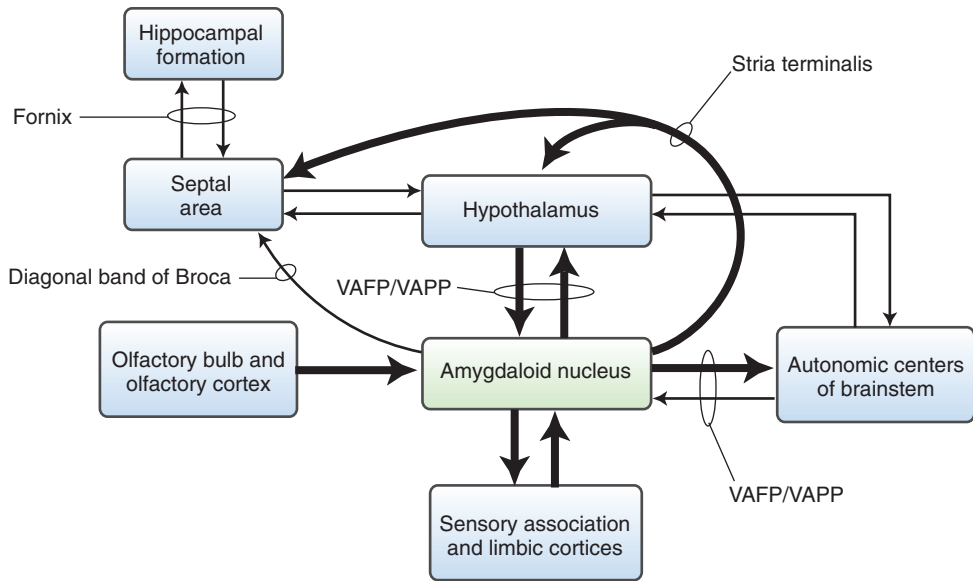


FIGURE 17.6. Major connections of the amygdala. The amygdaloid nucleus receives input from three major sources: the olfactory system, the sensory association and limbic cortices, and the hypothalamus. The major output from the amygdaloid nucleus is via two channels: the stria terminalis that projects to the hypothalamus and the septal area, and the ventral amygdalofugal pathway (VAFP) that projects to the hypothalamus, brainstem, and spinal cord. A smaller efferent bundle, the diagonal band of Broca, projects to the septal area. Afferent fibers from the hypothalamus and brainstem enter the amygdaloid nucleus via the ventral amygdalopetal pathway (VAPP).

6. Habenulointerpeduncular tract-tractus retroflexus

- projects from the habenular nucleus (epithalamus) to the interpeduncular nucleus (midbrain).

C. Papez circuit (see Figure 17.4)

- a circular pathway that interconnects the major limbic structures.
- contains the following stations:
 1. **Hippocampal formation**
 - projects via the **fornix** to the mamillary nucleus.
 2. **Mamillary body**
 - projects via the **mamillothalamic tract** to the anterior nucleus of the thalamus.
 3. **Anterior nucleus of the thalamus**
 - projects to the **cingulate gyrus**.
 - receives the mamillothalamic tract.
 4. **Cingulate gyrus**
 - projects via the entorhinal cortex to the hippocampal formation (see Figure 17.5).

D. Functional and clinical considerations

1. **Hippocampus**
 - has a low threshold for seizure activity.
 - involved in learning and memory.
 - bilateral ablation results in the **inability to form long-term memories**.
2. **Cingulate gyrus**
 - Lesions result in **akinesia, mutism, apathy, and indifference to pain**.
3. **Amygdala**
 - modulates hypothalamic and endocrine activities.
 - has the highest concentration of opiate receptors in the brain.
 - has a high concentration of estradiol receptors.
 - bilateral lesions result in **placidity**, with **loss of fear, rage, and aggression**.

4. Klüver–Bucy syndrome

- results from ablation of the temporal poles, including the amygdalae, the hippocampal formations, and the anterior temporal neocortex.
- can result from temporal lobe surgery for epilepsy, viral encephalitis (e.g., herpes simplex virus affects primarily the temporal lobes), and temporal lobe contusions owing to head trauma.
- characterized by placidity, hypersexuality, hyperphagia, and psychic blindness (visual agnosia).

5. Mamillary bodies and the dorsomedial nucleus of the thalamus

- damaged by chronic alcoholism and thiamine (vitamin B₁) deficiency, which results in **Korsakoff syndrome** (amnesic-confabulatory syndrome). Clinical signs include memory disturbances (amnesia), confabulation, and temporospatial disorientation.

Review Test

1. Rhinorrhea will most likely result from a fracture of _____ bone.

- (A) ethmoid
- (B) frontal
- (C) lacrimal
- (D) nasal
- (E) palatine

2. A patient presents with visual agnosia and is referred to a psychiatric unit. Psychic blindness will most likely result from bilateral lesions of the _____.

- (A) accumbens septi nucleus
- (B) amygdala
- (C) hippocampus
- (D) subiculum
- (E) superior colliculus

3. Who wrote the classic paper *A Proposed Mechanism of Emotion* that describes a major pathway of the limbic system?

- (A) Brodmann
- (B) Klüver and Bucy
- (C) Liepmann
- (D) Papez
- (E) Wernicke and Korsakoff

4. A 40-year-old woman was referred to a psychiatric unit with signs of nymphomania that were first manifest after a car accident. The responsible lesion would most likely be in the _____.

- (A) alveus
- (B) amygdala
- (C) cornu ammonis
- (D) dentate gyrus
- (E) subiculum

5. A 40-year-old man was admitted to the hospital and was examined by a staff neurologist. Examination revealed the following: alcohol abuse, paralysis of conjugate gaze, nystagmus, confusion, and memory loss. These symptoms are likely owing to a deficiency in _____.

- (A) niacin
- (B) vitamin A

- (C) vitamin B₁
- (D) vitamin B₆
- (E) vitamin B₁₂

6. Bilateral ablation of the _____ results in the inability to form long-term memories.

- (A) amygdala
- (B) cingulate gyrus
- (C) hippocampus
- (D) hypothalamus
- (E) ventral tegmental area

7. A 50-year-old woman presents with ipsilateral anosmia, optic atrophy, and contralateral papilledema. The syndrome is:

- (A) Brown-Séquard.
- (B) Edinger-Westphal.
- (C) Foster Kennedy.
- (D) Klüver-Bucy.
- (E) Wernicke-Korsakoff.

Questions 8 to 12

The response options for items 8 to 12 are the same. Select one answer for each item in the set.

- (A) Diagonal band of Broca
- (B) Medial forebrain bundle
- (C) Stria medullaris
- (D) Stria terminalis
- (E) Tractus retroflexus

Match the characteristic with the structure it best describes.

8. Consists of septohabenular fibers

9. Forms the medial border of the anterior perforated substance

10. Lies between the thalamus and the caudate nucleus

11. Projects from the epithalamus to the mid-brain tegmentum

12. Is a major efferent pathway from the amygdala

Questions 13 to 16

The response options for items 13 to 16 are the same. Select one answer for each item in the set.

- (A) Amygdala
- (B) Hippocampal formation
- (C) Both A and B
- (D) Neither A nor B

Match each characteristic with the structure it most appropriately describes.

- 13.** Is located in the temporal lobe
- 14.** Is destroyed in Klüver-Bucy syndrome
- 15.** Projects via the stria terminalis
- 16.** Receives direct olfactory input

Answers and Explanations

1–A. Rhinorrhea will most likely result from a fracture of the cribriform plate of the ethmoid bone, which can tear the arachnoid membrane and result in a leakage of cerebrospinal fluid into the nasal cavity.

2–B. Bilateral lesions of the amygdalae result in psychic blindness, the inability to recognize objects visually. Subjects can see objects but do not understand what they see. Bilateral lesions of the hippocampus result in memory loss (e.g., viral encephalitis). Lesions of the superior colliculus result in paralysis of upward and downward gaze.

3–D. Papez wrote *A Proposed Mechanism of Emotion*; the circuit is hippocampal formation → mamillary body → anterior thalamic nucleus → cingulate gyrus → entorhinal cortex → hippocampal formation (see Figure 17.4). Klüver–Bucy syndrome is characterized by placidity, hypersexuality, hyperphagia, and psychic blindness (visual agnosia). Wernicke–Korsakoff syndrome is characterized by alcohol abuse resulting in thiamine deficiency, conjugate gaze palsies, ataxia, confusion, and memory loss. Liepmann is known for his classic book on ataxias. Brodmann is known for his brain maps, called the Brodmann areas.

4–B. Bilateral ablation of the inferior temporal cortex results in damage to the amygdala resulting in hypersexuality, hyperphagia, docility, and psychic blindness (Klüver–Bucy syndrome).

5–C. Lack of thiamine B_1 results in Wernicke–Korsakoff syndrome; the classic clinical triad of Wernicke encephalopathy is confusion, gait ataxia, and ophthalmoplegia. Korsakoff syndrome is profound memory impairment and confabulation. Vitamin A deficiency results in impaired night vision; when ingested in excess, vitamin A may cause pseudotumor cerebri. Pyridoxine (vitamin B_6) is used to prevent isoniazid neuropathy. Vitamin B_{12} deficiency results in anemia and subacute combined degeneration. Niacin (nicotinic acid) is used to prevent pellagra.

6–C. Bilateral ablation of the hippocampus results in the inability to form long-term memories. The hippocampus plays a major role in learning and memory.

7–C. Foster Kennedy syndrome includes ipsilateral anosmia, optic atrophy, and contralateral papilledema; pressure on the olfactory tract causes ipsilateral anosmia, whereas pressure on the optic nerve causes ipsilateral optic atrophy and a central scotoma and contralateral papilledema. Edinger and Westphal described this parasympathetic nucleus of the rostral midbrain, more appropriately called the accessory oculomotor nucleus (p. 283). Brown–Séquard is associated with a spinal cord lesion, spinal cord hemisection. Klüver and Bucy described the limbic lobe syndrome (p. 439). Wernicke–Korsakoff syndrome consists of Wernicke encephalopathy and Korsakoff psychosis.

8–C. The stria medullaris (thalami) contains septohabenular fibers (i.e., fibers that project from the septal nuclei to the habenular nuclei). The stria medullaris (singular) should not be confused with the striae medullares (plural). The striae medullares (rhombencephali) arise from the arcuate nuclei of the medulla and are seen on the floor of the rhomboid fossa.

9–A. The diagonal band of Broca is the medial border of the anterior perforated substance. This fiber bundle contains amygdaloseptal and septoamygdalar fibers. The nucleus of the diagonal band projects via the fornix to the hippocampal formation.

10–D. The stria terminalis and the vena terminalis lie in the sulcus terminalis between the thalamus and the caudate nucleus.

11–E. The tractus retroflexus contains habenulointerpeduncular fibers that project from the habenular nuclei of the epithalamus to the interpeduncular nucleus of the midbrain tegmentum.

12–D. The stria terminalis is a major efferent pathway from the amygdala. It projects to the septal area and to the bed nucleus of the stria terminalis.

13–C. Both the hippocampal formation and the amygdala are found in the parahippocampal gyrus of the temporal (limbic) lobe.

14–C. The hippocampal formation and the amygdala are both involved in Klüver–Bucy syndrome.

15–A. The amygdala projects via the stria terminalis and via the ventral amygdalofugal pathway. The stria terminalis is the most prominent projection from the amygdaloid complex.

16–A. The amygdala receives both direct and indirect olfactory input.

Basal Nuclei and the Extrapyrarnidal Motor System

Objectives

- List the traditional/main components of the basal nuclei and include the terminology that describes their groupings.
- Describe the major connections of the basal nuclei.
- List the major neurotransmitters of the basal nuclei.
- Trace the indirect and direct pathways through the basal nuclei.
- Describe Parkinson's disease, Huntington's disease, and ballisms.

I. BASAL NUCLEI (FIGURE 18.1)

- consists of subcortical nuclei (gray matter) within the cerebral hemispheres.
- commonly known by their misnomer—**basal ganglia**.
- list of components varies widely and depends on focus of interest.

A. Four main components

1. **Caudate nucleus**
2. **Putamen**
3. **Globus pallidus**
4. **Amygdala** (see Chapter 17 III A 7)

B. Groupings of the basal nuclei

1. **Striatum (neostriatum)**
 - consists of the **caudate nucleus** and the **putamen**, which are similar in structure and connections and have a common embryologic origin.
2. **Lentiform nucleus**
 - consists of the **putamen** and the **globus pallidus**.
3. **Corpus striatum**
 - consists of the **lentiform nucleus** and the **caudate nucleus**.

II. EXTRAPYRAMIDAL MOTOR SYSTEM (SEE FIGURE 18.1)

- also called the striatal motor system.
- plays a role in the initiation and execution of somatic motor activity, in particular of willed movement.

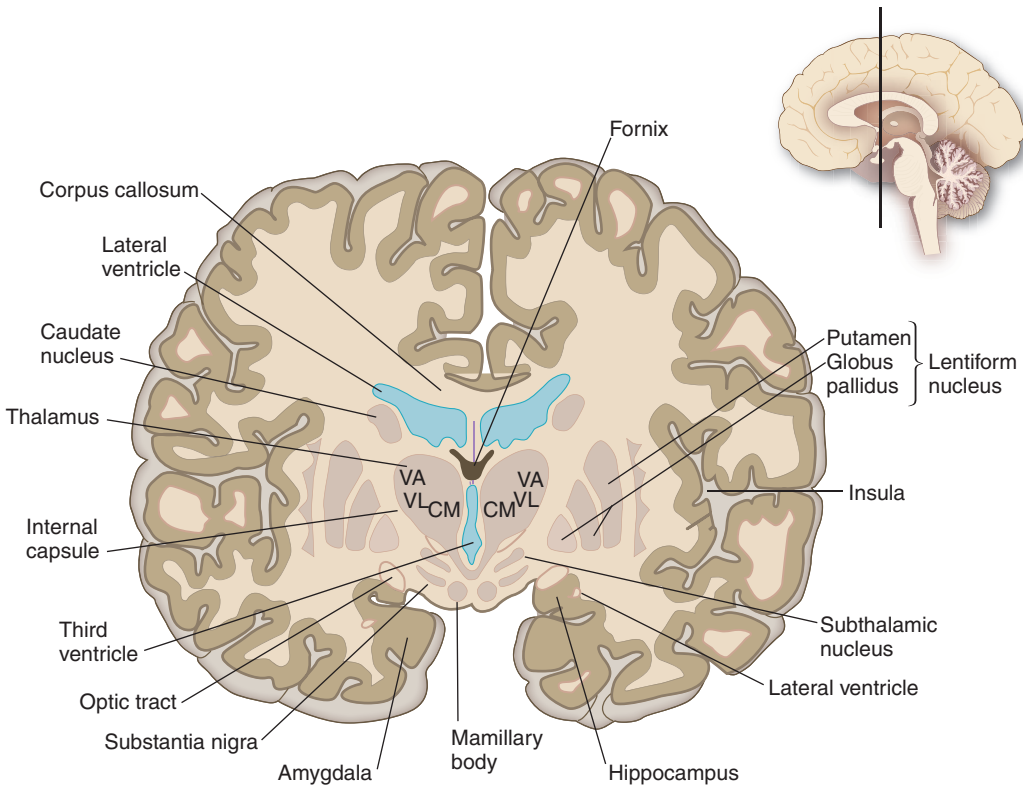


FIGURE 18.1. A coronal section through the mid-thalamus at the level of the mamillary bodies. The basal nuclei are all prominent at this level and include the striatum and the lentiform nucleus. The subthalamic nucleus and substantia nigra are important components of the striatal motor system. (Modified from Fix JD. *High-Yield Neuroanatomy*. 3rd ed. Philadelphia, PA: Lippincott Williams & Wilkins; 2005:142.)

- involved in automatic stereotyped motor activity of a postural and reflex nature.
- exerts its influences on motor activities via the thalamus, motor cortex, corticobulbar and cortico-spinal systems.

A. Components of the extrapyramidal motor system

- consist of the following nuclei.
 - 1. Striatum (caudatoputamen or neostriatum)**
 - Caudate nucleus
 - Putamen
 - 2. Globus pallidus (pallidum or paleostriatum)**
 - primary output nuclei of the basal nuclei
 - a. Medial (internal) segment**
 - adjacent to the internal capsule.
 - b. Lateral (external) segment**
 - adjacent to the putamen.
 - 3. Subthalamic nucleus**
 - lies between the internal capsule and the thalamus and between the internal capsule and the lenticular fasciculus.
 - 4. Thalamus**
 - **Ventral anterior nucleus**
 - **Ventral lateral nucleus**
 - **Centromedian nucleus**

5. Substantia nigra

- **Pars compacta**
 - a. contains dopaminergic neurons, which contain the pigment melanin.
- **Pars reticularis**
 - a. contains gamma-aminobutyric acid (GABA)-ergic neurons.
 - b. functions as another basal nuclei output.

6. Pedunculopontine nucleus

- lies in the lateral tegmentum of the caudal midbrain.

B. Major connections of the extrapyramidal system (Figure 18.2)

1. Striatum

- receives its largest input from the **neocortex**—from almost all neocortical areas.
- receives input from the **thalamus** (centromedian nucleus) and from the **substantia nigra**.
- projects fibers to two major nuclei: the **globus pallidus** and the **substantia nigra** (pars reticularis).

2. Globus pallidus (Figure 18.3)

- receives input from two major nuclei: the **striatum** and the **subthalamic nucleus**.
- projects fibers to three major nuclei: the **subthalamic nucleus**, the **thalamus** (ventral anterior, ventral lateral, and centromedian nuclei), and the **pedunculopontine nucleus**.

3. Subthalamic nucleus

- receives input from the **globus pallidus** and from the **motor cortex**.
- projects fibers to the globus pallidus.

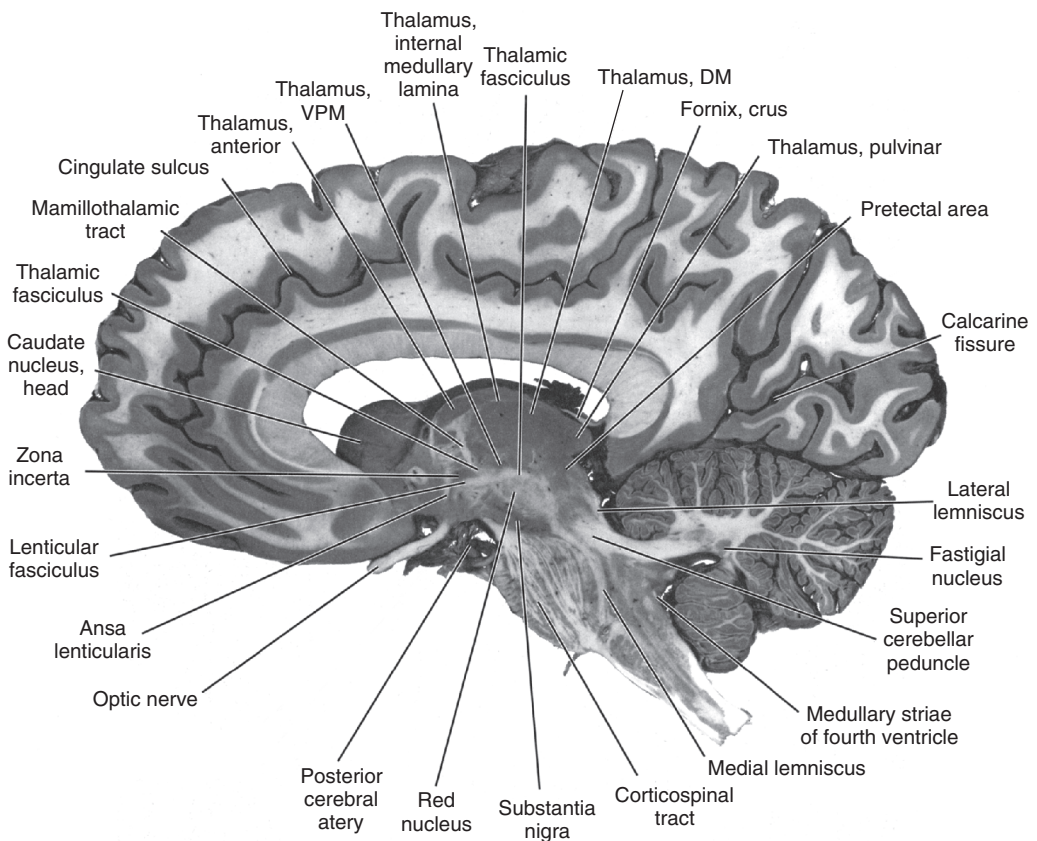


FIGURE 18.2. A parasagittal section through the caudate nucleus and the substantia nigra. (Modified from Woolsey TA, Hanaway J, Gado MH. *The Brain Atlas: A Visual Guide to the Human Central Nervous System*. 2nd ed. Hoboken, NJ: John Wiley & Sons; 2003:128.)

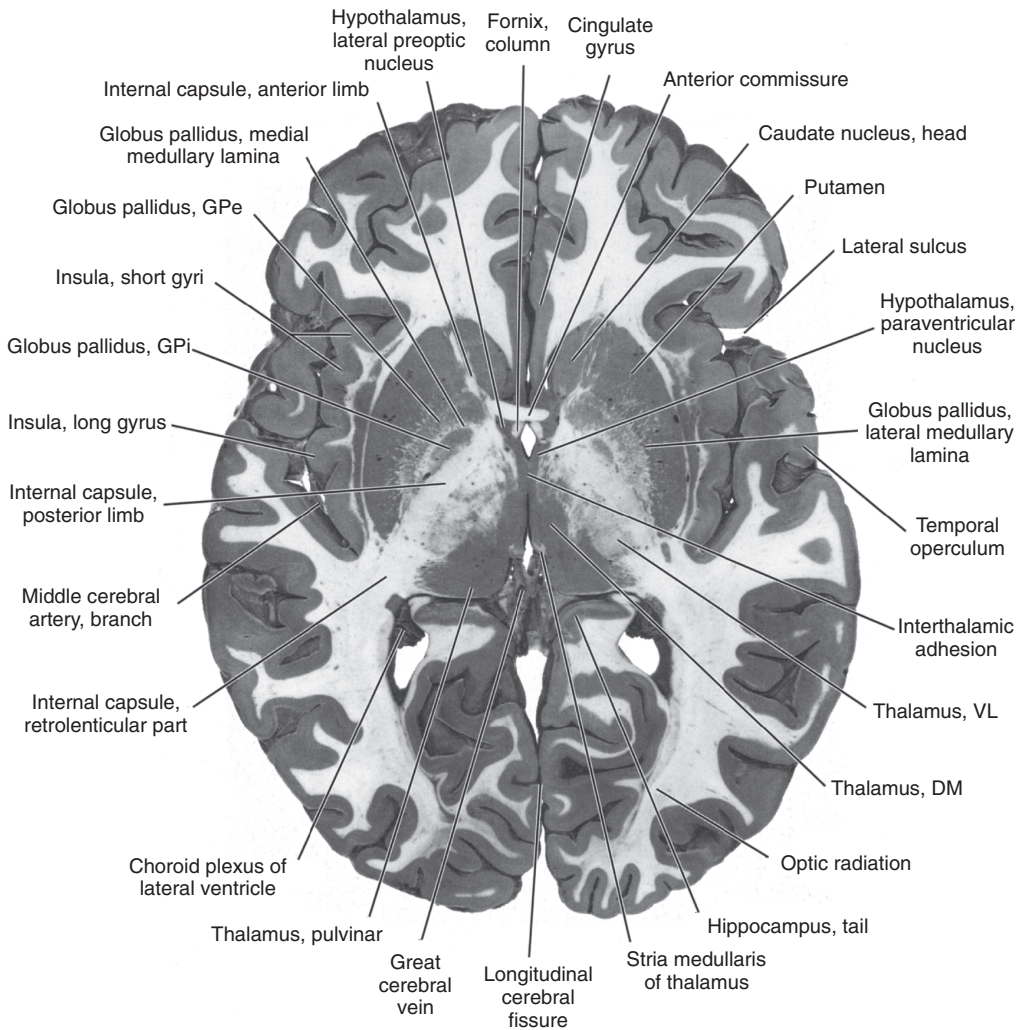


FIGURE 18.3. An axial (horizontal) section through the anterior commissure and the massa intermedia. (Modified from Woolsey TA, Hanaway J, Gado MH. *The Brain Atlas: A Visual Guide to the Human Central Nervous System*. 2nd ed. Hoboken, NJ: John Wiley & Sons; 2003:100.)

4. Thalamus (see Figure 13.1)

- Input to the thalamus
 - a. Globus pallidus
 - projects to the ventral anterior, ventral lateral, and centromedian nuclei.
 - b. Substantia nigra
 - projects from the pars reticularis to the **ventral anterior, ventral lateral, and the mediodorsal nuclei** of the thalamus.
- Projections from the thalamus
 - a. Motor cortex (area 4)
 - from the ventral lateral and centromedian nuclei
 - b. Premotor cortex (area 6)
 - from the ventral anterior and ventral lateral nuclei
 - c. Supplementary motor cortex (area 6)
 - from the ventral lateral and ventral anterior nuclei
 - d. Striatum
 - from the centromedian nucleus

5. Substantia nigra

- receives input from the **striatum**.
- projects fibers to the **striatum** and the **thalamus** (ventral anterior, ventral lateral, and dorsomedial nuclei).

6. Pedunculopontine nucleus

- receives GABA-ergic input from the **globus pallidus**.
- projects glutaminergic fibers to the **globus pallidus** and to the **substantia nigra**.

C. Major neurotransmitters of the neurons of the extrapyramidal system (Figure 18.4)

1. Glutamate-containing neurons (see Figure 21.10)

- project from the cerebral cortex to the striatum.
- project from the subthalamic nucleus to the globus pallidus.
- excite **striatal GABA-ergic** and **cholinergic neurons**.

2. GABA-containing neurons (see Figure 21.9)

- the predominant neurons of the striatal system.
- found in the striatum, globus pallidus, and substantia nigra (pars reticularis).
- give rise to the following **GABA-ergic projections**: striatopallidal, striatonigral, pallidothalamic, and nigrothalamic projections.
- degenerate in Huntington's disease.

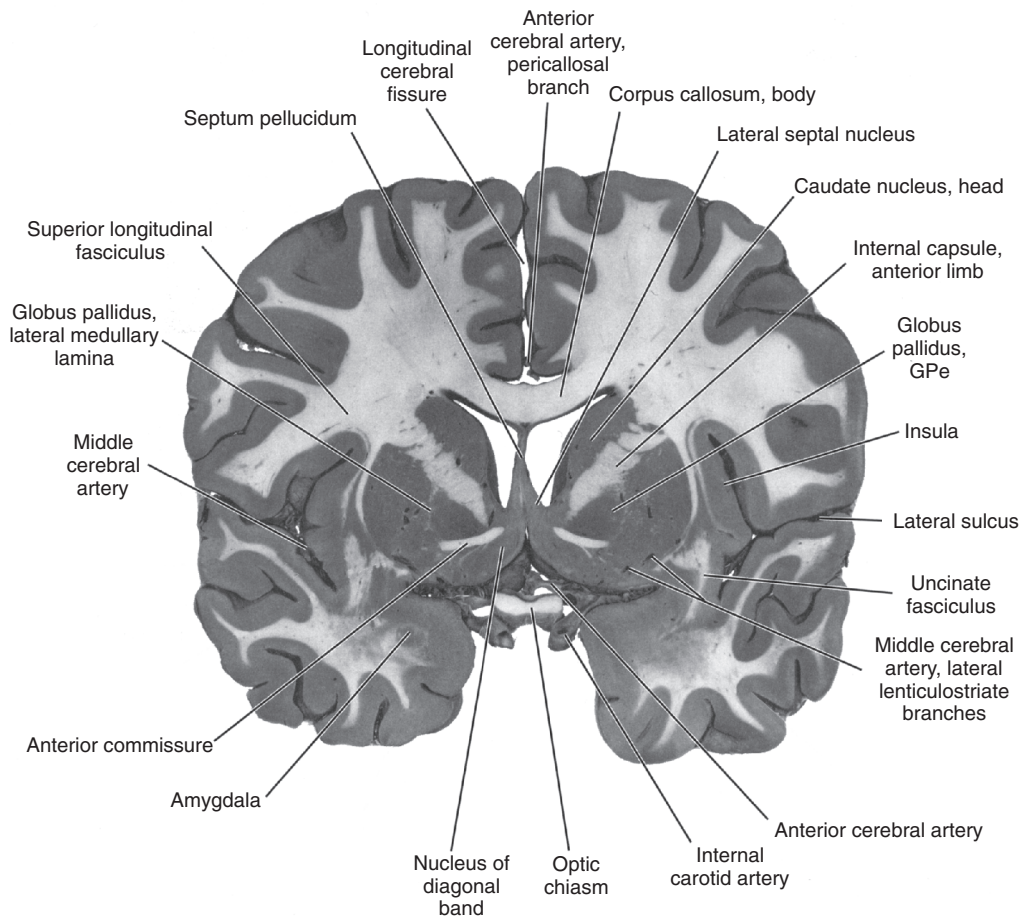


FIGURE 18.4. A coronal section through the lentiform nucleus and the amygdala; the lentiform nucleus consists of the putamen and the globus pallidus. The amygdaloid nucleus appears as a circular profile below the uncus. (Modified from Woolsey TA, Hanaway J, Gado MH. *The Brain Atlas: A Visual Guide to the Human Central Nervous System*. 2nd ed. Hoboken, NJ: John Wiley & Sons; 2003:60.)

3. **Dopamine-containing neurons** (see Figure 21.2)
 - found in the pars compacta of the substantia nigra.
 - give rise to the dopaminergic nigrostriatal projection.
 - degenerate in Parkinson's disease.
4. **Neurons containing acetylcholine (ACh)** (see Figure 21.1)
 - local circuit neurons found in the striatum.
5. **Neuropeptide-containing neurons** (see Figures 21.6 through 21.8)
 - include enkephalin, dynorphin, substance P, somatostatin, neurotensin, neuropeptide Y, and cholecystokinin.
 - also found in the basal nuclei.
 - coexist with the major neurotransmitters (e.g., GABA and/or enkephalin and GABA and/or substance P).

D. Ventral striatopallidal complex and its connections

- play a role in initiating movements in response to motivational and emotional activity (e.g., limbic functions).
 1. **Ventral striatum**
 - consists of the **nucleus accumbens** and the olfactory tubercle.
 - receives input from the olfactory, prefrontal, and hippocampal cortices.
 - projects to the ventral pallidum.
 2. **Ventral pallidum**
 - consists of the substantia innominata.
 - receives input from the ventral striatum.
 - projects to the medial dorsal nucleus of the thalamus.

E. Clinical correlations

1. **Parkinson's disease**
 - a condition that is associated with degeneration and depigmentation of neurons in the substantia nigra.
 - results in the **depletion of dopamine** in the caudate nucleus and putamen.
 - includes clinical manifestations of **bradykinesia** and **hypokinesia** (difficulty in initiating and performing volitional movements); **rigidity** (cog-wheel and lead-pipe rigidity); and **resting tremor** (pill-rolling tremor).
2. **MPTP-induced parkinsonism**
 - caused by 1-methyl-4-phenyl-1,2,3,6-tetrahydropyridine (MPTP), a **meperidine analog** found in illicit recreational drugs.
 - results in the destruction of dopaminergic neurons that are located in the substantia nigra.
3. **Progressive supranuclear palsy**
 - associated with **Parkinson's disease**. Progressive supranuclear palsy together with Parkinson's disease is called the Parkinson-plus syndrome.
 - characterized by supranuclear ophthalmoplegia, primarily downgaze paresis, which is followed by paresis of other eye movements. As the disease progresses, the remainder of the motor cranial nerves become involved, resulting in the clinical picture of pseudo-bulbar palsy (see Glossary).
 - characterized by neuronal cell loss in the globus pallidus, red nucleus, substantia nigra, periaqueductal gray, and dentate nucleus.
 - spares the cerebral and the cerebellar cortices.
 - results in neurofibrillary tangles in the surviving neurons.
4. **Huntington's disease (chorea)**
 - an inherited **autosomal dominant movement disorder** associated with severe degeneration of the cholinergic and GABA-ergic neurons, which are located in the caudate nucleus and putamen.
 - usually accompanied by **gyral atrophy** in the frontal and temporal lobes.
 - can be traced to a single gene defect on chromosome 4.

- characterized by impaired initiation and slowness of saccadic eye movements; patients cannot make a volitional saccade without moving the head.
 - results in clinical manifestations of **choreiform movements** and **progressive dementia**.
 - results in **hydrocephalus ex vacuo** owing to the loss of neurons located in the head of the caudate nucleus, and to a lesser extent in the putamen.
 - prenatal and postnatal diagnosis using DNA techniques is available.
5. **Other choreiform dyskinesias**
- **Sydenham chorea (St. Vitus dance)**
 - a. the commonest chorea.
 - b. occurs mainly in girls as a sequela to rheumatic fever.
 - **Chorea gravidarum**
 - a. occurs usually during the second trimester of pregnancy.
 - b. in many cases, a history of Sydenham chorea can be obtained.
6. **Ballism and hemiballism**
- extrapyramidal motor disorders most often resulting from a vascular lesion (infarct) of the subthalamic nucleus.
 - characterized by **violent flinging (ballistic) movements of one or both extremities**; symptoms appear on the contralateral side.
 - may be treated with dopamine-blocking drugs or with GABA-mimetic agents.
 - may be treated surgically by **ventrolateral thalamotomy**.
7. **Hepatolenticular degeneration (Wilson disease)**
- an autosomal recessive disorder owing to a **defect in the metabolism of copper** (ceruloplasmin).
 - has its gene locus on chromosome 13.
 - results in clinical manifestations of **tremor, rigidity, and choreiform or athetotic movements**. Tremor is the commonest neurologic sign.
 - has psychiatric symptoms, including psychosis, personality disorders, and dementia.
 - results in a **corneal Kayser–Fleischer ring**, which is pathognomonic.
 - marked by lesions in the liver (cirrhosis) and in the lentiform nuclei (necrosis and cavitation of the putamen).
 - diagnosed by low serum ceruloplasmin, elevated urinary excretion of copper, and increased copper concentration in liver biopsy.
 - treated with the copper-chelating agent D-penicillamine and pyridoxine for anemia.
8. **Tardive dyskinesia**
- a syndrome of repetitive choreic movements affecting the face, limbs, and trunk.
 - results from treatment with antipsychotic drugs (e.g., phenothiazines, butyrophenones, or metoclopramide).

Review Test

1. A six-year-old girl has brief, irregular contractions in her feet; symptoms are suspected to be a result of an untreated strep infection. What is the diagnosis?

- (A) Chorea gravidarum
- (B) Chorea major
- (C) Ballism
- (D) Hemiballism
- (E) Sydenham chorea

2. Which thalamic nucleus projects to the striatum?

- (A) Centromedian nucleus
- (B) Mediodorsal nucleus
- (C) Ventral anterior nucleus
- (D) Ventral lateral nucleus
- (E) Ventral posterolateral nucleus

3. The globus pallidus projects to the thalamus via the:

- (A) ansa lenticularis.
- (B) ansa peduncularis.
- (C) fasciculus retroflexus.
- (D) stria medullaris.
- (E) stria terminalis.

4. The predominant neurons of the striatal system contain:

- (A) acetylcholine.
- (B) dopamine.
- (C) GABA.
- (D) glutamate.
- (E) serotonin.

5. An ophthalmologist sees a Kayser–Fleischer ring while examining Descemet’s membrane with a slit lamp; what trace metal is found in the membrane?

- (A) Aluminum
- (B) Copper
- (C) Iron
- (D) Magnesium
- (E) Mercury

6. A 50-year-old woman has resting tremor, cog-wheel rigidity, bradykinesia, and shuffling

gait. The incidence of this disease in patients over 50 years of age is:

- (A) 1%.
- (B) 2%.
- (C) 3%.
- (D) 4%.
- (E) 5%.

Questions 7 to 15

The response options for items 7 to 15 are the same. Select one answer for each item in the set.

- (A) Chorea gravidarum
- (B) Hemiballism
- (C) Hepatolenticular degeneration
- (D) Huntington’s disease
- (E) Parkinson’s disease
- (F) Sydenham chorea
- (G) Tardive dyskinesia

Match each of the characteristics with the appropriate lettered movement disorder.

7. Is the overall commonest cause of chorea

8. Results from a loss of dopaminergic neurons in the pars compacta of the substantia nigra

9. A corneal Kayser–Fleischer ring is pathognomonic for this dyskinesia

10. Results from a lesion of the subthalamic nucleus

11. Is characterized by repetitive choreic movements affecting the face, limbs, and trunk, which results from treatment with antipsychotic drugs

12. Can be traced to a single gene defect on chromosome 4

13. Has its gene locus on chromosome 13

14. Is characterized by cortical atrophy and loss of neurons in the head of the caudate nucleus

15. Central nervous system lesions are characterized by necrosis and cavitation of the putamen

Answers and Explanations

- 1-E.** Sydenham chorea (St. Vitus dance) is the commonest chorea. It occurs mainly in girls as a sequela to rheumatic fever, which may develop after a strep infection. Chorea major (Huntington's disease) is an inherited disorder that manifests as choreiform movements and progressive dementia; chorea gravidarum occurs during the second trimester of pregnancy; and ballism and hemiballism are violent flinging movement of one or both extremities as a result of an infarct of the subthalamic nucleus.
- 2-A.** The striatum (caudate nucleus and putamen) receives thalamic input from the centromedian nucleus, the largest of the intralaminar nuclei.
- 3-A.** The globus pallidus projects to the thalamus via the lenticular and thalamic fasciculi and via the ansa lenticularis. The ansa peduncularis (part of the inferior thalamic peduncle) interconnects the amygdaloid nucleus and the hypothalamus. It also interconnects the orbitofrontal cortex and the thalamus (mediodorsal nucleus). The fasciculus retroflexus (habenulointerpeduncular tract) interconnects the habenular nucleus and the interpeduncular nucleus. The stria medullaris (thalami) interconnects the septal area (nuclei) and the habenular nuclei. The stria terminalis projects from the amygdaloid complex to the septal area and the hypothalamus.
- 4-C.** GABA-containing neurons are the predominant neurons of the striatal system. They are found in the striatum, globus pallidus, and substantia nigra (pars reticularis).
- 5-B.** Wilson disease is an autosomal recessive disorder that results from a defect in the metabolism of copper. Wilson disease is diagnosed by low serum ceruloplasmin, elevated urinary excretion of copper, and increased copper concentration in liver biopsy. Tremor is the commonest symptom and is known as the wing-beating tremor.
- 6-A.** The incidence of Parkinson's disease is 1% of the population past 50 years of age.
- 7-F.** Sydenham chorea (St. Vitus dance) is the commonest cause of chorea overall. Magnetic resonance imaging (MRI) studies show an increased signal in the head of the caudate nucleus with T_2 -weighted images. Quantitative MRI reveals an increase in the size of the caudate nucleus, putamen, and globus pallidus. In Huntington disease, there is massive loss of neurons in the caudatoputamen.
- 8-E.** Parkinson's disease results from a loss of dopaminergic neurons in the pars compacta of the substantia nigra.
- 9-C.** Hepatolenticular degeneration, Wilson disease, is an autosomal recessive disorder resulting from a defect in the metabolism of copper. The Kayser-Fleisher ring is a green band of pigmentation found around the limbus in Descemet membrane; it is a pathognomonic of Wilson disease.
- 10-B.** Hemiballism results from a contralateral lesion (usually vascular) of the subthalamic nucleus. It is characterized by violent flinging (ballistic) movements of one or both extremities.
- 11-G.** Tardive dyskinesia is a syndrome characterized by repetitive choreic movements affecting the face and trunk, which results from treatment with antipsychotic drugs (e.g., phenothiazines, butyrophenones, or metoclopramide).
- 12-D.** Huntington disease has its gene locus on chromosome 4 (gene location 4p16.3).
- 13-C.** In Wilson disease the abnormal gene has been assigned to the esterase D locus on chromosome 13.
- 14-D.** Huntington disease is characterized by cortical atrophy and loss of neurons in the head of the caudate nucleus, which results in hydrocephalus ex vacuo.
- 15-C.** Wilson disease is characterized by necrosis and cavitation of the putamen.

Objectives

- Describe the external anatomy of the cerebellum and identify the parts on a diagram.
- Differentiate between the longitudinal divisions of the cerebellum and the anterior-posterior divisions of the cerebellum and ascribe a general function to each.
- Describe the cerebellar peduncles.
- List the layers of the cerebellar cortex and the cells contained within each.
- List the fiber types of the cerebellum and the cells/systems associated with each.
- Describe the major cerebellar pathways.
- Describe the results of cerebellar dysfunction, including hypotonia, and dyssynergia.
- Describe the results of cerebellar lesions, including syndromes, tumors, and atrophies.

I. OVERVIEW

- develops from the alar plates (rhombic lips) of the metencephalon.
- located infratentorially within the posterior fossa and lies between the temporal and occipital lobes and the brainstem.
- has three primary functions: the **maintenance of posture and balance**, the **maintenance of muscle tone**, and the **coordination of voluntary motor activity**.

II. MAJOR DIVISIONS OF THE CEREBELLUM

- consists of a midline **vermis** and two lateral **hemispheres**.
- covered by a three-layered **cortex**, which contains folia and fissures.
- contains a central medullary core, which is the **white matter** that contains myelinated axons and the four cerebellar nuclei (dentate, emboliform, globose, and fastigial nuclei). The emboliform and globose nuclei are called the interposed nucleus.

A. Cerebellar lobes (Figure 19.1)

- phylogenetic and functional divisions.
 1. **Anterior lobe (spinocerebellum)**
 - lies anterior to the primary fissure.
 - receives input from stretch receptors (muscle spindles) and Golgi tendon organs (GTOs) via the spinocerebellar tracts.
 - plays a role in the regulation of muscle tone.

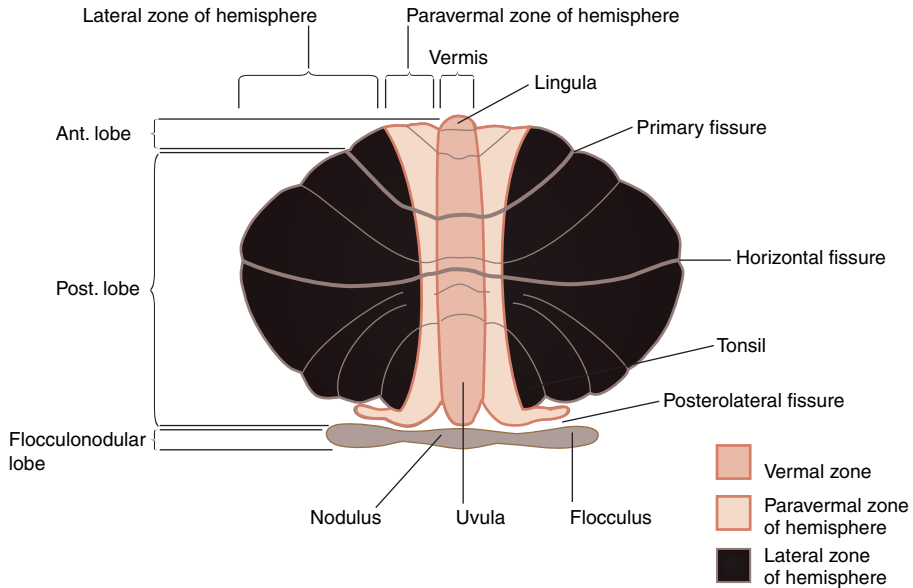


FIGURE 19.1. Schematic diagram of the fissures, lobules, and lobes of the cerebellum. Functional longitudinal zones of the cerebellum are associated with cerebellar nuclei. The vermal (median) zone projects to the fastigial nucleus, the paravermal (paramedian) zone projects to the interposed nucleus, and the lateral zone projects to the dentate nucleus.

2. Posterior lobe (neocerebellum)

- lies between the primary fissure and the posterolateral fissure.
- receives massive input from the neocortex via the corticopontocerebellar fibers.
- plays a role in the coordination of voluntary motor activity.

3. Flocculonodular lobe (vestibulocerebellum)

- consists of the nodulus (of the vermis) and the flocculus.
- receives input from the vestibular system.
- plays a role in the maintenance of posture and balance.

B. Longitudinal organization of the cerebellum (see Figure 19.1)

- includes three functional longitudinal zones that are associated with specific cerebellar nuclei and pathways.
 - 1. Median (vermal) zone of the hemisphere**
 - contains the vermal cortex, which projects to the fastigial nucleus.
 - 2. Paramedian (paravermal) zone of the hemisphere**
 - contains the paravermal cortex, which projects to the interposed nuclei (emboliform and globose nuclei).
 - 3. Lateral zone of the hemisphere**
 - contains the hemispheric cortex, which projects to the dentate nucleus.

C. Cerebellar peduncles (see Figure 1.7)

1. Inferior cerebellar peduncle

- connects the cerebellum to the caudal medulla and rostral pons.
- consists of two divisions:

a. Restiform body

- an afferent fiber system containing
 - (1) **Posterior spinocerebellar tract**
 - (2) **Cuneocerebellar tract**
 - (3) **Olivocerebellar tract**

b. Juxtarestiform body

- contains afferent and efferent fibers:
 - (1) **Vestibulocerebellar fibers (afferent)**
 - (2) **Cerebellovestibular fibers (efferent)**

2. Middle cerebellar peduncle

- the largest cerebellar peduncle.
- connects the cerebellum to the pons.
- an afferent fiber system containing **pontocerebellar fibers** to the neocerebellum.

3. Superior cerebellar peduncle

- connects the cerebellum to the caudal pons and rostral midbrain.
- represents the major output from the cerebellum.

a. Efferent pathways

- Dentatorubrothalamic tract
- Interpositorubrothalamic tract
- Fastigiotalamic tract
- Fastigiovestibular tract

b. Afferent pathways

- Anterior spinocerebellar tract
- Trigemino-cerebellar fibers
- Cerebello-cerebellar fibers

III. CEREBELLAR CORTEX

A. Three-layered cerebellar cortex (Figure 19.2)

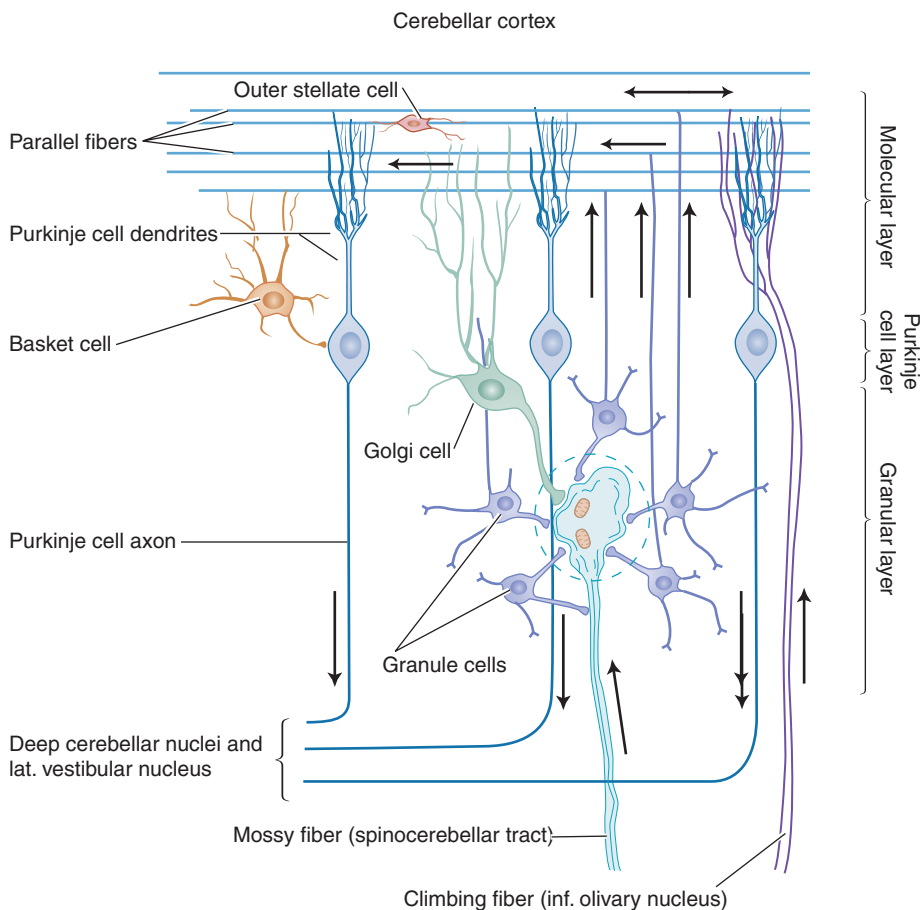


FIGURE 19.2. Schematic diagram of the three-layered cerebellar cortex, showing the neuronal elements and their connections. The *circular broken line* contains a cerebellar glomerulus. Climbing and mossy fibers represent excitatory input. Purkinje cell axons provide the sole output from the cerebellar cortex, which is inhibitory.

1. Molecular layer

- the outer cell-sparse layer that underlies the pia mater.
- contains dendritic arborizations of Purkinje cells and the parallel fibers of the granule cells.
- contains stellate (outer) cells and basket (inner stellate) cells.

2. Purkinje cell layer

- found between the molecular layer and the granule cell layer.

3. Granule cell layer

- found between the Purkinje cell layer and the cerebellar white matter.
- contains granule cells, Golgi cells, and cerebellar glomeruli.

B. Neurons and fibers of the cerebellum (Figure 19.3; see Figure 19.2)

1. Purkinje cell

- conveys the only output from the cerebellar cortex.
- projects inhibitory output (gamma-aminobutyric acid [GABA]) to the cerebellar and vestibular nuclei.
- excited by parallel and climbing fibers.
- inhibited (by GABA) by basket and stellate cells.

2. Granule cell

- excites (by glutamate) Purkinje, basket, stellate, and Golgi cells via parallel fibers.
- inhibited by Golgi cells.
- excited by mossy fibers.

3. Mossy fibers

- the afferent excitatory fibers of the **spinocerebellar and pontocerebellar tracts**.
- terminate as mossy fibers on granule cells.
- excite granule cells to discharge via their parallel fibers.

4. Climbing fibers

- the afferent excitatory fibers of the **olivocerebellar tract**.
- terminate on neurons of the cerebellar nuclei and on dendrites of Purkinje cells.

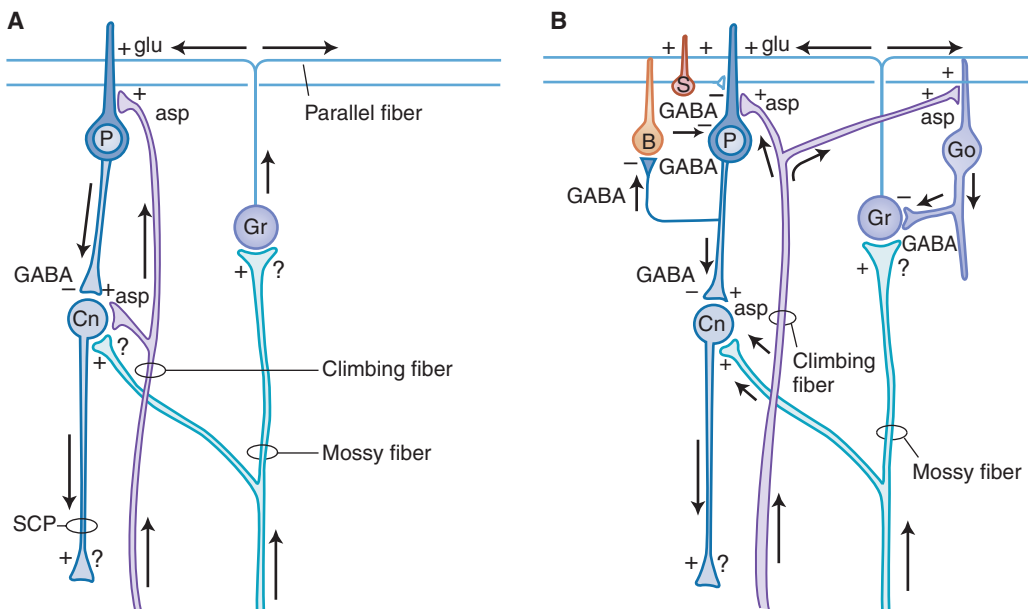


FIGURE 19.3. The basic connections of the cerebellar cortex. **(A)** The basic input and output circuit. **(B)** Connections of the inhibitory interneurons of the cerebellar cortex. *asp* = aspartate; *B* = basket cell; *Cn* = neuron of the cerebellar nuclei; *Gr* = granule cell; *GABA* = gamma-aminobutyric acid; *glu* = glutamate; *Go* = Golgi cell; *P* = Purkinje cell; *S* = stellate cell; *SCP* = superior cerebellar peduncle. Inhibitory neurons of the cerebellum use GABA. Glutamate is the transmitter for granule cells. Aspartate is thought to be the transmitter of the climbing fibers. Excitatory synapses are indicated by a plus sign (+); inhibitory synapses are indicated by a minus sign (-); the question mark (?) indicates that the neurotransmitter is not known.

IV. MAJOR CEREBELLAR PATHWAYS (FIGURE 19.4)

A. Vestibulocerebellar pathway

- plays a role in the maintenance of posture, balance, and the coordination of eye movements.
- receives its major input from the vestibular receptors of the kinetic and static labyrinths.
 1. **Semicircular ducts and otolith organs**
 - project to the flocculonodular lobe and the vestibular nuclei.
 2. **Flocculonodular lobe**
 - receives visual input from the superior colliculus and the striate cortex.
 - projects to the vestibular nuclei.
 3. **Vestibular nuclei**
 - project via the medial longitudinal fasciculi (MLFs) to the ocular motor nuclei of CN III, CN IV, and CN VI to coordinate eye movements.
 - project via the medial and lateral vestibulospinal tracts to the spinal cord to regulate neck and antigravity muscles, respectively.

B. Vermal spinocerebellar pathway

- maintains muscle tone and postural control over truncal (axial) and proximal (limb girdle) muscles.
 1. **Vermis**
 - receives spinocerebellar and labyrinthine input.
 - projects to the fastigial nucleus.

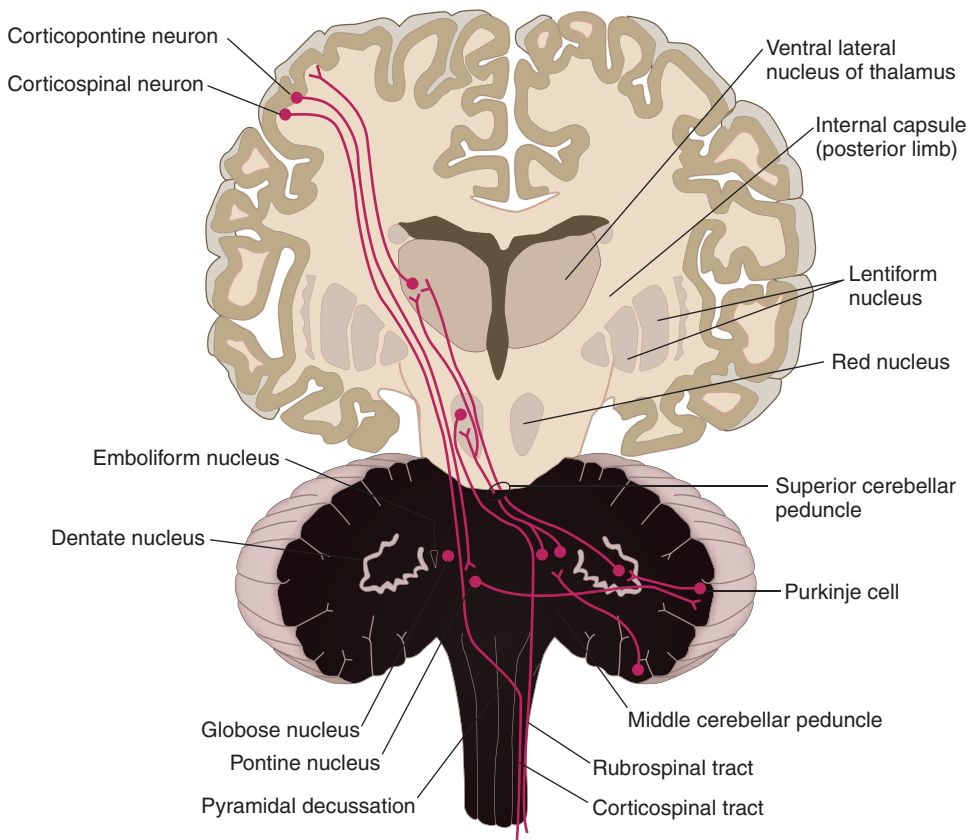


FIGURE 19.4. The principal cerebellar connections. The major efferent pathway is the dentatothalamocortical tract. The cerebellum receives input from the cerebral cortex through the corticopontocerebellar tract. (Modified from Fix JD. *High-Yield Neuroanatomy*. 3rd ed. Philadelphia, PA: Lippincott Williams & Wilkins; 2005:112.)

2. Fastigial nucleus

- has excitatory output.
- projects via the vestibular nuclei to the spinal cord.
- projects to the ventral lateral nucleus of the thalamus.

3. Ventral lateral nucleus of the thalamus

- receives input from the fastigial nucleus.
- projects to the trunk area of the precentral gyrus.

4. Precentral gyrus

- gives rise to the **anterior corticospinal tract**, which regulates muscle tone of the truncal and proximal muscles.

C. Paravermal spinocerebellar pathway

- maintains muscle tone and postural control over distal muscle groups.

1. Paravermis

- receives spinocerebellar input from distal muscles.
- projects to the interposed nuclei.

2. Interposed nuclei (emboliform and globose)

- have excitatory output.
- project to:
 - Ventral lateral nucleus**
 - projects to the extremities area of the precentral gyrus. The precentral gyrus gives rise to the **lateral corticospinal tract**, which regulates the distal muscle groups.
 - Red nucleus**
 - gives rise to the crossed **rubrospinal tract**, which mediates control over distal muscles.
 - receives input from the contralateral nucleus interpositus and bilateral input from the motor and premotor cortices.

D. Lateral hemispheric cerebellar pathway (see Figure 19.4)

- also called the **neocerebellar** or **pontocerebellar pathway**.
- regulates the initiation, planning, and timing of volitional motor activity.

1. Cerebellar hemisphere

- receives input from the contralateral motor and sensory cortex via the **corticopontocerebellar tract**.
- projects via Purkinje cell axons to the dentate nucleus.

2. Dentate nucleus

- has excitatory output.
- projects via the superior cerebellar peduncle to the contralateral red nucleus, ventral lateral nucleus of the thalamus, and the inferior olivary nucleus.

a. Red nucleus pathway

- The **red nucleus** projects to the inferior olivary nucleus.
- The **inferior olivary nucleus** projects via the contralateral inferior cerebellar peduncle to the cerebellum.

b. Ventral lateral nucleus pathway

- The **ventral lateral nucleus** of the thalamus projects to the motor (4) and premotor (6) cortices.
- The **motor and premotor cortices** give rise to the following tracts:

(1) Corticobulbar tract

- innervates cranial nerve nuclei.

(2) Lateral corticospinal tract

- regulates volitional synergistic motor activity.

(3) Corticopontocerebellar tracts

- regulate the output of the neocerebellum.

c. Inferior olivary nucleus pathway

- The inferior olivary nucleus **receives direct input from the dentate nucleus** via the crossed descending fibers of the superior cerebellar peduncle.
- The inferior olivary nucleus **projects directly to the dentate nucleus** via the contralateral inferior cerebellar peduncle.

V. CEREBELLAR DYSFUNCTION

- characterized by hypotonia, disequilibrium, and dyssynergia.

A. Hypotonia

- a loss of the resistance normally offered by muscles to palpation or to passive manipulation.
- results from the loss of cerebellar facilitation of the motor cortex via tonic firing of the cerebellar nuclei.
- results in a floppy, loose-jointed, rag-doll appearance with pendular reflexes; the patient appears inebriated.

B. Disequilibrium

- refers to loss of balance, characterized by gait and trunk dystaxia.

C. Dyssynergia

- a loss of coordinated muscle activity and includes the following:
 1. **Dysarthria**
 - slurred or scanning speech.
 2. **Dystaxia**
 - a lack of coordination in the execution of voluntary movement (e.g., gait, trunk, leg, and arm dystaxia).
 3. **Dysmetria**
 - the inability to arrest muscular movement at the desired point (past-pointing).
 4. **Intention tremor**
 - a type of dysmetria that occurs during a voluntary movement.
 5. **Dysidiadochokinesia**
 - the inability to perform rapid alternating movements (e.g., rapid supination and pronation of the hands).
 6. **Nystagmus**
 - a form of dystaxia consisting of to-and-fro eye movements (ocular dysmetria).
 7. **Decomposition of movement (by-the-numbers phenomenon)**
 - consists of breaking down a smooth muscle act into a number of jerky awkward component parts.
 8. **Rebound or lack of check**
 - results from the inability to adjust to changes in muscle tension.
 - caused by loss of the cerebellar component of the stretch reflex.
 - may be tested for by having the patient flex the forearm at the elbow against resistance; sudden release results in the forearm striking the patient's chest.

VI. CEREBELLAR LESIONS

A. Anterior vermis syndrome

- involves the lower limb region of the anterior lobe.
- results from atrophy of the rostral vermis—most commonly caused by alcohol abuse.
- results in gait, trunk, and leg dystaxia.

B. Posterior vermis syndrome

- involves the flocculonodular lobe.
- usually the result of brain tumors in children.
- most frequently caused by medulloblastomas or ependymomas.
- results in truncal dystaxia.

C. Hemispheric syndrome

- usually involves one cerebellar hemisphere.
- frequently the result of a brain tumor or an abscess.
- results in arm, leg, trunk, and gait dystaxia.
- results in cerebellar signs that are ipsilateral to the lesion.

D. Phenytoin (antiepileptic drug) intoxication

- may cause ataxia, nystagmus, gait disturbances, and dysarthric speech.

E. Tumors of the cerebellum

1. Astrocytomas

- constitute 30% of all brain tumors in children.
- occur most frequently in the cerebellar hemisphere.
- after a surgical removal, survival for many years is common.

2. Medulloblastomas

- malignant tumors that constitute 20% of all brain tumors in children.
- occur most frequently in the cerebellar vermis.
- thought to originate from the superficial granular layer of the cerebellar cortex.
- usually obstruct passage of cerebrospinal fluid (CSF) and cause hydrocephalus.
- often disseminate throughout the CSF tract.

3. Ependymomas

- constitute 10% of all brain tumors in children.
- the most common spinal cord tumors in all ages.
- occur most frequently in the fourth ventricle.
- usually obstruct passage of CSF and cause hydrocephalus.

F. Cerebellar atrophies

- inherited disorders.

1. Friedreich ataxia

- the most common hereditary ataxia, with an autosomal recessive mode of inheritance.
- involves the posterior columns, corticospinal tracts, spinocerebellar tracts, and dentate nuclei.
- has the same spinal cord pathology as **subacute combined degeneration** (see Chapter 8 VII G).
- frequently associated with chronic myocarditis.

2. Cerebello-olivary degeneration (Holmes disease)

- has an autosomal dominant mode of inheritance.
- results in a loss of Purkinje and granule cells, followed by a loss of neurons in the inferior olivary nuclei.
- results in gait ataxia, dysarthria, and intention tremor.

3. Olivopontocerebellar degeneration (Dejerine–Thomas syndrome)

- has an autosomal dominant mode of inheritance.
- results in a loss of Purkinje cells, neurons of the inferior olivary nucleus, and neurons in the pontine nuclei; results in demyelination of the posterior columns and the spino-cerebellar tracts.
- frequently results in a loss of neurons in the substantia nigra and basal nuclei.
- results in gait ataxia, dysarthria, and intention tremor; may show parkinsonian signs (rigidity and akinesia).

Review Test

1. A 30-year-old woman complains of unsteadiness while standing or walking. She tends to deviate to the right. Neurologic examination reveals the following signs: dysmetria on the right, dysdiadochokinesia, and a nystagmus that is more marked when she looks to the right side. The lesion is most likely found in the:

- (A) cerebellar hemisphere, left side.
- (B) cerebellar hemisphere, right side.
- (C) globus pallidus, left side.
- (D) medial medulla, left side.
- (E) medial medulla, right side.

2. To which of the following nuclei do the Purkinje cells of the cerebellum project the inhibitory axons?

- (A) Arcuate nucleus
- (B) Fastigial nucleus
- (C) Inferior olivary nucleus
- (D) Superior olivary nucleus
- (E) Ventral lateral nucleus

3. The most common cause of anterior vermis syndrome is _____.

- (A) alcohol abuse
- (B) an abscess
- (C) a tumor
- (D) lead intoxication
- (E) vascular occlusion

4. The most common cerebellar tumor in children is _____.

- (A) an astrocytoma
- (B) an ependymoma
- (C) glioblastoma multiforme

- (D) medulloblastoma
- (E) oligodendrocytoma

5. A tumor that is derived from the external granular layer of the cerebellar cortex is a(n) _____.

- (A) astrocytoma
- (B) chordoma
- (C) ependymoma
- (D) germinoma
- (E) medulloblastoma

6. A 10-year-old boy has a headache, early-morning vomiting, staggering gait, adiadochokinesia, finger-to-nose sign, heel-to-shin sign, bilateral Babinski signs, choked disk, abducent palsy, and scanning speech, as in "I DID not GIVE any TOYSTO my son for CHRISTmas." What is the most likely diagnosis?

- (A) Brown-Séquard syndrome
- (B) Olivopontocerebellar degeneration
- (C) Posterior vermis syndrome
- (D) Sturge-Weber syndrome
- (E) Tabes dorsalis

7. An 8-year-old girl is examined by a neurologist who finds the followings deficits: ataxia, marked sensory hypesthesias, kyphoscoliosis, pes cavus, myocarditis, and retinitis pigmentosa inherited as autosomal recessive trait. What is the name of this disease?

- (A) Amyotrophic lateral sclerosis
- (B) Brown-Séquard syndrome
- (C) Friedrich ataxia
- (D) Subacute combined degeneration
- (E) Werdnig-Hoffmann disease

Answers and Explanations

1-B. Dysmetria, dysidiadochokinesia, intention tremor, and nystagmus are classic cerebellar signs. In the finger-to-nose test, the patient past-points on the side of the lesion. The medial medulla has no cerebellar pathways. In contrast, the lateral medulla has cerebellar pathways; lesions result in cerebellar ataxia and could be misdiagnosed as a cerebellar hemispheric lesion. The globus pallidus is atrophied in Huntington's disease and in Wilson disease, and it is damaged bilaterally by carbon monoxide intoxication.

2-B. Purkinje cells project inhibitory axons to all cerebellar nuclei: fastigial, globose, emboliform, and dentate. In addition, they project to all vestibular nuclei: lateral, superior, medial, and inferior. The superior olivary nucleus is an auditory relay nucleus, and the inferior olivary nucleus is a cerebellar relay nucleus. The arcuate nucleus is an ectopic pontine nucleus that lies next to the pyramidal tract, and its function is unknown. The ventral lateral thalamic nucleus receives input from the dentate nucleus.

3-A. Anterior vermis syndrome is a result of chronic alcohol abuse. Patients have dystaxia of the lower limb and trunk. Posterior vermis syndrome involves the flocculonodular lobe; it is most frequently caused by an ependymoma or a medulloblastoma. Patients have truncal dystaxia. Hemispheric syndrome usually is the result of a tumor (astrocytoma) or abscess; patients have arm, leg, trunk, and gait dystaxia.

4-A. Astrocytomas (30%) are the most common cerebellar tumors in children, followed by medulloblastomas (20%) and ependymomas (10%).

5-E. Medulloblastomas are derived from the external granular layer of the cerebellar cortex. Medulloblastomas give rise to posterior vermis syndrome.

6-C. Posterior vermis syndrome is generally indicative of brain tumors in children, frequently a medulloblastoma. Symptoms include vomiting, morning headache, stumbling gait, frequent falls, diplopia, papilledema, and sixth nerve palsy. Tabes dorsalis is posterior column syndrome that results from untreated syphilis. Olivopontocerebellar degeneration has an autosomal dominant mode of inheritance and results in gait ataxia, dysarthria, intention tremor, and possibly parkinsonian signs (rigidity and akinesia). Sturge-Weber syndrome is neurocutaneous congenital disorder caused by an arteriovenous malformation in the telencephalon. Brown-Séquard syndrome is paralysis, ataxia, and loss of sensation as a result of a spinal cord hemisection.

7-C. Friedreich ataxia is the most common hereditary ataxia, with an autosomal recessive mode of inheritance. It is often associated with chronic myocarditis; other symptoms include muscle weakness, loss of coordination, vision impairment, hearing loss, slurred speech, and curvature of the spine (kyphoscoliosis). Friedreich ataxia has the same spinal cord pathology (posterior column syndrome) as subacute combined degeneration, which is caused by a vitamin B₁₂ deficiency. Symptoms include loss of tactile discrimination; loss of joint and vibratory sensation; stereoaesthesia; sensory dystaxia; paresthesias and pain; hyporeflexia or areflexia; urinary incontinence, constipation, and impotence; and Romberg sign. Subacute combined degeneration includes both sensory and motor deficits; amyotrophic lateral sclerosis is a pure motor syndrome; Werdnig-Hoffmann disease is a hereditary degenerative disease of infants that affects only lower motor neurons; and Brown-Séquard syndrome is paralysis, ataxia, and loss of sensation as a result of spinal cord hemisection (see Chapter 8).

Autonomous Nervous System

Objectives

- Differentiate between the sympathetic and parasympathetic nervous systems—include cell locations, neurotransmitters, and functions.
- Describe visceral afferents and their relationship to the motor fibers.
- Describe autonomic influence on the eye, heart, blood vessels, and bladder.

I. OVERVIEW

- a general visceral efferent (**GVE**) motor system that controls and regulates smooth muscle, cardiac muscle, and glands.
- has three divisions: the **sympathetic**, the **parasympathetic**, and the **enteric**.
- consists of two types of projection neurons: **preganglionic neurons** and **postganglionic neurons** (sympathetic ganglia have interneurons).
- general visceral afferent (GVA) fibers run with GVE fibers.
- all postganglionic sympathetic fibers in the head run on branches of CN V to their target.

II. DIVISIONS OF THE AUTONOMIC NERVOUS SYSTEM

A. Sympathetic division (Figure 20.1; Table 20.1)

- also called the **thoracolumbar** or **adrenergic system**.
- stimulates activities that are mobilized during emergency situations, the fight, fright, and flight responses, which include increased heart rate and force of contraction and increased blood pressure.
 1. **Preganglionic neurons** (see Figures 6.2 and 6.3)
 - located in the intermediolateral cell column (T1–L2).
 - project via anterior roots and white communicating rami to the sympathetic trunk or via splanchnic nerves to prevertebral (collateral) ganglia. They synapse at both locations with postganglionic neurons.
 2. **Postganglionic neurons** (see Figures 6.2 and 6.3)
 - located in the sympathetic trunk (paravertebral ganglia) and in prevertebral (collateral) ganglia.
 - in the sympathetic trunk, project via gray communicating rami to spinal nerves and innervate blood vessels, arrector pili muscles, and sweat glands.
 - in prevertebral ganglia, project to abdominal and pelvic viscera.

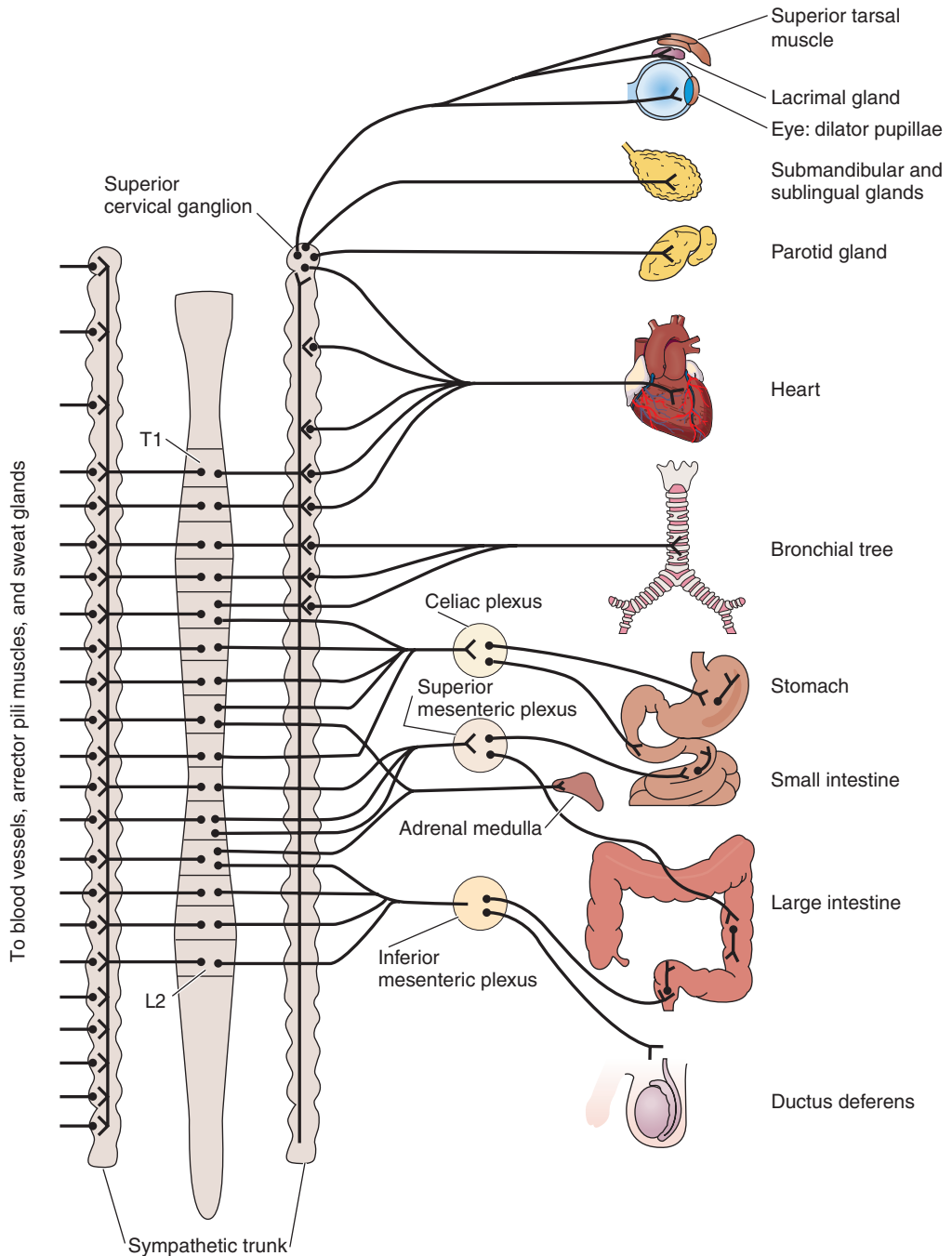


FIGURE 20.1. Schematic diagram showing the sympathetic (thoracolumbar) innervation of the ANS. The entire sympathetic innervation of the head is via the superior cervical ganglion. Gray communicating rami are found at all spinal cord levels, whereas white communicating rami are found only in spinal segments T1 to L2. ANS = autonomic nervous system. (Modified from Fix JD. *High-Yield Neuroanatomy*. 3rd ed. Philadelphia, PA: Lippincott Williams & Wilkins; 2005:128.)

table 20.1 Sympathetic and Parasympathetic Activity on Organ Systems

Structure	Sympathetic Function	Parasympathetic Function
Eye		
Radial muscle of iris (dilator pupillae)	Dilates pupil (mydriasis)	
Circular muscle of iris (sphincter pupillae)		Constricts pupil (miosis)
Ciliaris		Contracts for near vision (accommodation)
Lacrimal gland		Stimulates secretion
Salivary glands	Viscous secretion	Watery secretion
Sweat glands		
Thermoregulatory	Increases	
Apocrine (stress)	Increases	
Heart		
Sinoatrial node	Accelerates	Decelerates (vagal arrest)
Atrioventricular node	Increases conduction velocity	Decreases conduction velocity
Contractility	Increases	Decreases (atria)
Vascular smooth muscle		
Skin, splanchnic vessels	Contracts	
Skeletal muscle vessels	Relaxes	
Bronchiolar smooth muscle	Relaxes	Contracts
Gastrointestinal tract		
Smooth muscle		
Walls	Relaxes	Contracts
Sphincters	Contracts	Relaxes
Secretion and motility	Decreases	Increases
Genitourinary tract		
Smooth muscle		
Bladder wall	Little or no effect	Contracts
Sphincter	Contracts	Relaxes
Penis, seminal vesicles	Ejaculation	Erection
Adrenal medulla	Secretes epinephrine and norepinephrine	
Metabolic functions		
Liver	Gluconeogenesis and glycogenolysis	
Fat cells	Lipolysis	
Kidney	Renin release	

3. Interneurons

- called small intensely fluorescent (SIF) cells.
- located in sympathetic ganglia.
- dopaminergic and inhibitory.

4. Neurotransmitters

- **Acetylcholine (ACh)**
 - a. the neurotransmitter of **preganglionic neurons**.
- **Norepinephrine**
 - a. the neurotransmitter of **postganglionic sympathetic neurons**, with the exception of sweat glands and some blood vessels that receive cholinergic sympathetic innervation.
- **Epinephrine**
 - a. produced by the chromaffin cells of the adrenal medulla.

B. Parasympathetic division (Figure 20.2; see Table 20.1)

- called the **craniosacral** or **cholinergic system**.
- stimulates activities that conserve energy and restore body resources, including reduction of heart rate and increase in digestion and absorption of food.
- **uses ACh** as the neurotransmitter for both preganglionic and postganglionic synapses.

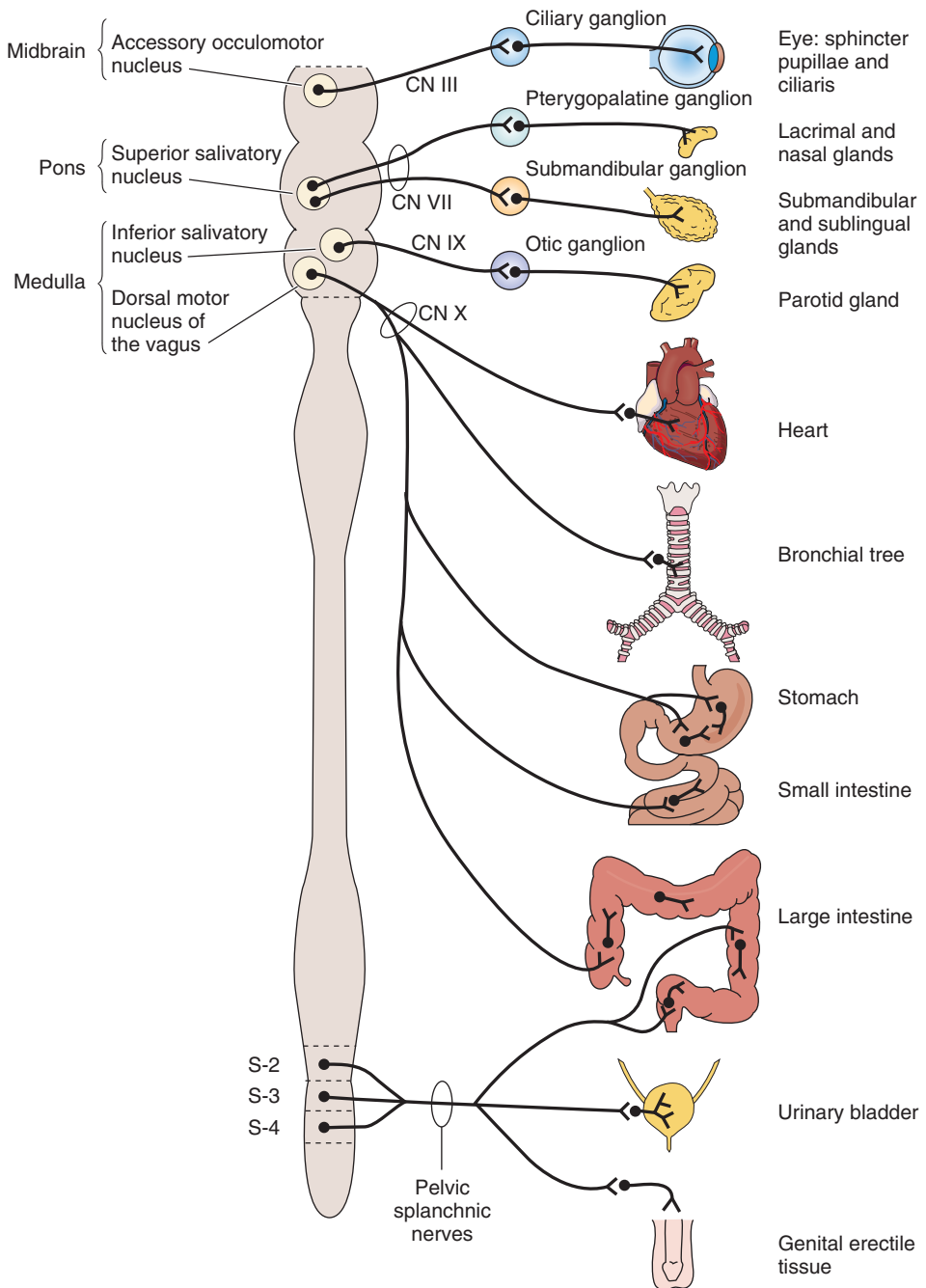


FIGURE 20.2. Schematic diagram showing the parasympathetic (craniosacral) innervation of the ANS. Sacral outflow includes segments S2–S4. Cranial outflow is mediated via four cranial nerves: CN III, CN VII, CN IX, and CN X. *ANS* = autonomic nervous system. (Modified from Fix JD. *High-Yield Neuroanatomy*. 3rd ed. Philadelphia, PA: Lippincott Williams & Wilkins; 2005:129.)

1. Cranial division

- associated with four cranial nerves.
 - a. **Oculomotor nerve (CN III)** (see IV A 2; Figure 16.4)
 - **accessory oculomotor nucleus**
 - (1) projects preganglionic fibers to ciliary ganglion.
 - **ciliary ganglion**
 - (1) projects postganglionic fibers to sphincter pupillae and ciliaris.
 - b. **Facial nerve (CN VII)** (see Figure 10.6)
 - **Superior salivatory nucleus**
 - (1) projects preganglionic fibers to the pterygopalatine and submandibular ganglia.
 - **Pterygopalatine ganglion**
 - (1) projects postganglionic fibers to the lacrimal gland and to the mucosa of the nasal cavity and palate.
 - **Submandibular ganglion**
 - (1) projects postganglionic fibers to the submandibular and sublingual glands.
 - c. **Glossopharyngeal nerve (CN IX)** (see Figure 9.5)
 - **Inferior salivatory nucleus**
 - (1) projects preganglionic fibers to the otic ganglion.
 - **Otic ganglion**
 - (1) projects postganglionic fibers to the parotid gland.
 - d. **Vagus nerve (CN X)** (see Figures 9.3 and 9.4)
 - **Dorsal motor nucleus**
 - (1) projects preganglionic fibers to intramural (terminal) ganglia within or adjacent to visceral organs.
 - **Intramural (terminal) ganglia**
 - (1) innervate, via short postganglionic fibers, viscera of the thorax and abdomen as far as the mid-transverse colon.
 - **Nucleus ambiguus**
 - (1) projects preganglionic fibers to the intramural ganglia of the heart (sinoatrial and atrioventricular nodes).

2. Sacral division

- originates from the sacral parasympathetic nucleus of sacral segments S2–S4.
- postganglionic neurons lie on, near, or in the wall of the innervated viscus.
- innervates via pelvic splanchnic nerves the lower abdomen and pelvic viscera, including the colon distal to the mid-transverse colon, urinary bladder, and genital viscera.
- involved with **micturition**, **defecation**, and **sexual function**.

C. Enteric division

- consists of intramural (enteric) ganglia and plexuses of the gastrointestinal tract, including the submucosal (Meissner's) plexus and the myenteric (Auerbach's) plexus.
- influenced by postganglionic adrenergic sympathetic input.
- influenced by preganglionic cholinergic parasympathetic input.
- functions independently when deprived of central nervous system (CNS) innervation.
- plays a major role in the control of **gastrointestinal motility**.

III. VISCERAL AFFERENT FIBERS AND PAIN

- All sympathetic and parasympathetic nerves contain both **GVA** and **GVE** fibers.

A. GVA fibers and innervated structures

1. GVA cell bodies

- found in spinal ganglia, inferior ganglia of the glossopharyngeal nerve (CN IX) and the vagus nerve (CN X), and the geniculate ganglion of the facial nerve (CN VII).

2. GVA pain fibers

- found in the white communicating rami.
- accompany nerves carrying sympathetic fibers.
- have their cell bodies in the spinal ganglia of the thoracolumbar region (T1–L2).

3. GVA reflex fibers

- accompany both sympathetic and parasympathetic fibers.
- terminate centrally in the solitary nucleus and mediate the gag reflex.

4. Carotid sinus

- a slight dilation of the common carotid artery at the bifurcation. It contains baroreceptors; when stimulated, the receptors cause bradycardia and a decrease in blood pressure.
- innervated by GVA fibers from CN IX.

5. Carotid body

- a small structure just above the bifurcation of the common carotid artery; it contains chemoreceptors that respond to carbon dioxide, oxygen, and pH levels.
- innervated by GVA fibers from CN IX and CN X.

B. Visceral pain

- results from the following conditions:

1. **Distension**
2. **Spasms or strong contractions**
3. **Mechanical stimulation**
4. **Myocardial ischemia**

C. Visceral somatic referred pain

- the false reference or localization of a painful visceral stimulus to a somatic dermatome of the same spinal cord segment.

IV. AUTONOMIC INNERVATION OF SELECTED ORGANS (SEE TABLE 20.1)

A. Eye**1. Sympathetic input**

- **Hypothalamic neurons** project to the intermediolateral cell column at T1 and T2, the ciliospinal center (of Budge).
- The **intermediolateral cell column** (T1–T2) projects preganglionic fibers via the sympathetic trunk to the superior cervical ganglion.
- The **superior cervical ganglion** projects postganglionic fibers via the internal carotid artery to the cavernous sinus.
- Pupillodilator fibers reach the dilator pupillae muscle of the iris via the superior orbital fissure and via the nasociliary and ciliary nerves (CN V; long and short). Some pupillodilator fibers accompany the caroticotympanic nerves prior to entering the orbit; this explains Horner syndrome (ptosis, enophthalmos, miosis, flushing, and hemihidrosis) with otitis media.
- Fibers to the superior tarsal muscle (of **Müller**) reach the upper eyelid via the **ophthalmic artery**.
- Interruption of sympathetic input to the eye at any level results in **Horner syndrome**.

2. Parasympathetic input (see Figure 16.4)

- The accessory oculomotor **nucleus** projects preganglionic fibers via the oculomotor nerve (CN III) to the ciliary ganglion.
- The **ciliary ganglion** projects postganglionic fibers via the short ciliary nerves (CN V₁) to the sphincter pupillae (which acts to constrict the pupil) and ciliaris (which affects lens shape in accommodation).
- **Postganglionic fibers** mediate the efferent limb of the pupillary light reflex.
- Interruption of the parasympathetic input results in **internal ophthalmoplegia** (a fixed [unresponsive] and dilated pupil) and cycloplegia (paralysis of accommodation).

B. Blood vessels

- receive their innervation from the **sympathetic** division of the ANS.
 1. **Arteries and arterioles**
 - Constriction of cutaneous and splanchnic blood vessels results from sympathetic stimulation of α -receptors.
 - Dilation of skeletal muscle arteries results from sympathetic stimulation of β -receptors.
 - Blood vessels are not affected by parasympathetic stimulation.
 2. **Large veins and venules**
 - only moderately innervated.
 3. **Cerebral blood vessels**
 - respond to circulating metabolites (carbon dioxide and oxygen).

C. Heart

1. **Sympathetic input**
 - The **intermediolateral cell column** (T1–T5) projects preganglionic fibers to the upper thoracic ganglia and to the three cervical ganglia of the sympathetic trunk.
 - The **rostral sympathetic trunk** projects postganglionic fibers via cardiac nerves to the ventricular and atrial walls and the pacemaker tissue.
 - **Stimulation of cardiac nerves** results in an increase in heart rate and in the force of cardiac contractility.
2. **Parasympathetic input**
 - The **nucleus ambiguus** of CN X projects preganglionic fibers via the vagus nerve to the intramural ganglia of the atria and the sinoatrial node.
 - **Postganglionic fibers** from the intramural ganglia innervate the heart.
 - **Vagal stimulation** lowers the strength and rate of cardiac contraction.

D. Bladder

- Control is predominantly parasympathetic.
 1. **Sympathetic input**
 - from T12 to L3 via the inferior mesenteric plexus and via the inferior hypogastric plexus to the detrusor and the internal sphincter.
 - damage to sympathetic fibers has no effect on bladder function.
 2. **Parasympathetic input**
 - from S2–S3 via the pelvic splanchnic nerves to the detrusor and the internal urethral sphincter.
 - stimulation results in emptying the bladder.
 - paralysis produces an atonic bladder, with no reflex or voluntary control.
 3. **Somatomotor input**
 - from S2 to S4 via the pudendal nerves to the external urethral sphincter.
 4. **Sensory input to spinal cord**
 - via hypogastric, pelvic, and pudendal nerves.
 - damage results in an atonic bladder with overflow incontinence.
 5. **Ascending pathway for bladder sensation**
 - controls the urge to void.
 - found with sacral fibers of the anterolateral system.
 - Transection results in loss of the urge to void and overflow incontinence.
 6. **Upper motor neuron (UMN) input**
 - controls volitional micturition.
 - from the paracentral lobule via the corticospinal tract (between the denticulate ligament and the lateral horn).
 - bilateral transection results in an uninhibited neurogenic bladder. Sensation is normal, but the patient has no control over voiding; the bladder fills and suddenly empties without cortical control.

V. CLINICAL CORRELATIONS

A. Megacolon (Hirschsprung disease)

- also called **congenital aganglionic megacolon**.
- characterized by extreme dilation and hypertrophy of the colon with fecal retention and by the absence of ganglion cells in the myenteric plexus.
- results from the **failure of neural crest cells to migrate into the colon**.

B. Familial dysautonomia (Riley–Day syndrome)

- an **autosomal recessive trait** characterized by abnormal sweating, blood pressure instability (orthostatic hypotension), difficulty in feeding owing to inadequate muscle tone in the gastrointestinal tract, and progressive sensory loss.
- results from a **loss of neurons in autonomic and sensory ganglia**.

C. Raynaud disease

- a painful disorder of the terminal arteries of the extremities.
- characterized by idiopathic paroxysmal bilateral cyanosis of the digits owing to arterial and arteriolar contraction caused by cold or emotion.
- may be treated by **preganglionic sympathectomy**.

D. Peptic ulcer

- results from **excessive production of hydrochloric acid** because of increased parasympathetic (tone) stimulation.

E. Botulism

- occurs when *Clostridium botulinum* toxin blocks the release of ACh from presynaptic vesicles in motor end plates and in synapses of autonomic ganglia.
- leads to paralysis of striated muscles.
- dry eyes and mouth and gastrointestinal ileus are the autonomic deficits.
- characterized by the absence of sensory impairment.

Review Test

1. Postganglionic sympathetic cholinergic fibers innervate the _____.

- (A) detrusor
- (B) ductus deferens
- (C) lacrimal gland
- (D) sweat glands
- (E) trigone of the urinary bladder

2. Which of the following ganglia does not contain postganglionic parasympathetic neurons?

- (A) Celiac
- (B) Ciliary
- (C) Otic
- (D) Pterygopalatine
- (E) Submandibular

3. Which one of the following deficits results from the destruction of the ciliary ganglion?

- (A) Loss of corneal reflex
- (B) Loss of direct pupillary reflex
- (C) Loss of lacrimation
- (D) Miosis
- (E) Severe ptosis

Questions 4 to 8

The response options for items 4 to 8 are the same. Select one answer for each item in the set.

- (A) Hirschsprung disease
- (B) Horner syndrome
- (C) Peptic ulcer disease
- (D) Raynaud disease
- (E) Riley-Day syndrome

Match each of the characteristics below with the condition it best describes.

4. Results from increased parasympathetic stimulation

5. Is a painful vasospastic disorder affecting the digits

6. Is an autosomal recessive trait characterized by abnormal sweating and blood pressure instability

7. Results from congenital absence of ganglion cells in the myenteric plexus

8. Consists of anisocoria and lack of sweating

Questions 9 to 14

The response options for items 9 to 14 are the same. Select one answer for each item in the set.

- (A) ACh
- (B) Dopamine
- (C) Nitric oxide
- (D) Norepinephrine
- (E) VIP

Match the characteristics below with the appropriate neurotransmitter.

9. Is a vasodilator

10. Is the neurotransmitter of the SIF cells

11. Innervates apocrine sweat glands

12. Innervates eccrine (merocrine) sweat glands

13. Is the transmitter responsible for penile erection

14. Is the neurotransmitter of the arrector pili

Answers and Explanations

1–D. Postganglionic sympathetic cholinergic fibers innervate the eccrine (merocrine) sweat glands and some blood vessels; blood vessels, however, are predominantly innervated by postganglionic sympathetic adrenergic fibers. Apocrine sweat glands of the axilla are innervated by adrenergic fibers; these glands secrete in response to mental stress.

2–A. The celiac ganglion is a sympathetic prevertebral (collateral) ganglion that contains postganglionic neurons.

3–B. Destruction of the ciliary ganglion interrupts postganglionic parasympathetic fibers, which innervate the sphincter pupillae and ciliaris; this results in loss of the direct pupillary reflex, mydriasis, and loss of accommodation. In addition, postganglionic sympathetic vasomotor fibers are interrupted, resulting in a hyperemic globe. Postganglionic sympathetic pupillodilator fibers reach the iris via the nasociliary and long ciliary nerves. Severe ptosis results from an oculomotor paralysis involving the fibers that innervate the levator palpebrae. Mild ptosis results from a lesion of the oculosympathetic fibers, which innervate the superior tarsal muscle (Horner syndrome).

4–C. Peptic ulcer disease results from increased parasympathetic tone.

5–D. Raynaud disease is a benign symmetric disease characterized by painful vasospasms affecting the digits.

6–E. Riley-Day syndrome—familial dysautonomia—is an autosomal recessive trait characterized by abnormal sweating and blood pressure instability.

7–A. Congenital aganglionic megacolon (Hirschsprung disease) results from failure of the neural crest cells to migrate into the wall of the distal colon (sigmoid colon and rectum) and form the myenteric plexus. It is characterized by extreme dilation and hypertrophy of the colon, with fecal retention.

8–B. Anisocoria (unequal pupils) and hemianhidrosis (lack of sweating on half of the face) are consistent with Horner syndrome, which also involves ptosis, miosis, and hemianhidrosis.

9–E. Vasoactive intestinal peptide (VIP) is a vasodilator found in postganglionic parasympathetic fibers, co-localized with ACh.

10–B. Dopamine is the neurotransmitter of the SIF cells.

11–D. Norepinephrine innervates apocrine sweat glands; these glands of the axilla and anal region respond to emotional stress.

12–A. ACh innervates eccrine (merocrine) sweat glands, which respond to heat stress.

13–C. Nitric oxide is the transmitter responsible for penile erection.

14–D. Norepinephrine is the neurotransmitter of the arrector pili.

Neurotransmitters and Pathways

Objectives

- List the various types of pathways as characterized by their neurotransmitter.
- Describe the major pathways, function, and characteristics of acetylcholine, dopamine, norepinephrine, serotonin, opioid and nonopioid peptides, and amino acids.
- Describe endogenous pain control pathways.

I. INTRODUCTION

A. Neurotransmitters

- substances released on excitation from presynaptic neurons. They produce the effects of nerve stimulation in postsynaptic neurons or in receptor cells.

B. Neurochemical pathways and loci

- can be classified based on the chemical composition of their neurotransmitters.
 1. **Monoaminergic pathways**
 - make use of **monoamines** as neurotransmitters; they contain one amine group. Monoamines include **dopamine**, **norepinephrine**, **epinephrine**, and **serotonin**.
 - a. **Catecholaminergic pathways**
 - make use of a monoamine that contains a catechol nucleus. Catecholamines include **dopamine**, **norepinephrine**, and **epinephrine**.
 - include dopaminergic, noradrenergic (norepinephrinergic), and adrenergic (epinephrinergic) pathways.
 - b. **Indolaminergic pathways**
 - make use of a monoamine that contains an indole nucleus. **Serotonin** is an indolamine.
 - include serotonergic pathways.
 2. **Cholinergic pathways**
 - make use of **acetylcholine** (ACh) as a neurotransmitter.
 3. **Peptidergic pathways**
 - make use of **peptides** as neurotransmitters.
 4. **Gamma-aminobutyric acid (GABA)–ergic pathways**
 - make use of **GABA** as a neurotransmitter.
 5. **Glutamatergic pathways**
 - make use of **glutamate** as a neurotransmitter.
 6. **Glycinergic pathways**
 - make use of **glycine** as a neurotransmitter.
 7. **L-Arginine–nitric oxide pathway**
 - makes use of the gaseous neurotransmitter **nitric oxide**. (Figure 21.1)

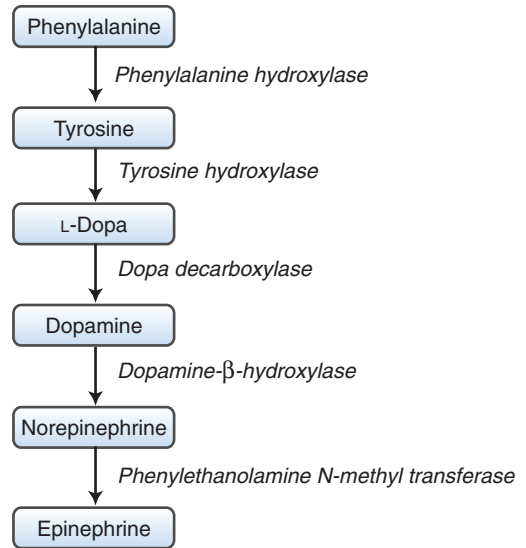


FIGURE 21.1. Synthesis of catecholamines from phenylalanine. Epinephrine, which is derived from norepinephrine, is found primarily in the adrenal medulla.

II. ACETYLCHOLINE

A. Characteristics

- can be identified indirectly by the marker choline acetyltransferase.
- the major neurotransmitter of the peripheral nervous system (PNS), neuromuscular junction, parasympathetic nervous system, preganglionic sympathetic fibers, and postganglionic sympathetic fibers to the sweat glands.
- found in neurons of the somatic and visceral motor nuclei in the brainstem and spinal cord.

B. Major cholinergic pathways (Figure 21.2)

Acetylcholine

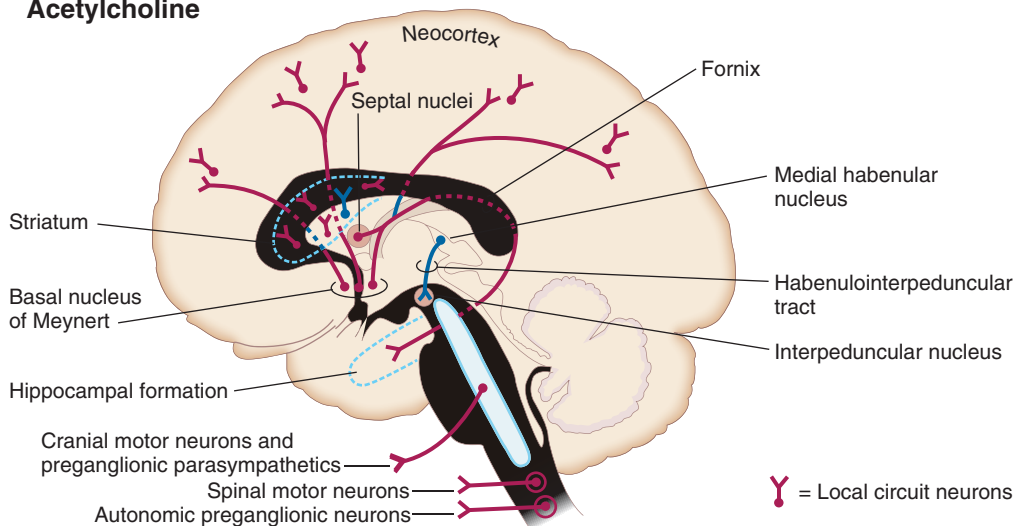


FIGURE 21.2. Distribution of ACh-containing neurons and their axonal projections. The basal nucleus of Meynert projects to the entire cortex; this nucleus degenerates in Alzheimer disease. Striatal ACh–local circuit neurons degenerate in Huntington chorea. ACh = acetylcholine.

1. Septal nuclei

- project via the fornix to the hippocampal formation.

2. Basal nucleus of Meynert

- located in the substantia innominata of the basal forebrain, between the globus pallidus and the anterior perforated substance.
- projects to the entire neocortex.
- receives input from the locus ceruleus, raphe nuclei, substantia nigra, amygdala, and orbitofrontal and temporal cortices.
- degenerates in **Alzheimer disease**.

3. Striatum

- contains ACh in its local circuit neurons.
- has cholinergic neurons that degenerate in **Huntington disease** and **Alzheimer disease**.

4. Neocortex

- contains ACh in its local circuit neurons.

III. DOPAMINE

A. Characteristics

- a **catecholamine**.
- can be identified by the marker tyrosine hydroxylase.
- plays a role in cognitive, motor, and neuroendocrine functions.
- **depleted in Parkinson disease**.
- has **increased production in schizophrenics**.

B. Major dopaminergic pathways (Figure 21.3)

1. Nigrostriatal pathway

- The substantia nigra projects to the striatum.
- Destruction of dopaminergic nigral neurons results in **parkinsonism**.

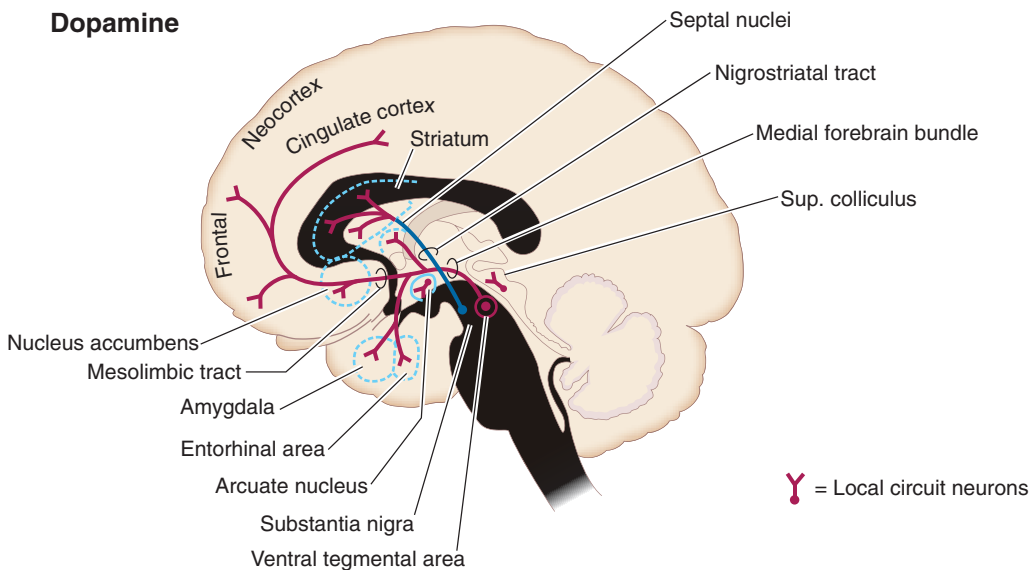


FIGURE 21.3. Distribution of dopamine-containing neurons and their projections. Two major ascending dopamine pathways arise in the midbrain: the nigrostriatal tract from the substantia nigra and the mesolimbic tract from the ventral tegmental area. In Parkinson disease, loss of dopaminergic neurons occurs in the substantia nigra and in the ventral tegmental area.

2. Mesolimbic pathway

- The ventral tegmental area projects to all cortical and subcortical structures of the limbic system.
- Linked to behavior and schizophrenia.

3. Tuberohypophyseal (tuberoinfundibular) pathway

- The arcuate nucleus of the hypothalamus projects to the portal vessels of the infundibulum.
- Released dopamine inhibits the release of **prolactin** from the adenohypophysis.

IV. NOREPINEPHRINE (NORADRENALIN)

A. Characteristics

- a catecholamine.
- can be localized by the marker dopamine β -hydroxylase.
- the transmitter of the postganglionic sympathetic neurons.
- may play a role in the genesis and maintenance of **mood**. The catecholamine hypothesis of mood disorders states that reduced norepinephrine activity is related to **depression** and that increased norepinephrine activity is related to **mania**.

B. Noradrenergic pathways (Figure 21.4)

1. Locus ceruleus

- contains the largest concentration of noradrenergic neurons in the central nervous system (CNS).
- located in the pons and midbrain.
- projects to all parts of the CNS.
- receives input from the cortex, limbic system, reticular formation, raphe nuclei, cerebellum, and spinal cord.

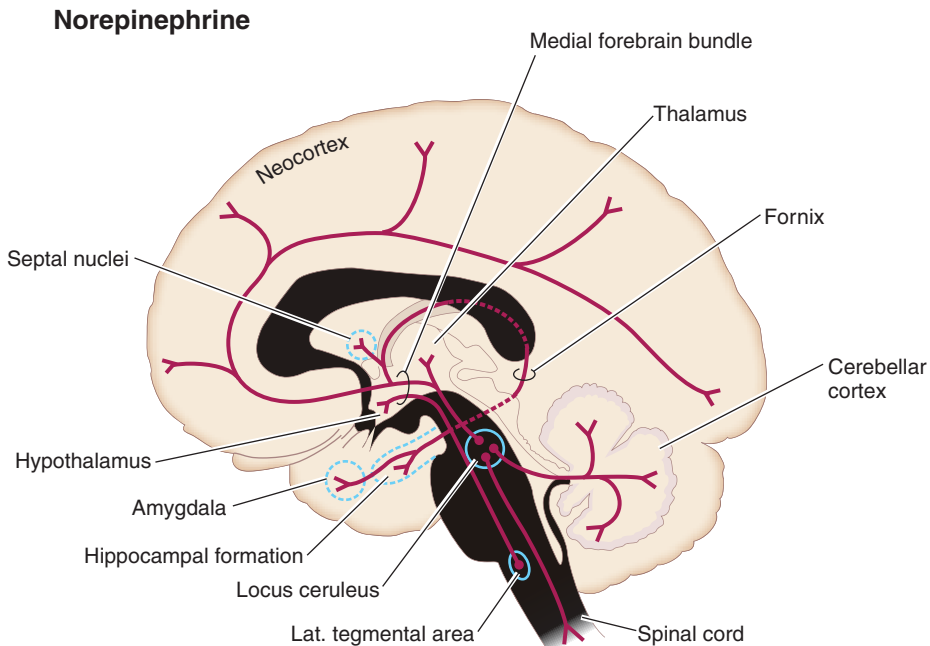


FIGURE 21.4. Distribution of norepinephrine-containing neurons and their projections. The locus ceruleus, located in the pons and midbrain, is the chief source of noradrenergic fibers. The locus ceruleus projects to all parts of the CNS. *CNS* = central nervous system.

- shows a significant loss of neurons in Alzheimer disease and Parkinson disease.
 - hypothesized to play a role in **anxiety** and **panic disorders**.
2. **Lateral tegmental area**
- located in the medulla and pons.
 - projects via the central tegmental tract and the medial forebrain bundle to the hypothalamus and thalamus.

V. SEROTONIN (5-HYDROXYTRYPTAMINE [5-HT])

A. Characteristics

- can be identified by the marker tryptophan hydroxylase.
- plays an important role in influencing arousal, sensory perception, emotion, and higher cognitive functions.
- the **permissive serotonin hypothesis** states that reduced 5-HT activity permits reduced levels of catecholamines to cause depression and elevated levels to cause mania.
- **severe depression** and **insomnia** are associated with low 5-HT levels, and **mania** is associated with high 5-HT activity. Dysfunction of 5-HT is believed to underlie obsessive-compulsive disorder.
- tricyclic antidepressants and fluoxetine increase 5-HT availability by reduction of its reuptake.

B. Major serotonergic pathways (Figure 21.5)

- 5-HT neurons are found only in the **raphe nuclei** of the brainstem. Raphe nuclei project diffusely to the entire CNS (see Figure 21.4).
1. **Raphe nuclei of the medulla**
 - project to the posterior horns of the spinal cord.
 2. **Raphe nuclei of the pons**
 - project to the spinal cord and cerebellum.
 3. **Raphe nuclei of the midbrain**
 - project to widespread areas of the diencephalon and the telencephalon, including the striatum.

Serotonin

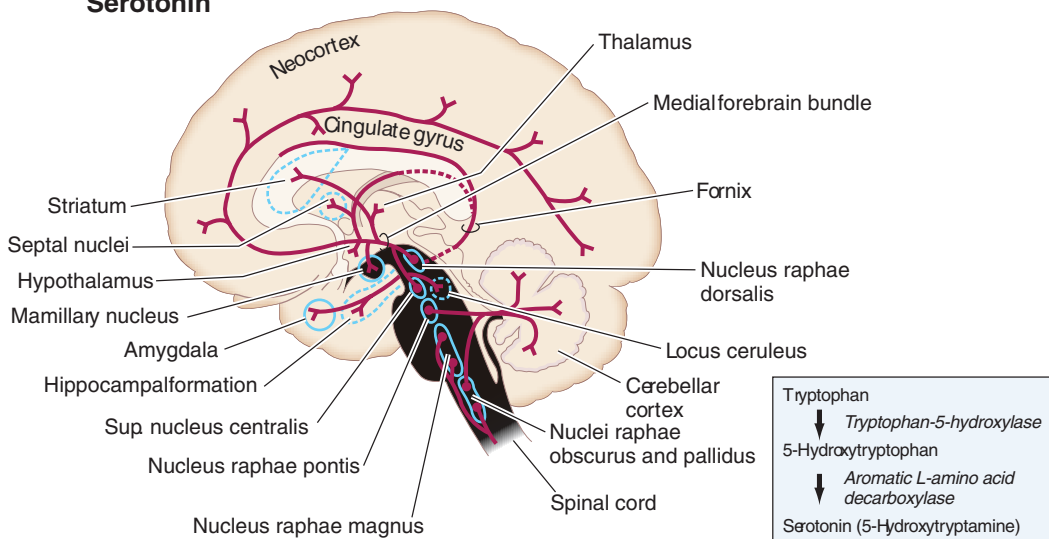


FIGURE 21.5. Distribution of 5-HT (serotonin)-containing neurons and their projections. Serotonin-containing neurons are found in nuclei of the raphe. They project widely to the forebrain, cerebellum, and spinal cord. The *inset* shows the synthetic pathway of serotonin.

C. Pineal gland (epiphysis cerebri)

- contains the highest concentration of 5-HT in the body.
- contains pinealocytes, which convert 5-HT to melatonin.

VI. OPIOID PEPTIDES

A. Endorphins (Figure 21.6)

- derived from **pro-opiomelanocortin** (POMC), the precursor of adrenocorticotrophic hormone (ACTH).
- include β -endorphin, the major endorphin found in the brain.
- appear to play a major role in **endocrine function**.
- Endorphinergic neurons are found almost exclusively in the **hypothalamus** (arcuate and pre-mamillary nuclei). These neurons project to the hypothalamus, amygdala, nucleus accumbens, septal area, thalamus, and locus ceruleus (midbrain and pons).

B. Enkephalins (Figure 21.7)

- derived from **proenkephalin**.
- the most widely distributed and abundant opioid peptides.
- found in highest concentrations in the **globus pallidus**.
- synthesized in striatal neurons, which project to the globus pallidus.
- located mainly in local circuits of the limbic and striatal systems.
- coexist with dopamine, norepinephrine, ACh, and GABA.
- play a role in **pain suppression** in the posterior horn of the spinal cord.

C. Dynorphins

- derived from **prodynorphin**.
- follow, in general, the distribution map for enkephalin.
- found in high concentrations in the **hypothalamus** and **amygdala**.

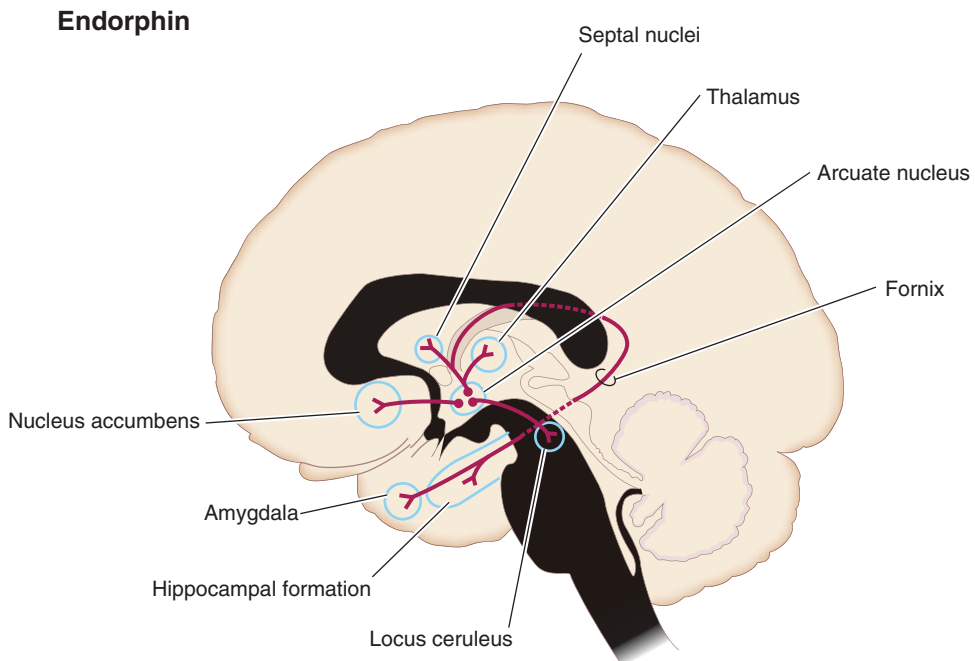


FIGURE 21.6. Distribution of endorphin-containing neurons and their projections. Endorphinergic neurons are found almost exclusively in the hypothalamus (arcuate nucleus).

Enkephalin

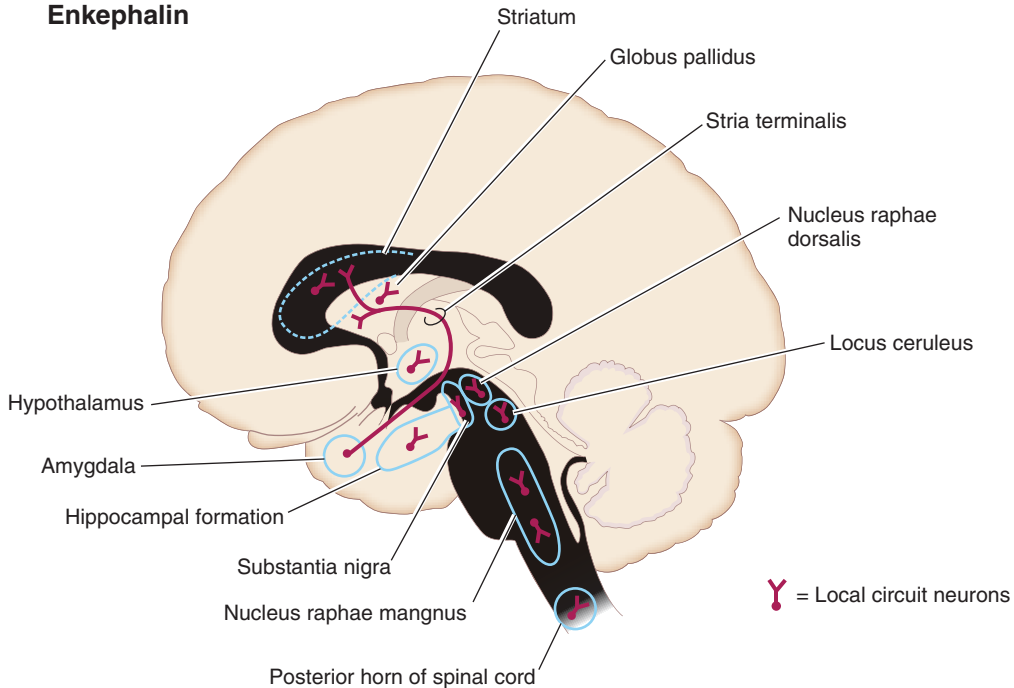


FIGURE 21.7. Distribution of enkephalin-containing neurons and their projections. They are found primarily in local circuits of the limbic and striatal systems. Enkephalinergic neurons of the brainstem and spinal cord play a role in pain suppression mechanisms.

VII. NONOPIOID NEUROPEPTIDES

A. Substance P (Figure 21.8)

- an excitatory neurotransmitter.
- found in spinal ganglion cells, which project to the substantia gelatinosa.
- plays a role in **pain transmission** (in A δ and C fibers).
- synthesized in striatal neurons, which project to the globus pallidus and the substantia nigra.
- found in highest concentration in the **substantia nigra** (striatonigral and pallidonigral tracts).

B. Somatostatin (Figure 21.9)

- also called somatotropin release-inhibiting factor.
- Somatostatinergic neurons are found in the anterior hypothalamus and in the preoptic region, striatum, amygdala, cerebral cortex, and in spinal ganglion cells. Somatostatinergic neurons from the anterior hypothalamus project their axons to the median eminence, where somatostatin enters the hypophyseal portal system and regulates the release of growth hormone (GH) and thyroid-stimulating hormone (TSH).
- The concentration of somatostatin in the neocortex and hippocampus is significantly reduced in **Alzheimer disease**.

VIII. AMINO ACIDS

- the major transmitters in the mammalian CNS.

A. Inhibitory amino acid transmitters

- aliphatic amino acids that have **one acidic and one amine function**.

Substance P

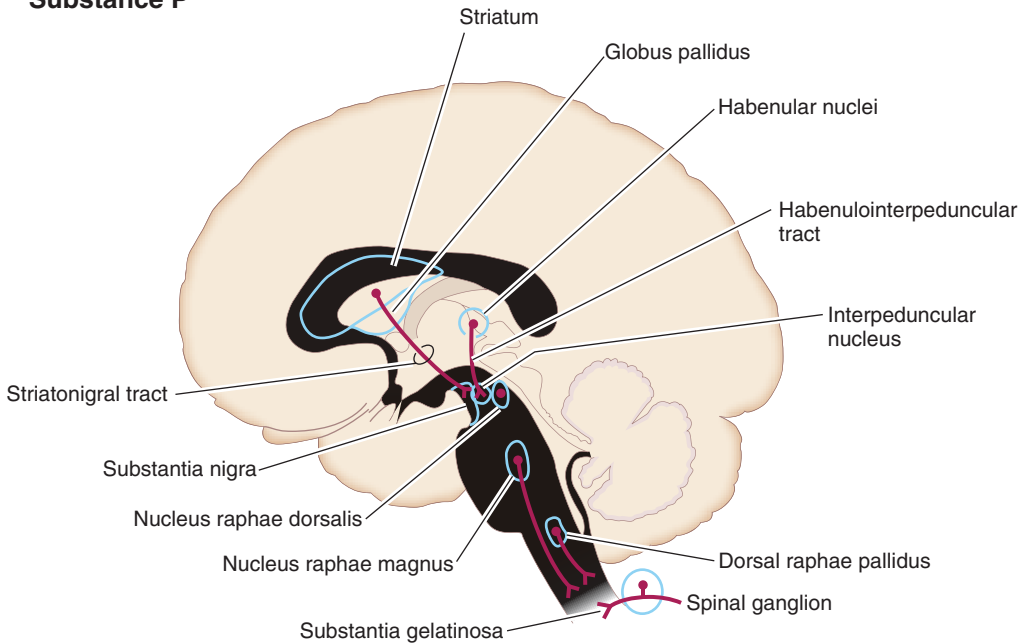


FIGURE 21.8. Distribution of substance P-containing neurons and their projections. Substance P is the neurotransmitter for nociceptive neurons of the spinal ganglia. Striatal substance P neurons project via the striatonigral tract to the substantia nigra.

1. GABA (Figure 21.10)

- can be localized by the marker glutamic acid decarboxylase.
- the major inhibitory neurotransmitter of the brain.
- coexists with substance P and with enkephalin.

Somatostatin

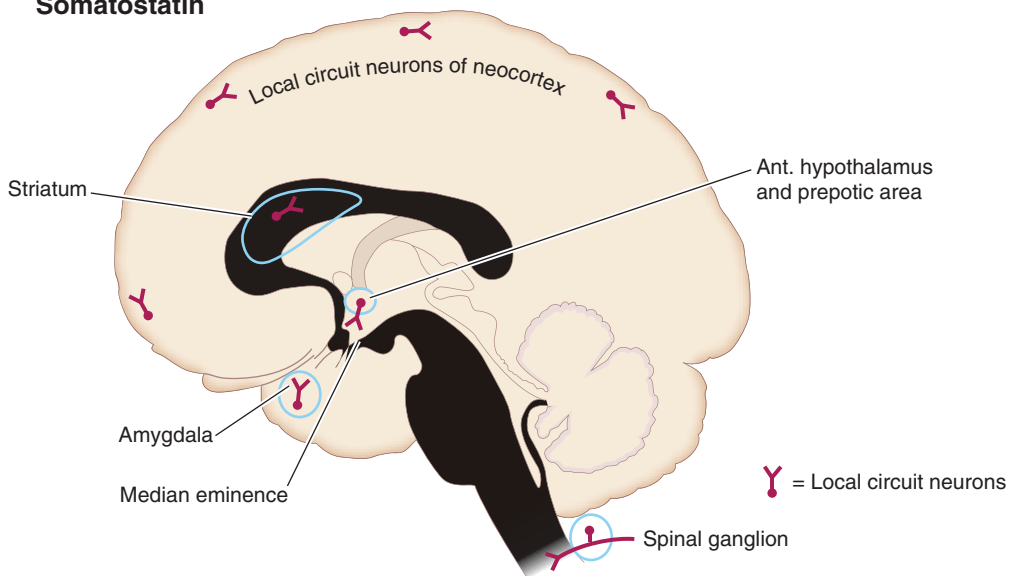


FIGURE 21.9. Distribution of somatostatin-containing neurons and their projections. Somatostatin is found primarily in the anterior hypothalamus and preoptic area. Somatostatinergic neurons project to the hypophyseal portal system and thus regulate the release of growth hormone.

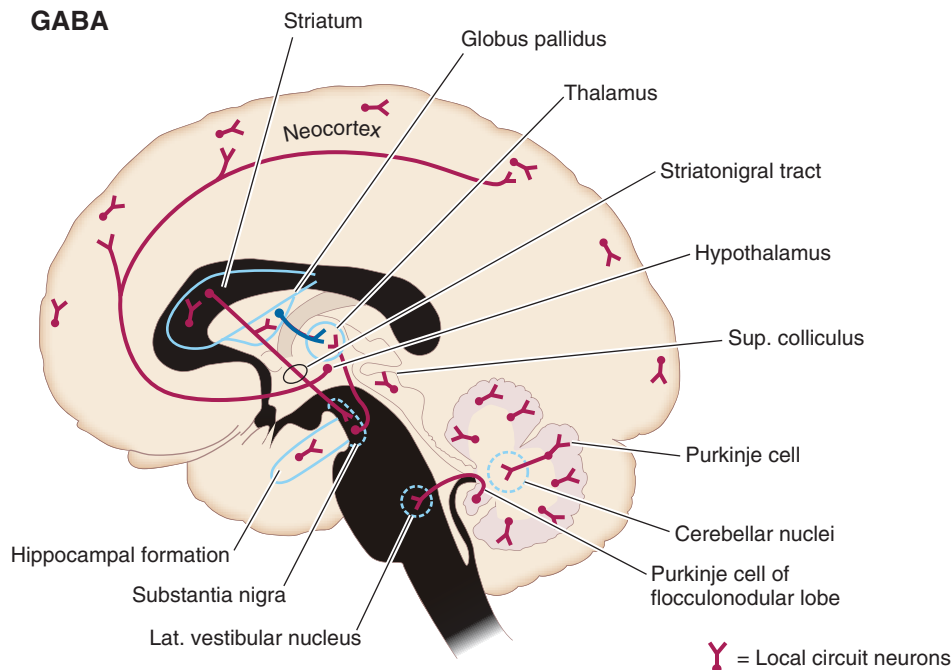


FIGURE 21.10. Distribution of GABA-containing neurons and their projections. GABA-ergic neurons are the major inhibitory cells of the CNS. GABA local circuit neurons are found in the neocortex, allocortex, and in the cerebellar cortex (Purkinje cells). Striatal GABA-ergic neurons project to the globus pallidus and the substantia nigra. Pallidal GABA-ergic neurons project to the thalamus and the subthalamic nucleus. *GABA* = gamma-aminobutyric acid.

- Purkinje, stellate, basket, and Golgi cells of the cerebellar cortex are GABA-ergic (see Figure 19.3).
- GABA-ergic striatal neurons project to the globus pallidus and the substantia nigra.
- GABA-ergic pallidal neurons project to the thalamus.
- GABA-ergic nigral neurons project to the thalamus.

2. Glycine

- the major inhibitory neurotransmitter of the spinal cord.
- used by the Renshaw cells of the spinal cord.
- its inhibitory action is blocked by strychnine.

B. Excitatory amino acid transmitters

- aliphatic amino acids that have two acidic functions and one alpha-amino group.

1. Glutamate (Figure 21.11)

- a major excitatory neurotransmitter of the brain; 60% of brain synapses are glutamatergic.
- the neurotransmitter of the cerebellar granule cell.
- used by the corticobulbar and corticospinal tracts.
- used by spinal ganglion cells.
- believed to be involved in long-term potentiation of hippocampal neurons via *N*-methyl-D-aspartate (NMDA) receptors.
- plays a role in kindling-induced seizures.
- plays a role in **pain transmission** (in A δ and C fibers).
- neocortical glutamatergic neurons project to the striatum, the subthalamic nucleus, and the thalamus. The subthalamic nucleus projects glutamatergic fibers to the globus pallidus.

2. Aspartate (see Figure 21.11)

- a major excitatory transmitter of the brain.
- the transmitter of the climbing fibers of the cerebellum.

Glutamate and Aspartate

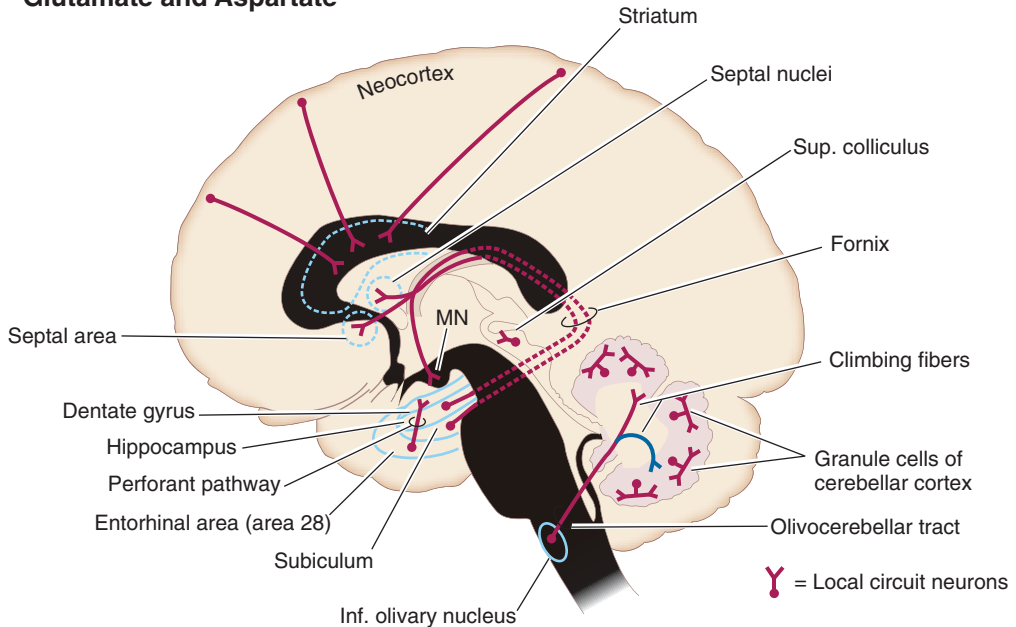


FIGURE 21.11. Distribution of glutamate- and aspartate-containing neurons and their projections. Glutamate is considered the major excitatory transmitter of the CNS. Cortical glutamatergic neurons project to the striatum; hippocampal and subicular glutamatergic neurons project via the fornix to the septal area and hypothalamus. Neurons of the inferior olivary nucleus project aspartatergic fibers to the cerebellum. The granule cells of the cerebellum are glutamatergic. *CNS* = central nervous system; *MN* = mammillary nucleus.

IX. NITRIC OXIDE

- a gaseous neurotransmitter that is produced when nitric oxide synthase converts arginine to citrulline with the formation of nitric oxide.
- located in the olfactory system, striatum, cortex, hippocampal formation, supraoptic nucleus of the hypothalamus, and cerebellum.
- responsible for the smooth muscle relaxation of the corpus cavernosum and thus penile erection.
- believed to play a role in memory formation (long-term potentiation in the hippocampal formation).

X. FUNCTIONAL AND CLINICAL CORRELATIONS

A. Endogenous pain control system

1. Ascending pathway

- Spinoreticular pain impulses project to the periaqueductal gray of the midbrain.

2. Descending raphe–spinal pathway

- Excitatory neurons of the periaqueductal gray project to the nucleus raphe magnus of the pons.
- Excitatory neurons of the nucleus raphe magnus project serotonergic fibers to enkephalinergic inhibitory neurons of the substantia gelatinosa.
- Enkephalinergic neurons of the substantia gelatinosa inhibit afferent pain fibers (substance P) and tract neurons that give rise to the spinoreticular and spinothalamic tracts.

3. Descending ceruleospinal pathway

- projects from the locus ceruleus to the spinal cord.
- thought to directly inhibit tract neurons that give rise to the ascending pain pathways.

B. Parkinson disease

- results from **degeneration of dopaminergic neurons** found in the pars compacta of the substantia nigra.
- results in **reduction of dopamine** in the striatum and in the substantia nigra.
- results in the formation of **Lewy bodies**, intraneuronal inclusions in the substantia nigra.

C. Huntington disease (Huntington chorea)

- results from **loss of ACh- and GABA-containing neurons** in the striatum (caudatoputamen).
- results in **loss of GABA** in the striatum and substantia nigra.

D. Alzheimer disease

- results from the **degeneration of cortical neurons** and **cholinergic neurons** found in the basal nucleus of Meynert.
- associated with a **60%–90% loss of choline acetyltransferase** in the cerebral cortex.
- characterized histologically by the presence of neurofibrillary tangles, senile (neuritic) plaques, granulovacuolar degeneration, and Hirano bodies.
- Senile plaques consist of degenerated nerve cell processes and a central core of amyloid β -protein.

E. Myasthenia gravis

- an autoimmune syndrome that occurs in the presence of antibodies to the nicotinic ACh receptor.
- caused by the action of antibodies that reduce the number of receptors in the neuromuscular junction resulting in **muscle paresis**.
- involves extraocular and eyelid muscles (e.g., in diplopia, ptosis).
- involves bulbar muscles (e.g., in nasal speech, jaw fatigue).
- leads to weaker limbs proximally and stronger limbs distally.
- may be diagnosed with intravenous edrophonium.
- may be effectively treated with thymectomy, followed by corticosteroid therapy.

F. Lambert–Eaton myasthenic syndrome

- caused by a presynaptic defect of ACh release.
- results in weakness in the limb muscles but not in the bulbar muscles. Muscle strength improves with use, unlike in myasthenia gravis, where muscle use results in fatigue.
- associated with neoplasms (e.g., lung, breast, prostate) in 50% of cases.
- leads to autonomic dysfunction, with dry mouth, constipation, impotence, and urinary incontinence.

Review Test

Questions 1 to 19

The response options for items 1 to 19 are the same. Select one answer for each item in the set.

- (A) ACh
- (B) Aspartate
- (C) β -Endorphin
- (D) Dopamine
- (E) Endorphin
- (F) Enkephalin
- (G) Epinephrine
- (H) GABA
- (I) Glutamate
- (J) Glycine
- (K) Nitric oxide
- (L) Norepinephrine
- (M) Serotonin
- (N) Somatostatin
- (O) Substance P

Match each of the statements with the neurotransmitter it best describes.

1. Its highest concentration is found in the pineal gland
2. Is found in pseudounipolar ganglion cells and in the substantia gelatinosa
3. Is responsible for the smooth muscle relaxation of the corpus cavernosum and thus penile erection
4. Is produced by neurons found in the locus ceruleus
5. Is the neurotransmitter of the corticostriatal pathway
6. Is produced by neurons of the raphe nuclei
7. Is the neurotransmitter of the climbing fibers of the cerebellum
8. Low levels are associated with severe depression and insomnia
9. Is produced by neurons found in the basal nucleus of Meynert

10. Is produced almost exclusively in the hypothalamus

11. A reduction of postsynaptic receptor sites for this neurotransmitter causes myasthenia gravis

12. Is the neurotransmitter of the Renshaw cells

13. Striatal levels of this neurotransmitter are reduced in Huntington disease

14. Is the neurotransmitter of the Purkinje cells

15. Is the neurotransmitter of the cerebellar granule cell

16. Is found in high concentration in the pars compacta of the substantia nigra and in the ventral tegmental area of the mesencephalon

17. Is the neurotransmitter of the mesolimbic pathway

18. Inhibits the release of prolactin from the adenohypophysis

19. Is the main neurotransmitter of the pallidothalamic and nigrothalamic tracts

Questions 20 to 24

The response options for items 20 to 24 are the same. Select one answer for each item in the set.

- (A) Alzheimer disease
- (B) Huntington disease
- (C) Lambert-Eaton myasthenic syndrome
- (D) Myasthenia gravis
- (E) Parkinson disease

Match each of the cases with the disorder it best describes.

20. A 60-year-old man presents with a resting tremor in his right upper extremity that has progressively worsened over the past 3 years. He recently had a positron emission tomography scan using a radioactive marker, which

showed a reduction of levodopa metabolism. This reduction was likely caused by dopaminergic neuronal death. What is the diagnosis for this patient?

21. A 25-year-old woman complains of difficulty swallowing and weakness in her hands and fingers. A blood test reveals antibodies to the nicotinic acetylcholine receptor. What is the diagnosis for this patient?

22. A brain autopsy of an 85-year-old woman reveals neurofibrillary tangles and neuritic plaques. What did this patient have?

23. A 53-year-old smoker complains of weakness in his arms and legs but notes that his muscle strength seems to improve when exercising. He also complains of dry mouth and constipation. A chest radiograph reveals a mass in the left lung. What is the diagnosis?

24. A 45-year-old man complains that he has been experiencing jerky, uncontrollable

movements. He reports having noticed similar symptoms for the past few years but notes that the symptoms seem to be getting worse. His family history reveals that his father had some of the same symptoms prior to his death in an automobile accident. The magnetic resonance imaging scan shows cell loss in the caudatoputamen. What is the diagnosis?

25. _____ is the major excitatory neurotransmitter in the brain.

- (A) Ach
- (B) Aspartate
- (C) GABA
- (D) Glutamate
- (E) Glycine

26. The major inhibitory neurotransmitter in the brain is _____.

- (A) GABA
- (B) Nitric oxide
- (C) Serotonin
- (D) Somatostatin
- (E) Substance P

Answers and Explanations

- 1–M.** The highest concentration of serotonin is found in the pineal body (epiphysis cerebri). Pinealocytes convert 5-HT to melatonin.
- 2–O.** Substance P is the neurotransmitter of pain fibers and is found in pseudounipolar ganglion cells and in the substantia gelatinosa of the spinal cord. Substance P is also found in the caudal spinal trigeminal tract.
- 3–K.** Nitric oxide is responsible for the smooth muscle relaxation of the corpus cavernosum and thus penile erection.
- 4–L.** The highest concentration of norepinephrine neurons is found in the locus ceruleus.
- 5–I.** Glutamate is the neurotransmitter of the corticostriatal pathway.
- 6–M.** Serotonin is produced by neurons of the raphe nuclei.
- 7–B.** Aspartate is the neurotransmitter of the climbing fibers of the cerebellum.
- 8–M.** Low levels of 5-HT are associated with severe depression and insomnia.
- 9–A.** ACh is found in highest concentration in the basal nucleus of Meynert, between the anterior perforated substance and the globus pallidus, a forebrain nucleus.
- 10–E.** Endorphin is produced almost exclusively in the hypothalamus (arcuate nucleus).
- 11–A.** In myasthenia gravis, there is a reduced acetylcholine receptor concentration in the motor end plate owing to an autoimmune reaction directed against the receptor proteins.
- 12–J.** Glycine is the major inhibitory neurotransmitter of the spinal cord; glycine is used by Renshaw cells, inhibitory interneurons driven by axon collaterals of lower motor neurons.
- 13–H.** Striatal levels of GABA are greatly reduced in Huntington disease. This attrition of GABA-ergic neurons in the head of the caudate nucleus results in hydrocephalus ex vacuo.
- 14–H.** GABA is the neurotransmitter of the Purkinje cells.
- 15–I.** Glutamate is the neurotransmitter of the cerebellar granule cells.
- 16–D.** Dopamine is found in high concentration in the pars compacta of the substantia nigra and in the ventral tegmental area of the mesencephalon.
- 17–D.** Dopamine is the neurotransmitter of the mesolimbic pathway. This pathway is linked to behavior and schizophrenia.
- 18–D.** Dopamine inhibits the release of prolactin from the adenohypophysis. Dopaminergic neurons are found in the arcuate nucleus of the hypothalamus.
- 19–H.** GABA, the most common inhibitory neurotransmitter of the brain, is the main neurotransmitter of the pallidothalamic and nigrothalamic tracts.
- 20–E.** Parkinson disease results from degeneration of dopaminergic neurons found in the pars compacta of the substantia nigra. Although Parkinson disease is typically diagnosed based on neurologic symptoms, a positron emission tomography scan with radioactive labeling can sometimes be used as a diagnostic tool.
- 21–D.** Myasthenia gravis is an autoimmune syndrome whose symptoms usually include the presence of antibodies to the nicotinic acetylcholine receptor. Other symptoms include muscle paresis, diplopia, ptosis, jaw fatigue, and weak proximal limbs.

22–A. Alzheimer disease is characterized histologically by the presence of neurofibrillary tangles, senile (neuritic) plaques, granulovacuolar degeneration, and Hirano bodies. This disease results from the degeneration of cortical neurons and cholinergic neurons found in the basal nucleus of Meynert. It is also associated with a 60%–90% loss of choline acetyltransferase in the cerebral cortex.

23–C. Lambert-Eaton myasthenic syndrome is an autoimmune syndrome caused by a presynaptic defect of ACh release. It results in weakness in limb muscles, and muscle strength improves with use. It is associated with neoplasms (e.g., lung, breast, prostate) in 50% of cases.

24–B. Huntington disease is a hereditary disorder that results from a loss of ACh- and GABA-containing neurons in the striatum. Some symptoms include jerky, random, uncontrollable, rapid (choreiform) movements; slowness of saccadic eye movements; and progressive dementia.

25–D. Glutamate is the major excitatory neurotransmitter; 60% of brain synapses are glutamatergic.

26–A. GABA is the major inhibitory neurotransmitter and can be localized by using glutamic acid decarboxylase as a marker.

Objectives

- Differentiate between neocortex and allocortex.
- List the six layers of neocortex and the characterizing feature of each.
- List the major functional areas of the cerebral cortex with their Brodmann areas, including sensory areas, motor areas, and higher association areas.
- Describe cortical dominance.
- Describe the blood flow to the major cortical areas.
- Define the various types of apraxia, aphasia, and dysprosodies.

I. OVERVIEW

- contains 20 billion (2×10^{10}) nerve cells.
- consists of the neocortex (90%) and the allocortex (10%).

A. Neocortex (isocortex; homogenetic cortex)

- a six-layered cortex.

B. Allocortex (heterogenetic cortex)

- three-layered and includes two types:
 1. Archicortex
 - includes the hippocampus and the dentate gyrus.
 2. Paleocortex
 - includes the olfactory cortex.

II. NEOCORTEX

- The six layers of neocortex are expressed as roman numerals I through VI:

A. Molecular layer (I)

- the superficial layer deep to the pia mater.

B. External granular layer (II)**C. External pyramidal layer (III)**

- gives rise to association and commissural fibers.

D. Internal granular layer (IV)

- receives thalamocortical fibers from the thalamic nuclei of the ventral tier (e.g., ventral posterolateral [VPL] and ventral posteromedial [VPM] nuclei).
- in the striate cortex (area 17), receives input from the lateral geniculate body.
- myelinated fibers of this layer form the stripe of Gennari—visible to the naked eye.

E. Internal pyramidal layer (V)

- gives rise to corticobulbar, corticospinal, and corticostriatal fibers.
- contains the giant cells of Betz that are found only in the motor cortex (area 4) of the precentral gyrus and the anterior paracentral lobule.

F. Multiiform layer (VI)

- the deepest layer of the cortex. It gives rise to projection, commissural, and association fibers.
- the major source of corticothalamic fibers.

III. FUNCTIONAL AREAS OF THE CEREBRAL CORTEX (FIGURE 22.1)

- divided into 47 cytoarchitectural areas, the **Brodmann areas**.

A. Sensory areas**1. Primary somatosensory cortex (areas 3, 1, and 2)**

- located in the **postcentral gyrus** and in the posterior part of the **paracentral lobule**.
- receives input from the ventral posterior nucleus.
- contributes to the corticospinal tract.
- somatotopically organized as the **sensory homunculus** (Figure 22.2A).
- stimulation results in contralateral numbness and tingling (paresthesia).
- destruction results in a contralateral loss of tactile discrimination (**hypesthesia** and **astereognosis**) and a loss of ability to localize sensation.

2. Secondary somatosensory cortex

- lies ventral to the primary somatosensory area along the superior bank of the lateral sulcus.

3. Somatosensory association cortex

- Superior parietal lobule (areas 5 and 7)
 - a. receives input from areas 3, 1, and 2. Area 7 receives visual input from area 19.
 - b. Destruction results in **contralateral losses of tactile discrimination, stereognosis** (the ability to recognize form), and **statognosis** (the ability to recognize the position of body parts in space). Destruction also leads to neglect of events occurring in the contralateral portion of the external world.
- Supramarginal gyrus (area 40)
 - a. interrelates somatosensory, auditory, and visual input (multimodal sensory stimuli).
 - b. Destruction in the dominant hemisphere may result in the following deficits:
 - Ideomotor or “classic” apraxia
 - (1) the inability to button one’s clothes or comb one’s hair when asked.
 - (2) the inability to manipulate tools, with retention of the ability to explain their use.
 - Ideational or sensory apraxia
 - (1) characterized by the inability to formulate the ideational plan for executing the several components of a complex multistep act (e.g., performing the steps of tying a shoe when asked to do so).
 - (2) occurs most frequently in diffuse cerebral degenerating disease, Alzheimer disease, and multi-infarct dementia.

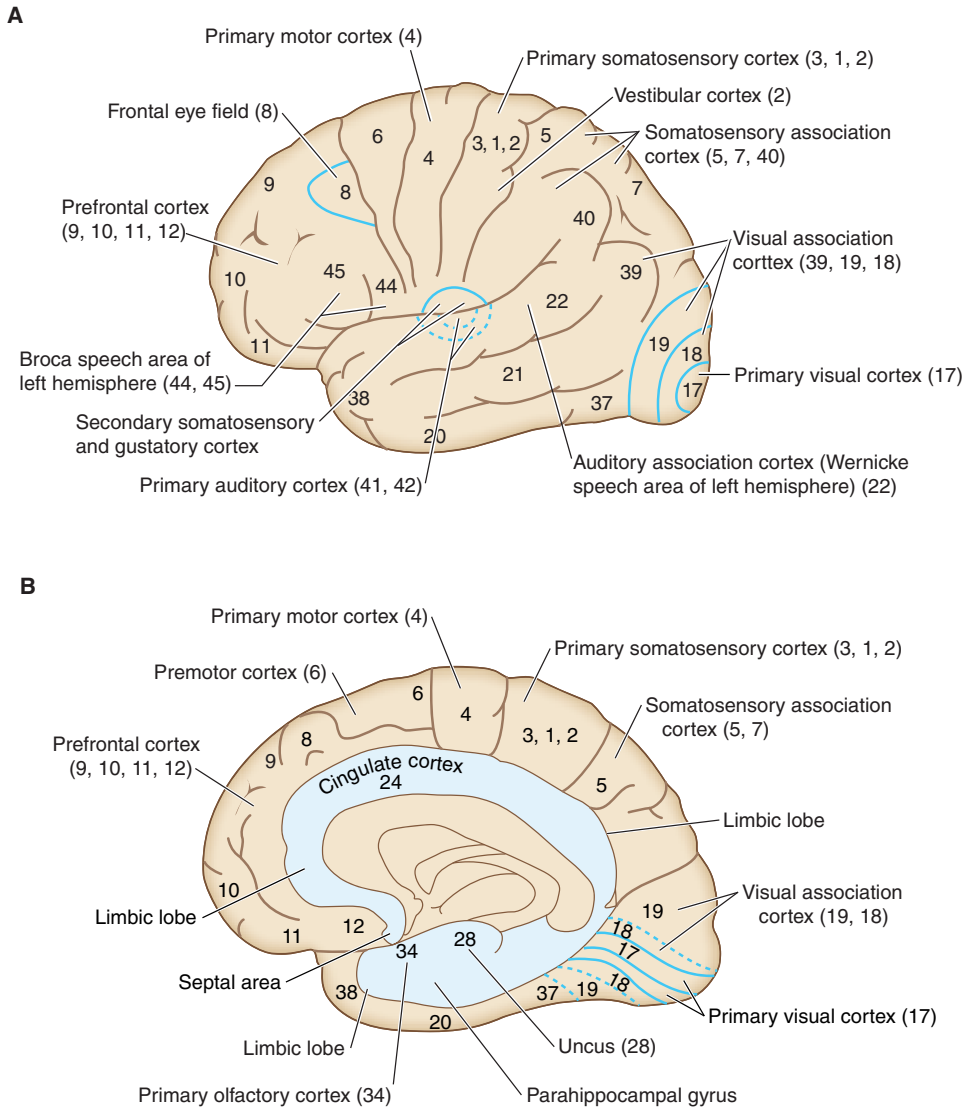


FIGURE 22.1. Some motor and sensory areas of the cerebral cortex. **(A)** Lateral surface of the hemisphere. **(B)** Medial surface of the hemisphere. The numbers refer to the Brodmann areas.

- **Facial apraxia**
(1) the inability to perform facial-oral movements on command (i.e., lick the lips); the most common apraxia.
- **Conduction aphasia**
(1) associated with poor repetition of spoken language (results from interruption of the arcuate fasciculus; see III C 4).

4. Primary visual cortex (area 17)

- located in the occipital lobe in both banks of the calcarine sulcus.
- receives input from the lateral geniculate body.
- destruction results in **visual field deficits** (e.g., contralateral homonymous hemianopia) (see Figure 16.2).

5. Secondary and tertiary visual cortices

- include areas 18 and 19 of the occipital lobe.
- lesions may result in **visual hallucinations**.

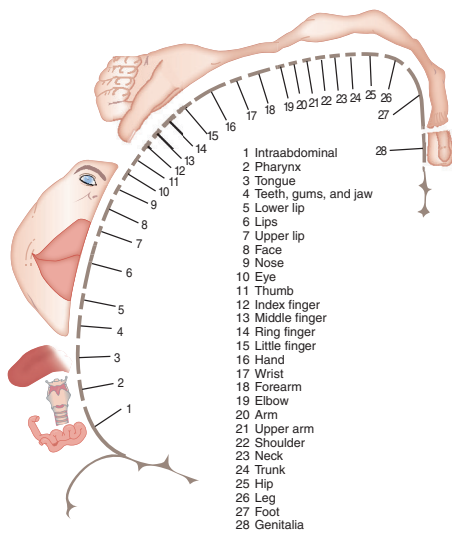
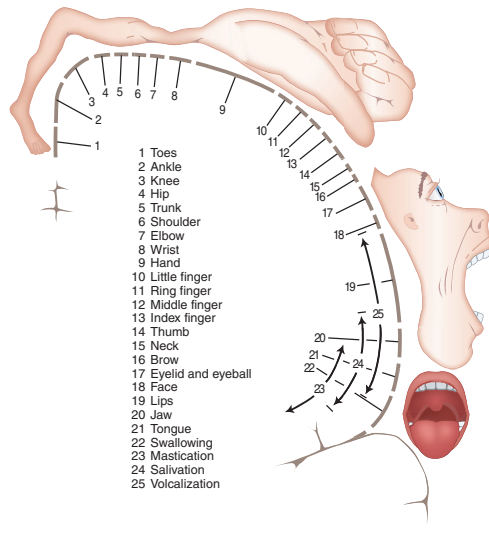
A Sensory Homunculus**B** Motor Homunculus

FIGURE 22.2. The sensory and motor homunculi. **(A)** Sensory representation in the postcentral gyrus. **(B)** Motor representation in the precentral gyrus. (Modified from Penfield W and Rasmussen T. *The Cerebral Cortex of Man*. New York, NY: Hafner Publishing; 1968: 44, 57.)

6. Visual association cortex (angular gyrus [area 39])

- Receives input from areas 18 and 19.
- Destruction of the underlying visual radiation results in **contralateral homonymous hemianopia** or **lower quadrantanopia**.
- Destruction in the dominant hemisphere results in **Gerstmann syndrome** with the following deficits:
 - a. Right-left confusion
 - b. Finger agnosia (inability to recognize, name, or select one's own or another's fingers)
 - c. Agraphia (inability to express thoughts in writing with possible retention of the ability to copy written or printed words; often coexists with alexia)
 - d. Dyscalculia (difficulty with arithmetic)

7. Primary auditory cortex (areas 41 and 42)

- located in the superior temporal gyrus.
- receives input from the medial geniculate body.
- unilateral destruction results in only **partial deafness** (owing to bilateral cochlear representation).

8. Auditory association cortex (area 22)

- located in the posterior part of the superior temporal gyrus.
- includes **Wernicke speech area**.
- includes the **planum temporale** (part of Wernicke speech area), which is larger in the dominant hemisphere.
- Lesion in the dominant hemisphere results in **Wernicke sensory aphasia**.
- Lesion in the nondominant hemisphere results in **sensory dysprosody** (inability to perceive the pitch or rhythm of speech).

9. Gustatory cortex (area 43)

- located in the parietal operculum and parainsular cortex.
- receives taste input from the VPM nucleus of the thalamus.

10. Vestibular cortex (area 2)

- located in the postcentral gyrus.
- receives input from the ventral posteroinferior (VPI) and the VPL nuclei of the thalamus.

B. Motor areas

1. Primary motor cortex (area 4)

- located in the **precentral gyrus** and in the anterior part of the **paracentral lobule**.
- contributes to the corticospinal tract.
- somatotopically organized as the **motor homunculus** (see Figure 22.2B).
- contains the giant cells of Betz in layer V.
- stimulation results in contralateral movements of voluntary muscles, especially distal muscles of the limbs.
- ablation results in a **contralateral upper motor neuron (UMN) lesion**.
- bilateral lesions of the paracentral lobule (e.g., parasagittal meningiomas) result in **urinary incontinence**.

2. Premotor cortex (area 6)

- located anterior to the precentral gyrus.
- contributes to the corticospinal tract.
- plays a role in the **control of proximal and axial muscles**; it prepares the motor cortex for specific movements in advance of their execution.
- stimulation results in adversive movements of the head and trunk and flexion and extension of the limbs.
- lesions in the dominant hemisphere may cause **sympathetic apraxia** (motor apraxia in the left hand).

3. Supplementary motor cortex (area 6)

- located on the medial surface of the hemisphere anterior to the paracentral lobule.
- contributes to the corticospinal tract.
- plays a role in **programming complex motor sequences** and in **coordinating bilateral movements**; it regulates the somatosensory input into the motor cortex.
- stimulation results in vocalization with associated facial movements and coordinated movements of the limbs.
- ablation in human subjects has resulted in transient **speech deficits** or **aphasias**.
- bilateral lesions result in **hypertonus of the flexor muscles** but no paralysis.

4. Frontal eye field (area 8)

- located in the posterior part of the middle frontal gyrus.
- projects via the corticotectobulbar tract to the contralateral lateral gaze center of the pons (abducent nucleus).
- stimulation (irritative lesion) results in conjugate deviation of the eyes to the opposite side.
- destructive lesions result in **conjugate deviation of the eyes toward the side of the lesion**.

C. Areas of higher cortical function

1. Prefrontal cortex (areas 9–12)

- Characteristics of the prefrontal cortex
 - a. extends from area 6 to the frontal pole (area 10).
 - b. has reciprocal connections with the dorsomedial nucleus of the thalamus.
- Frontal lobe syndrome (Phineas Gage syndrome)
 - a. results from lesions of the prefrontal cortex.
 - b. results in the following signs:
 - Inappropriate social behavior
 - (1) Lesions usually involve the fronto-orbital prefrontal cortex.
 - Difficulty in adaptation and loss of initiative
 - (1) Lesions involve the dorsolateral prefrontal cortex.
 - Sucking, groping, and grasping reflexes
 - Gait apraxia, incontinence, abulia (loss of the ability to perform voluntary actions), or akinetic mutism (a coma-like state called coma vigil)
 - (1) These signs result from bilateral disease.

2. Broca speech area (areas 44 and 45) (Figure 22.3)

- Characteristics of the Broca speech area
 - a. located in the posterior part of the inferior frontal gyrus in the dominant hemisphere.
 - b. connected to Wernicke speech area by the arcuate fasciculus.

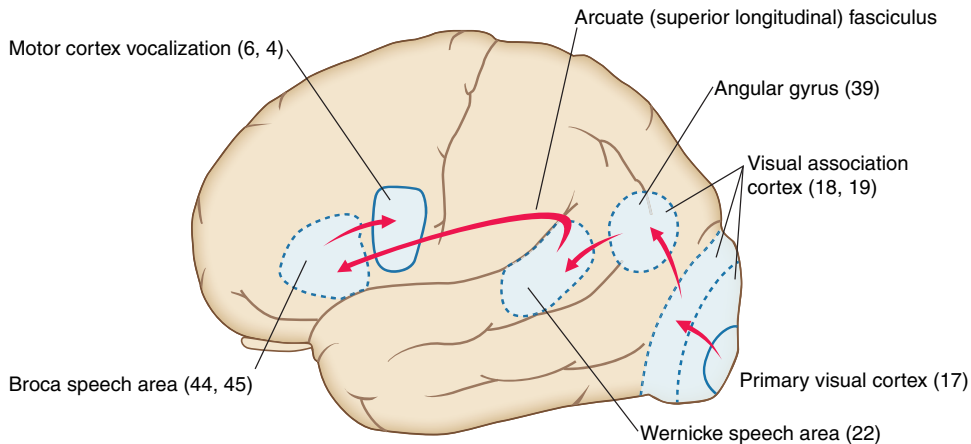


FIGURE 22.3. Cortical areas of the dominant hemisphere that play an important role in language production. The visual image of a word is projected from the visual cortex (area 17) to the visual association cortices (areas 18 and 19) and then to the angular gyrus (area 39). Further processing occurs in Wernicke speech area (area 22), where the auditory form of the word is recalled. Via the arcuate fasciculus, this information reaches Broca speech area (areas 44 and 45), where motor speech programs control the vocalization mechanisms of the precentral gyrus. Lesions of Broca speech area, Wernicke speech area, or the arcuate fasciculus result in dysphasias.

- Broca aphasia
 - a. results from lesions in Broca speech area.
 - b. also called **motor, expressive, nonfluent**, or **anterior aphasia**.
 - c. causes patients to speak slowly (nonfluent) and with effort; however, they have good comprehension of spoken and written language.
 - d. frequently accompanied by **contralateral weakness of the lower face and arm** and a **sympathetic apraxia** of the left hand (the inability to write with the nonparalyzed hand).
- 3. **Wernicke speech area (area 22)** (see Figure 22.3)
 - Characteristics of the Wernicke speech area
 - a. located in the posterior part of the superior temporal gyrus in the dominant hemisphere.
 - b. connected to Broca speech area by the arcuate fasciculus.
 - Wernicke aphasia
 - a. results from lesions in the dominant hemisphere.
 - b. also called **sensory, receptive, fluent**, or **posterior aphasia**.
 - c. Patients have poor comprehension of speech, speak faster than normal, and have difficulty in finding the right words to express themselves. They appear unaware of the deficit.
- 4. **Arcuate fasciculus**
 - Characteristics of the arcuate fasciculus
 - a. underlies the supramarginal gyrus (area 40) and the frontoparietal operculum.
 - b. connects the audiovisual association areas (areas 22, 39, and 40) with Broca speech area (areas 44 and 45).
 - Conduction aphasia
 - a. results from transection of the arcuate fasciculus.
 - b. a **fluent aphasia** associated with poor repetition of spoken language. Speech comprehension and expression are relatively good.
 - c. **Paraphrasic errors** (using incorrect words) are common, and **object naming is impaired** (nominal aphasia or amnesic aphasia). Patients are aware of the deficit.
- 5. **Corpus callosum**
 - interconnects corresponding hemispheric areas.
 - does not contain commissural fibers from the hand region of the motor or sensory strips, or from the striate cortex.

- receives its blood supply from the anterior cerebral artery and the posterior cerebral artery; the splenium is perfused by the posterior cerebral artery.
- damage to the splenium results in left hemidyslexia.

IV. CEREBRAL DOMINANCE

A. Dominant hemisphere

- responsible for propositional language consisting of grammar, syntax, and semantics.
- also responsible for speech and calculation.
- the left hemisphere is dominant in 95% of cases.
 1. Lesions of the dominant superior parietal lobule (Figure 22.4A)
 - result in contralateral loss of sensory discrimination (**astereognosis**; i.e., loss of posterior column modalities; area 5).
 - result in contralateral neglect (area 7).
 2. Lesions of the dominant inferior parietal lobule (see Figure 22.4A)
 - involve the supramarginal and angular gyri (areas 40 and 39).
 - result in the following conditions:
 - a. Receptive aphasia
 - b. Gerstmann syndrome
 - c. Alexia with agraphia (often coexists with Gerstmann syndrome)
 - d. Tactile agnosia
 - e. Ideomotor apraxia
 - f. Ideational apraxia

B. Nondominant hemisphere

- primarily responsible for **three-dimensional** or **spatial perception** and **nonverbal ideation** (music and poetry).
 1. **Lesions of the nondominant superior parietal lobule** (see Figure 22.4B)
 - result in **contralateral loss of sensory discrimination** (i.e., loss of posterior column modalities; area 5).
 - result in **contralateral neglect** (area 7).
 2. **Lesions of the nondominant inferior parietal lobule**
 - involve the supramarginal and angular gyri.
 - result in the following conditions:
 - a. Left-sided hemineglect
 - results in a lack of awareness of the left half of space or the left half of the body.
 - results in hemi-inattention or extinction.
 - b. Topographic memory loss
 - results in the inability to negotiate familiar surroundings.
 - c. Anosognosia (denial of deficit)
 - results in indifference to the causal disease (e.g., hemiparesis or hemianopia).
 - d. Constructional apraxia
 - results in the inability to draw simple designs (e.g., cross, star, or clock); the left side of the design is omitted.
 - may also occur in lesions of the dominant hemisphere.
 - e. Dressing apraxia
 - results in the inability to dress oneself.
 3. **Lesions of the nondominant inferior frontal gyrus (areas 44 and 45)**
 - correspond to Broca speech area and result in **expressive dysprosody** (the inability to articulate the pitch and rhythm of speech).
 4. **Lesions of the nondominant superior temporal gyrus (area 22)**
 - correspond to Wernicke speech area and result in **receptive dysprosody** (the inability to perceive pitch and rhythm of speech).

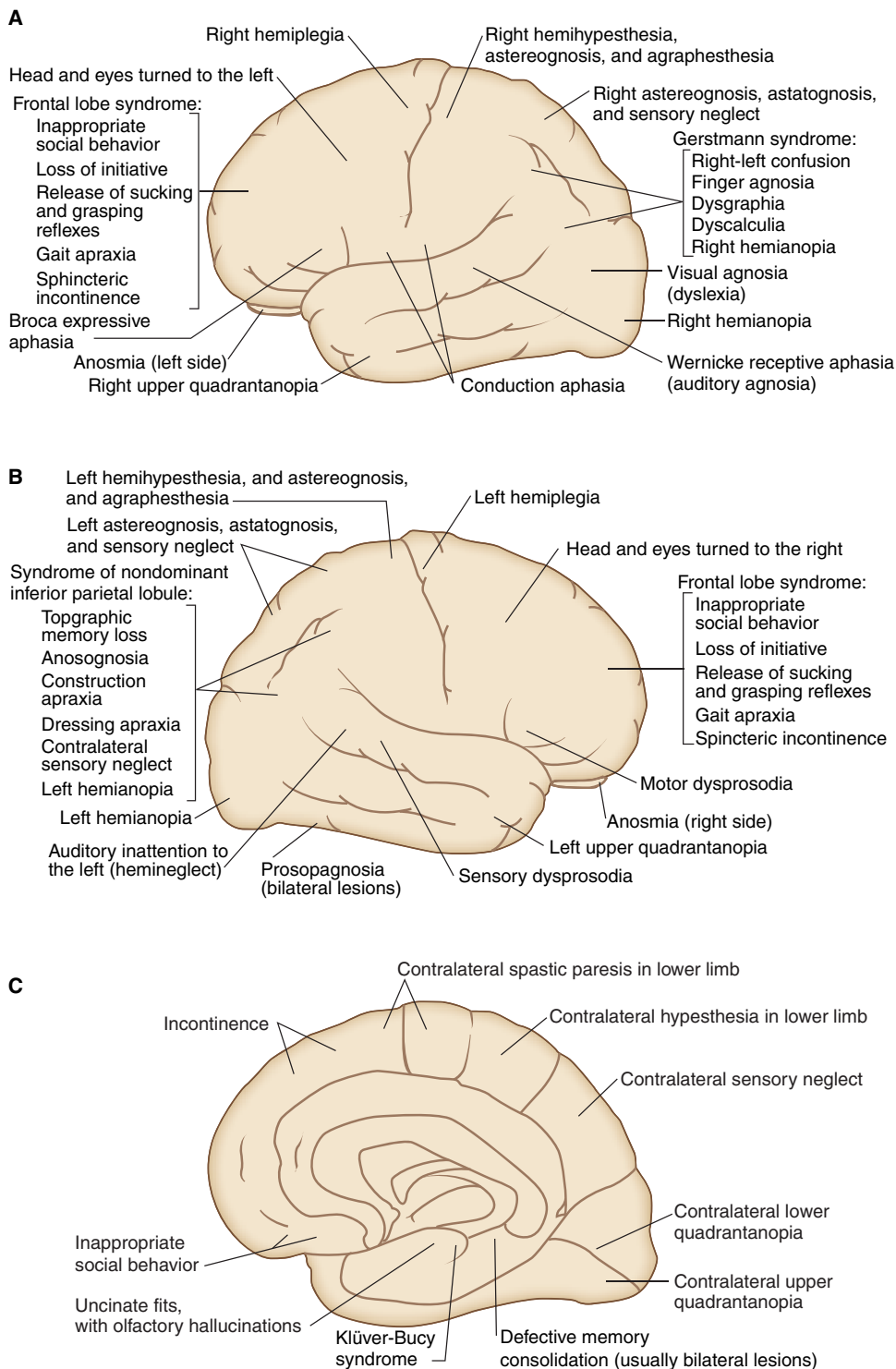


FIGURE 22.4. Focal destructive hemispheric lesions and resulting symptoms. **(A)** Lateral convex surface of the dominant left hemisphere. **(B)** Lateral convex surface of the nondominant right hemisphere. **(C)** Medial surface of the nondominant hemisphere. (Modified from Fix JD. *High-Yield Neuroanatomy*. 3rd ed. Philadelphia, PA: Lippincott Williams & Wilkins; 2005:161.)

V. SPLIT-BRAIN SYNDROME (FIGURE 22.5)

A. Description of split-brain syndrome

- represents a **disconnection syndrome** that results from transection (commissurotomy) of the corpus callosum.

B. Deficits

- Inability of a blindfolded patient to match an object held in one hand with that held in the other hand
- Inability, when blindfolded, to correctly name objects placed in the left hand (**anomia**)
- Inability to match an object seen in the right half of the visual field with one seen in the left half (the test must be performed rapidly to eliminate bilateral visual scanning)

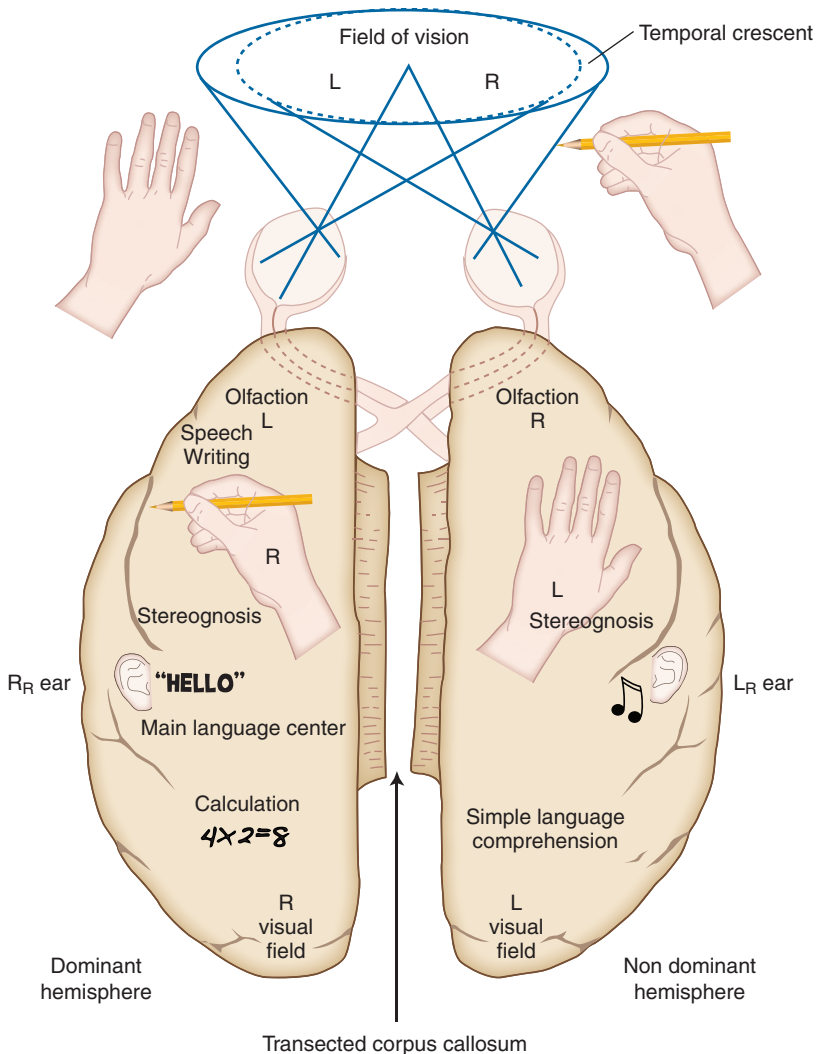


FIGURE 22.5. Functions of the split brain after transection of the corpus callosum. Tactile and visual perception is projected to the contralateral hemisphere; olfaction is perceived on the same side; and audition is perceived predominantly in the opposite hemisphere. The left hemisphere is dominant for language; the right hemisphere is dominant for spatial construction and nonverbal ideation. (Modified from Noback CR and Demarest RJ. *The Human Nervous System*. Baltimore, MD: Williams & Wilkins; 1991:416.)

4. **Alexia** in the left visual fields (the verbal symbols seen in the right visual cortex have no access to the language centers of the left hemisphere)

VI. BLOOD SUPPLY TO THE MAJOR FUNCTIONAL CORTICAL AREAS

- Only **cortical branches** are discussed in this section.

A. Anterior cerebral artery (see Figure 3.3)

1. Territory of the anterior cerebral artery

- supplies the medial aspect of the hemisphere.

2. Occlusion: affected areas and deficits

- Paracentral lobule
 - a. contralateral somatosensory loss in the lower extremity with paresthesia, numbness, and apallesthesia (loss of vibration sensation)
 - b. contralateral weakness and hyperreflexia in the lower extremity with the Babinski sign
 - c. urinary incontinence with bilateral infarction
- Corpus callosum: infarction
 - a. dyspraxia and tactile agnosia of the left limbs

B. Middle cerebral artery (see Figure 3.4)

1. Territory of the middle cerebral artery

- supplies the lateral convex surface of the hemisphere.

2. Occlusion: affected areas and deficits

- Frontal lobe
 - a. Precentral gyrus
 - contralateral facial weakness and weakness in the upper extremity
 - b. Frontal eye field
 - conjugate deviation of the eyes to the affected side
 - c. Prefrontal cortex
 - affects judgment, insight, and mood (frontal lobe syndrome).
 - d. Inferior frontal gyrus of the dominant side
 - Broca expressive aphasia and contralateral weakness of the lower face and arm
 - sympathetic apraxia of the left hand
- Temporal lobe
 - a. Transverse temporal gyri of Heschl
 - deafness with bilateral destruction
 - b. Superior temporal gyrus of the dominant side
 - Wernicke receptive aphasia
 - c. Superior and middle temporal gyri (superolateral parts)
 - auditory illusions and hallucinations
- Parietal lobe
 - a. Postcentral gyrus and superior parietal lobule
 - loss of sensory discrimination and stereognosis
 - hemineglect (may occur with either left or right parietal lesions)
 - b. Inferior parietal lobule of the dominant hemisphere
 - ideomotor and ideational apraxia
 - Gerstmann syndrome
 - c. Inferior parietal lobule of the nondominant hemisphere
 - hemineglect syndrome
 - topographic memory loss, anosognosia, and constructional and dressing apraxia

C. Posterior cerebral artery (see Figure 3.5)

1. Territory of the posterior cerebral artery

- supplies the occipital lobe, the inferior aspect of the temporal lobe (excluding the temporal pole), and the splenium of the corpus callosum.

2. Occlusion: affected areas and deficits

- Occipital lobe: visual cortex (striate and extrastriate)
 - a. if bilateral, cortical blindness (pupils are reactive to light)
 - b. contralateral homonymous hemianopia with macular sparing
- Temporal lobe (inferomedial aspect): hippocampal formation and amygdala
 - a. also perfused by the anterior choroidal artery
 - b. if bilateral or in the dominant hemisphere, memory deficit (amnesia)
 - c. incapacity to create and store new long-term memories; the patient retains and may recall long-term memories.
- Occipitotemporal region (ventromesial aspect)
 - a. Bilateral lesions may result in **prosopagnosia** (the inability to identify a familiar face) and **achromatopsia** (acquired color blindness).

D. Left posterior cerebral artery

1. Territory of the left posterior cerebral artery

- supplies the splenium of the corpus callosum and the left visual cortex.

2. Occlusion

- results in **infarction** of the splenium of the corpus callosum and the left visual cortex; visual input from the right visual cortex cannot reach the parietal language centers of the dominant hemisphere.
- may cause **alexia without agraphia and aphasia**; because the left inferior parietal lobule and Wernicke speech area are intact, the patient can write and is not dysphasic.

E. Jacksonian seizures (Jacksonian march)

- unilateral simple partial motor seizures that start with a tonic contraction of the fingers on one hand, the face on one side, or one foot, and progress to clonic contractions of the entire half of the body; they may progress to grand mal seizures.
- can result from tumors, hematomas, and brain abscesses.
- can affect the opposite side via the corpus callosum.

VII. APRAXIA

- the inability to perform motor activities in the presence of intact motor and sensory systems and normal comprehension.

A. Ideomotor apraxia

- the loss of the ability to perform intransitive or imaginary gestures, resulting in the inability to perform complicated motor tasks (e.g., saluting, blowing a kiss, or making the V-for-peace sign).
- may be typified by facial apraxia, which is also known as buccofacial or facial-oral apraxia, the most common type of apraxia.
- results from a lesion in the Wernicke area.

B. Ideational apraxia

- the inability to demonstrate the use of real objects (e.g., smoke a pipe [a multistep complex sequence]).
- a misuse of objects owing to a disturbance of identification (agnosia).
- results from a lesion in the Wernicke area.

C. Construction apraxia

- the inability to draw or construct a geometric figure (e.g., the face of a clock).
- called hemineglect if the patient draws only the right half of the clock. The lesion is located in the right inferior parietal lobule (see Figure 22.4).

D. Gait apraxia

- characterized by diminished cadence, wide base, short steps, and shuffling progression; it is reminiscent of parkinsonian gait.
- a frontal lobe sign seen in normal-pressure hydrocephalus with gait apraxia, dementia, and incontinence.

VIII. APHASIA

- impaired or absent communication by speech, writing, or signs (i.e., loss of the capacity for spoken language).
- results from lesions in the dominant hemisphere.
- the following symptoms and signs are associated with certain aphasia (Figure 22.6).

A. Broca (motor) aphasia

- characterized by good comprehension; effortful, dysarthric, telegraphic, and nonfluent speech; poor repetition; and contralateral lower facial and upper limb weakness.
- results from a lesion in the frontal lobe, in the inferior frontal gyrus (Brodmann 44 and 45).

B. Wernicke (sensory) aphasia

- characterized by poor comprehension, fluent speech, poor repetition, and quadrantanopia.
- also marked by paraphasic errors such as non sequiturs (Latin—does not follow logically what is said previously), neologisms (words with no meaning), and driveling speech.
- results from a lesion in the posterior temporal lobe, in the superior temporal gyrus (Brodmann 22).

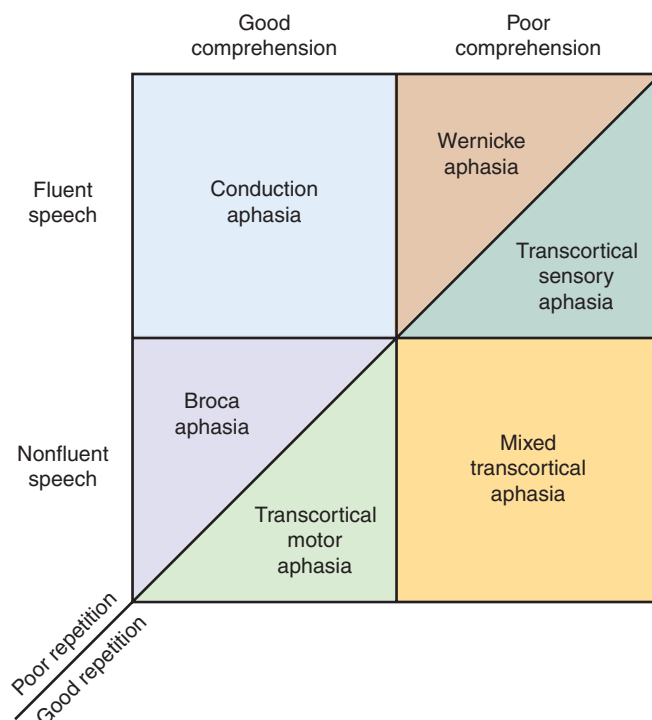


FIGURE 22.6. The aphasia square is used to differentiate six common aphasia. Broca, conduction, and Wernicke aphasia are all characterized by poor repetition. (Modified from Miller J, Fountain N. *Neurology Recall*. Baltimore, MD: Williams & Wilkins; 1997:35.)

C. Conduction aphasia

- involves the transection of the arcuate fasciculus; the arcuate fasciculus interconnects Broca speech area with Wernicke speech area.
- characterized by good comprehension, poor repetition, and fluent speech.

D. Transcortical motor aphasia

- involves good comprehension, good repetition, and nonfluent speech.

E. Transcortical mixed aphasia

- involves poor comprehension, good repetition, and nonfluent speech.

F. Transcortical sensory aphasia

- involves poor comprehension, good repetition, and fluent speech.

G. Global aphasia

- results from a lesion of the perisylvian area, which contains the Broca and Wernicke areas.
- combines all the symptoms of Broca and Wernicke aphasias.

H. Thalamic aphasia

- a dominant thalamic syndrome that closely resembles a thought disorder of patients with schizophrenia and chronic drug-induced psychosis.
- involves fluent paraphasic speech with normal comprehension and repetition.

I. Basal nuclei

- Diseases of the basal nuclei may cause aphasia.
- Lesions of the anterior basal nuclei result in nonfluent aphasia, and lesions of the posterior basal nuclei result in fluent aphasia.

J. Watershed infarcts

- areas of infarction in the boundary zones of the anterior, middle, and posterior cerebral arteries. Infarcts cause the motor, mixed, and sensory transcortical aphasias.
- vulnerable to hypoperfusion and thus may separate the Broca and Wernicke speech areas from the surrounding cortex.

IX. DYSPROSODIES

- nondominant hemispheric language deficits that affect the emotionality of speech (inflection, melody, emphasis, and gesturing).

A. Expressive dysprosody

- results from a lesion that corresponds to the Broca area but is located in the nondominant hemisphere.
- patients cannot express emotion or inflection in their speech.

B. Receptive dysprosody

- results from a lesion that corresponds to the Wernicke area but is located in the nondominant hemisphere.
- patients cannot comprehend the emotionality or inflection in the speech they hear.

Review Test

1. A 55-year-old right-handed veteran received a small shrapnel wound in the head. Within 1 year of receiving his wound, the man complained of seizures and was treated with seizure medication. The medication was not effective, and a section of the anterior corpus callosum was performed successfully. Which of the following neurologic deficits is most likely?

- (A) Alexia
- (B) Gait dystaxia
- (C) Loss of binocular vision
- (D) Sympathetic apraxia in the right hand
- (E) The inability, with closed eyes, to identify verbally an object held in the left hand

2. A 70-year-old hypertensive man suddenly experiences numbness on the right side of his body. When asked to raise his left hand, he raises his right hand. The lesion is most likely in the:

- (A) left parietal lobe.
- (B) left temporal lobe.
- (C) right frontal lobe.
- (D) right internal capsule.
- (E) right parietal lobe.

3. A 45-year-old farmer complains of headaches. Neurologic examination reveals pronator drift and mild hemiparesis on the right side. The patient's eyes and head are turned to the left side, and papilledema is visible on the left side. The lesion is most likely in which of the following cortices?

- (A) Frontal
- (B) Insular
- (C) Occipital
- (D) Parietal
- (E) Temporal

4. An 80-year-old microbiologist has a cerebral infarction. His speech is limited to expletives, he cannot write but does respond to questions by shaking his head, and he has lower facial weakness on the right side. The lesion is most likely in the:

- (A) left frontal lobe.
- (B) left parietal lobe.
- (C) left temporal lobe.

- (D) right frontal lobe.
- (E) right parietal lobe.

5. A lesion resulting in a nonfluent expressive aphasia will be found most likely in the:

- (A) frontal lobe.
- (B) limbic lobe.
- (C) occipital lobe.
- (D) parietal lobe.
- (E) temporal lobe.

6. Broca aphasia is frequently associated with:

- (A) an UMN lesion.
- (B) auditory hallucinations.
- (C) construction apraxia.
- (D) finger agnosia.
- (E) visual field deficits.

7. Alexia without agraphia and aphasia will most likely result from occlusion of the:

- (A) left anterior cerebral artery.
- (B) left middle cerebral artery.
- (C) left posterior cerebral artery.
- (D) right anterior cerebral artery.
- (E) right posterior cerebral artery.

8. Agraphia and dyscalculia will most likely result from a lesion in the:

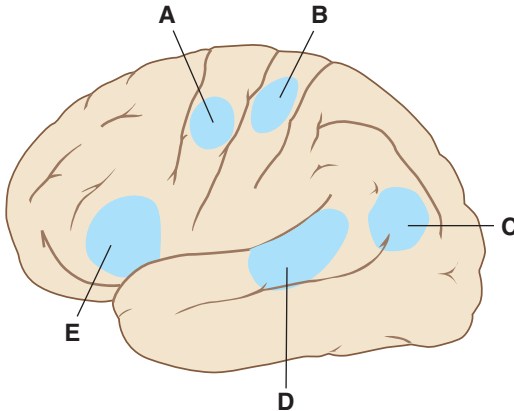
- (A) left frontal lobe.
- (B) left parietal lobe.
- (C) left temporal lobe.
- (D) right occipital lobe.
- (E) splenium of corpus callosum.

9. A patient is asked to bisect a horizontal line through the middle, to draw the face of a clock, and to copy a cross. The patient bisected the horizontal line to the left of the midline, placed all of the numerals of the clock on the right side, and did not complete the cross on the left side. The most likely lesion site for this deficit is the:

- (A) left frontal lobe.
- (B) left occipital lobe.
- (C) left parietal lobe.
- (D) right parietal lobe.
- (E) right temporal lobe.

Questions 10 to 15

Match the descriptions in items 10 to 15 with the appropriate lettered area shown in the figure.



10. Broca speech area

11. Wernicke speech area

12. Lesion in this area results in contralateral astereognosis

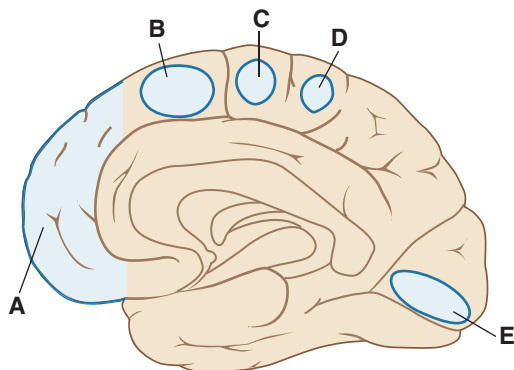
13. Infarction in this area results in an UMN lesion

14. Lesion in this area results in contralateral homonymous hemianopia

15. Lesion in this area results in finger agnosia, agraphia, and dyscalculia

Questions 16 to 20

Match the descriptions in items 16 to 20 with the appropriate lettered area shown in the figure.



16. Supplementary motor area

17. Lesion in this area results in paresthesias and numbness in the contralateral foot

18. Lesion in this area results in contralateral lower homonymous quadrantanopia

19. Lesion in this area results in a contralateral Babinski sign

20. Lesion in this area results in loss of initiative and inappropriate social behavior

21. Which of the following arteries, on occlusion, can result in Broca aphasia?

- (A) Angular artery
- (B) Anterior choroidal artery
- (C) Anterior temporal artery
- (D) Medial striate artery of Heubner
- (E) Operculofrontal artery

22. A patient is given a pipe, tobacco, and matches and is asked to smoke the pipe. The patient rubs the matches on the pipe. Which of the following neurologic diagnoses best describes this behavior?

- (A) Construction apraxia
- (B) Dysprosody
- (C) Ideational apraxia
- (D) Ideomotor apraxia
- (E) Prosopagnosia

23. A 65-year-old man complains of difficulty in walking. He has a history of chronic subdural hematomas. Neurologic examination reveals psychomotor slowing, sphincter incontinence, and enlarged ventricles without convolutional atrophy. The most likely diagnosis is:

- (A) Huntington disease.
- (B) normal-pressure hydrocephalus.
- (C) Parkinson disease.
- (D) progressive supranuclear palsy.
- (E) Wilson disease.

24. Neurologic examination indicates that a 50-year-old woman with hypertension has left homonymous hemianopia but is not aware of her deficit (anosognosia). When asked to copy a drawing of a clock face, she neglects to draw the numerals on the left side of the clock. Based on this examination, the lesion would most likely be in the:

- (A) frontal lobe.
- (B) insula.
- (C) left parietal lobe.
- (D) right parietal lobe.
- (E) right temporal lobe.

25. A 48-year-old woman who has had a stroke complains of weakness of her right arm and weakness of her right lower face. Language assessment reveals the following speech deficits: slow, labored speech; dysarthric, telegraphic speech; usually good comprehension; and poor repetition. Which of the following types of aphasia do these neurologic findings describe best?

- (A) Broca aphasia
- (B) Conduction aphasia
- (C) Transcortical motor aphasia
- (D) Transcortical sensory aphasia
- (E) Wernicke aphasia

26. A 65-year-old man has a cerebrovascular accident. Language assessment reveals the following speech abnormalities: impaired comprehension; impaired repetition; and paraphrasic speech, including non sequiturs and neologisms. Spontaneity and fluency are normal. Which of the following types of aphasia best fits this evaluation?

- (A) Broca aphasia
- (B) Conduction aphasia
- (C) Mixed transcortical aphasia

- (D) Transcortical motor aphasia
- (E) Wernicke aphasia

27. A 50-year-old man has a mass lesion underlying the left frontoparietal operculum. Language assessment reveals good comprehension, fluent speech, poor repetition, anomia, and agraphia. Which of the following types of aphasia best fits this case?

- (A) Broca aphasia
- (B) Conduction aphasia
- (C) Global aphasia
- (D) Transcortical sensory aphasia
- (E) Wernicke aphasia

28. A 45-year-old woman has a stroke. She exhibits weakness in her left arm, and she is unable to show emotion, inflection, and emphasis and gesturing in her propositional language. The lesion responsible for this language difficulty would most likely be in the:

- (A) left frontal lobe.
- (B) left parietal lobe.
- (C) left temporal lobe.
- (D) right frontal lobe.
- (E) right temporal lobe.

Answers and Explanations

1-E. Transection of corpus callosum results in the inability, when blindfolded, to identify verbally an object held in the left hand (dysnomia). The left hemisphere is dominant for language and naming objects. Alexia is found in lesions of the inferior parietal lobule. Gait dystaxia may result from normal-pressure hydrocephalus, which also involves dementia and incontinence. The man's visual pathways are not affected. Transection of callosal fibers adjacent to the left premotor cortex produces right hemiparesis, motor (Broca) dysphasia, and sympathetic dyspraxia of the left, nonparalyzed, arm.

2-A. The right hemiparesis points to a lesion on the left side involving the corticospinal tract. Left-right confusion is seen in Gerstmann syndrome along with finger agnosia. This syndrome results from destruction of the left angular gyrus.

3-A. The cortical center for lateral conjugate gaze is located in area 8 of the frontal lobe. Destruction of this area results in turning of the head and eyes toward the side of the lesion. Stimulation of this area results in contralateral turning of the eyes and head; pronator drift and hemiparesis are frontal lobe signs.

4-A. Lower facial weakness is a localizing neighborhood sign. The Broca speech area is located in the posterior part of the inferior frontal gyrus (Brodmann areas 44 and 45).

5-A. Nonfluent, expressive motor aphasia (Broca aphasia) results from a lesion in the posterior inferior frontal gyrus (areas 44 and 45) of the dominant frontal lobe.

6-A. Broca aphasia is frequently associated with an UMN lesion of the contralateral face and upper limb and occasionally of the lower limb. Broca speech area lies just anterior to the motor strip; Broca speech area as well as the motor strip is irrigated by the superior division of the middle cerebral artery (perolantic and rolandic arteries). Broca aphasia is frequently associated with sympathetic apraxia, an apraxia of the nonparalyzed left hand.

7-C. Alexia without agraphia and aphasia results from occlusion of the left posterior cerebral artery, which supplies the left visual cortex and callosal fibers (within the splenium) from the right visual association cortex. Interruption of bilateral visual association fibers en route to the left angular gyrus results in alexia. The patient will not be agraphic or dysphasic because the angular gyrus and Wernicke area are spared.

8-B. Lesions of the angular gyrus of the dominant hemisphere may result in Gerstmann syndrome, which consists of agraphia, dyscalculia, finger agnosia, and left-right confusion.

9-D. The inability to draw a clock face or bisect a line through the middle is called construction apraxia. Lesions of the right (nondominant) parietal lobe result in construction apraxia, dressing apraxia, anosognosia, and sensory hemineglect.

10-E. Broca speech area (areas 44 and 45) is found in the posterior part of the inferior frontal gyrus of the dominant hemisphere, directly anterior to the premotor and motor cortices.

11-D. Wernicke speech area is located in the posterior part of the superior temporal gyrus (part of Brodmann area 22) of the dominant hemisphere. A lesion of this area results in a fluent sensory (receptive) aphasia.

12-B. A lesion of the left postcentral gyrus results in a right astereognosis (tactile agnosia), the inability to identify objects by touch. Lesions of the superior parietal lobule result in contralateral astereognosis and in sensory neglect.

13-A. A lesion in the precentral gyrus is an UMN lesion. The precentral gyrus (motor strip) gives rise to one-third of the pyramidal tract (corticospinal tract) fibers.

14-C. A deep lesion of the angular gyrus can involve the visual radiation, resulting in a contralateral homonymous hemianopia.

15–C. The dominant angular gyrus is the neurologic substrate of Gerstmann syndrome, which consists of right-left confusion, finger agnosia, agraphia, and dyscalculia.

16–B. The supplementary motor cortex (area 6) lies on the medial aspect of the hemisphere, just anterior to the paracentral lobule.

17–D. A lesion in the posterior part of the paracentral lobule results in loss of joint and position sense (astatognosia) and loss of tactile discrimination (astereognosis) in the contralateral foot.

18–E. A lesion of the superior bank of the calcarine sulcus (cuneus) results in a contralateral lower homonymous quadrantanopia. A lesion destroying both cunei produces a lower homonymous altitudinal hemianopia.

19–C. A lesion of the anterior part of the paracentral lobule results in a contralateral paresis of the foot muscles and in Babinski sign (i.e., plantar reflex extensor or extensor toe sign).

20–A. Lesions of the prefrontal cortex can result in personality changes, with disorderly and inappropriate conduct and facetiousness and jocularity. Lesions interrupt fibers that interconnect the dorsomedial nucleus and the prefrontal cortex (e.g., prefrontal lobotomy or leukotomy).

21–E. The Broca speech area, located in the lower frontal gyrus of the left hemisphere, is supplied by the operculofrontal artery. This area may also be perfused by the prerolandic artery. Both arteries arise from the middle cerebral artery.

22–C. The patient, who is unable to light a match and smoke the pipe in proper sequence on command, has ideational or sensory apraxia, a disorder of a multistep action sequence. Construction apraxia is the inability to draw an entire clock face; patients with nondominant parietal lobe lesions cannot draw the left side of the clock (sensory neglect). Ideomotor apraxia is the inability to follow simple commands (i.e., stick out your tongue or make a fist). Prosopagnosia is the inability to recognize faces. Dysprosody is the difficulty producing or understanding the normal pitch, rhythm, and variation in stress in speech.

23–B. Normal-pressure hydrocephalus is characterized by the triad of gait apraxia (frontal lobe ataxia), incontinence, and dementia. The ventricles are moderately dilated. Huntington disease is a neurodegenerative disorder characterized by choreoathetosis, tremor, and dementia. Parkinson disease is characterized by a pill-rolling resting tremor, cogwheel rigidity, and bradykinesia (slowness in movement). Progressive supranuclear palsy is a movement disorder characterized by paresis of downgaze. Wilson disease (hepatolenticular degeneration) is a disease of copper metabolism characterized by a coarse “wing-beating” tremor. The corneal Kayser-Fleischer ring is pathognomonic.

24–D. Lesions of the nondominant (right) parietal lobe have the following deficits: anosognosia, topographic memory loss, dressing apraxia, sensory neglect, sensory extinction, and left homonymous hemianopia. Frontal lobe signs may include motor abnormalities, impairment of cognitive function, personality changes (disinhibition of behavior), and incontinence. The insula receives olfactory and gustatory input. Temporal lobe signs may include Wernicke aphasia, auditory, visual, olfactory, and gustatory hallucinations, and loss of recent memory.

25–A. Key features that point to Broca aphasia are slow, labored dysarthric telegraphic speech; relatively good speech comprehension; poor repetition; frequent depression; and frequent buccolingual dyspraxia. Broca aphasia is also called motor, expressive, and anterior aphasia. See Figure 22-6.

26–E. Wernicke aphasia is characterized by fluent speech, poor comprehension, poor repetition, and paraphrasic errors (e.g., driveling speech, non sequiturs, and neologisms).

27–B. Conduction aphasia results from a lesion that transects the arcuate fasciculus, thus separating the Broca speech area from the Wernicke speech area. This condition is characterized by markedly impaired repetition, with preserved fluency and comprehension. Conduction aphasia is usually associated with agraphia.

28–D. The center for expressive prosody is located in the posterior part of the inferior frontal gyrus of the nondominant lobe. The center for receptive prosody is located in the posterior part of the superior temporal gyrus of the nondominant hemisphere.

Comprehensive Examination

1. The cuneus is separated from the lingual gyrus by the:
(A) calcarine sulcus.
(B) collateral sulcus.
(C) intraparietal sulcus.
(D) parietooccipital sulcus.
(E) rhinal sulcus.
2. Which sinus receives drainage from the greatest number of arachnoid granulations?
(A) Cavernous sinus
(B) Sigmoid sinus
(C) Straight sinus
(D) Superior sagittal sinus
(E) Transverse sinus
3. Which one of the following statements concerning the Rathke's pouch is true? It
(A) is a mesodermal diverticulum.
(B) is derived from the neural tube.
(C) gives rise to the adenohypophysis.
(D) gives rise to the epiphysis.
(E) gives rise to the neurohypophysis.
4. Which of the following statements concerning the lateral horn of the spinal cord is true? It
(A) contains preganglionic parasympathetic neurons.
(B) gives rise to a spinocerebellar tract.
(C) gives rise to preganglionic sympathetic fibers.
(D) is most prominent at sacral levels.
(E) is present at all spinal cord levels.
5. Which of the following statements concerning the dorsal nucleus (of Clarke) is true? It
(A) is found in the anterior horn.
(B) is homologous to the cuneate nucleus of the medulla.
(C) is most prominent at upper cervical levels.
(D) is present at all spinal levels.
(E) projects to the cerebellum.
6. Which one of the following groups of cranial nerves is closely related to the corticospinal tract?
(A) CN III, CN IV, and CN V
(B) CN III, CN V, and CN VII
(C) CN III, CN VI, and CN VIII
(D) CN III, CN VI, and CN XII
(E) CN III, CN IX, and CN X
7. The primary auditory cortex is located in the:
(A) frontal operculum.
(B) inferior parietal lobule.
(C) postcentral gyrus.
(D) superior parietal lobule.
(E) transverse temporal gyri.
8. The neocerebellum projects to the motor cortex via the:
(A) anterior thalamic nucleus.
(B) lateral dorsal nucleus.
(C) lateral posterior nucleus.
(D) ventral anterior nucleus.
(E) ventral lateral nucleus.
9. The dentatothalamic tract decussates in the:
(A) caudal midbrain.
(B) caudal pons.
(C) diencephalon.
(D) rostral midbrain.
(E) rostral pons.
10. A pituitary tumor is most frequently associated with:
(A) altitudinal hemianopia.
(B) binasal hemianopia.
(C) bitemporal hemianopia.
(D) homonymous hemianopia.
(E) homonymous quadrantanopia.

11. Resection of the anterior portion of the left temporal lobe is most frequently associated with:

- (A) left homonymous hemianopia.
- (B) left lower homonymous quadrantanopia.
- (C) left upper homonymous quadrantanopia.
- (D) right lower homonymous quadrantanopia.
- (E) right upper homonymous quadrantanopia.

12. A 65-year-old farmer has had dull frontal headaches for the last 3 weeks. Neurologic examination reveals spastic hemiparesis on the right side and a pronator drift on the right side. What is the most likely diagnosis?

- (A) Brain tumor
- (B) Myasthenia gravis
- (C) Progressive supranuclear palsy
- (D) Pseudotumor cerebri
- (E) Subacute combined degeneration

13. An 18-year-old high school student has a fractured cervical vertebra. Neurologic examination reveals hemiparesis on the right side, Babinski and Hoffmann signs on the right side, loss of pain and temperature sensation on the left side, and normal pallesthesia in all extremities. The spinal cord lesion that will most likely explain the deficits involves the:

- (A) anterior column, bilateral.
- (B) lateral column, left side.
- (C) lateral column, right side.
- (D) posterior column, left side.
- (E) posterior column, right side.

14. Light shone into the left eye elicits a direct pupillary reflex but no consensual reflex. A lesion in which of the following structures accounts for this deficit?

- (A) Oculomotor nerve, right side
- (B) Oculomotor nerve, left side
- (C) Optic nerve, left eye
- (D) Optic nerve, right eye
- (E) Optic tract, right side

15. A 53-year-old housewife has a normal corneal blink reflex on her left side but no consensual blink on her right side. Which of the following neurologic deficits or signs will you expect to find on the right side?

- (A) Hemianesthesia
- (B) Hemianhidrosis
- (C) Hyperacusis
- (D) Internal ophthalmoplegia
- (E) Severe ptosis

16. A 49-year-old man has a loss of tactile sensation involving the anterior two-thirds of his tongue on the left side. Neurologic examination reveals paralysis of the masseter on the left side and loss of pain and temperature sensation from the teeth of the mandible on the left side. He has a lesion involving which one of the following nerves?

- (A) Chorda tympani
- (B) Facial
- (C) Hypoglossal
- (D) Trigeminal, mandibular division
- (E) Trigeminal, ophthalmic division

17. A 62-year-old man has a stroke and falls while cutting his lawn. He does not lose consciousness. Neurologic examination reveals loss of pain sensation on the right side of the face and on the left side of the body, falling and past-pointing to the right side, difficulty in swallowing, horizontal nystagmus to the right side, deviation of the uvula to the left when asked to say "ah," and Horner syndrome on the right side. The most likely site of this man's lesion is the:

- (A) internal capsule, left side.
- (B) lateral medulla, right side.
- (C) medial medulla, right side.
- (D) midbrain, right side.
- (E) pontine tegmentum.

18. A 64-year-old pharmacology professor complains of weakness in his right leg and double vision, especially when moving his eyes to the left. Neurologic examination reveals a dilated pupil and ptosis on the left side and a Babinski sign (extensor plantar reflex) on the right side. The most likely site of this patient's lesion is the:

- (A) internal capsule, right side.
- (B) midbrain crus cerebri, left side.
- (C) midbrain crus cerebri, right side.
- (D) pontine base, left side.
- (E) pontine tegmentum, right side.

19. While working in his shop, a 21-year-old machinist is struck by a penetrating metal fragment in the side of the head. Neurologic examination reveals the following language deficits: fluent speech, no ability to read aloud, no ability to repeat what you say, no ability to compensate by writing. The patient understands the problem but cannot resolve it. Where would you expect to find the fragment?

- (A) Between the supramarginal gyrus and the inferior frontal gyrus
- (B) In the angular gyrus

- (C) In the paracentral gyrus
- (D) In the posterior third of the superior temporal gyrus
- (E) In the transverse gyri

20. The catecholamine norepinephrine is the primary neurotransmitter found in the:

- (A) adrenal cortex.
- (B) adrenal medulla.
- (C) postganglionic parasympathetic neurons to the circular smooth muscle layer of the jejunum.
- (D) postganglionic sympathetic neurons to the smooth muscle of the renal arterioles.
- (E) postganglionic sympathetic neurons to the sweat glands.

21. A 30-year-old man sustains brain damage as the result of an automobile accident. Neurologic examination reveals incomplete retrograde amnesia, severe anterograde amnesia, and inappropriate social behavior, including hyperphagia, hypersexuality, and general disinhibition. The brain injury most likely involves the:

- (A) frontal lobes, lateral convexity.
- (B) frontal lobes, medial surface.
- (C) temporal lobes, lateral convexity.
- (D) temporal lobes, medial surface.
- (E) thalami.

22. A 55-year-old woman has difficulty reading small print. She most likely has:

- (A) astigmatism.
- (B) cataracts.
- (C) optic atrophy.
- (D) macular degeneration.
- (E) presbyopia.

23. The principal postnatal change in the pyramids is the result of:

- (A) an increase in endoneurial tubes to guide sprouting axons
- (B) an increase of corticospinal neurons from the paracentral lobule.
- (C) an increase in the total number of corticospinal axons.
- (D) a large increase of Schwann cells in the motor cortex.
- (E) myelination of preexisting corticospinal axons.

24. Special visceral afferent neurons that innervate receptor cells in taste buds synapse in the:

- (A) geniculate ganglion.
- (B) inferior salivatory nucleus.

- (C) nucleus of the solitary tract.
- (D) spinal trigeminal nucleus.
- (E) ventral posteromedial nucleus.

25. A woman receives an injection of a radioisotope to determine regional blood flow in the brain. She has a positron emission tomography scan to visualize variations in cortical blood flow. The examiner asks her to think about flexing her index finger without actually doing it. In which of the following cortical areas would you expect to see increased blood flow?

- (A) Angular gyrus
- (B) Broca area
- (C) Motor strip
- (D) S-I somatosensory cortex
- (E) Supplementary motor cortex

26. Which of the following sensory deficits results from the destruction of the right cuneate nucleus?

- (A) Analgesia, left hand
- (B) Analgesia, right foot
- (C) Apallesthesia, left foot
- (D) Apallesthesia, left hand
- (E) Apallesthesia, right hand

27. Which of the following postganglionic sympathetic responses results from the elaboration of acetylcholine?

- (A) Constriction of cutaneous blood vessels
- (B) Contraction of arrector pili muscles
- (C) Decreased gastrointestinal motility
- (D) Increased ventricular contractility
- (E) Stimulation of eccrine sweat glands

28. Which of the following neural structures mediates nausea?

- (A) Celiac ganglion
- (B) Greater splanchnic nerve
- (C) Inferior mesenteric ganglion
- (D) Superior mesenteric ganglion
- (E) Vagal nerves

29. Cerebrospinal fluid enters the bloodstream via the:

- (A) arachnoid villi.
- (B) choroid plexus.
- (C) interventricular foramen (of Monro).
- (D) lateral foramina (of Luschka).
- (E) median foramen (of Magendie).

30. Computed tomography of the head of a newborn infant reveals enlargement of the lateral ventricles and the third ventricle. Which

of the following is the most likely cause of this hydrocephalus?

- (A) Adhesive arachnoiditis
- (B) Aqueductal stenosis
- (C) Calcification of the arachnoid granulations
- (D) Choroid plexus papilloma
- (E) Stenosis of the median foramen

31. The cellular neuropathology of Alzheimer's disease resembles most closely that seen in:

- (A) Huntington disease.
- (B) multi-infarct dementia.
- (C) neurosyphilis.
- (D) Pick disease.
- (E) trisomy 21.

32. A 40-year-old man visits his general practitioner. He complains of shortness of breath and difficulty in performing his construction work. During the history taking, he tells his physician that he had an attack of gastroenteritis 3 weeks ago. The neurologic examination reveals ascending weakness and tingling in the legs and absence of muscle stretch reflexes in the legs. Cerebrospinal fluid analysis shows elevated protein without significant pleocytosis. The most likely diagnosis is:

- (A) Amyotrophic lateral sclerosis.
- (B) Guillain-Barré syndrome.
- (C) Multiple sclerosis.
- (D) Myasthenia gravis.
- (E) Werdnig-Hoffmann syndrome.

33. A 25-year-old female high school teacher has had difficulty walking. Five years ago she experienced a loss of vision in her left eye that improved in 3 weeks. Neurologic examination reveals a right afferent pupillary defect, hyperreflexia in both legs, reduced proprioception in both feet, and extensor plantar reflexes. Cerebrospinal fluid analysis shows oligoclonal bands. The most likely diagnosis is:

- (A) amyotrophic lateral sclerosis.
- (B) Guillain-Barré syndrome.
- (C) multiple sclerosis.
- (D) subacute combined degeneration.
- (E) syringobulbia.

34. A 48-year-old woman complains of a progressive loss of hearing and a buzzing noise in her right ear. Neurologic examination reveals an absent corneal reflex on the right side and sagging of the right corner of the mouth. Magnetic resonance imaging shows a mass in the right cerebellopontine angle. From which of

the following cell type proliferation will the neoplasm most likely arise?

- (A) Fibrous astrocytes
- (B) Microglia
- (C) Oligodendrocytes
- (D) Protoplasmic astrocytes
- (E) Schwann cells

35. A 50-year-old man complains of weakness in his left leg and loss of pain and temperature in his right leg. Neurologic examination reveals exaggerated muscle stretch reflexes in the left leg and an extensor plantar reflex on the left side. The lesion would most likely be located in the:

- (A) crus cerebri.
- (B) internal capsule.
- (C) lateral medulla.
- (D) medial medulla.
- (E) spinal cord.

36. A 20-year-old comatose man has sustained massive head injuries in an automobile accident. Ice water injected into the external auditory meatus elicits no ocular response. Head rotation does not result in the doll's-eye phenomenon. The lesion causing the injuries most likely affects the:

- (A) cochlear nuclei.
- (B) dentate nuclei.
- (C) ossicles.
- (D) utricles.
- (E) vestibular nuclei.

37. Which of the following agents may be used as an alternative to L-dopa to alleviate the chemical imbalance found in the striatum of a patient with Parkinson disease?

- (A) Aspartate
- (B) Anticholinergic agent
- (C) Dopamine antagonist
- (D) Glutamate
- (E) Serotonin reuptake inhibitor

38. Which of the following antidepressants is the most selective inhibitor of serotonin reuptake?

- (A) Amitriptyline
- (B) Doxepin
- (C) Fluoxetine
- (D) Nortriptyline
- (E) Tranylcypromine

39. A 20-year-old woman suddenly develops double vision. Neurologic examination reveals diplopia when she attempts to look to the left,

the inability to adduct the right eye, nystagmus in the left eye on attempted lateral conjugate gaze to the left, and convergence of both eyes on a near point. These deficits would result from occlusion of a branch of:

- (A) anterior cerebral artery.
- (B) basilar artery.
- (C) middle cerebral artery.
- (D) ophthalmic artery.
- (E) posterior cerebral artery.

40. A 50-year-old man had a stroke and developed ipsilateral paralysis and atrophy of the tongue, contralateral loss of vibrations sense, contralateral hemiplegia, contralateral Babinski sign. The level of this vascular syndrome is in the:

- (A) lateral medulla.
- (B) medial medulla.
- (C) midbrain.
- (D) pontine base.
- (E) pontine tegmentum.

41. Tritiated proline [^3H]-proline] is injected into the left upper quadrant of the left retina for anterograde transport. Radioactive label would be found in the:

- (A) cuneus, left side.
- (B) cuneus, right side.
- (C) lingual gyrus, left side.
- (D) lingual gyrus, right side.
- (E) optic nerve, left side.

42. Tritiated leucine [^3H]-leucine] is injected into the left inferior olivary nucleus for anterograde transport. Radioactive label would be found in the:

- (A) dorsal nucleus (of Clarke).
- (B) dentate nucleus, right side.
- (C) lateral cuneate nucleus, left side.
- (D) nuclei of the lateral lemnisci.
- (E) superior olivary nucleus, left side.

43. ^3H -proline is injected into the right ventral posterolateral nucleus for retrograde transport. Radioactive label would be found in the:

- (A) lateral cuneate nucleus, left side.
- (B) nucleus gracilis, left side.
- (C) nucleus gracilis, right side.
- (D) nucleus ruber, right side.
- (E) ventral lateral nucleus.

44. Horseradish peroxidase is injected into the nucleus of the inferior colliculus for retrograde

transport. In which of the following nuclei will the label be found?

- (A) Inferior olivary nucleus
- (B) Medial geniculate nucleus
- (C) Lateral geniculate nucleus
- (D) Superior olivary nucleus
- (E) Transverse gyrus of Heschl

45. A 30-year-old barber complains of difficulty chewing and weakness in the contralateral extremities and loss of pain and temperature sensation from the ipsilateral face. In which one of the following choices will this lesion be most likely found?

- (A) Medulla, lateral
- (B) Medulla, medial
- (C) Midbrain, base
- (D) Pons, base
- (E) Pons, tegmentum

46. A 45-year-old carpenter had bilateral paralysis of the tongue. Fasciculations were seen on the tongue and bilateral loss of deep sensibility (proprioception) in the trunk and limbs. The lesion would most likely be in the:

- (A) closed medulla pyramidal decussation.
- (B) midbrain, tegmentum.
- (C) open medulla, medial lemniscus bilateral, root fibers CN XII, bilateral.
- (D) pons, base.
- (E) pons, tegmentum.

47. A 25-year-old woman has paralysis of the face and lateral rectus, medial rectus palsy on attempted lateral conjugate gaze, nystagmus, normal convergence, miosis, ptosis, and multiple sclerosis. Where will this lesion be most likely found?

- (A) Lateral medulla
- (B) Medial medulla
- (C) Midbrain, tegmentum
- (D) Pons, tegmentum
- (E) Pons, base

48. A 40-year-old man had a stroke and developed ipsilateral paralysis and atrophy of the tongue, contralateral loss of vibration sense, contralateral hemiplegia, and contralateral Babinski sign. Which artery's thrombosis will result in these neurologic deficits?

- (A) Anterior inferior cerebellar artery
- (B) Anterior spinal artery
- (C) Labyrinthine artery
- (D) Posterior inferior cerebellar artery
- (E) Posterior spinal artery

49. A 55-year-old right-handed man had abnormal speech and language usage. The psychiatric interview revealed poor comprehension, fluent speech, poor repetition, and the neighborhood signs contralateral quadrantanopia and contralateral hemisensory loss. Match the neurologic deficits to the anatomic substrata.

- (A) Inferior frontal gyrus
- (B) Inferior temporal gyrus
- (C) Middle frontal gyrus
- (D) Precentral gyrus
- (E) Superior temporal gyrus

50. Which disease is preferentially found in the frontal lobe?

- (A) Creutzfeldt-Jakob disease
- (B) Down syndrome
- (C) Pick disease
- (D) Sturge-Weber syndrome
- (E) Tuberous sclerosis

51. A 60-year-old right-handed man had abnormal speech and language usage. The psychiatric interview revealed the following speech and language findings: good comprehension of spoken and written language; spontaneous speech fluent but paraphasic; poor repetition; inability to repeat polysyllabic words. A neighborhood sign is contralateral quadrantanopia. Match the neurologic deficits with the anatomic substrata.

- (A) Arcuate fasciculus
- (B) Arcuate nucleus
- (C) Dorsal longitudinal fasciculus
- (D) Indusium griseum
- (E) Medial longitudinal fasciculus

52. Which of the following structures contains calcium concretions?

- (A) Cerebral aqueduct
- (B) Cerebral peduncle
- (C) Inferior colliculus
- (D) Oculomotor nerve
- (E) Pineal gland

Questions 53 to 56

The response options for items 53 to 56 are the same. Select one answer for each nerve in the set.

- (A) Abducent
- (B) Accessory
- (C) Facial

- (D) Glossopharyngeal
- (E) Hypoglossal
- (F) Oculomotor
- (G) Olfactory
- (H) Optic
- (I) Trigeminal
- (J) Trochlear
- (K) Vagal
- (L) Vestibulocochlear

Match each description with the most appropriate cranial nerve.

53. Is derived from the walls of the diencephalic vesicle

54. Is often damaged in the process of transtentorial herniation

55. Mediates the sensory and motor innervation of pharyngeal arches 4 and 6

56. Innervates the muscle that depresses, intorts, and abducts the globe

Questions 57 to 58

The response options for items 57 and 58 are the same. Select one answer for each item in the set.

- (A) Anterior horn
- (B) Basal nuclei
- (C) Cerebellum
- (D) Frontal lobe
- (E) Occipital lobe
- (F) Parietal lobe
- (G) Temporal lobe
- (H) Subthalamic nucleus

For each patient described, select the most likely involved neurologic substrate.

57. A 50-year-old policeman complains of a tremor in both hands. This tremor is most obvious at rest. While the man is reaching for an object, the tremor disappears.

58. A 35-year-old tennis player is concerned about weakness in his arms and hands, and he notices a loss of muscle mass in the upper limbs. His muscle stretch reflexes are exaggerated in the lower extremities, and he has muscle twitches in the upper limbs.

Questions 59 to 65

The response options for items 59 to 65 are the same. Select one answer for each item in the set.

- (A) Diencephalon
- (B) Medulla
- (C) Midbrain
- (D) Pons
- (E) Telencephalon

Match each of the following structures with the appropriate part of the brain.

59. Cerebral aqueduct

60. Cranial nerves III and IV

61. Caudate nucleus

62. Optic chiasm

63. Olive and the pyramid

64. Pineal gland

65. Cranial nerves IX, X, and XII

Questions 66 to 70

The response options for items 66 to 70 are the same. Select one answer for each item in the set.

- (A) Astrocytes
- (B) Ependymal cells
- (C) Microglial cells
- (D) Oligodendrocytes
- (E) Schwann cells

Match each of the following descriptions with the most appropriate type of cell.

66. Are derived from the neural crest

67. May myelinate numerous axons

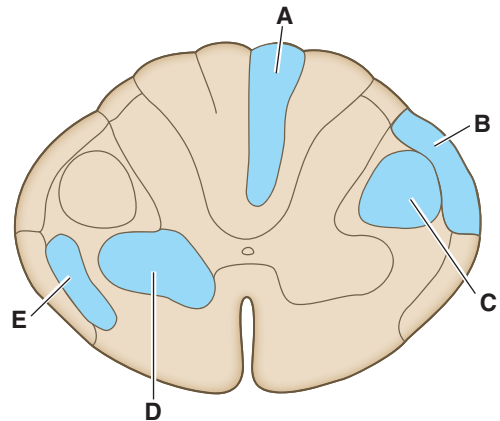
68. Have filaments that contain glial fibrillary acidic protein

69. Myelinate only one internode

70. Arise from monocytes

Questions 71 to 75

Match the descriptions in items 71 to 75 with the appropriate lettered lesion (*shaded area*) in the diagram of a cross-section of the spinal cord.



71. Ipsilateral lower limb dystaxia

72. Ipsilateral flaccid paralysis

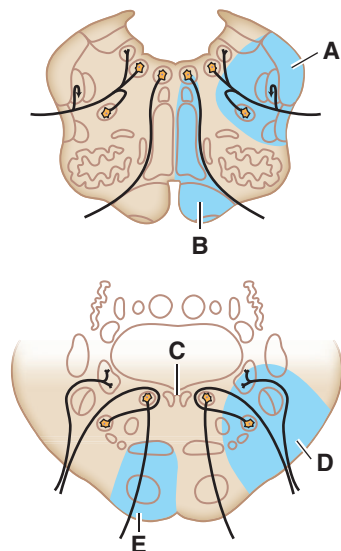
73. Contralateral loss of pain and temperature sensation one segment below the lesion

74. Exaggerated muscle stretch reflexes below the lesion

75. Loss of two-point tactile discrimination in the ipsilateral foot

Questions 76 to 81

Match the descriptions in items 76 to 81 with the appropriate lettered lesion (*shaded area*) shown on one of the two cross-sections of the brainstem.



76. Medial rectus palsy on attempted lateral gaze

77. Lateral rectus paralysis; contralateral spastic hemiparesis

78. Occlusion of the posterior inferior cerebellar artery

79. Loss of the corneal reflex; contralateral loss of pain and temperature sensation from the body and limbs

80. Hemiatrophy of the tongue; contralateral hemiparesis; contralateral loss of vibration sensation

81. Hoarseness, Horner syndrome, singultus

Questions 82 to 87

The response options for items 82 to 87 are the same. Select one answer for each item in the set.

- (A) Anterior thalamic nucleus
- (B) Centromedian nucleus
- (C) Mediodorsal nucleus
- (D) Ventral lateral nucleus
- (E) Ventral posteromedial nucleus

Match each of the following descriptions with the appropriate nucleus.

82. Receives input from the dentate nucleus

83. Receives input of taste sensation from the solitary nucleus

84. Receives input of pain and temperature sensation from the face

85. Receives the mamillothalamic tract

86. Projects to the putamen

87. Has reciprocal connections with the prefrontal cortex

Questions 88 to 93

The response options for items 88 to 93 are the same. Select one answer for each item in the set.

- (A) Anterior nucleus
- (B) Arcuate nucleus
- (C) Mamillary nucleus

(D) Paraventricular nucleus

(E) Suprachiasmatic nucleus

Match each description with the most appropriate hypothalamic nucleus.

88. Receives input from the hippocampal formation

89. Destruction results in hyperthermia

90. Receives input from the retina

91. Projects to the neurohypophysis

92. Regulates the activity of the adenohypophysis

93. Regulates water balance

Questions 94 to 98

The response options for items 94 to 98 are the same. Select one answer for each item in the set.

- (A) Caudate nucleus
- (B) Centromedian nucleus
- (C) Globus pallidus
- (D) Substantia nigra
- (E) Subthalamic nucleus

Match each description with the most appropriate nucleus.

94. Destruction causes contralateral hemiballism

95. Receives dopaminergic input from the midbrain

96. Gives rise to the ansa lenticularis and the lenticular fasciculus

97. Destruction causes hypokinetic rigidity

98. A loss of cells in this griseum causes greatly dilated lateral ventricles

Questions 99 to 105

The response options for items 99 to 105 are the same. Select one answer for each item in the set.

- (A) Acetylcholine
- (B) Dopamine
- (C) Gamma-aminobutyric acid
- (D) Norepinephrine
- (E) Serotonin

Match each of the following nuclei or cells with the appropriate neurotransmitter.

99. Raphe nuclei

100. Purkinje cells

101. Nucleus basalis (of Meynert)

102. Motor cranial nerve nuclei

103. Pars compacta of the substantia nigra

104. Locus ceruleus

105. Globus pallidus

Questions 106 to 110

The response options for items 106 to 110 are the same. Select one answer for each item in the set.

(A) β -Endorphin

(B) Enkephalin

(C) Glutamate

(D) Glycine

(E) Substance P

Match each description with the appropriate neurotransmitter.

106. Neurotransmitter of afferent pain fibers

107. Major inhibitory neurotransmitter of the spinal cord

108. Major neurotransmitter of the corticospinal pathway

109. Located almost exclusively in the hypothalamus

110. Helps inhibit input from afferent pain fibers

Questions 111 to 117

The response options for items 111 to 117 are the same. Select one answer for each item in the set.

(A) Left frontal lobe

(B) Left parietal lobe

(C) Left temporal lobe

(D) Right occipital lobe

(E) Right parietal lobe

Match each of the following neurologic deficits with the most likely lesion site.

111. Left upper quadrantanopia

112. Muscle weakness and clumsiness in the right hand; slow, effortful speech

113. Inability to identify a key placed in the left hand with the eyes closed

114. Denial of hemiparesis: patient ignores stimuli from one side of the body

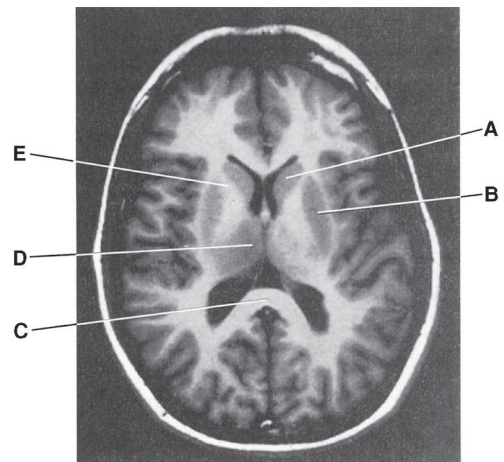
115. Poor comprehension of speech; patient is unaware of the deficit

116. Patient is unable to identify fingers touched by examiner when eyes are closed; is unable to perform simple calculations

117. Babinski sign and ankle clonus

Questions 118 to 122

Match the descriptions in items 118 to 122 with the appropriate lettered structure shown in the magnetic resonance image (MRI) of the axial section of the brain.



118. Thalamus

119. Internal capsule

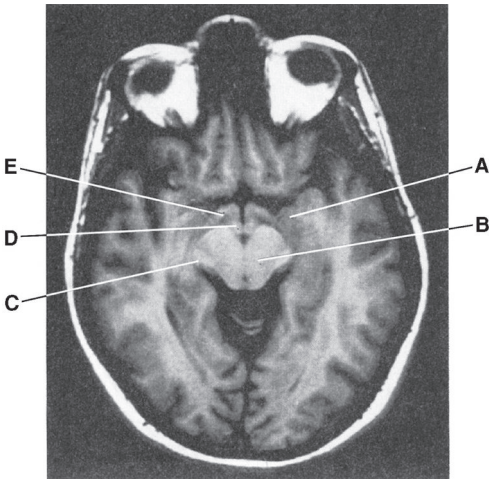
120. Putamen

121. Caudate nucleus

122. Splenium

Questions 123 to 127

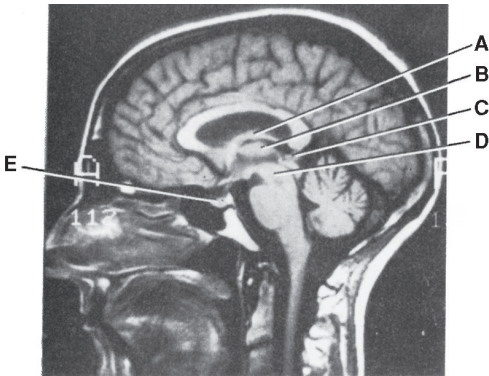
Match the descriptions in items 123 to 127 with the appropriate lettered structure shown in the MRI of the axial section of the brain.



- 123. Medial geniculate body
- 124. Mesencephalon
- 125. Mamillary body
- 126. Optic tract
- 127. Amygdala

Questions 128 to 132

Match the descriptions in items 128 to 132 with the appropriate letter shown in the MRI of the midsagittal section of the brain.



- 128. Pineal gland
- 129. Hypophysis
- 130. Mesencephalon
- 131. Thalamus
- 132. Fornix

Questions 133 to 142

Match the descriptions in items 133 to 142 with the appropriate diagnoses shown in the figure.

A Flashlight swung from right eye to left eye		B 	
C Looking right Looking left Eyes converged		D Looking straight ahead	
E Looking right	F Looking up Eyes converged		G Looking left and down
H No reaction to light Eyes converged		I Eyes of a comatose patient	J

133. Right third-nerve palsy
134. Destructive lesion of the right frontal lobe
135. Argyll Robertson pupil
136. Right fourth-nerve palsy
137. Parinaud syndrome
138. Right sixth-nerve palsy
139. Left third-nerve palsy
140. Internuclear ophthalmoplegia
141. Horner syndrome
142. Retrobulbar neuritis

Questions 143 to 147

The response options for items 143 to 147 are the same. Select one answer for each item in the set.

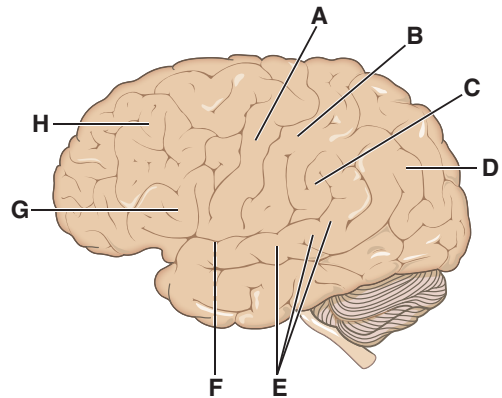
- (A) Anorexia
 (B) Diabetes insipidus
 (C) Hyperphagia and rage
 (D) Hyperthermia
 (E) Inability to thermoregulate

Match each defect below with the condition it best describes.

143. Bilateral lesions of the ventromedial hypothalamic nucleus
144. Bilateral lesions of the posterior hypothalamic nuclei
145. Lesions involving the supraoptic and paraventricular nuclei
146. Destruction of the anterior hypothalamic nuclei
147. Stimulation of the ventromedial nuclei

Questions 148 to 155

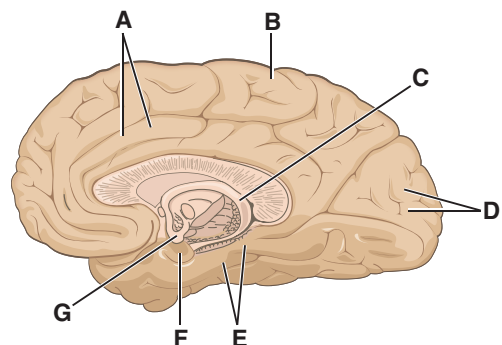
Match the descriptions in items 148 to 155 with the appropriate lettered structure in the figure.



148. Stimulation of this area results in turning the eyes and head to the contralateral side
149. A lesion here results in nonfluent, effortful, telegraphic speech
150. Ablation in this area results in a contralateral upper homonymous quadrantanopia
151. A lesion here results in fluent speech with paraphrastic errors (e.g., non sequiturs, neologisms, driveling speech)
152. A lesion of this area is characterized by finger agnosia, dyscalculia, dysgraphia, and dyslexia
153. Destruction of this area results in an aphasia characterized by fluent speech, good comprehension, and poor repetition
154. Lesions in this gyrus result in contralateral astereognosis
155. Lesions in this gyrus result in contralateral spasticity

Questions 156 to 162

Match the descriptions in items 156 to 162 with the appropriate lettered structure in the figure.



- 156.** In thiamine (vitamin B₁) deficiency, hemorrhagic lesions are found in this structure
- 157.** Bilateral lesions in this structure result in hyperphagia, hypersexuality, and psychic blindness (visual agnosia)
- 158.** Infarction (owing to cardiac arrest) of this area results in short-term memory loss
- 159.** Lesions of this area result in a lower homonymous quadrantanopia
- 160.** Bilateral transection of this structure may result in the acute amnesic syndrome
- 161.** Lesion of this area results in a contralateral extensor plantar reflex and ankle clonus
- 162.** Ablation of this area may result in akinesia, mutism, apathy, and indifference to pain
- 163.** Which of the following arteries perfuses the medullary pyramid?
- (A) Anterior communicating
 - (B) Anterior choroidal
 - (C) Anterior spinal
 - (D) Posterior inferior cerebellar
 - (E) Posterior spinal
- 164.** Which artery supplies the intra-axial fibers of the hypoglossal nerve XII?
- (A) Anterior inferior cerebellar
 - (B) Anterior spinal
 - (C) Basilar
 - (D) Posterior spinal
 - (E) Vertebral
- 165.** A berry aneurysm puts pressure on the optic chiasm in the anteroposterior plane resulting in a bitemporal hemianopia. On which one of the following arteries will aneurysm be most likely found?
- (A) Anterior communicating
 - (B) Anterior spinal
 - (C) Basilar
 - (D) Ophthalmic
 - (E) Posterior communicating
- 166.** A 10-year-old boy was struck on the side of the head with a golf ball. The middle meningeal artery was lacerated. In which space was blood found?
- (A) Confluence of the sinuses
 - (B) Epidural
 - (C) Subarachnoid
 - (D) Subdural
 - (E) Subpial
- 167.** A 25-year-old male student was examined by an ophthalmologist, who observed headaches; ptosis; a fixed, dilated pupil; and an eye that looked down and out. An aneurysm was demonstrated with carotid angiogram anteroposterior projection. Which artery harbored the aneurysm?
- (A) Anterior cerebral
 - (B) Anterior communicating
 - (C) Internal carotid
 - (D) Ophthalmic
 - (E) Posterior communicating
- 168.** Which one of the following arteries irrigates the dentate nucleus?
- (A) Anterior inferior cerebellar
 - (B) Posterior cerebral
 - (C) Posterior inferior cerebellar
 - (D) Superior cerebellar
 - (E) Vertebral
- 169.** A glioma deep to the facial colliculus results in diplopia and horizontal nystagmus on attempted lateral conjugate gaze. Paralysis of which one of the following muscles will explain the neurologic deficits?
- (A) Buccinator
 - (B) Lateral pterygoid
 - (C) Lateral rectus
 - (D) Orbicularis oculi
 - (E) Posterior belly of digastric
- 170.** Which of following Brodmann areas were not accounted for in his list of cytoarchitectonic regions?
- (A) Areas 3, 1, and 2
 - (B) Areas 9, 10, and 11
 - (C) Areas 13–15
 - (D) Areas 32, 23, and 24
 - (E) Areas 39 and 40
- 171.** In adults the choroid plexus of the lateral ventricle is calcified and can be visualized with plain film or computed tomography (CT). Where, within the ventricular system, is the calcified glomus of the choroid plexus?
- (A) Body
 - (B) Frontal horn

- (C) Occipital horn
- (D) Trigone
- (E) Temporal horn

172. Which one of the following circumventricular organs has a blood–brain barrier?

- (A) Area postrema
- (B) Median eminence of the tuber cinereum
- (C) Pineal body
- (D) Subcommissural organ
- (E) Subfornical organ

173. Which artery perfuses the leg area of the motor strip?

- (A) Heubner
- (B) Middle cerebral
- (C) Pericallosal
- (D) Posterior cerebral
- (E) Splenial

174. Which one of the following arteries following bilateral hypoperfusion results in Klüver–Bucy syndrome?

- (A) Anterior choroidal
- (B) Anterior communicating
- (C) Medial striate
- (D) Posterior cerebral
- (E) Posterior choroidal

175. Which of the cranial nerves exits the brainstem from the pontomedullary junction?

- (A) Abducent
- (B) Abducent, facial, and vestibulocochlear
- (C) Facial
- (D) Intermediate
- (E) Vestibulocochlear

176. Which one of the following arteries perfuses the medullary pyramid?

- (A) Anterior choroidal
- (B) Anterior communicating
- (C) Anterior spinal
- (D) Posterior inferior cerebellar
- (E) Posterior spinal

177. Name artery that supplies the intra-axial fibers of the hypoglossal nerve XII.

- (A) Anterior inferior cerebellar
- (B) Anterior spinal
- (C) Basilar
- (D) Posterior spinal
- (E) Vertebral

178. A berry aneurysm puts pressure on the optic chiasma in the anteroposterior plane,

resulting in a bitemporal hemianopia. On which one of the following arteries will the aneurysm be most likely found?

- (A) Anterior communicating
- (B) Internal carotid
- (C) Medial striate
- (D) Ophthalmic
- (E) Posterior communicating

179. Which is an abnormal quantity of white cells per microliter in the cerebrospinal fluid?

- (A) 2
- (B) 3
- (C) 4
- (D) 5
- (E) 8

180. The normal value of cerebrospinal fluid protein in milligrams per deciliter is less than:

- (A) 25.
- (B) 35.
- (C) 45.
- (D) 55.
- (E) 65.

181. Which is an example of a normal value for cerebrospinal fluid serum glucose in milligrams per deciliter?

- (A) 40
- (B) 50
- (C) 60
- (D) 70
- (E) 80

182. A 20-year-old female patient was evaluated by a neurologist. The neurologic examination reveals severe headaches, papilledema without mass, elevated cerebrospinal fluid pressure, and deteriorating vision. The diagnosis will most likely be:

- (A) Arnold Chiari II.
- (B) Dandy–Walker.
- (C) hydrocephalus ex vacuo.
- (D) normal-pressure hydrocephalus.
- (E) pseudotumor cerebri.

183. Through which of the following structures does cerebrospinal fluid enter the subarachnoid space?

- (A) Arachnoid villi
- (B) Cerebral aqueduct
- (C) Intraventricular foramina (of Monro)
- (D) Lateral foramina (of Luschka)
- (E) Third ventricle

184. A 40-year-old man had a stroke and developed ipsilateral paralysis and atrophy of the tongue, contralateral loss of vibration sense, contralateral hemiplegia, and contralateral Babinski sign. Which artery's thrombosis will result in the above mentioned neurologic deficits?

- (A) Anterior inferior cerebellar
- (B) Anterior spinal
- (C) Labyrinthine
- (D) Posterior inferior cerebellar
- (E) Posterior spinal

185. A 10-year-old boy presents with seizures, olfactory hallucinations, and a right upper quadrantanopia. The most likely causative lesion will be:

- (A) aneurysm of the anterior communicating artery.
- (B) Charcot-Bouchard aneurysm.
- (C) frontal lobe astrocytoma.
- (D) olfactory groove meningioma.
- (E) temporal lobe astrocytoma.

186. A 60-year-old high school teacher has up-going toes and spastic paralysis of all limbs and intact sensibility. Where is the corresponding lesion site in this case?

- (A) Base of pons, abducent nucleus
- (B) Base of pons, trigeminal nucleus
- (C) Closed medulla
- (D) Midbrain, inferior colliculus
- (E) Open medulla

187. The optic cup is an evagination of which of the following?

- (A) Diencephalon
- (B) Mesencephalon
- (C) Metencephalon
- (D) Myelencephalon
- (E) Telencephalon

188. General somatic afferent fibers are primarily concerned with conveying sensory input:

- (A) relating to vision, audition, and equilibrium.
- (B) relating to information from visceral organs.
- (C) relating to taste and smell.
- (D) relating to vision.
- (E) from skin, muscle, bone, and joints.

189. From what part of the neural tube is the spinal cord derived?

- (A) Anterior neuropore
- (B) Caudal
- (C) Cavity
- (D) Cranial
- (E) Posterior neuropore

190. Which one of the following basal nuclei is derived from the diencephalon?

- (A) Amygdala
- (B) Globus pallidus
- (C) Head of the caudal nucleus
- (D) Putamen
- (E) Tail of the caudal nucleus

191. Which of the following represents the general somatic efferent column of the pons?

- (A) Abducent nucleus
- (B) Hypoglossal nucleus
- (C) Inferior olivary nucleus
- (D) Inferior salivatory nucleus
- (E) Nucleus ambiguus

192. Which of the following represents the general visceral efferent column of the pons?

- (A) Cerebellum
- (B) Chief trigeminal nucleus
- (C) Pontine nuclei
- (D) Spinal trigeminal nucleus
- (E) Superior salivatory nucleus

193. When are the axons of the corticospinal tracts fully myelinated?

- (A) At birth
- (B) By the end of the first postnatal year
- (C) By the end of the second postnatal year
- (D) In the late embryonic period
- (E) In the midfetal period

194. The cochlear duct contains the spiral organ of Corti and is derived from:

- (A) both ectoderm and mesoderm.
- (B) ectoderm.
- (C) endoderm.
- (D) mesoderm.
- (E) neural crest.

195. The stapedius that moves the stapes is innervated by:

- (A) Cervical nerves C₂ and C₃.
- (B) CN III.

- (C) CN V.
- (D) CN VII.
- (E) CN XII.

196. Which one of the following is a classic cerebellar sign?

- (A) Athetosis
- (B) Chorea
- (C) Cogwheel rigidity
- (D) Hemiballismus
- (E) Intention tremor

197. Which one of the following spinocerebellar tracts shows the phenomenon of doubling?

- (A) Anterior spinocerebellar tract
- (B) Cuneocerebellar tract
- (C) Olivocerebellar tract
- (D) Posterior spinocerebellar tract
- (E) Trigemino-cerebellar fibers

198. Which of the followings triads of cranial nerves is damaged if the muscles attached to the styloid process are paralyzed?

- (A) V, IX, and X
- (B) VII, IX, and X
- (C) VII, IX, and XII
- (D) VII, X, and XII
- (E) X, XI, and XII

199. A 25-year-old man was involved in a car accident. The emergency department physician noticed clear fluid dribbling from the nose. Rhinorrhea will most likely result from a fracture of:

- (A) ethmoid bone.
- (B) frontal bone.
- (C) lacrimal bone.
- (D) nasal bone.
- (E) palatine bone.

200. Horseradish peroxidase is injected into the circumvallate papillae on the anterior two-thirds of the tongue for retrograde transport labeling. In which of the following way stations will marker be found?

- (A) Geniculate ganglion
- (B) Medial dorsal nucleus of the thalamus

- (C) Nodose ganglion
- (D) Petrosal ganglion
- (E) Ventroposterior lateral nucleus of the thalamus

201. To which one of the following nerves does trauma to the foramen rotundum cause damage?

- (A) Mandibular
- (B) Maxillary
- (C) Ophthalmic
- (D) Optic
- (E) Trochlear

202. An optic glioma is found in the optic canal. Which structures will most likely be damaged by the invasive tumor?

- (A) Ophthalmic artery and ophthalmic vein
- (B) Ophthalmic nerve and optic nerve
- (C) Ophthalmic vein and ophthalmic nerve
- (D) Optic nerve and ophthalmic artery
- (E) Optic nerve and ophthalmic vein

203. A 60-year-old hypertensive woman complained of facial numbness on the right side including the tongue. A cortical lesion was seen with MRI. Where will the lesion most likely be found?

- (A) Anterior paracentral lobule
- (B) Middle frontal gyrus
- (C) Postcentral gyrus
- (D) Posterior paracentral lobule
- (E) Precentral gyrus

204. A 20-year-old woman is examined by a neurologist. The patient presents initially with spastic paresthesia and double vision; additional neurologic deficits and signs are optic neuritis, internuclear ophthalmoplegia, urinary urgency, scanning speech, and Lhermitte sign. Match the neurologic deficits and signs to the syndromes.

- (A) Amyotrophic lateral sclerosis
- (B) Brown-Séquard syndrome
- (C) Multiple sclerosis
- (D) Poliomyelitis
- (E) Syringomyelia

Answers and Explanations

1–A. The calcarine sulcus separates the cuneus from the lingual gyrus. The banks of the calcarine sulcus contain the visual cortex.

2–D. The superior sagittal sinus receives drainage from the greatest number of arachnoid granulations.

3–C. The Rathke pouch is an ectodermal outpocketing of the stomodeum anterior to the buccopharyngeal membrane. It gives rise to the adenohypophysis (pars distalis, pars tuberalis, and pars intermedia).

4–C. The lateral horn (T1–L2) gives rise to preganglionic sympathetic fibers.

5–E. The dorsal nucleus (of Clarke; T1–L2) gives rise to the posterior spinocerebellar tract that ascends and enters the cerebellum through the inferior cerebellar peduncle.

6–D. In the midbrain, the pyramidal tract lies in the basis pedunculi; oculomotor fibers of CN III pass through the medial part of the basis pedunculi. In the pons, the pyramidal tract lies in the base of the pons; abducent fibers pass through the lateral part of the pyramidal fasciculi. In the medulla, the pyramidal tracts form the medullary pyramids; hypoglossal fibers of CN XII lie just lateral to the pyramids.

7–E. The primary auditory cortex (areas 41 and 42) is located in the transverse temporal gyri of Heschl, a part of the superior temporal gyrus.

8–E. The neocerebellum (the posterior lobe minus the vermis and the paravermis) sends input to the motor cortex through the ventral lateral nucleus of the thalamus. The pathway is the neocerebellar cortex, dentate nucleus, contralateral ventral lateral nucleus of the thalamus, and motor cortex (area 4).

9–A. The dentatothalamic tract decussates in the caudal midbrain tegmentum at the level of the inferior colliculus. This massive decussation of the superior cerebellar peduncles is characteristic of this level.

10–C. Pituitary tumors frequently compress the decussating fibers of the optic chiasm and produce a bitemporal hemianopia. Nasal fibers decussate, and temporal fibers remain ipsilateral.

11–E. Resection of the anterior portion of the temporal lobe transects the fibers of the Meyer's loop and results in a contralateral upper homonymous quadrantanopia. Inferior retinal quadrants are represented in the inferior banks of the calcarine sulcus.

12–A. Headache and papilledema are signs of brain tumor, and pronator drift is a frontal lobe sign owing to weakness of the supinator. Tumor pressure on the corticospinal tract results in contralateral spastic hemiparesis. In progressive supranuclear palsy, the patient cannot look down. In myasthenia gravis, there is skeletal muscle weakness. In pseudotumor cerebri, there are no mass lesions but headache and papilledema. In subacute combined degeneration, the posterior columns and the corticospinal tracts are affected.

13–C. The lateral corticospinal tract and the lateral spinothalamic tract are both found in the lateral funiculus. Transection of the corticospinal tract results in ipsilateral paresis, and transection of the spinothalamic tract results in contralateral loss of pain and temperature sensation. Pallesthesia (vibration sense) is normal.

14–A. The contralateral oculomotor nerve is responsible for the consensual reaction.

- 15–C.** Hyperacusis is increased acuity of hearing and undue sensitivity to low tones. It results from paralysis of the stapedius (CN VII). The stapedius reduces the amplitude of sound vibrations of the stapes in the oval window.
- 16–D.** The mandibular division of the trigeminal nerve (CN V₃) innervates the muscles of mastication (e.g., masseter) and mediates the tactile sensation of the anterior two-thirds of the tongue. The glossopharyngeal nerve (CN IX) provides the tactile, nociceptive, and taste innervation of the posterior third of the tongue. The facial nerve (CN VII) provides taste innervation to the anterior two-thirds of the tongue.
- 17–B.** This is the classic lateral medullary syndrome, which is also known as Wallenberg syndrome (see Figure 12.1B).
- 18–B.** This is a classic medial midbrain lesion characteristic of Weber syndrome. It includes the crus cerebri and the exiting intra-axial fibers of the oculomotor nerve (see Figure 12.3C).
- 19–A.** The metal fragment is found between the inferior frontal gyrus and the supramarginal gyrus. The two gyri are connected by the arcuate fasciculus; transection results in conduction aphasia. The arcuate fasciculus interconnects Broca area and Wernicke area. The key deficit is the inability to repeat (see Figure 22.6).
- 20–D.** Norepinephrine is the neurotransmitter of postganglionic sympathetic neurons, with the exception of sweat glands and some blood vessels that receive cholinergic sympathetic innervation. Epinephrine is produced by the chromaffin cells of the adrenal medulla.
- 21–D.** Bilateral damage of the medial temporal gyri, including the amygdalae, can cause severe memory loss. Such damage to the amygdalae may lead to inappropriate social behavior (e.g., hyperphagia, hypersexuality, general disinhibition). Bilateral destruction of the amygdalae results in Klüver-Bucy syndrome.
- 22–E.** Presbyopia is progressive loss of the ability to accommodate, the decreased ability to focus on near objects. Astigmatism is the difference in refracting power of the cornea and lens in different meridians. Cataracts are opacities that appear with aging. Optic atrophy is degeneration of the optic nerve and papillomacular bundle and loss of central vision.
- 23–E.** The corticospinal fibers are not completely myelinated at birth; this does not occur until 18 months to 2 years of age. During this time, the Babinski reflex can be elicited; later it is suppressed.
- 24–C.** The nucleus of the solitary tract receives taste fibers from cranial nerves VII, IX, and X. Neurons of this tract project to the ventral posteromedial nucleus of the thalamus.
- 25–E.** The supplementary motor cortex plans for motor activity. Broca's area is a language center. The angular gyrus is concerned with mnemonic constellations. The motor strip gives rise to the corticospinal and corticobulbar tracts. The S-1 somatosensory cortex subserves somatic sensibility.
- 26–E.** Destruction of the right cuneate nucleus results in apallesthesia (loss of vibration sensation) in the right hand. The cuneate nucleus, a way station in the posterior column–medial lemniscus pathway, mediates tactile discrimination and vibration sensation.
- 27–E.** Eccrine sweat glands are innervated by postganglionic sympathetic cholinergic fibers. Apocrine sweat glands are innervated by postganglionic sympathetic norepinephrinergic fibers.
- 28–E.** The vagal nerves mediate the feeling of nausea via general visceral afferent fibers.
- 29–A.** Cerebrospinal fluid enters the bloodstream via the arachnoid villi. Hypertrophied arachnoid villi are called arachnoid granulations or pacchionian bodies.
- 30–B.** Aqueductal stenosis results in enlargement of the third and lateral ventricles. The condition is strongly associated with prenatal infections (e.g., cytomegalovirus infection). Congenital hydrocephalus occurs in 1 in 1000 live births. Mental retardation, spasticity, and tremor are common. Shunting is the treatment of choice; cerebrospinal fluid is shunted from the distended ventricle to the peritoneal cavity.

31–E. Alzheimer disease is commonly seen in trisomy 21, or Down syndrome, after 40 years of age. It is the commonest single cause of mental retardation. The neuropathology of Down syndrome is similar to that of Alzheimer disease: Reduced choline acetyltransferase activity, cell loss in the nucleus basalis of Meynert, an increase of amyloid β -protein, and Alzheimer neurofibrillary changes and neuritic plaques are found.

32–B. This describes classic Guillain–Barré syndrome, with prior infection, ascending paralysis, distal paresthesias, and albuminocytologic dissociation.

33–C. This is a classic description of multiple sclerosis. Characteristics of the condition are exacerbations and remissions, involvement (demyelination) of long tracts, blurred vision, and an afferent pupillary defect. Cerebrospinal fluid contains electrophoretically detectable oligoclonal immunoglobulin (oligoclonal bands). In addition, rates of synthesis and concentration of intrathecally generated immunoglobulin G and immunoglobulin M in the cerebrospinal fluid are elevated. Oligoclonal bands are also found in syphilis, meningoenzephalitis, subacute sclerosing panencephalitis, and Guillain–Barré syndrome.

34–E. Proliferating Schwann cells may give rise to schwannomas, which are also called acoustic neuromas or neurilemmomas.

35–E. Hemisection of the spinal cord would result in ipsilateral spastic paresis below the lesion and loss of pain and temperature on the contralateral side. The plantar response would be extensor and ipsilateral (Babinski sign).

36–E. A lesion of the vestibular nuclei eliminates oculovestibular reflexes.

37–B. An anticholinergic agent (e.g., trihexyphenidyl) may be used as an alternative to l-dopa to alleviate the chemical imbalance found in the striatum of a patient with Parkinson disease.

38–C. Fluoxetine (Prozac) is the most selective inhibitor of serotonin reuptake.

39–B. The paramedian (transverse pontine) branches of the basilar artery supply the medial longitudinal fasciculus of the pons. Destruction of this fasciculus results in medial longitudinal fasciculus syndrome, or internuclear ophthalmoplegia. In addition, the superior cerebellar artery may irrigate the medial longitudinal fasciculus.

40–A. Lateral medullary syndrome, also called Wallenberg syndrome; symptoms include contralateral loss of pain and temperature sensation from the face, loss of gag reflex, hemiataxia and hemiasynergia of cerebellar type, Horner's syndrome, and ipsilateral nystagmus. The affected structures are the medial and inferior vestibular nuclei, inferior cerebellar peduncle, nucleus ambiguus of CN IX and CN X (somatic visceral efferent), glossopharyngeal nerve roots, vagal nerve roots, spinothalamic tracts, the spinal trigeminal nucleus and tract, and the descending sympathetic tract.

41–A. A lesion of the upper left retinal quadrant in the left eye would show radioactive label in the left cuneus. Lesions of the cuneus result in lower field defects, and lesions of the lingual gyrus result in upper field defects. Remember the upper retinal quadrants project to the upper banks of the calcarine fissure, whereas the lower retinal quadrants project to the lower banks of the calcarine fissure.

42–B. The dentate nucleus receives massive input from the contralateral inferior olivary nucleus; it projects crossed fibers to the ventral lateral nucleus of the thalamus and red nucleus (parvocellular part). The lateral cuneate nucleus gives rise to the cuneocerebellar tract, and the lateral lemniscus and its nuclei are important way stations in the auditory pathway.

43–B. The right ventral posterolateral nucleus receives posterior column modalities via the medial lemniscus from the left side of the body. The nucleus ruber is a midbrain motor nucleus: it plays a role in the control of flexor tone. The lateral cuneate nucleus projects unconscious proprioception to the cerebellum, (e.g., from muscles and tendons). The ventral lateral nucleus receives input from the cerebellum (dentate nucleus).

44–A. The nucleus of the inferior colliculus projects retrograde to the inferior olivary nucleus of the caudal pons. The medial geniculate nucleus is an auditory way station, the inferior olivary

nucleus is a cerebellar relay station, and the transverse gyrus of Heschl is a primary auditory center. Retrograde transport studies show that horseradish peroxidase is picked up by the axon terminals and transported to the perikarya; anterograde studies show that labeled amino acids are taken up by the perikarya and transported anterograde to distant nuclei.

45–D. The base of the pons contains intra-axial root fibers of CN V, corticobulbar fibers to nucleus CN XII, and corticospinal fibers. Spinotrigeminal fibers mediate pain and temperature sensation from the ipsilateral face.

46–C. The open medulla contains the medial lemniscus bilateral and root fibers of CN XII bilateral. Deficits to the medial lemniscus will result in contralateral loss of proprioception, discriminative tactile sensation, and vibration sensation from the trunk and lower extremity. The medulla gives rise to CN IX, CN X, and CN XII; CN XII controls movement of the tongue.

47–D. The pontine tegmentum contains CN VI and CN VII; the medial longitudinal fasciculus (MLF), medial lemniscus, spinotrigeminal nucleus and tract; spinothalamic tract; and the spinothalamic tract (Horner syndrome). Internuclear ophthalmoplegia, also known as MLF syndrome, results from a lesion of the MLF. Lesions occur in the dorsomedial pontine tegmentum and may affect one or both MLFs. This is a frequent sign of multiple sclerosis; it results in medial rectus palsy on attempted lateral gaze and monocular nystagmus in the abducting eye with normal convergence.

48–B. Thrombosis of the anterior spinal artery results in the medial medullary syndrome. Symptoms of medial medullary syndrome include contralateral hemiparesis of the trunk and extremities; contralateral loss of proprioception, discriminative tactile sensation, and vibration sensation from the trunk and extremities; and ipsilateral flaccid paralysis of the tongue.

49–E. Wernicke speech area is in the posterior superior temporal gyrus (Brodmann's area 22). Wernicke aphasia is characterized by faster-than-normal speech, difficulty finding the right words to express ideas, and poor comprehension of the speech of others. Patients appear unaware of the deficit.

50–C. Pick disease—frontotemporal lobar degeneration—shows an extreme degree of atrophy in the temporal and frontal lobes. Creutzfeldt–Jakob is a human prion disease affecting the central nervous system. Down syndrome is a chromosomal anomaly characterized by trisomy 21. Tuberous sclerosis and Sturge–Weber syndrome are neurocutaneous diseases that result in lesions of the skin and neurologic problems (e.g. mental retardation, seizures).

51–A. The arcuate fasciculus (superior longitudinal fasciculus) is a fiber trajectory that interconnects Broca speech area (44 and 45) with Wernicke speech area (22). Transection of this fiber bundle results in conduction aphasia with poor repetition of spoken language, relatively good speech comprehension and expression, paraphrastic errors (using incorrect words), and impaired object naming. Patients are aware of the deficit.

52–E. The pineal body is a midline diencephalic structure that contains calcium concretions; it is seen in computed tomographic images. The cerebral peduncles, the superior and inferior colliculi, the oculomotor nerves, and the cerebral aqueduct are found in the midbrain. Stenosis of the aqueduct results in noncommunicating hydrocephalus.

53–H. The optic nerve is derived from the wall of the diencephalic vesicle.

54–F. The oculomotor nerve is often damaged in the process of transtentorial herniation.

55–K. The vagus nerve mediates the sensory and motor innervation of the pharyngeal arches 4 and 6.

56–J. The trochlear nerve innervates the muscle that depresses, intorts, and abducts the globe.

57–B. Parkinson disease is characterized by a triad of symptoms: pill-rolling tremor, rigidity, and hypokinesia. The substantia nigra (a basal nucleus) bears the brunt of the cell loss. Cerebellar disease is characterized by intention tremor, ataxia, and hypotonia. Destruction of the subthalamic nucleus results in contralateral hemiballismus.

58–A. In amyotrophic lateral sclerosis there is loss of both anterior horn cells and cortical pyramidal cells that give rise to the pyramidal tract. This motor system disease consists of an upper motor neuron component and a lower motor neuron component. There are no sensory deficits in amyotrophic lateral sclerosis.

59–C. The cerebral aqueduct is in the midbrain (mesencephalon). It interconnects the third and fourth ventricles.

60–C. The tegmentum of the midbrain contains the nuclei of the oculomotor nerve (CN III) and the trochlear nerve (CN IV). The midbrain also contains the mesencephalic nucleus of the trigeminal nerve (CN V).

61–E. The caudate nucleus, a basal nucleus, is located in the white matter of the telencephalon. It forms the lateral wall of the frontal horn of the lateral ventricle.

62–A. The optic chiasma is in the diencephalon between the anterior commissure and the infundibulum of the pituitary gland (hypophysis).

63–B. The olive and the pyramid are prominent structures on the surface of the medulla. The olive contains the inferior olivary nucleus. The pyramid contains the corticospinal tract.

64–A. The pineal gland is part of the epithalamus—a subdivision of the diencephalon.

65–B. Cranial nerves IX, X, and XII are located in the medulla.

66–E. Schwann cells of the peripheral nervous system are neural crest derivatives.

67–D. Oligodendrocytes of the central nervous system can myelinate numerous axons. Schwann cells myelinate only one internode.

68–A. The filaments of astrocytes contain fibrillary glial acidic protein, a marker for astrocytes and astrocytic tumor cells. Another biochemical marker is glutamine synthetase found exclusively in astrocytes.

69–E. Schwann cells are myelin-forming cells of the peripheral nervous system. They myelinate only one internode and are derived from the neural crest. Schwann cells function in regeneration and remyelination of severed axons in the peripheral nervous system but may proliferate to form schwannomas, benign tumors of peripheral nerves (e.g., acoustic neuromas of CN VIII).

70–C. Microglial cells arise from monocytes. They are phagocytes of the central nervous system.

71–B. Interruption of the posterior spinocerebellar tract results in ipsilateral lower limb dys-taxia (i.e., incoordination). The cerebellum is deprived of its muscle spindle input from the lower extremity.

72–D. Destruction of anterior horn cells (lower motor neurons) results in ipsilateral flaccid paralysis with muscle atrophy and loss of muscle stretch reflexes (areflexia).

73–E. Interruption of the lateral spinothalamic tract results in a contralateral loss of pain and temperature sensation one segment below the lesion. The decussation occurs in the anterior white commissure in the spinal cord.

74–C. Interruption of the lateral corticospinal tract results in an ipsilateral upper motor neuron lesion. It is characterized by exaggerated muscle stretch reflexes (hyperreflexia), spastic paresis, muscle weakness, loss or diminution of superficial reflexes (i.e., abdominal and cremaster reflexes), and the Babinski sign. The deficits are below the lesion on the same side. The lateral corticospinal tract decussates in the caudal medulla.

75–A. A lesion of the gracile fasciculus results in a loss of two-point tactile discrimination in the ipsilateral foot. The posterior column–medial lemniscus pathway decussates in the caudal medulla.

76–C. This lesion includes the two medial longitudinal fasciculi. The patient has medial longitudinal fasciculus syndrome and medial rectus palsy on attempted lateral gaze to either side. Convergence remains intact.

77-E. This lesion includes three major structures: the medial lemniscus, corticospinal fibers, and exiting abducent root fibers (CN VI) traversing the corticospinal fibers. Interruption of the abducent fibers causes ipsilateral lateral rectus paralysis with medial strabismus. Damage to the uncrossed corticospinal fibers results in contralateral spastic hemiparesis.

78-A. Occlusion of the posterior inferior cerebellar artery (PICA) infarcts the lateral zone of the medulla, causing PICA syndrome. The major involved structures are the inferior cerebellar peduncle, spinal trigeminal tract and nucleus, spinal lemniscus, nucleus ambiguus, and exiting fibers of CN X.

79-D. This lesion includes the facial motor nucleus and its intra-axial fibers, hence the loss of the corneal reflex (efferent limb). The spinal trigeminal tract and nucleus and the spinal lemniscus are also damaged by this lesion. Damage to the spinal trigeminal tract and nucleus causes ipsilateral facial anesthesia, including loss of the corneal reflex (afferent limb). Damage to the spinal lemniscus (lateral spinothalamic tract) causes a contralateral loss of pain and temperature sensation from the body and extremities.

80-B. This lesion damages the hypoglossal nucleus and exiting root fibers, the medial lemniscus, and the corticospinal tract. Damage to the hypoglossal nerve results in an ipsilateral flaccid paralysis of the tongue, a lower motor neuron lesion. Damage to the medial lemniscus results in a contralateral loss of tactile discrimination and vibration sensation. Damage to the corticospinal (pyramid) tracts results in contralateral spastic hemiparesis. This symptom complex is known as medial medullary syndrome.

81-A. Lateral medullary syndrome (posterior inferior cerebellar artery syndrome) usually includes hoarseness, Horner syndrome, and singultus (hiccups). Damage to the nucleus ambiguus causes flaccid paralysis of the muscle of the larynx with hoarseness (dysphonia and dysarthria). Interruption of descending autonomic fibers to the ciliospinal center at T1 causes sympathetic paralysis of the eye (Horner syndrome). The anatomic causes of singultus are not clear.

82-D. The ventral lateral nucleus receives input from the dentate nucleus of the cerebellum and projects to the motor cortex (area 4). The ventral posterolateral nucleus also receives input from the dentate nucleus and projects to the motor cortex.

83-E. The ventral posteromedial nucleus receives input of taste sensation from the solitary nucleus of the medulla and pons and projects this input to the gustatory cortex of the parietal operculum (area 43).

84-E. The ventral posteromedial nucleus receives general somatic afferent input from the face, including pain and temperature sensation. It also receives special visceral afferent taste sensation) input from the tongue, palate, and epiglottis.

85-A. The anterior thalamic nucleus receives input from the mamillary nucleus via the mamillo-thalamic tract and direct input from the hippocampal formation via the fornix. The anterior nucleus projects, via the anterior limb of the internal capsule, to the cingulate gyrus (areas 23, 24, and 32).

86-B. The centromedian nucleus, the largest of the intralaminar nuclei, projects to the putamen and to the motor cortex. The centromedian nucleus receives input from the globus pallidus and the motor cortex (area 4).

87-C. The dorsomedial nucleus of the thalamus, or the mediodorsal nucleus, has reciprocal connections with the prefrontal cortex (areas 9-12).

88-C. The mamillary nucleus receives input from the hippocampal formation (i.e., subiculum) via the fornix.

89-A. The anterior nucleus of the hypothalamus helps prevent a rise in body temperature by activating processes that favor heat loss (e.g., vasodilation of cutaneous blood vessels, sweating). Lesions of this nucleus result in hyperthermia (hyperpyrexia).

90-E. The suprachiasmatic nucleus receives direct input from the retina; it plays a role in the maintenance of circadian rhythms.

91–D. The neurons of the paraventricular and supraoptic nuclei of the hypothalamus produce antidiuretic hormone (vasopressin) and oxytocin. These peptides are transported via the supraopticohypophyseal tract to the neurohypophysis. Lesions of these nuclei or their hypophyseal tract result in diabetes insipidus.

92–B. The neurons of the arcuate nucleus (infundibular nucleus) produce hypothalamic-releasing and release-inhibiting hormones, which are conveyed to the adenohypophysis through the hypophyseal portal system. These hormones regulate production of adenohypophyseal hormones and their release into the systemic circulation.

93–D. The paraventricular and supraoptic nuclei produce antidiuretic hormone, which helps regulate water balance in the body.

94–E. Hemiballism results from circumscribed lesions of the subthalamic nucleus.

95–A. The caudate nucleus and the putamen (neostriatum) receive dopaminergic input from the pars compacta of the substantia nigra—the nigrostriatal tract.

96–C. Neurons of the globus pallidus give rise to the ansa lenticularis and the lenticular fasciculus, two pathways that project to the ventral anterior, ventral lateral, and centromedian nuclei of the thalamus.

97–D. Destruction or degeneration of the substantia nigra results in parkinsonism.

98–A. In Huntington chorea, there is a loss of neurons in the striatum. Cell loss in the head of the caudate nucleus causes dilation of the frontal horn of the lateral ventricle (hydrocephalus ex vacuo), which is visible on CT and MRI studies.

99–E. Serotonin (5-HT) is produced by neurons located in the raphe nuclei. This paramedian column of cells extends from the caudal medulla to the rostral midbrain.

100–C. Purkinje neurons are GABA-ergic. GABA-ergic neurons are also found in the striatum, globus pallidus, and pars reticularis of the substantia nigra.

101–A. The nucleus basalis of Meynert contains cholinergic neurons that project to the entire neocortex.

102–A. Acetylcholine is the neurotransmitter of motor cranial nerves (general somatic efferent, special visceral efferent, and general visceral efferent) and anterior horn cells of the spinal cord.

103–B. Neurons of the pars compacta of the substantia nigra contain dopamine. Dopamine is present also in the ventral tegmental area of the midbrain, the superior colliculus, and the arcuate nucleus of the hypothalamus.

104–D. The locus ceruleus is the largest assembly of noradrenergic (norepinephrinergic) neurons in the brain. It is located in the lateral pontine and midbrain tegmenta. Locus ceruleus neurons project to the entire neocortex and cerebellar cortex.

105–C. The globus pallidus contains GABA-ergic neurons that project to the thalamus and subthalamic nucleus.

106–E. Substance P is contained in spinal ganglion cells and is the neurotransmitter of afferent pain fibers. Substance P also is produced by striatal neurons, which project to the globus pallidus and substantia nigra.

107–D. Glycine is the major inhibitory neurotransmitter of the spinal cord. The Renshaw interneurons of the spinal cord are glycinergic.

108–C. Glutamate is the major excitatory neurotransmitter of the brain; neocortical glutamatergic neurons project to the caudate nucleus and the putamen (striatum).

109–A. β -Endorphinergic neurons are located almost exclusively in the hypothalamus (arcuate and premammillary nuclei).

110–B. Enkephalinergic neurons in the posterior horn of the spinal cord presynaptically inhibit the spinal ganglion cells that mediate pain impulses.

111–D. A lesion of the lingual gyrus of the right occipital lobe can cause a left upper homonymous quadrantanopia. Lower retinal quadrants are represented in the lower banks of the calcarine sulcus.

112–A. A lesion of the Broca speech area (areas 44 and 45) and the adjacent motor cortex of the precentral gyrus (area 4) can cause Broca expressive aphasia and an upper motor neuron lesion involving the hand area of the motor strip. This territory is supplied by the superior division of the middle cerebral artery (prerolandic and rolandic arteries).

113–E. A parietal lesion in the right postcentral gyrus (areas 3, 1, and 2) or in the right superior parietal lobule (areas 5 and 7) can cause astereognosis, the deficit in which a patient with eyes closed cannot identify a familiar object placed in the left hand. This territory is supplied by the superior division of the middle cerebral artery (the rolandic and anterior parietal arteries). The dorsal aspect of the superior parietal lobule on the convex surface is also supplied by the anterior cerebral artery.

114–E. Characteristic signs of damage to the nondominant hemisphere include hemineglect, topographic memory loss, denial of deficit (anosognosia), and construction and dressing apraxia. A lesion in the right inferior parietal lobule could account for these deficits. This territory is supplied by the inferior division of the middle cerebral artery (posterior parietal and angular arteries).

115–C. Wernicke receptive aphasia is characterized by poor comprehension of speech, unawareness of the deficit, and difficulty finding the correct words to express a thought. The Wernicke speech area is found in the posterior part of the left superior temporal gyrus (area 22). This territory is supplied by the inferior division of the middle cerebral artery (posterior temporal branches).

116–B. Gerstmann syndrome includes left–right confusion, finger agnosia, dysgraphia, and dyscalculia. This syndrome results from a lesion of the left angular gyrus of the inferior parietal lobule. This territory is supplied by branches from the inferior division of the middle cerebral artery (angular and posterior parietal arteries).

117–A. A lesion of the anterior paracentral lobule results in an upper motor neuron lesion (spastic paresis) involving the contralateral foot. Ankle clonus, exaggerated muscle stretch reflexes, and the Babinski sign are common.

118–D. The thalamus.

119–E. The anterior limb of the internal capsule.

120–B. The putamen.

121–A. The head of the caudate nucleus.

122–C. The splenium of the corpus callosum.

123–C. The medial geniculate body.

124–B. The mesencephalon.

125–D. The mamillary body.

126–E. The optic tract.

127–A. The amygdala (amygdaloid nuclear complex).

128–C. The pineal gland (epiphysis).

129–E. The hypophysis (pituitary gland).

130–D. The mesencephalon (midbrain).

131–B. The thalamus.

132–A. The fornix.

133–J. A right third-nerve palsy with complete ptosis. The ptosis results from paralysis of the levator palpebrae.

134–I. A destructive lesion of the frontal eye fields results in a deviation of the eyes toward the lesion. An irritative lesion results in deviation of the eyes away from the lesion.

135–H. The Argyll Robertson pupil is characterized by irregular miotic pupils that do not respond to light but do converge in response to accommodation. It is a sign of tertiary syphilis.

136–G. A right fourth-nerve palsy is characterized by the inability of the patient to depress the globe from the adducted position.

137–F. Parinaud syndrome is characterized by inability to perform upward or downward conjugate gaze and may be associated with ptosis and pupillary abnormalities.

138–E. A right sixth-nerve palsy is characterized by inability to abduct the eye.

139–D. A third-nerve palsy is characterized by a down-and-out eye, complete ptosis, and a dilated (blown) pupil. The lid was retracted to view the pupil.

140–C. Internuclear ophthalmoplegia results from a lesion of one or both medial longitudinal fasciculi. Transection of the right medial longitudinal fasciculus results in medial rectus palsy on attempted lateral gaze to the left. Convergence is normal, and nystagmus is seen in the abducting eye.

141–B. Horner syndrome consists of miosis, mild ptosis, hemianhidrosis, and enophthalmos. It results from loss of sympathetic input to the head.

142–A. Retrobulbar neuritis is an inflammation of the optic nerve that reduces the light-carrying ability of the nerve. This condition can be diagnosed by the swinging flashlight test. Light shown into the normal eye results in constriction of both pupils. Swinging the flashlight to the affected eye results in a dilated pupil in both eyes. This pupil is called an afferent, or Marcus Gunn, pupil.

143–C. A bilateral lesion of the ventromedial hypothalamic nucleus results in hyperphagia and savage behavior.

144–E. A bilateral lesion of the posterior hypothalamic nucleus results in the inability to thermoregulate (poikilothermia). Bilateral destruction of only the posterior aspect of the lateral hypothalamic nucleus results in anorexia and emaciation.

145–B. Lesions involving the supraoptic and paraventricular nuclei or the supraopticohypophyseal tract result in diabetes insipidus with polydipsia and polyuria.

146–D. Destruction of the anterior hypothalamic nuclei results in hyperthermia.

147–A. Stimulation of the ventromedial nuclei inhibits the urge to eat, resulting in emaciation (cachexia). Whereas, destruction of the ventromedial nuclei results in hyperphagia and savage behavior.

148–H. Stimulation of the frontal eye field (Brodmann area 8) results in turning of the eyes and head to the contralateral side.

149–G. A lesion of the Broca speech area (Brodmann areas 44 and 45) results in nonfluent, effortful, and telegraphic speech as well as Broca aphasia.

150–F. Ablation of the anterior third of the temporal lobe interrupts Meyer's loop, which projects to the lingual gyrus (the lower bank of the calcarine fissure). The lower bank of the calcarine fissure represents the upper visual field. This lesion results in a contralateral upper homonymous quadrantanopia.

151–E. A lesion destroying the Wernicke area (Brodmann 22) is Wernicke aphasia—characterized by poor comprehension, fluent speech, poor repetition, and paraphasic errors (non sequiturs, neologisms, and driveling speech [meaningless double talk]).

152–D. This constellation of dominant hemispheric deficits results from destruction of the angular gyrus (Brodmann area 39). Called Gerstmann syndrome, it is characterized by left–right confusion, finger agnosia, dyslexia, dysgraphia, dyscalculia, and a homonymous contralateral lower quadrantanopia.

153–C. A lesion of the supramarginal gyrus (Brodmann area 40) or of the arcuate fasciculus results in conduction aphasia characterized by fluent speech, good comprehension, poor repetition, and paraphrasic speech (fluently spoken jargon-like Wernicke aphasia) and writing.

- 154–B.** Lesions of the postcentral gyrus, sensory strip (Brodmann areas 3, 1, and 2) result in contralateral astereognosia, hemihypesthesia, and agraphesthesia.
- 155–A.** Lesions of the precentral gyrus, motor strip (Brodmann area 4) result in contralateral spastic hemiparesis with pyramidal signs.
- 156–G.** In thiamine (vitamin B1) deficiency, hemorrhagic lesions are found in the mamillary bodies.
- 157–F.** Bilateral lesions of the amygdala result in Klüver-Bucy syndrome, with hyperphagia, hypersexuality, and psychic blindness (visual agnosia).
- 158–E.** Bilateral damage to the parahippocampal gyri and the underlying hippocampal formation results in severe loss of short-term memory (e.g., hypoxia, hypoxemia, and herpes simplex virus encephalitis).
- 159–D.** Lesions of the cuneus interrupt the visual radiations en route to the upper bank of the calcarine fissure, which represents the inferior visual field quadrants.
- 160–C.** The fornix (a limbic structure) interconnects the septal area and the hippocampal formation. Bilateral transection of this structure may result in an acute amnesic syndrome.
- 161–B.** The motor strip for the foot is in the anterior paracentral lobule on the medial aspect of the hemisphere. A lesion here results in a contralateral hemiparesis of the foot and leg with pyramidal signs.
- 162–A.** Ablation of the cingulate gyrus (cingulectomies) has been used to treat psychotic and neurotic patients. The cingulate gyrus is part of the limbic lobe; lesions can result in akinesia, mutism, apathy, and indifference to pain.
- 163–C.** The anterior spinal artery supplies the pyramids, medial lemniscus, and intra-axial fibers of the hypoglossal nerve (CN XII) in the medulla. The anterior communicating artery connects the two anterior cerebral arteries and is a common site for berry (saccular) aneurysms. The anterior choroidal artery supplies the choroid plexus of the temporal horn, the hippocampus, amygdala, optic tract, lateral geniculate body and globus pallidus. The posterior spinal artery supplies the gracile and cuneate fasciculi and their posterior relay nuclei. The posterior inferior cerebellar artery supplies the dorsolateral zone of the medulla.
- 164–B.** The anterior spinal artery perfuses the intra-axial fibers of the anterior horn. The basilar artery gives rise to the pontine arteries. The posterior spinal artery irrigates the posterior columns. The vertebral artery is a branch of the subclavian artery. The anterior inferior cerebellar artery supplies the facial and trigeminal nuclei as well as the vestibular and cochlear nuclei.
- 165–A.** The anterior communicating artery is a common site for berry aneurysms; berry aneurysms of the anterior communicating artery frequently pressure the optic chiasm and cause a bitemporal lower quadrantanopia. The basilar artery gives rise to the pontine arteries. The ophthalmic artery branches into the central artery of the retina. The anterior cerebral artery supplies the anterior limb of the internal capsule via the medial striate artery (Heubner's artery). The posterior communicating artery irrigates the optic chiasm, optic tract, hypothalamus, subthalamus, and anterior half of the ventral portion of thalamus. Berry aneurysms of the posterior communicating artery frequently cause third-nerve palsy.
- 166–B.** Laceration of the middle meningeal artery results in epidural hemorrhage. The middle meningeal artery lies between the periosteal and meningeal dura, below the temporal and parietal bones and supplies most of the dura and almost its entire calvarial portion.
- 167–E.** The aneurysm was on the posterior communicating artery; pressure on the oculomotor nerve results in a complete third-nerve palsy with the following signs: dilated fixed pupil, ptosis, and eye looking down and out. The anterior cerebral artery supplies part of the caudate nucleus, putamen, and anterior limb of the internal capsule via the medial striate artery of Heubner. The anterior communicating artery supplies the leg and foot areas of the motor and sensory cortices (paracentral lobule). The internal carotid artery provides direct branches to the optic nerve, optic chiasm, hypothalamus, and genu of the internal capsule. The ophthalmic artery branches into the central artery of the retina.

168–D. The superior cerebellar artery supplies the dentate nucleus, the largest efferent nucleus of the cerebellum. Damage to this nucleus results in cerebellar signs: dystaxia, dysmetria, and intention tremor. The vertebral artery gives rise to the posterior inferior cerebellar artery, which supplies the medial and inferior vestibular nuclei, inferior cerebellar peduncle, nucleus ambiguus, intra-axial fibers of the glossopharyngeal nerve (CN IX) and vagus nerve (CN X), spinothalamic tract of the anterolateral system, and spinal trigeminal nucleus and tract. The anterior inferior cerebellar artery irrigates the dorsal lateral pons CN V, CN VII, and CN VIII. The posterior cerebral artery supplies the posterior half of the thalamus, the medial and lateral geniculate bodies, the occipital lobe, visual cortex, and inferior surface of the temporal lobe, including the hippocampal formation.

169–C. A lesion of the lateral rectus results in diplopia and horizontal nystagmus on attempted lateral conjugated gaze. It is innervated by CN VI. The buccinator (facial expression), the posterior belly of the digastric (facial expression), and the orbicularis oculi (corneal reflex) are innervated by the facial nerve (CN VII). The pterygoids (mouth movement) are innervated by the mandibular division of the trigeminal nerve (CN V₃).

170–C. Areas 13–15 were not noted by Brodmann and may be located deep in the lateral fissure.

171–D. The trigone contains a calcified globus of choroid plexus. In axial CT sections the adult calcified pineal body is also visualized, lying halfway between the two trigona.

172–D. The subcommissural organ lies in the roof of the cerebral aqueduct near the posterior commissure; it has a blood–brain barrier. All circumventricular organs except the subcommissural organ have fenestrated capillaries and thus lack a blood–brain barrier.

173–C. The pericallosal artery, a branch of the anterior cerebral artery, irrigates the lower limb area of the paracentral lobule. The middle cerebral artery supplies the trunk, upper limb, and face areas of the motor and sensory cortices. The posterior cerebral artery supplies the occipital lobe, visual cortex, and inferior surface of the temporal lobe, including the hippocampal formation. The splenic artery supplies the spleen. Heubner’s medial striate artery irrigates the anterior limb of the internal capsule.

174–A. The anterior choroidal artery is a branch of the middle cerebral artery. It supplies the amygdala, the posterior limb of the internal capsule, the globus pallidus, and the optic tract. Klüver–Bucy syndrome results in placidity, hypersexuality, hyperphagia, and psychic blindness (visual agnosia).

175–B. Three cranial nerves—the abducent, facial, and vestibulocochlear nerves—exit from the pontomedullary sulcus. The facial nerve has two divisions, the cranial nerve proper (motor) and the intermediate division (sensory). The intermediate division contains general somatic afferent and special visceral afferent fibers.

176–C. The anterior spinal artery supplies the pyramid and the medial lemniscus. The anterior communicating artery connects the two anterior cerebral arteries and is a common site for berry (saccular) aneurysms. The anterior choroidal artery supplies the choroid plexus of the temporal horn, the hippocampus, amygdala, optic tract, lateral geniculate body, and globus pallidus. The posterior spinal artery supplies the gracile and cuneate fasciculi and their posterior relay nuclei. The posterior inferior cerebellar artery supplies the dorsolateral zone of the medulla (Wallenberg).

177–B. The anterior spinal artery perfuses the intra-axial fibers of the anterior horn. The basilar artery gives rise to the pontine arteries. The posterior spinal artery irrigates the posterior columns. The vertebral artery is a branch of the subclavian artery. The anterior inferior cerebellar artery supplies the facial and trigeminal motor nuclei, the vestibular nuclei, and the cochlear nuclei.

178–A. The anterior communicating artery connects the two anterior cerebral arteries. Berry (saccular) aneurysms may impinge upon the optic chiasm and produce a bitemporal hemianopia. The posterior communicating artery is also the site of berry aneurysms, which may pressure the oculomotor nerve causing a third-nerve palsy: the eyes look “down and out.”

179–E. Cerebrospinal fluid typically contains no more than 5 lymphocytes per microliter (see Table 2.1).

180–C. The normal total protein value for cerebrospinal fluid is less than 45 mg/dl in the lumbar cistern (see Table 2.1).

181–E. Normal serum glucose level in cerebrospinal fluid is 66% of blood, which is 80 to 120 mg/dl.

182–E. Pseudotumor cerebri, or benign intracranial hypertension, is characterized by papilledema without mass, elevated cerebrospinal fluid pressure, and deteriorating vision. Normal-pressure hydrocephalus is characterized clinically by the triad of progressive dementia, ataxic gait, and urinary incontinence, (wacky, wobbly, and wet). Hydrocephalus ex vacuo results from a loss of neurons in the caudate nucleus (e.g., Huntington disease). Arnold Chiari II is a cerebellomedullary malformation in which the caudal vermis, cerebellar tonsils, and medulla herniate through the foramen magnum, resulting in an obstructive hydrocephalus. Dandy–Walker consists of a huge cyst of the posterior fossa associated with atresia of the outlet foramina (of Luschka and Magendie).

183–D. Cerebrospinal fluid enters the subarachnoid space via the outlet foramina of the fourth ventricle (foramina of Luschka and Magendie).

184–B. Thrombosis of the anterior spinal artery results in the medial medullary syndrome (see Figure 12.1). Deficits include contralateral hemiparesis of the trunk and extremities; contralateral loss of proprioception, discriminative tactile sensation, and vibration sensation from the trunk and extremities; and ipsilateral flaccid paralysis of the tongue.

185–E. Seizures have the highest incidence in the temporal lobe. Astrocytoma is the most common glioma in the temporal lobe. Charcot–Bouchard microaneurysms are found in the lenticulostriate arteries. They rupture most frequently in the basal nuclei. They are the most common cause of nontraumatic intraparenchymal hemorrhage. The olfactory groove meningioma impinges on the olfactory tract and optic nerve, causing ipsilateral anosmia, ipsilateral optic atrophy, and contralateral papilledema. The astrocytoma transected Meyer’s loop and produced the contralateral quadrantanopia.

186–C. The lesion is found in the lower closed medulla at the spinomedullary junction. The term closed means not covered by the fourth ventricle. A lesion of the decussation of the pyramids results in spastic paralysis of all limbs and intact sensibility. The location of the cranial nerve nuclei of the brainstem reveals where the lesion is in the neuraxis: midbrain, CN III, and CN IV; pons, CN V, CN VI, CN VII, and CN VIII; medulla, CN VIII, CN IX, and CN X.

187–A. The optic cup and its derivatives, the retina and optic nerve, develop from the diencephalon.

188–E. General somatic afferent fibers are one of four functional components of spinal nerves (see Figure 6.3). They convey sensory input from skin, muscle, bone, and joints to the central nervous system. General visceral afferent fibers convey sensory input from visceral organs to the central nervous system. Special somatic afferent fibers convey sensory information related to vision, audition and equilibrium, while special visceral afferent fibers convey sensory information related to taste and smell.

189–B. The spinal cord derives from the caudal part of the neural tube. The cranial part becomes the brain. The cavity gives rise to the central canal of the spinal cord and ventricles of the brain. The anterior neuropore is an opening in the neural tube that in the fourth week becomes the lamina terminalis. The posterior neuropore is a second opening in the neural tube that closes in the fourth week.

190–B. The globus pallidus originates in the diencephalon. Neuroblasts from the subthalamus migrate into the telencephalic white matter to form the globus pallidus.

191–A. The abducent nucleus is the general somatic efferent column of the pons.

192–E. The superior salivatory nucleus is the general visceral efferent column of the pons. All somatic and visceral motor nuclei are derived from the basal plate. The cerebellum and pontine nuclei and the sensory nuclei of cranial nerves are derivatives of the alar plate.

193–C. Axons of the corticospinal tracts are not fully myelinated until the end of the second postnatal year. Babinski sign (extensor plantar reflex) can be elicited in infants for this reason.

194–B. The cochlear duct is derived from a thickening of the surface ectoderm called the otic placode.

195–D. The stapes is innervated by CN VII.

196–E. Intention tremor is a deficit in coordination of voluntary movements caused by lesions in the lateral cerebellum (e.g., finger-to-nose test). Athetosis is slow, writhing movements representative of basal nuclei damage. Chorea is involuntary movements caused by overactivity of dopamine and is a classic symptom of Huntington's disease. Cogwheel rigidity is a classic rigidity seen in Parkinson disease owing to lack of dopamine. Hemiballismus is large, flinging movements of the limbs owing to a lesion in the subthalamic nucleus.

197–A. The anterior spinocerebellar tract crosses the midline via the anterior commissure and crosses the dorsal aspect of the superior cerebellar peduncle to terminate in the anterior cerebellar vermis.

198–C. The stylohyoid, stylopharyngeus, and styloglossus are attached to the styloid process. The stylohyoid is innervated by the somatic visceral efferent component of CN VII. The stylopharyngeus is innervated by the somatic visceral efferent component of CN IX. The styloglossus is innervated by CN XII.

199–A. Rhinorrhea will most likely result from a fracture of the cribriform plate of the ethmoid bone, which can tear the arachnoid membrane and result in a leakage of cerebrospinal fluid into the nasal cavity.

200–A. The facial nerve (CN VII) innervates the taste buds from the anterior two-thirds of the tongue, providing input to the solitary tract and solitary nucleus via the geniculate ganglion (see gustatory pathway, Figure 17.2).

201–B. The maxillary nerve passes through the foramen rotundum; the mandibular nerve passes through the foramen ovale; the ophthalmic nerve passes through the superior orbital fissure; the optic nerve passes through the optic canal; and the trochlear nerve passes thru the cavernous sinus. A fracture of the foramen rotundum causes damage to the maxillary nerve.

202–D. The optic canal transmits the optic nerve (CN II) and the ophthalmic artery.

203–C. The postcentral gyrus is the sensory strip, the somatosensory cortex (areas 3, 1, and 2). Sensation to the face and tongue areas is on the inferior aspect of the postcentral gyrus (see the sensory homunculus, Chapter 23). The anterior paracentral lobule subserves motor innervation to the feet. The posterior paracentral lobule subserves sensory innervation to the feet. The precentral gyrus is the motor cortex. The middle frontal gyrus contains the frontal eye field (area 8).

204–C. Multiple sclerosis is a demyelinating disease characterized by exacerbations and remissions. In multiple sclerosis patients, cerebrospinal fluid contains oligoclonal immunoglobulin G bands, indicating chronic inflammation. Amyotrophic lateral sclerosis is a motor neuron disease. Poliomyelitis is an enterovirus. Brown-Séquard syndrome is spinal cord hemisection. Syringomyelia is central cavitation of the cervical spinal cord.

Appendix

table A-1 Appendix: Table of Cranial Nerves

Cranial Nerve	Type	Origin	Function	Course
I—Olfactory	SVA	Bipolar olfactory neurons (in olfactory epithelium in roof of nasal cavity)	Smell (olfaction)	Central axons project to the olfactory bulb via the cribriform plate of the ethmoid bone.
II—Optic	SSA	Retinal ganglion cells	Vision	Central axons converge at the optic disk and form the optic nerve, which enters the skull via the optic canal. Optic nerve axons terminate in the lateral geniculate bodies.
III—Oculomotor Parasympathetic	GVE	Accessory oculomotor nucleus (rostral midbrain)	Sphincter pupillae, ciliaris	Axons exit the midbrain; the interpeduncular fossa traverse the cavernous sinus and enter the orbit via the superior orbital fissure.
Motor	GSE	Oculomotor nucleus (rostral midbrain)	Superior, inferior, and medial recti; inferior oblique; levator palpebrae superioris	
IV—Trochlear	GSE	Trochlear nucleus (caudal midbrain)	Superior oblique	Axons decussate in superior medullary velum, exit posteriorly inferior to the inferior colliculi, encircle the midbrain, traverse the cavernous sinus, and enter the orbit via the superior orbital fissure.
V—Trigeminal Motor	SVE	Trigeminal motor nucleus (mid pons)	Muscles of mastication, tensor tympani, anterior belly of the digastric, mylohyoid and tensor palati	Ophthalmic nerve exits via the superior orbital fissure; maxillary nerve exits via the foramen rotundum; mandibular nerve exits via the foramen ovale; ophthalmic and maxillary nerves traverse the cavernous sinus; GSA fibers enter the spinal trigeminal tract of CN V.
Sensory	GSA	Trigeminal ganglion and mesencephalic nucleus CN V (rostral pons and midbrain)	Tactile, pain, and thermal sensation from the face; the oral and nasal cavities and the supratentorial dura	
VI—Abducent	GSE	Abducent nucleus (caudal pons)	Lateral rectus	Axons exit the pons from the inferior pontine sulcus, traverse the cavernous sinus, and enter the orbit via the superior orbital fissure.

(Continued)

table A-1 Appendix: Table of Cranial Nerves (*continued*)

Cranial Nerve	Type	Origin	Function	Course
VII—Facial Parasympathetic	GVE	Superior salivatory nucleus (caudal pons)	Lacrimal gland (via pterygopalatine ganglion); submandibular and sublingual glands (via submandibular ganglion)	Axons exit the pons in the cerebellar pontine angle and enter the internal auditory meatus; motor fibers traverse the facial canal of the temporal bone and exit via the stylomastoid foramen; taste fibers traverse the chorda tympani and lingual nerve; GSA fibers enter the spinal trigeminal tract of CN V; SVA fibers enter the solitary tract.
Motor	SVE	Facial motor nucleus (caudal pons)	Muscles of facial expression; stapedius	
Sensory	GSA	Geniculate ganglion (temporal bone)	Tactile sensation to skin of ear	
Sensory	SVA	Geniculate ganglion	Taste sensation from the anterior two-thirds of tongue (via chorda tympani)	
VIII—Vestibulocochlear Vestibular nerve	SSA	Vestibular ganglion (internal auditory meatus)	Equilibrium (innervates hair cells of semicircular ducts, saccule, and utricle)	Vestibular and cochlear nerves join in the internal auditory meatus and enter the brain stem in the cerebellopontine angle; vestibular nerve projects to the vestibular nuclei and the flocculonodular lobe of the cerebellum; cochlear nerve projects to the cochlear nuclei.
Cochlear nerve		Spiral ganglion (modiolus of temporal bone)	Hearing (innervates hair cells of the organ of Corti)	
IX—Glossopharyngeal Parasympathetic	GVE	Inferior salivatory nucleus (rostral medulla)	Parotid gland (via the otic ganglion)	Axons exit (motor) and enter (sensory) medulla from the postolivary sulcus; axons exit and enter the skull via jugular foramen; GSA fibers enter the spinal trigeminal tract of CN V; GVA and SVA fibers enter the solitary tract.
Motor	SVE	Nucleus ambiguus (rostral medulla)	Stylopharyngeus	
Sensory	GSA	Superior ganglion (jugular foramen)	Tactile sensation to middle ear cavity	
Sensory	GVA	Inferior (petrosal) ganglion (in jugular foramen)	Tactile sensation to posterior third of tongue, pharynx, middle ear, and auditory tube; input from carotid sinus and carotid body	
Sensory	SVA	Inferior (petrosal) ganglion (in jugular foramen)	Taste from posterior third of the tongue	
X—Vagus Parasympathetic	GVE	Dorsal motor nucleus of CN X (medulla)	Viscera of the thoracic and abdominal cavities to the mid-transverse colon [via terminal (mural) ganglia]	Axons exit (motor) and enter (sensory) medulla from the postolivary sulcus; axons exit and enter the skull via the jugular foramen; GSA fibers enter the spinal trigeminal tract of CN V; GVA and SVA fibers enter the solitary tract.

table A-1 Appendix: Table of Cranial Nerves (*continued*)

Cranial Nerve	Type	Origin	Function	Course
Motor	SVE	Nucleus ambiguus (mid-medulla)	Muscles of the larynx and pharynx	
Sensory	GSA	Superior ganglion (jugular foramen)	Tactile sensation to the external ear	
Sensory	GVA	Inferior (nodose) ganglion (in jugular foramen)	Mucous membranes of the pharynx, larynx, esophagus, trachea, and thoracic and abdominal viscera to the mid-transverse colon	
Sensory	SVA	Inferior (nodose) ganglion (in jugular foramen)	Taste from the epiglottis	
XI—Accessory Motor	SVE	Anterior horn neurons C1–C6	Sternocleidomastoid and trapezius	Axons exit the spinal cord, ascend through the foramen magnum, and exit the skull via the jugular foramen.
XII—Hypoglossal	GSE	Hypoglossal nucleus (medulla)	Intrinsic and extrinsic muscles of the tongue (except the palatoglossus)	Axons exit from the preolivary sulcus of the medulla and exit the skull via the hypoglossal canal.

SVA = special visceral afferent; SSA = special somatic afferent; GVE = general visceral efferent; GSE = general somatic efferent; SVE = special visceral efferent; GSA = general somatic afferent; GVA = general visceral afferent; CN = cranial nerve.



Glossary

abasia—Inability to walk.

abulia—Inability to perform voluntary actions or to make decisions; seen in bilateral frontal lobe disease.

accommodation—Increase in thickness of the lens needed to focus a near object on the retina; mediated by the contraction of ciliaris.

adenohypophysis—Anterior lobe of the pituitary gland, derived from Rathke's pouch.

adenoma sebaceum—Cutaneous lesion seen in tuberous sclerosis.

Adie pupil—Myotonic pupil; a tonic pupil, usually large, that constricts very slowly to light and convergence; generally unilateral and frequently occurs in young women with diminished deep tendon reflexes.

afferent pupil (Marcus Gunn pupil)—A pupil that reacts sluggishly to direct light stimulation; caused by a lesion of the afferent pathway (e.g., multiple sclerosis involving the optic nerve).

agenesis—Failure of a structure to develop (e.g., agenesis of the corpus callosum).

ageusia—Loss of the sensation of taste (gustation).

agnosia—Lack of the sensory-perceptual ability to recognize objects: visual, auditory, and tactile.

agraphesthesia—Inability to recognize figures written on the skin.

agraphia—Inability to write; seen in Gerstmann syndrome.

akathisia—Acatheisia; the inability to remain in a sitting position; motor restlessness; may appear after the withdrawal of neuroleptic drugs.

akinesia—Absence or loss of the power of voluntary motion; seen in Parkinson disease.

akinetetic mutism—State in which the patient can move and speak but cannot be prompted to do so; results from bilateral occlusion of the anterior cerebral artery or midbrain lesions.

alar plate—Division of the mantle zone of the developing spinal cord that gives rise to sensory neurons; receives sensory input from the spinal ganglia.

albuminocytologic dissociation—Elevated cerebrospinal fluid (CSF) protein with a normal CSF cell count; seen in Guillain-Barré syndrome.

alexia—Visual aphasia; word or text blindness; loss of the ability to grasp the meaning of written or printed words; seen in Gerstmann syndrome.

Alzheimer disease—Condition characterized pathologically by the presence of senile plaques, neurofibrillary tangles, granulovacuolar degeneration, Hirano bodies, and amyloid deposition; patients are demented, with severe memory loss.

alternating hemianesthesia—Ipsilateral facial anesthesia and a contralateral body anesthesia; results from a pontine or medullary lesion involving the spinal trigeminal tract and the anterolateral system.

alternating hemiparesis—Ipsilateral cranial nerve palsy and a contralateral hemiparesis (e.g., alternating abducent hemiparesis).

altitudinal hemianopia—Defect in which the upper or the lower half of the visual field is lost.

amaurosis fugax—Transient monocular blindness usually related to carotid artery stenosis or less often to embolism of retinal arterioles.

amnesia—Disturbance or loss of memory; seen with bilateral medial temporal lobe lesions.

amusia—Form of aphasia characterized by the loss of ability to express or recognize simple musical tones.

amyotrophic lateral sclerosis (ALS)—A nonhereditary motor neuron disease affecting both upper and lower motor neurons; characterized by muscle weakness, fasciculations, fibrillations, and giant motor units on electromyography. There are no sensory deficits in ALS. It is also called Lou Gehrig's disease.

amyotrophy—Muscle wasting or atrophy.

analgesia—Insensibility to painful stimuli.

anencephaly—Failure of the cerebral and cerebellar hemispheres to develop; results from failure of the anterior neuropore to close.

anesthesia—State characterized by the loss of sensation.

aneurysm—Circumscribed dilation of an artery (e.g., berry aneurysm).

anhidrosis—Absence of sweating; found in Horner syndrome.

anisocoria—Pupils that are unequal in size; found in third-nerve palsy and Horner syndrome.

anomia—Anomic aphasia; the inability to name objects; may result from a lesion of the angular gyrus.

anosmia—Olfactory anesthesia; loss of the sense of smell.

anosognosia—Ignorance of the presence of disease.

Anton syndrome (visual anosognosia)—Lack of awareness of being cortically blind; may result from bilateral occipital lobe lesions affecting the visual association cortex.

aphasia—Impaired or absent communication by speech, writing, or signs; loss of the capacity for spoken language.

aphonia—Loss of the voice.

apparent enophthalmos—Ptosis seen in Horner syndrome that makes the eye appear as if it is sunk back into the orbit.

apraxia—Disorder of voluntary movement; the inability to execute purposeful movements; the inability to properly use an object (e.g., a tool).

aprosoia (aprosoia)—Absence of normal pitch, rhythm, and the variation of stress in speech.

area postrema—Chemoreceptor zone in the medulla that responds to circulating emetic substances; it has no blood-brain barrier.

areflexia—Absence of reflexes.

Argyll Robertson pupil—Pupil that responds to convergence but not to light; seen in neurosyphilis and lesions of the pineal region.

Arnold-Chiari malformation—Characterized by herniation of the caudal cerebellar vermis and cerebellar tonsils through the foramen magnum; associated with lumbar myelomeningocele, dysgenesis of the corpus callosum, and obstructive hydrocephalus.

arrhinencephaly—Characterized by agenesis of the olfactory bulbs; results from malformation of the forebrain; associated with trisomy 13-15 and holoprosencephaly.

ash-leaf spots—Hypopigmented patches typically seen in tuberous sclerosis.

astasia-abasia—Inability to stand or walk.

astatognosia—Position agnosia; the inability to recognize the position or disposition of an extremity or digit in space.

astereognosis (stereoanesthesia)—Tactile amnesia; the inability to judge the form of an object by touch.

asterixis—Flapping tremor of the outstretched arms seen in hepatic encephalopathy and Wilson disease.

ataxia (incoordination)—Inability to coordinate muscles during the execution of voluntary movement (e.g., cerebellar and posterior column ataxia).

athetosis—Slow, writhing, involuntary purposeless movements seen in Huntington disease (chorea).

atresia—Absence of one or more normal openings (e.g., atresia of the outlet foramina of the fourth ventricle, which results in Dandy-Walker syndrome).

atrophy—Muscle wasting; seen in lower motor neuron disease.

auditory agnosia—Inability to interpret the significance of sound; seen in Wernicke dysphasia/aphasia.

autotopagnosia (somatotopagnosia)—Inability to recognize parts of the body; seen with parietal lobe lesions.

Babinski sign—Extension of the great toe in response to plantar stimulation (S-1); indicates corticospinal (pyramidal) tract involvement.

Balint syndrome (optic ataxia)—Condition characterized by a failure to direct oculomotor function in the exploration of space; failure to follow a moving object in all quadrants of the field once the eyes are fixed on the object.

ballism—Dyskinesia resulting from damage to the subthalamic nucleus; characterized by violent flailing and flinging of the contralateral extremities.

basal plate—Division of the mantle zone that gives rise to lower motor neurons.

Bell palsy—Idiopathic facial nerve paralysis.

Benedikt syndrome—Condition characterized by a lesion of the midbrain affecting the intra-axial oculomotor fibers, medial lemniscus, and cerebellothalamic fibers.

berry aneurysm—Small saccular dilation of a cerebral artery; ruptured berry aneurysms are the commonest cause of nontraumatic subarachnoid hemorrhage.

blepharospasm—Involuntary recurrent spasm of both eyelids; effective treatment is injections of botulinum toxin into the orbicularis oculi muscles.

blood-brain barrier—Tight junctions (zonulae occludentes) of the capillary endothelial cells.

blood-cerebrospinal fluid barrier—Tight junctions (zonulae occludentes) of the choroid plexus.

bradykinesia—Extreme slowness in movement; seen in Parkinson disease.

Broca aphasia—Difficulty in articulating or speaking language; found in the dominant inferior frontal gyrus; also called expressive, anterior, motor, or nonfluent aphasia.

bulbar palsy—Progressive bulbar palsy; a lower motor neuron paralysis affecting primarily the motor nuclei of the medulla; the prototypic disease is amyotrophic lateral sclerosis, characterized by dysphagia, dysarthria, and dysphonia.

caloric nystagmus—Nystagmus induced by irrigating the external auditory meatus with either cold or warm water; remember **COWS** mnemonic: **c**old, **o**pposite; **w**arm, **s**ame.

cauda equina—Sensory and motor nerve rootlets found below the L2 vertebral level; lesions of the cauda equina result in motor and sensory defects of the lower limb.

cerebral edema—Abnormal accumulation of fluid in the brain; associated with volumetric enlargement of brain tissue and ventricles; may be vasogenic, cytotoxic, or both.

cerebral palsy—Defect of motor power and coordination resulting from brain damage; the commonest cause is hypoxia and asphyxia manifested during parturition.

Charcot-Bouchard aneurysm—Miliary aneurysm; microaneurysm; rupture of this type of aneurysm is the commonest cause of intraparenchymal hemorrhage; most commonly found in the basal nuclei.

Charcot-Marie-Tooth disease—Most commonly inherited neuropathy affecting lower motor neurons and spinal ganglion cells.

cherry-red spot (macula)—seen in Tay-Sachs disease; resembles a normal-looking retina; the retinal ganglion cells surrounding the fovea are packed with lysosomes and no longer appear red.

chorea—Irregular, spasmodic, purposeless, involuntary movements of the limbs and facial muscles; seen in Huntington disease.

choreiform—Resembling chorea.

choreoathetosis—Abnormal body movements of combined choreic and athetoid patterns.

chromatolysis—Disintegration of Nissl substance following transection of an axon (axotomy).

clasp-knife spasticity—When a joint is moved briskly, resistance is felt initially and then fades like the opening of a pocket knife; seen with corticospinal lesions.

clonus—Contractions and relaxations of a muscle; seen with corticospinal tract lesions.

cogwheel rigidity—Rigidity characteristic of Parkinson disease. Bending a limb results in ratchet-like movements.

conduction aphasia—Aphasia in which the patient has relatively normal comprehension and spontaneous speech but difficulty with repetition; results from a lesion of the arcuate fasciculus, which interconnects the Broca area and the Wernicke area.

confabulation—Making bizarre and incorrect responses; seen in Wernicke-Korsakoff psychosis.

construction apraxia—Inability to draw or construct geometric figures; frequently seen in nondominant parietal lobe lesions.

conus medullaris syndrome—Condition characterized by paralytic bladder, fecal incontinence, impotence, and perianogenital sensory loss; involves segments S3–Co.

Corti organ (spiral organ)—Structure containing hair cells responding to sounds that induce vibrations of the basilar membrane.

Creutzfeldt-Jakob disease—Rapidly progressing dementia, likely caused by an infectious prion; histologic picture is that of a spongiform encephalopathy; classic triad is dementia, myoclonic jerks, and typical electroencephalograph findings.

crocodile tears syndrome—Lacrimation during eating; results from a facial nerve injury proximal to the geniculate ganglion; regenerating preganglionic salivatory fibers are misdirected to the pterygopalatine ganglion, which projects to the lacrimal gland.

cupulolithiasis—Dislocation of the otoliths of the utricular macula that causes benign positional vertigo.

cycloplegia—Paralysis of accommodation (CN III) (i.e., paralysis of the ciliaris).

Dandy-Walker malformation—Characterized by congenital atresia of the foramina of Luschka and Magendie, hydrocephalus, posterior fossa cyst, and dilatation of the fourth ventricle; associated with agenesis of the corpus callosum.

decerebrate posture (rigidity)—posture in comatose patients where the arms are overextended, the legs are extended, the hands are flexed, and the head is extended; the causal lesion is in the rostral midbrain.

decorticate posture (rigidity)—posture in comatose patients where the arms are flexed and the legs are extended; the causal lesion involves both hemispheres.

dementia pugilistica (punch-drunk syndrome)—Condition characterized by dysarthria, parkinsonism, and dementia; ventricular enlargement and fenestration of the septum pellucidum are common; the commonest cause of death is subdural hematoma.

diabetes insipidus—Condition characterized by excretion of large amounts of pale urine; results from inadequate output of the antidiuretic hormone from the hypothalamus.

diplegia—Paralysis of the corresponding parts on both sides of the body.

diplopia—Double vision.

doll's-eyes maneuver (oculocephalic reflex)—Moving the head of a comatose patient with intact brainstem; results in a deviation of the eyes to the opposite direction.

Down syndrome—Condition that results from a chromosomal abnormality (trisomy 21); Alzheimer disease is common in Down syndrome in persons older than 40 years.

dressing apraxia—Loss of the ability to dress oneself; frequently seen in nondominant parietal lobe lesions.

Duret hemorrhages—Midbrain and pontine hemorrhages resulting from transtentorial (uncal) herniation.

dysarthria—Disturbance of articulation (e.g., vagal nerve paralysis).

dyscalculia—Difficulty in performing calculations; seen in lesions of the dominant parietal lobule.

dysdiadochokinesia—Inability to perform rapid alternating movements (e.g., supination and pronation of the hand); seen in cerebellar disease.

dysesthesia—Impairment of sensation; disagreeable sensation produced by normal stimulation.

dyskinesias—Movement disorders attributed to pathologic states of the striatal (extrapyramidal) system; movements are generally characterized as in suppressible, stereotyped, and automatic.

dysmetria—Past-pointing; a form of dystaxia seen in cerebellar disease.

dysnomia—Dysnomic (nominal) aphasia; difficulty in naming objects or persons; seen with some degree in all aphasias.

dysphagia—Difficulty in swallowing; dysaglutition.

dysphonia—Difficulty in speaking; hoarseness.

dyspnea—Difficulty in breathing.

dysprosodia—Dysprosody; difficulty of speech in producing or understanding the normal pitch, rhythm, and variation in stress; lesions are found in the nondominant hemisphere.

dyssynergia—Incoordination of motor acts; seen in cerebellar disease.

dystaxia—Difficulty in coordinating voluntary muscle activity; seen in posterior column and cerebellar disease.

dystonia (torsion dystonia)—Sustained involuntary contractions of agonists and antagonists (e.g., torticollis); may be caused by the use of neuroleptics.

dystrophy—Progressive changes possibly related to nutrition. When applied to muscle disease, it implies abnormal development and genetic determination.

edrophonium (Tensilon)—Diagnostic test for myasthenia gravis.

embolus—Plug formed by a detached thrombus.

emetic—Agent that causes vomiting; see **area postrema**.

encephalocele—Result of herniation of meninges and brain tissue through an osseous defect in the cranial vault.

encephalopathy—Any disease of the brain.

enophthalmos—Recession of the eye within the orbit.

epicritic sensation—Discriminative sensation; posterior column–medial lemniscus modalities.

epilepsy—Chronic disorder characterized by paroxysmal brain dysfunction caused by excessive neuronal discharge (seizure); usually associated with some alteration of consciousness; can be associated with a reduction of gamma-aminobutyric acid.

epiloia—Tuberous sclerosis, a neurocutaneous disorder; characterized by dementia, seizures, and adenoma sebaceum.

epiphora—Tear flow owing to lower eyelid palsy (CN VII).

exencephaly—Congenital condition in which the skull is defective, thus exposing the brain; seen in anencephaly.

extrapyramidal (motor) system—Motor system including the striatum (caudate nucleus and putamen), globus pallidus, subthalamic nucleus, and substantia nigra; also called the striatal (motor) system.

facial apraxia—Inability to perform facial movements on command.

fasciculations—Visible twitching of muscle fibers seen in lower motor neuron disease.

festination—Acceleration of a shuffling gait seen in Parkinson disease.

fibrillations—Nonvisible contractions of muscle fibers found in lower motor neuron disease.

flaccid paralysis—Complete loss of muscle power or tone resulting from lower motor neuron disease.

folic acid deficiency—Common cause of megaloblastic anemia; may also cause fetal neural tube defects (e.g., spina bifida).

gait apraxia—Diminished capacity to walk or stand; frequently seen with bilateral frontal lobe disease.

gegenhalten—Paratonia; a special type of resistance to passive stretching of muscles; seen with frontal lobe disease.

Gerstmann syndrome—Condition characterized by right–left confusion, finger agnosia, dysgraphia, and dyscalculia; results from a lesion of the dominant inferior parietal lobule.

glioma—Tumor (neoplasm) derived from glial cells.

global aphasia—Difficulty with comprehension, repetition, and speech.

graphesthesia—Ability to recognize figures written on the skin.

hallucination—False sensory perception with localizing value.

hematoma—Localized mass of extravasated blood; a contained hemorrhage (e.g., subdural or epidural).

hemianopia—Hemianopsia; loss of vision in one half of the visual field of one or both eyes.

hemiballism—Dyskinesia resulting from damage to the subthalamic nucleus; characterized by violent flinging and flailing movements of the contralateral extremities.

hemianhidrosis—Absence of sweating on half of the body or face; seen in Horner syndrome.

hemiparesis—Slight paralysis affecting one side of the body; seen in stroke involving the internal capsule.

hemiplegia—Paralysis of one side of the body.

herniation—Pressure-induced protrusion of brain tissue into an adjacent compartment; may be transtentorial (uncal), subfalcine (subfalcial), or transforaminal (tonsillar).

heteronymous—Referring to noncorresponding halves or quadrants of the visual fields (e.g., binasal hemianopia).

herpes simplex encephalitis—Disorder characterized by headache, behavioral changes (memory), and seizures; the commonest cause of encephalitis in the central nervous system; the temporal lobes are preferentially the target of hemorrhagic necrosis.

hidrosis—Sweating, perspiration, and diaphoresis.

Hirano bodies—Eosinophilic rodlike structures (inclusions) found in the hippocampus in Alzheimer disease.

holoprosencephaly—Failure of the prosencephalon to diverticulate and form two hemispheres.

homonymous—Referring to corresponding halves or quadrants of the visual fields (e.g., left homonymous hemianopia).

Horner syndrome—Oculosympathetic paralysis consisting of miosis, hemianhidrosis, mild ptosis, and apparent enophthalmos.

hydranencephaly—Condition in which the cerebral cortex and white matter are replaced by membranous sacs; believed to be the result of circulatory disease.

hydrocephalus—Condition marked by excessive accumulation of cerebrospinal fluid and dilated ventricles.

hygroma—Collection of cerebrospinal fluid in the subdural space.

hypacusis—Hearing impairment.

hypalgesia—Decreased sensibility to pain.

hyperacusis—Abnormal acuteness of hearing; the result of a facial nerve paralysis (e.g., Bell palsy).

hyperphagia—Gluttony; overeating as seen in hypothalamic lesions.

hyperpyrexia—High fever as seen in hypothalamic lesions.

hyperreflexia—An exaggeration of muscle stretch reflexes as seen with upper motor neuron lesions: a sign of spasticity.

hyperthermia—Increased body temperature; seen with hypothalamic lesions.

hypertonia—Increased muscle tone; seen with upper motor neuron lesions.

hypesthesia—Hypoesthesia; diminished sensitivity to stimulation.

hypokinesia—Diminished or slow movement; seen in Parkinson disease.

hypophysis—Pituitary gland.

hypothermia—Reduced body temperature; seen in hypothalamic lesions.

hypotonia—Reduced muscle tone; seen in cerebellar disease.

ideational or sensory apraxia—Characterized by the inability to formulate the ideational plan for executing the several components of a complex multistep act; the patient cannot go through the steps of boiling an egg when asked to; occurs most frequently in diffuse cerebral degenerating disease (e.g., Alzheimer disease, multi-infarct dementia).

ideomotor or “classic” apraxia (ideokinetic apraxia)—Inability to button one’s clothes when asked, to comb one’s hair when asked, or to manipulate tools (e.g., hammer or screwdriver), although the patient can explain their use.

idiopathic—Denoting a condition of an unknown cause (e.g., idiopathic Parkinson disease).

infarction—Sudden insufficiency of blood supply caused by vascular occlusion (e.g., emboli or thrombi), resulting in tissue necrosis (death).

intention tremor—Tremor that occurs when a voluntary movement is made; a cerebellar tremor.

internal ophthalmoplegia—Paralysis of the iris and ciliaris caused by a lesion of the oculomotor nerve.

internuclear ophthalmoplegia (INO)—Medial rectus palsy on attempted conjugate lateral gaze caused by a lesion of the medial longitudinal fasciculus.

intra-axial—Refers to structures found within the neuraxis; within the brain or spinal cord.

ischemia—Local anemia caused by mechanical obstruction of the blood supply.

junction scotoma—results from a lesion of decussating fibers from the inferior nasal retinal quadrant, which loop into the posterior part of the contralateral optic nerve; in the contralateral upper temporal quadrant.

Kayser-Fleischer ring—Visible deposition of copper in Descemet membrane of the corneoscleral margin; seen in Wilson disease (hepatolenticular degeneration).

Kernig sign—Test for meningitis. Subject lies on back with thigh flexed to a right angle, then tries to extend the leg; this movement is impossible with meningitis.

kinesthesia—Sensory perception of movement, muscle sense; mediated by the posterior column-medial lemniscus system.

Klüver-Bucy syndrome—Characterized by psychic blindness, hyperphagia, and hypersexuality; results from bilateral temporal lobe ablation including the amygdaloid nuclei.

labyrinthine hydrops—Excess of endolymphatic fluid in the membranous labyrinth; cause of Ménière disease.

lacunae—Small infarcts associated with hypertensive vascular disease.

Lambert-Eaton myasthenic syndrome—Condition that results from a defect in presynaptic acetylcholine release; 50% of the patients have a malignancy.

lead-pipe rigidity—Rigidity characteristic of Parkinson disease.

Lewy bodies—Eosinophilic, intracytoplasmic inclusions found in the neurons of the substantia nigra in Parkinson disease.

Lhermitte sign—Electric-like shocks extending down the spine caused by flexing the head; results from damage of the posterior columns.

lipofuscin (ceroid)—Normal inclusion of many neurons and glial cells; increases as the brain ages.

Lish nodules—Pigmented hamartomas of the iris seen in neurofibromatosis type 1.

lissencephaly—Agyria; results from failure of the germinal matrix neuroblasts to reach the cortical mantle and form the gyri; the surface of the brain remains smooth.

locked-in syndrome—Results from infarction of the base of the pons; infarcted structures include the corticobulbar and corticospinal tracts, leading to quadriplegia and paralysis of the lower cranial nerves; patients can communicate only by blinking or moving their eyes vertically.

locus ceruleus—Pigmented (neuromelanin) nucleus found in the pons and midbrain; contains the largest collection of norepinephrinergic neurons in the brain.

macrographia (megalographia)—Large handwriting seen in cerebellar disease.

magnetic gait—Patient walks as if feet were stuck to the floor; seen in normal-pressure hydrocephalus.

medial longitudinal fasciculus (MLF)—Fiber bundle found in the dorsomedial tegmentum of the brainstem just under the fourth ventricle; it carries vestibular and ocular motor axons, which mediate vestibulo-ocular reflexes (e.g., nystagmus); severance of this tract results in internuclear ophthalmoplegia.

Mees lines—Transverse lines on fingernails and toenails; results from arsenic poisoning.

megalencephaly—Large brain weighing more than 1800 g.

meningocele—Protrusion of the meninges of the brain or spinal cord through an osseous defect in the skull or vertebral canal.

meningoencephalocele—Protrusion of the meninges and the brain through a defect in the skull.

meroanencephaly—Less severe form of anencephaly in which the brain is present in rudimentary form.

microencephaly (micrencephaly)—a small brain weighing less than 900 g. The adult brain weighs about 1400 g.

micrographia—Small handwriting seen in Parkinson disease.

microgyria (polymicrogyria)—Small gyri; the cortical lamination pattern is not normal; seen in Arnold-Chiari syndrome.

Millard-Gubler syndrome—Alternating abducent and facial hemiparesis; an ipsilateral sixth and seventh nerve palsy and a contralateral hemiparesis.

mimetic muscles—Muscles of facial expression; innervated by facial nerve (CN VII).

miosis—Constriction of the pupil; seen in Horner syndrome.

Möbius syndrome—Congenital oculofacial palsy; consists of a congenital facial diplegia (CN VII) and a convergent strabismus (CN VI).

mononeuritis multiplex—Vasculitic inflammation of several different nerves (e.g., polyarteritis nodosa).

MPTP (1-methyl-4-phenyl-1,3,3,6-tetrahydropyridine) poisoning—Toxic destruction of the dopaminergic neurons in the substantia nigra, resulting in parkinsonism.

multi-infarct dementia—Dementia owing to the cumulative effect of repetitive infarcts; strokes characterized by cortical sensory, pyramidal, and bulbar and cerebellar signs, resulting in permanent damage; primarily seen in hypertensive patients.

multiple sclerosis—Myelinoclastic disease in which the myelin sheath is destroyed, with the axon remaining intact; characterized by exacerbations and remissions with paresthesias, double vision, ataxia, and incontinence; cerebrospinal fluid findings include increased gamma globulin, increased beta globulin, presence of oligoclonal bands, and increased myelin basic protein.

muscular dystrophy—X-linked myopathy characterized by progressive weakness, fiber necrosis, and loss of muscle cells; two commonest types are Duchenne and myotonic muscular dystrophy.

mydriasis—Dilation of the pupil; seen in oculomotor paralysis.

myelopathy—Disease of the spinal cord.

myeloschisis—Cleft spinal cord resulting from failure of the neural folds to close or from failure of the posterior neuropore to close.

myoclonus—Clonic spasm or twitching of a muscle or a group of muscles as seen in juvenile myoclonic epilepsy; comprises single jerks.

myopathy—Disease of the muscle.

myotatic reflex—Monosynaptic muscle stretch reflex.

neglect syndrome—Result of unilateral parietal lobe lesion; neglect of one-half of the body and of extracorporeal space; simultaneous stimulation results in extinction of one of the stimuli and there is loss of optokinetic nystagmus on one side.

Negri bodies—Intracytoplasmic inclusions observed in rabies; commonly found in the hippocampus and cerebellum.

neuraxis—Unpaired part of the central nervous system: spinal cord, rhombencephalon, and diencephalon.

neurilemma—Neurolemma; the sheath of Schwann; Schwann cells (neurilemmal cells) produce the myelin sheath in the peripheral nervous system.

neurofibrillary tangles—Abnormal double helical structures found in the neurons of Alzheimer patients.

neurofibromatosis (von Recklinghausen disease)—A neurocutaneous disorder. Neurofibromatosis type 1 consists predominantly of peripheral lesions (e.g., café au lait spots, neurofibromas, Lish nodules, schwannomas). Type 2 consists primarily of intracranial lesions (e.g., bilateral acoustic schwannomas and gliomas).

neurohypophysis—Posterior lobe of the pituitary gland; derived from the downward extension of the hypothalamus, the infundibulum.

neuropathy—Disorder of the nervous system.

Nissl bodies/substance—Rough endoplasmic reticulum found in the nerve cell body and dendrites but not in the axon.

nociceptive—Capable of appreciation or transmission of pain.

normal-pressure hydrocephalus—Hydrocephalus characterized by normal cerebrospinal fluid pressure and the clinical triad of dementia, gait dystaxia (magnetic gait), and urinary incontinence; shunting is effective; mnemonic is **W**acky, **W**obbly, **W**et.

nucleus basalis of Meynert—Contains the largest collection of cholinergic neurons in the brain; located in the forebrain between the anterior perforated substance and the globus pallidus; neurons degenerate in Alzheimer disease.

nystagmus—Oscillations of the eyeballs; named after the fast component; seen in vestibular and cerebellar disease.

obex—Caudal apex of the rhomboid fossa; marks the beginning of the open medulla.

Ondine curse—Inability of patient to breathe while sleeping; results from damage to the respiratory centers of the medulla.

optokinetic nystagmus—Nystagmus induced by looking at moving stimuli (targets); also called railroad nystagmus.

otitis media—Infection of the middle ear, which can cause conduction deafness; can also cause Horner syndrome.

otorrhea—Discharge of cerebrospinal fluid via the ear canal.

otosclerosis—New bone formation in the middle ear resulting in fixation of the stapes; the most frequent cause of progressive conduction deafness.

palsy—Paralysis; often used to connote partial paralysis or paresis.

papilledema—Choked disk; edema of the optic disk; caused by increased intracranial pressure (e.g., tumor, epidural or subdural hematoma).

paracusis—Impaired hearing; an auditory illusion or hallucination.

paralysis—Loss of muscle power owing to denervation; results from a lower motor neuron lesion.

paraphrasia (paraphasia)—A form of aphasia in which a person substitutes one word for another, resulting in unintelligible speech.

paraplegia—Paralysis of both lower limbs.

paresis—Partial or incomplete paralysis.

paresthesia—Abnormal sensation such as tingling, pricking, or numbness; seen with posterior column disease (e.g., tabes dorsalis).

Parinaud syndrome—Lesion of the midbrain tegmentum resulting from pressure of a germinoma, a tumor of the pineal region; the patient has a paralysis of upward gaze.

Pick disease—Dementia affecting primarily the frontal lobes; spares the posterior third of the superior temporal gyrus; clinically indistinguishable from Alzheimer disease.

pill-rolling tremor—Tremor at rest; seen in Parkinson disease.

planum temporale—Auditory association cortex found posterior to the transverse gyri of Heschl on the inferior bank of the lateral sulcus; a part of Wernicke area; larger on the left side in males.

poikilothermia—Inability to thermoregulate; seen with lesions of the posterior hypothalamus.

polydipsia—Frequent drinking; seen in lesions of the hypothalamus (diabetes insipidus).

polyuria—Frequent micturition; seen with hypothalamic lesions (diabetes insipidus).

porencephaly—Cerebral cavitation caused by localized agenesis of the cortical mantle; the cyst is lined with ependyma.

presbycusis (presbyacusia)—The inability to perceive or discriminate sounds as part of the aging process; results from atrophy of the organ of Corti.

progressive supranuclear palsy—Characterized by supranuclear ophthalmoplegia, primarily a downgaze paresis followed by paresis of other eye movements; as the disease progresses, the remaining motor cranial nerves become involved.

proprioception—Reception of stimuli originating from muscles, tendons, and other internal tissues; conscious proprioception is mediated by the posterior column–medial lemniscus system.

prosopagnosia—Difficulty in recognizing familiar faces.

protopathic sensation—Pain, temperature, and light (crude) touch sensation; the modalities mediated by the anterolateral system.

pseudobulbar palsy (pseudobulbar supranuclear palsy)—Upper motor neuron syndrome resulting from bilateral lesions that interrupt the corticobulbar tracts; symptoms include difficulties with articulation, mastication, and deglutition; results from repeated bilateral vascular lesions.

psychic blindness—Type of visual agnosia seen in the Klüver–Bucy syndrome.

psychosis—Severe mental thought disorder.

ptosis—Drooping of the upper eyelid; seen in Horner syndrome and oculomotor nerve paralysis (CN III).

pyramidal (motor) system—Voluntary motor system consisting of upper motor neurons in the corticobulbar and corticospinal tracts.

quadrantanopia—Loss of vision in one quadrant of the visual field in one or both eyes.

quadriplegia—Tetraplegia; paralysis of all four limbs.

rachischisis—Spondyloschisis; failure of the vertebral arches to develop and fuse and form the neural tube.

raphe nuclei—Paramedian nuclei of the brainstem that contain serotonergic neurons.

Rathke's pouch—Ectodermal outpocketing of the stomodeum; gives rise to the adenohypophysis (anterior lobe of the pituitary gland).

retrobulbar neuritis—Optic neuritis frequently caused by the demyelinating disease multiple sclerosis.

rhinorrhea—Leakage of cerebrospinal fluid via the nose.

rigidity—Increased muscle tone in both extensors and flexors; seen in Parkinson disease; cogwheel rigidity and lead-pipe rigidity.

Romberg sign—Loss of balance when the subject stands with feet together and closes the eyes; a sign of posterior column ataxia.

saccadic movement—Quick jump of the eyes from one fixation point to another; impaired saccades are seen in Huntington disease.

scanning speech—Scanning dysarthria; words are broken up into syllables; typical of cerebellar disease and multiple sclerosis; example: I DID not GIVE any TOYS TO my son FOR CHRISTmas.

schizophrenia—Psychosis characterized by a disorder in the thinking processes (e.g., delusions and hallucinations); associated with dopaminergic hyperactivity.

scotoma—Blind spot in the visual field.

senile (neuritic) plaques—Swollen dendrites and axons, neurofibrillary tangles, and a core of amyloid; found in Alzheimer disease.

shagreen spots—Cutaneous lesions found in tuberous sclerosis.

shaken baby syndrome—Syndrome with three major physical findings: retinal hemorrhages, large head circumference, and bulging fontanelle; 80% of the subdural hemorrhages are bilateral.

sialorrhea (ptyalism)—Excess of saliva (e.g., drooling)—seen in Parkinson disease.

singultus—Hiccups; frequently seen in the posterior inferior cerebellar artery syndrome.

simultanagnosia—Inability to understand the meaning of an entire picture even though some parts may be recognized; the inability to perceive more than one stimulus at a time.

somatesthesia—Somesthesia; bodily sensations that include touch, pain, and temperature.

spastic paresis—Partial paralysis with hyperreflexia resulting from transection of the corticospinal tract.

spasticity—Increased muscle tone (hypertonia) and hyperreflexia (exaggerated muscle stretch reflexes); seen in upper motor neuron lesions.

spina bifida—Neural tube defect with the variants: spina bifida occulta, spina bifida with meningocele, spina bifida with meningocele, and rachischisis; results from failure of the vertebral laminae to close in the midline.

status marmoratus—Hypermyelination in the putamen and thalamus; results from perinatal asphyxia; clinically presents as double athetosis.

stereoaesthesia—Astereognosis; inability to judge the form of an object by touch.

Stiff-man syndrome—Myopathy characterized by progressive and permanent stiffness of the muscles of the back, neck, and spreading to involve the proximal muscles of the limbs; caused by a disturbance of the inhibitory action of Renshaw cells in the spinal cord.

strabismus—Lack of parallelism of the visual axes of the eyes; squint; heterotropia.

stria medullaris (of the thalamus)—Fiber bundle extending from the septal area to the habenular nuclei.

stria terminalis—Semicircular fiber bundle extending from the amygdala to the hypothalamus and septal area.

striae medullares (of the rhombencephalon)—Fiber bundles that divide the rhomboid fossa into a rostral pontine part and a caudal medullary part.

Sturge-Weber syndrome—Neurocutaneous congenital disorder including a port-wine stain (venous angioma) and calcified leptomeningeal angiomatoses (railroad track images seen on plain film); seizures occur in up to 90% of patients.

subclavian steal syndrome—Occlusion of the subclavian artery, proximal to the vertebral artery, resulting in a shunting of blood down the vertebral and into the ipsilateral subclavian artery; physical activity of the ipsilateral upper limb may cause signs of vertebrobasilar insufficiency (dizziness or vertigo).

sulcus limitans—Groove separating the sensory alar plate from the motor basal plate; extends from the spinal cord to the mesencephalon.

sunset sign—Downward look by eyes; the sclerae are above the irides and the upper eye lids are retracted; seen in congenital hydrocephalus and in progressive supranuclear palsy.

swinging flashlight sign—Test to diagnose a relevant afferent pupil; light shone into the afferent pupil results in a small change in pupil size bilaterally, and light shone into the normal pupil results in a decrease in pupil size in both eyes.

sympathetic apraxia—Motor apraxia (in the left hand); seen in lesions of the dominant frontal lobe.

syringomyelia—Cavitation of the cervical spinal cord resulting in bilateral loss of pain and temperature sensation and wasting of the intrinsic muscles of the hands; syringes may be found in the medulla (syringobulbia) and pons (syringopontia) and in Arnold-Chiari malformation.

tabes dorsalis—Locomotor ataxia; progressive demyelination and sclerosis of the posterior columns and roots; seen in neurosyphilis.

tactile agnosia—Inability to recognize objects by touch.

tardive dyskinesia—Syndrome of repetitive, choreoathetoid movements frequently affecting the face; results from treatment with antipsychotic agents.

Tay-Sachs disease (GM2 gangliosidosis)—Inherited metabolic disease of the central nervous system; characterized by motor seizures, dementia, and blindness; a cherry-red spot (macula) occurs in 90% of cases; caused by a deficiency of hexosaminidase A.

tethered cord syndrome (filum terminale syndrome)—Syndrome characterized by numbness of the legs and feet, foot drop, loss of bladder control, and impotence.

thrombus—Clot in an artery that is formed from blood constituents; gives rise to an embolus.

tic douloureux—Trigeminal neuralgia.

tinnitus—Ringing in the ear(s); seen with irritative lesions of the cochlear nerve (e.g., acoustic neuroma).

titubation—A head tremor in the anterior-posterior direction, often accompanying midline cerebellar lesions; is also a staggering gait.

tremor—Involuntary, rhythmic, oscillatory movement.

tuberous sclerosis (Bourneville disease)—Neurocutaneous disorder characterized by the trilogy of mental retardation, seizures, and adenoma sebaceum; cutaneous lesions include periungual fibromas, shagreen patches, and ash-leaf spots.

uncinate fit—Form of psychomotor epilepsy, including hallucinations of smell and taste; results from lesions of the parahippocampal gyrus (uncus).

upper motor neurons (UMNs)—Cortical neurons that give rise to the corticospinal and corticobulbar tracts; destruction of UMNs or their axons results in a spastic paresis; some authorities include brainstem neurons that synapse on lower motor neurons (i.e., neurons from the red nucleus).

vertigo—Sensation of movement owing to vestibular disease.

visual agnosia—Inability to recognize objects by sight.

von Hippel-Lindau disease—Disorder characterized by lesions of the retina and cerebellum; retinal and cerebellar hemangioblastomata; non-central nervous system lesions may include renal, epididymal, and pancreatic cysts as well as renal carcinoma.

Wallenberg syndrome—Condition characterized by hoarseness, cerebellar ataxia, anesthesia of the ipsilateral face and contralateral body, and cranial nerve signs of dysarthria, dysphagia, dysphonia, vertigo, and nystagmus; results from infarction of the lateral medulla owing to occlusion of the vertebral artery or its major branch, the posterior inferior cerebellar artery; Horner syndrome is frequently found on the ipsilateral side.

Wallerian degeneration—Anterograde degeneration of an axon and its myelin sheath after axonal transection.

Weber syndrome—Lesion of the midbrain basis pedunculi involving the root fibers of the oculomotor nerve and the corticobulbar and the cortospinal tracts.

Werdnig-Hoffman syndrome (spinal muscular atrophy)—Early childhood disease of the anterior horn cells (lower motor neuron disease).

Wernicke aphasia—Difficulty in comprehending spoken language; also called receptive, posterior, sensory, or fluent aphasia.

Note: Page numbers followed by f indicate illustrations; those followed by t indicate tables; and those followed by Q indicate end-of-chapter Question and Answer sections.

A

- Abducens nucleus, 18f
- Abducent nerve, 7f, 9, 12f, 13f, 151, 339t
 - anatomy of, 146f, 148f, 151
 - clinical correlations for, 151
- Abducent nucleus, 134f, 136, 143Q, 148f
- Abscess, brain, 85f
- Abulia, 297
- Accessory cuneate nucleus, 131f, 132
- Accessory nerve, 2f, 7f, 10, 156, 159Q, 341t
 - anatomy of, 148f, 156
 - clinical correlations for, 156
- Accessory oculomotor, 148f
- Accessory oculomotor nucleus, 68, 141, 148f, 149, 272, 273
- Accommodation, visual, 227, 228f
- Acervulus, 34
- Acetylcholine, 270, 276Q, 279–280, 279f, 291Q
 - clinical correlations for, 287–288
 - in striatal system, 254
- Achilles reflex, 102Q
- Achromatopsia, 303
- Acoustic neuroma, 169, 176–177, 177f, 206, 219Q
- Acoustic schwannoma, 217
- Acute idiopathic polyneuritis, 120, 126Q
- Adenohypophysis, 69, 194, 195f
- Adie pupil, 231
- Afferent pupil, 230, 230f
- Agensis, 74
- Ageusia, 153, 239
- Agnosia
 - finger, 296
 - tactile, 294, 307Q
- Agraphesthesia, 300f
- Agraphia, 296, 303
- Akinesia, 343
- Akinetic mutism, 297
- Alar plate, 64–66, 65f, 66f, 68, 68f, 77Q
- Albuminocytologic dissociation, 120
- Alcohol, fetal injury from, 75
- Alexia, 299, 302, 303, 306Q
- Allocortex, 70, 293
- Altitudinal hemianopia, 223f, 225
- Alzheimer disease, 288, 292Q
- Amacrine cells, 222
- Ambient cistern, 28, 36Q
- Amino acid transmitters, 284–287, 286, 287f
 - excitatory, 286–287, 287f
 - inhibitory, 286, 286f
- Ampullae, 66f
- Amygdala, 20f, 21f, 43f, 250f
 - anatomy of, 14f, 15f, 20f, 21f, 241–242, 243f, 245Q
 - lesions of, 243, 245Q
- Amygdaloid nuclear complex, 198Q, 240
- Amygdaloid nucleus, 243f, 244
- Amyotrophic lateral sclerosis, 118f, 120, 125Q
- Amyotrophy, 117
- Anencephaly, 72
- Anesthesia, 121f, 156, 188
- Aneurysms
 - aortic, 156
 - berry, 52, 52f, 56Q
 - Charcot-Bouchard, 52
 - definition of, 52
 - oculomotor nerve compression by, 149
- Angiography
 - carotid, 48, 48–50f
 - cerebral, 48–49, 48–51f
 - vertebral, 48f, 49, 50f, 51f
- Angular gyrus, 3f, 4
- Anhidrosis, 122
- Anisocoria, 229, 232Q
- Ankle jerk reflex, 102Q
- Annulus fibrosus, herniation through, 124
- Anomia, 301
- Anosmia, 146, 159Q, 237
- Anosognosia, 299
- Anterior aphasia, 298
- Anterior cerebral artery, 32f, 41f, 43f, 44, 48–51f, 56Q
 - occlusion of, 302
- Anterior choroidal artery, 41f, 42, 43f, 48f
- Anterior commissure, 4f, 7, 11f, 13f, 14f, 19f, 21f
 - development of, 71
- Anterior communicating artery, 41f, 44, 50f
- Anterior cord syndrome, 122, 122f
- Anterior corticospinal tract, 109, 110f, 111f, 114Q, 119, 121, 126Q
 - lesions of, 118f, 119, 121f
 - transection of, 121, 122f
- Anterior funiculus, 98f
- Anterior horn, 28, 29f, 63f, 64, 98f, 130f
 - destruction of, 122, 122f, 125Q
 - motor neurons of, 214
- Anterior inferior cerebellar artery (AICA) syndrome, 41f, 48f, 56Q, 174, 174f, 180Q
- Anterior internal frontal artery, 42f
- Anterior lateral sulcus, 98
- Anterior lobe, 69f
 - of cerebellum, 10, 258, 259f
- Anterior median fissure, 63f, 98, 98f
- Anterior medullary velum, 5f
- Anterior meningeal artery, 45
- Anterior neuropore, 59, 59f
- Anterior nucleus, 5f, 15f
 - hypothalamic, 191, 191f, 198Q
 - olfactory, 239
 - thalamic, 183, 185f, 186f, 197Q, 239, 243
- Anterior paracentral lobule, 2
- Anterior parietal artery, 42f
- Anterior perforated substance, 3f, 6, 7f, 14f, 20f
- Anterior ramus, 25f, 96f, 97
- Anterior root, 25f, 95f, 96, 96f
- Anterior spinal artery, 39, 40f, 41f, 44
 - occlusion of, 118f, 122, 122f, 126Q

- Anterior spinocerebellar tract, 106, 107f, 108f, 111f, 121f, 130f, 131f, 132f, 133, 134f, 135f
 lesions of, 118f, 120
 transection of, 121, 122f
- Anterior spinothalamic tract, 106, 111f, 114Q
 lesions of, 118f, 120
 transection of, 121, 122f
- Anterior temporal artery, 42f, 43f
- Anterior trigeminothalamic tract, 164–165, 164f
- Anterior vermis syndrome, 264, 266Q
- Anterior white commissure, 98f, 106, 121f
- Anterograde degeneration, 84f, 86, 91Q
- Anterograde transport, 87
- Anterolateral sulcus, 98f
- Antigonadotrophic function, 35
- Aortic aneurysm, 156
- Aphasia, 296, 304–305, 307Q
 basal nuclei, 305
 Broca, 297–298, 304, 306Q, 307Q, 308Q
 conduction, 298, 305, 307Q, 308Q
 global, 305
 thalamic, 305
 transcortical mixed, 305
 transcortical motor, 305
 transcortical sensory, 305
 watershed, 305
 Wernicke, 296, 298, 304, 307Q, 308Q
- Aphasia square, 304f
- Apraxia, 294, 303–304
 construction, 299, 304, 306Q
 dressing, 299
 facial, 295
 gait, 304
 ideational, 294, 303
 ideomotor, 294, 303
 sensory, 294, 307Q
 sympathetic, 297, 298
- Aqueduct of Sylvius. *See* Cerebral aqueduct
- Aqueductal stenosis, 73f
- Arachnoid, 24–25, 25f
- Arachnoid granulations, 24–25, 27f
- Arachnoid villus, 24–25, 30
- Archicortex, 70, 293
- Arcuate fasciculus, 298
- Arcuate nucleus, 131f, 132, 132f, 191f, 192, 196, 198Q
- Area postrema, 10, 34, 34f, 35, 133
- Area subcallosa, 4f
- Areflexia, 113, 117, 121f
- Argyll Robertson pupil, 230, 230f, 232Q
- Arhinencephaly, 75
- Arnold–Chiari malformation, 73–74, 73f, 77Q
- Arterial circle of Willis, 41f, 45, 189
- Arteries. *See also specific arteries*
 autonomic innervation of, 270t, 274
 of brain, 41–45, 41–44f
 of spinal cord, 39, 40f
- Artery of Adamkiewicz, 39, 40f
- Ascending branch of lateral sulcus, 3f
- Ascending cervical artery, 40f
- Ascending sensory pathways, of pons, 134, 135f
- Ascending spinal tracts, 104–109, 105f, 107f, 111f
- Aseptic meningitis, 31, 31t
- Aspartate, 286, 286f, 291Q
- Astatognosis, 307Q
- Astereognosis, 294, 299, 307Q
- Astrocyte, 62, 82, 91Q
- Astrocytoma, 83–86, 85f, 265, 266Q
- Astroglia, 62
- Atrium, 28, 29f
- Auditory association cortex, 295f, 296
- Auditory pathway, 204–206, 204f
- Auditory radiation, 204f, 205
- Auditory system, 202–210. *See also under* Hearing
 brainstem auditory evoked responses and, 207, 208f, 209Q
 disorders of, 207
 ear in, 202–204
 overview of, 202
 peripheral/central connections in, 204f
- Autonomic ganglion, 60
- Autonomic nervous system, 268–277
 clinical correlations for, 275
 divisions of, 268–272
 enteric, 272
 organs innervated by, 269f, 270t, 271f, 273–274
 overview of, 268
 parasympathetic, 270–272, 270t, 271f
 sympathetic, 268–270, 269f, 270t
- Axon(s), 81
 motor, 82t
 regeneration of, 87
 sensory, 82t
- Axon hillock, 80f
- Axonal transport, 87, 91Q
- B**
- Babinski sign, 113, 119, 180Q, 307Q
- Bacterial meningitis, 31, 31t, 36Q
- Ballism, 255
- Basal ganglia, anatomy of, 6, 7f
- Basal nucleus, 249, 250f, 305
 development of, 70
 of Meynert, 280
- Basal plate, 63f, 64, 65f, 66f, 67, 68, 68f
- Basilar artery, 11f, 40f, 41, 41f, 48f, 50f, 51f
- Basilar membrane, 203
- Basis pedunculi, 13f, 20f, 21f, 43f, 68, 109, 137f, 138, 139
- Bell palsy, 153
- Benedikt syndrome, 175–176, 176f
- Benign intracranial hypertension, 31, 36Q
- Benign positional vertigo, 217, 219Q
- Berry aneurysm, 52, 56Q
- Binasal hemianopia, 224, 232Q
- Bipolar neurons, 79, 80f, 222
 of spiral ganglion, 203
 of vestibular ganglion, 203, 212f, 214
- Bitemporal hemianopia, 224, 232Q, 233Q
- Bitemporal lower quadrantanopia, 52
- Bladder, autonomic innervation
 of, 270t, 274
- Blood vessels. *See also* Arteries; Veins
 autonomic innervation of, 270t, 274
- Blood–brain barrier, 87, 88f
- Blood–CSF barrier, 83, 88f
- Bony labyrinth, 203
- Botulism, 275
- Brachium conjunctivum, 5f
- Brachium of inferior colliculus, 5f, 9, 138
- Brachium of superior colliculus, 3f, 9
- Brachium pontis, 5f
- Bradykinesia, 254
- Brain
 abscess of, 85f
 anatomy of, 1–21
 arteries of, 41–45, 41–44f
 axial section of, 19, 19–21f
 coronal section of, 14–18f

- divisions of, 1–21. *See also* Cerebellum; Diencephalon; Medulla oblongata; Mesencephalon; Pons; Telencephalon
 - herniation of, 32–33, 32–33f, 149, 230–231, 230f, 232Q
 - inferior surface of, 3f
 - lateral surface of, 3f
 - medial surface of, 4f
 - midsagittal section of, 4f, 11f
 - parasagittal section of, 12f, 13f
 - tumors of, 36Q, 83–86, 85f, 91Q, 265, 266Q
 - veins of, 45–46, 51f
 - vesicles of, development of, 61–62, 61f
 - Brain sand, 34
 - Brainstem, 129–144, 130f. *See also* Medulla oblongata; Mesencephalon; Pons
 - anatomy of, 5f, 130f, 140f
 - corticobulbar pathways in, 140f, 142
 - lesions of, 172–182
 - acoustic neuroma, 176–177
 - internuclear ophthalmoplegia and, 177
 - in jugular foramen syndrome, 177–178
 - of medulla, 172–173
 - of mesencephalon, 175–176
 - neoplastic, 175–176
 - of pons, 173–175
 - in subclavian steal syndrome, 178
 - vascular, 172–173, 173f
 - overview of, 129
 - tumors of, 85f, 175–176
 - Brainstem auditory evoked response, 207, 208f, 209Q
 - Branchial striated muscle (larynx), 66f
 - Bridging veins. *See* Superior cerebral veins
 - Broca aphasia, 298, 304, 306Q, 307Q, 308Q
 - Broca speech area, 295f, 297–298, 298f, 306Q, 307Q
 - Brodman areas, 294–297, 295f
 - Brown–Séquard syndrome, 118f, 121, 122f, 126Q
 - Buccofacial apraxia, 295
- C**
- Calcareous granules, 34
 - Calcarine artery, 43f, 48f, 50f, 51f
 - Calcarine sulcus, 3f, 4f, 11f, 12f
 - Callosomarginal artery, 42f, 48f, 49f
 - Caloric nystagmus, 215f, 216, 218Q
 - Cancer. *See* Tumors
 - Capillaries, 87, 88f
 - Carotid angiography, 48, 48–50f
 - Carotid artery, 22Q
 - aneurysms of, 149
 - Carotid body, 155, 273
 - Carotid sinus, 155, 273
 - Carotid sinus reflex, 155
 - Catecholamines, 278. *See also* Neurotransmitters
 - synthesis of, 279f
 - Cauda equina, 26f, 64, 96
 - Cauda equina syndrome, 122f, 123, 126Q
 - Caudal rhombencephalon, 64
 - Caudate, 76f
 - Caudate nucleus, 5f, 6, 7f, 12–20f, 19f, 22Q, 43f, 70f, 250, 250f, 251f
 - Cavernous internal carotid artery, 49f, 50f, 51f
 - Cavernous sinus, 47, 49f, 162, 163, 168f
 - thrombosis of, 56Q
 - Cavernous sinus syndrome, 169
 - Celiac ganglion, 276Q
 - Center of Budge, 99, 102Q
 - Central canal, 27f, 98f, 130f, 131f
 - Central facial palsy, 154
 - Central nervous system. *See also* Brain; Spinal cord
 - congenital malformations of, 71–76
 - development of, 58–78
 - tumors of, 83–86, 85f
 - Central retinal artery, 221
 - Central sulcus, 3f, 4f, 11f, 12f, 13f
 - Central tegmental tract, 131f, 132, 132f, 135, 135f, 139, 141, 239
 - Centromedian nucleus, 184, 185f, 186f, 197Q
 - Cephalic flexure, 62
 - Cerebellar anlage, 67
 - Cerebellar astrocytoma, 83–84, 85f
 - Cerebellar atrophy, 265
 - Cerebellar cortex, 258, 260–261, 260f, 261f
 - Cerebellar pathways, 132–133
 - Cerebellar peduncles, 5f
 - inferior, 10, 12f, 13f, 18f, 108f, 109, 131–132f, 133, 134f, 135, 135f, 137f, 259
 - middle, 7f, 10, 17f, 134f, 135, 135f, 260, 262f
 - superior, 10, 12f, 18f, 108f, 109, 134f, 135, 135f, 137f, 260, 262f
 - Cerebellar vermis, 74f
 - Cerebello-olivary degeneration, 265
 - Cerebellomedullary cistern, 27, 27f
 - Cerebellopontine angle cistern, 27
 - Cerebellum, 3f, 4f, 21f, 61f, 67f, 258–267
 - anatomy of, 2f, 4f, 10, 258–263, 259f
 - clinical correlations for, 264–265, 266Q
 - development of, 67
 - divisions of, 258–260, 259f
 - hemispheres, 258, 259f
 - lateral hemispheric pathway, 263
 - lobes, 10, 213f, 214, 258–259, 259f, 262f
 - longitudinal zones, 259, 259f
 - overview of, 258
 - paravermal spinocerebellar pathway, 263
 - vermal spinocerebellar pathway, 262–263
 - vermis, 258, 259f
 - vestibulocerebellar pathway, 262
 - Cerebral angiography, 48–49, 48–51f
 - Cerebral aqueduct, 4f, 9, 11f, 17f, 20f, 21f, 27f, 28–29, 29f, 61f, 67, 68f, 74f, 137f, 138, 139, 144Q
 - stenosis of, 75
 - Cerebral arterial circle, 189
 - Cerebral commissures, 4f, 7
 - Cerebral cortex, 7, 293–310
 - arcuate fasciculus, 298
 - blood supply of, 302–303
 - corpus callosum, 298–299
 - development of, 70, 70f
 - hemispheric dominance in, 299, 300f
 - layers of, 293
 - motor areas of, 297
 - overview of, 293
 - prefrontal, 297
 - sensory areas of, 294–297, 295f, 296f
 - speech areas of, 298
 - split-brain syndrome and, 301–302, 301f
 - Cerebral dominance, 299, 300f
 - Cerebral hemispheres, 1–2, 2–5f, 61f
 - development of, 70, 70f
 - dominance of, 299–300, 300f
 - split-brain syndrome and, 301–302, 301f
 - Cerebral herniation, 32, 32–33f, 33, 149
 - Cerebral veins, 46, 51f
 - Cerebrospinal fluid, 30
 - excessive accumulation of, 30–31, 36Q, 37Q, 75, 75f
 - in meningitis, 31–32, 31f
 - properties of, 30, 37Q

- Cervical cord, 94f, 95, 100, 102Q
 Cervical enlargement, 95
 Cervical flexure, 62
 Cervical internal carotid artery, 49f
 Cervical spondylosis with myelopathy, 124, 126Q
 Charcot-Bouchard aneurysm, 52
 Charcot-Marie-Tooth disease, 118f, 124
 Chemical synapses, 82
 Chief sensory nucleus, 130f, 135f, 136, 164, 164f
 Choked disk, 147, 231
 Choline acetyltransferase, 288
 Cholinergic neurons, 80, 80f
 Chorda tympani, 152, 153f
 Chorea, 254–255
 Chorea gravidarum, 255
 Choreiform dyskinesias, 255
 Choriocapillaris, 220, 221
 Choroid plexus, 8, 9, 19f, 65f, 66f
 anatomy of, 12f, 18f, 19f, 30
 cells of, 63
 in cerebrospinal fluid production, 30
 development of, 66, 77Q
 papilloma of, 85
 Chromaffin cells, 60
 Ciliary ganglion, 149, 226, 272, 276Q
 Ciliospinal center, 99, 102Q, 111, 112f
 in pupillary dilation, 227, 228f
 Cingulate gyrus, 3f, 4f, 6, 12f, 17f, 22Q, 239, 243
 lesions of, 244
 Cingulate sulcus, 4f, 13f
 Cingulum, 12f
 Circle of Willis, 41f, 45
 Circuit of Papez, 239, 241f, 243, 245Q
 Circumventricular organs, 34–35
 Cisterna magna, 27
 Clasp-knife spasticity, 119, 126Q
 Claustrum, 14f, 15f, 16f, 19f, 250f
 Climbing fibers, 261
 Clonus, 113, 119
 Coccygeal cord segment, 94f, 95
 Coccygeal ligament, 24, 26f
 Coccygeal segment, 100
 Coccygeal vertebrae, 94f, 95
 Cochlea, 66f, 203
 Cochlear duct, 203, 212f
 Cochlear nerve, 130f, 154, 203, 204f, 340t
 Cochlear nucleus, 65, 66, 204f, 205
 Collateral sulcus, 2f, 3f, 4f
 Collateral trigone, 29f
 Colloid cyst of third ventricle, 85f
 Commissure of fornix, 8
 Commissurotomy, split-brain syndrome and,
 301–302, 301f
 Communicating hydrocephalus, 30, 75
 Complete internal ophthalmoplegia, 170Q
 Conduction aphasia, 298, 305, 307Q, 308Q
 Conduction deafness, 206
 Cones, 220–222
 Confluence of sinuses, 27f, 46, 49f, 51f, 57Q, 74f
 Congenital aganglionic megacolon, 275, 276Q
 Construction apraxia, 299, 304, 306Q
 Contralateral homonymous hemianopia, 224, 225, 231,
 232Q, 296, 307Q
 Conus medullaris, 26f, 27f, 40f, 64, 77Q, 94f, 95
 Conus medullaris syndrome, 122f, 123
 Convergence-accommodation reaction,
 227–228, 228f
 Convergence nucleus, 227
 Convergent strabismus, 151
 Corneal Kayser-Fleischer ring, 255
 Corneal reflex, 152f, 153, 159Q, 163, 165, 167, 233Q
 Corpus callosum, 4f, 7, 12f, 14f, 15–17f, 73f, 74f, 250f,
 298–299
 development of, 71
 infarction of, 302
 transection of, split-brain syndrome and,
 300–301, 301f
 Corpus striatum, 249
 development of, 70
 Cortex, 76f
 Corticobulbar pathways, 140f, 142
 Corticobulbar tract, 135, 140f, 158f, 263
 Corticopontine neuron, 262f
 Corticopontine tract, 135, 137f
 Corticopontocerebellar tract, 263
 Corticospinal fibers, 12f
 Corticospinal neuron, 262f
 Corticospinal tract, 70f
 Cranial epidural space, 26
 Cranial nerves, 2f, 7f, 145–161, 339–341t. *See also*
 specific nerves
 Craniopharyngioma, 69, 69f, 85f, 196, 199Q, 233Q
 Cranium bifidum, 72–73, 72f
 Cribriform plate fracture, 237, 245Q
 Crocodile tears syndrome, 154
 Crus cerebri, 7f, 15f, 16f, 32f, 68, 69f, 109, 137f, 139
 Cuneate nucleus, 65f
 Cuneate tubercle, 5f, 10
 Cuneocerebellar tract, 108f, 109, 114Q
 Cuneus, 4f, 6, 11f, 225
 Cuprolithiasis, 217
 Cutaneous mechanoreceptors, 89–90, 89f
 Cycloplegia, 149
 Cyst, colloid, 85f
 Cytoskeleton, 81
- D**
- Dandy-Walker syndrome, 74, 74f
 Deafness, 154, 206, 210Q, 296
 tests for, 207, 208f, 209Q
 Decerebrate rigidity, 216
 Decorticate rigidity, 216
 Decussation of superior cerebellar peduncle, 11f, 17f,
 137f, 139, 143Q
 Decussation of trochlear nerve, 137f
 Deep cerebral veins, 46
 Dejerine-Thomas syndrome, 265
 Dendrites, 81
 Dentate gyrus, 4f, 6, 240
 Dentate nucleus, 13f, 134f, 262f, 263
 Dentatorubrothalamic tract, 176
 Denticulate ligament, 24, 25f, 93
 Depression, 282
 Dermatomes, 97, 97f
 Descending motor pathways
 of medulla oblongata, 130f, 132
 of pons, 135, 135f
 Descending raphe-spinal pathway, 287
 Descending spinal tracts, 109–111, 110–111f, 112f
 Development, of nervous system, 58–78
 Diabetes insipidus, 191
 Diabetic oculomotor palsy, 149
 Diagonal band nucleus, 14f
 Diagonal band of Broca, 3f, 6, 242, 245Q
 Diaphragma sellae, 25
 Diencephalon
 anatomy of, 5f, 7f, 8–9, 22Q
 development of, 61, 61f, 62, 68
 Diplegia, 199

Diplopia, 149
 horizontal, 151
 vertical, 150
 Disequilibrium, 154
 in cerebellar dysfunction, 264
 Doll's head eye phenomenon, 215, 215f
 Dopamine, 192, 276Q, 280–281, 280f, 291Q
 clinical correlations for, 288
 in striatal system, 254
 Dorsal accessory olivary nucleus, 131f
 Dorsal cochlear nucleus, 132f, 136, 204f, 205
 Dorsal intermediate sulcus, 5f
 Dorsal longitudinal fasciculus, 193f, 194, 198Q
 Dorsal median sulcus, 5f
 Dorsal midbrain syndrome, 179Q, 230f
 Dorsal motor nucleus, 65, 66, 130f, 131f, 133, 272
 of the vagus, 148f
 Dorsal nucleus of Clarke, 98f
 Dorsal tegmental nucleus, 137f, 139
 Dorsolateral sulcus, 5f
 Dorsomedial nucleus, 184, 185f, 186f, 191, 191f, 197Q, 237, 239, 244
 Double vision. *See* Diplopia
 Down syndrome, 77
 Dressing apraxia, 299
 Dura mater, 25, 25f, 26f
 Dural sinuses, 25, 27f
 Duret hemorrhage, 32f
 Dysarthria
 in cerebellar dysfunction, 264
 in vagal nerve dysfunction, 156
 Dyscalculia, 296
 Dysdiadochokinesia, 264
 Dysmetria, 264
 Dysphagia, in vagal nerve dysfunction, 156, 157f
 Dysphonia, 156, 157f
 Dyspnea, 156
 Dysprosodies, 305
 expressive, 305
 receptive, 305
 Dysprosody, 296, 299, 307Q
 Dyssynergia, in cerebellar dysfunction, 264
 Dystaxia, 264

E

Ear
 anatomy of, 202–204
 disorders of, 206, 210Q
 inner, 203, 211–213, 212f
 middle, 203, 210Q
 outer, 152, 202
 Edinger–Westphal nucleus, 141, 149
 Efferent cochlear bundle, 206
 Electrical synapses, 82
 Emboliform nucleus, 134f, 262f
 Encephaloceles, 72–73, 72f
 End feet, 83
 Endolymph, 213
 Endorphins, 283, 283f, 291Q
 Enkephalins, 283, 284f
 Enteric nervous system, 272. *See also* Autonomic nervous system
 Ependyma, 76f
 Ependymal cells, 62, 83
 Ependymocytes, 62
 Ependymoma, 85f, 86, 265
 Epiconus syndrome, 122f, 123, 126Q
 Epidural hemorrhage (hematoma), 33f, 34f, 45, 53, 53f, 56Q

Epidural space, 25f
 Epidural veins, 25f
 Epinephrine, 270
 Epithalamus, 5f, 8, 68
 Equilibrium, 154
 Esotropia, 151
 Ethmoid fracture, 237, 245Q
 Exotropia, 179f
 Expressive aphasia, 298
 Expressive dysprosody, 299, 305, 307Q
 External capsule, 3f
 External ear, 152, 202
 External granular layer, 67
 Extrapramidal motor system, 249. *See also* Striatal motor system
 clinical correlations for, 254–255
 components of, 249–251
 neurotransmitters of, 253–254
 overview of, 249
 Eye. *See also under* Ocular; Optic; Visual
 autonomic innervation of, 270t, 273

F

Facial apraxia, 295
 Facial colliculus, 5f, 9
 Facial expression muscles, 153
 Facial motor nucleus, 148f
 Facial nerve, 2f, 7f, 9, 27, 151–154, 159Q, 340t
 anatomy of, 146f, 148f, 151–154, 153f
 clinical correlations for, 153–154
 corticobulbar innervation of, 141f, 142
 in lacrimal pathway, 152, 153f
 in parasympathetic nervous system, 272
 in submandibular pathway, 152–153, 153f
 Facial nucleus, 134f, 136, 143Q
 False porencephaly, 75f, 76
 Falx cerebri, 25
 Familial dysautonomia, 275
 Fasciculations, 117
 Fasciculus cuneatus, 5f, 104, 105f, 111f, 114Q, 121f, 129, 130f, 131f
 Fasciculus gracilis, 5f, 104, 105f, 111f, 114Q, 121f, 129, 130f, 131f
 Fasciculus interfascicularis, 111f
 Fasciculus proprius, 112
 Fasciculus septomarginalis, 111f
 Fastigial nucleus, 134f, 263
 Fenestrated capillaries, 87, 88f
 Fetal alcohol syndrome, 75
 Fibrillations, 117
 Fibrous astrocytes, 82
 Fields of Forel, 8
 Filum terminale, 24, 26f, 27f, 76, 94, 123
 Filum terminale syndrome, 76
 Finger agnosia, 296, 306Q
 First-order neurons, 104, 114Q
 anterior spinocerebellar tract, 107f, 109
 anterior spinothalamic tract, 106
 anterior trigeminothalamic tract, 164
 cuneocerebellar tract, 108f, 109
 gustatory, 238
 lateral spinothalamic tract, 106, 107f
 posterior column–medial lemniscus pathway, 104, 105f
 posterior spinocerebellar tract, 106–107, 108f
 posterior trigeminothalamic tract, 165
 Fissures, cerebellar, 10
 5-Hydroxytryptamine, 282–283, 282f
 Flaccid paralysis, 113, 151, 153

Flocculonodular lobe, 10, 212f, 214, 259, 259f, 262
 Flocculus, 2f, 10
 Floor plate, 63f, 64, 66f
 Folded neural tissue, 72f
 Folia of cerebellum, 10
 Foramen magnum, 73f
 Foramen ovale, 163
 Foramen rotundum, 163
 Foramen spinosum, 45, 160Q
 Forebrain, development of, 61, 61f, 70–71, 70f
 Fornical commissure. *See* Hippocampal commissure
 Fornix, 11f, 15–20f, 19f, 22Q, 191f, 193f, 194, 198Q, 242, 250f
 Fornix column, 4f
 Foster Kennedy syndrome, 233Q, 237, 245Q
 Fourth ventricle, 65f, 67f, 73f
 anatomy of, 4f, 11f, 27f, 29, 29f, 66f
 development of, 66
 Fovea centralis, 220
 Fracture
 cribriform plate, 237, 245Q
 skull, 35
 Friedreich hereditary ataxia, 118f, 123, 126Q, 265, 266Q
 Frontal eye field, 228, 295f, 297
 Frontal horn, 28, 29f
 Frontal lobe, 1–2, 4f, 308Q
 Frontal lobe syndrome, 297
 Frontopolar artery, 42f
 Frontopolar branch, 49f
 Fusiform gyrus, 5

G

Gag reflex, 156, 159Q
 Gait apraxia, 304
 Gamma-aminobutyric acid (GABA), 286, 286f, 289Q
 clinical correlations for, 288
 in striatal system, 253, 256Q
 Gamma motor neurons, 90
 Gamma rigidity, 216
 Ganglia, autonomic, 60
 Ganglion cells, 222, 224, 226, 226f
 Gasserian ganglion, 162
 General somatic afferent (GSA) fibers, 64, 65, 65–67f, 95, 96f, 162
 General somatic efferent (GSE) fibers, 65, 65–67f, 77Q, 95, 96f
 General visceral afferent (GVA) fibers, 64, 65–67f, 95, 96f, 272–273
 General visceral efferent (GVE) fibers, 65–67f, 96, 96f
 Geniculate ganglion, 147f, 153f
 Geniculocalcarine tract, 224–225, 225f
 Genu corpus callosum, 12f
 Germinoma, 85f
 Gerstmann syndrome, 296, 306Q
 Giant cells of Betz, 109
 Glial cells, 62
 Glial filaments, 83
 Glioblastoma multiforme, 85f, 86
 Glioblasts, 62–63
 Gliomas, 83–86, 85f
 Gliosis, 83
 Global aphasia, 305
 Globose nucleus, 134f, 262f
 Globus pallidus, 19f, 43f, 70f, 76f, 250f, 284
 anatomy of, 6, 14f, 15f, 16f, 19f, 186, 188f, 197Q, 250, 251–252, 251f, 252f
 development of, 68, 70

Glomus, 28
 calcified, 33f
 Glossopharyngeal nerve, 154–155, 159Q, 340t
 anatomy of, 2f, 7f, 10, 146–147f, 154–155, 159Q
 characteristics of, 154–155
 clinical correlations for, 155, 159Q
 components of, 155
 inferior salivatory nucleus of, 65
 in parasympathetic nervous system, 272
 Glucose, in cerebrospinal fluid, 30
 Glutamate, 286, 286f, 289Q, 291Q
 in striatal system, 253
 Glycine, 286, 291Q
 Golgi neurons, 80
 Golgi tendon organs (GTOs), 90
 Gracile nucleus, 65f
 Gracile tubercle, 5f, 10
 Granule cells, 240, 261
 Graphesthesia, 300f
 Gray communicating ramus, 96f, 97, 102Q
 Gray matter, 63f
 of brain, 99–100
 Gray ramus, 25f
 Great cerebral vein of Galen, 57Q
 Great vein of Galen, 27f, 46, 49f
 Greater petrosal nerve, 153f
 Guillain–Barré syndrome, 120, 126Q
 Gustatory anesthesia, 239
 Gustatory cortex, 239, 295f, 296
 Gustatory system, 237–239, 238f
 Gyrencephaly, 71
 Gyrus, development of, 71
 Gyrus rectus, 2, 2f, 4f, 20f, 21f

H

Habenular nucleus, 240
 Habenular trigone, 5f, 8
 Habenulointerpeduncular tract, 243, 245Q
 Hair cells, 203, 204f, 211, 212, 212f, 218Q
 Hallpike maneuver, 219Q
 Hearing loss, 154, 206, 210Q
 Hearing tests, 207, 208f, 209Q
 Heart, autonomic innervation of, 270t, 274
 Hemangioblastomas, 85f
 Hematoma. *See* Hemorrhage/hematoma
 Hemianopia
 binasal, 224, 232Q
 bitemporal, 224, 232Q, 233Q
 homonymous, 224, 225, 231, 233Q, 296, 307Q
 Hemiballism, 255
 Hemineglect, 299
 Hemiparesis, 188
 Hemiretina, 222, 223f
 Hemispheric dominance, 299–300, 300f
 Hemispheric syndrome, 265
 Hemorrhage/hematoma
 Duret, 32f
 epidural, 33f, 34f, 45, 53, 53f, 56Q
 intracranial, 52–53, 52–53f
 intraparenchymal, 33f
 subarachnoid, 31t
 subdural, 26, 33f, 52, 53f, 56Q
 Hepatolenticular degeneration, 255, 256Q
 Hereditary spastic paraplegia/diplegia, 119
 Herniation, cerebral, 32, 32–33f, 33, 149, 230, 230f
 Herniation of medulla, 73f
 Herniation of vermis, 73f
 Herpes zoster, 120

- Herpes zoster ophthalmicus, 168
 Heschl's gyrus, 22Q
 Hidrosis, 122
 Hindbrain, development of, 61f, 62
 Hippocampal artery, 43f
 Hippocampal commissure
 anatomy of, 8, 15f
 development of, 71
 Hippocampal formation, 6, 16f, 17f, 18f, 20f, 21f, 22Q,
 192, 240–241, 242f, 243, 245Q
 Hippocampal sulcus, 3f, 4f
 Hippocampus, 250f
 anatomy of, 6, 240, 240f, 242f
 clinical correlations for, 243–244, 245Q
 Hirschsprung disease, 275, 276Q
 Holmes disease, 265
 Holmes–Adie pupil, 231
 Holoprosencephaly, 75
 Homonymous hemianopia, 224, 225, 231, 233Q,
 296, 307Q
 Homonymous quadrantanopia, 225,
 232Q, 296, 307Q
 Homunculi
 motor, 296f, 297
 sensory, 294, 296f
 Horizontal cells, 222
 Horizontal diplopia, 151
 Horner syndrome, 44, 111, 112f, 125Q, 169, 173, 227,
 230f, 232Q, 273, 276Q
 Huntington's disease, 254–255, 256Q,
 288, 289Q
 Hydranencephaly, 75f, 76
 Hydrocephalus, 30–31, 36Q, 75f
 congenital, 75, 75f
 normal-pressure, 30, 307Q
 Hyperacusis, 153
 Hyperreflexia, 119
 Hypertension, benign intracranial, 31, 36Q
 Hypertonia, in upper motor neuron
 disease, 113
 Hypesthesia, 294
 Hypoglossal nerve, 2f, 7f, 10, 146f, 148f, 157–158,
 158f, 341t
 Hypoglossal nucleus, 65, 66, 130f, 131f, 133, 148f
 Hypoglossal trigone, 5f, 10
 Hypokinesia, 254
 Hypophyseal fossa, 25
 Hypophyseal portal system, 195f
 Hypophyseal stalk, 25
 Hypophysis
 anatomy of, 4f, 22Q
 development of, 69, 69f
 tumors of, 85f, 196, 198Q
 Hypothalamic-releasing/release-inhibiting
 factors, 196
 Hypothalamic sulcus, 70f
 Hypothalamospinal tract, 111, 112f, 195
 transection of, 121, 122f
 Hypothalamus, 4f, 8, 11f, 20f, 70f, 189–196, 242
 anatomy of, 189
 in autonomic function, 195
 clinical correlations for, 196
 connections of, 192–194, 193f
 development of, 68
 fiber systems of, 194–195, 195f
 in fluid balance, 196
 in food intake regulation, 196
 nuclei of, 189–192, 190f, 191f
 opioid peptides of, 196, 283, 283f, 284f
 overview of, 189
 in pupillary dilation, 227, 228f
 regions of, 189–192, 190f, 191f
 in temperature regulation, 195–196
 Hypotonia, in cerebellar dysfunction, 264
- I**
 Ideational apraxia, 303, 307Q
 Ideational/sensory apraxia, 294
 Ideomotor apraxia, 303
 Inclusion bodies, 81
 Incus, 203, 209Q
 Indolaminergics, 278
 Inferior anastomotic vein, 49f
 Inferior cerebellar peduncle, 5f, 10, 13f, 18f, 108f, 109,
 131–132f, 133, 134f, 135, 135f, 137f, 259
 Inferior colliculus, 4f, 5f, 9, 18f, 21f, 130f, 137f, 138
 Inferior colliculus nucleus, 137f, 138, 204f, 205
 Inferior frontal gyrus, 2, 3f
 Inferior frontal sulcus, 3f
 Inferior horn, 28, 29f
 Inferior internal parietal artery, 42f
 Inferior oblique, 149
 Inferior olivary nucleus, 12f, 17f, 64, 65f, 131f, 132, 132f,
 143Q, 214, 263
 Inferior ophthalmic vein, 57Q
 Inferior parietal lobe, 3f, 4
 Inferior petrosal sinus, 47
 Inferior rectus, 149
 Inferior sagittal sinus, 46, 49f
 Inferior salivatory nucleus, 65, 130f, 132f,
 133, 148f, 272
 Inferior temporal gyrus, 3f, 5
 Inferior temporal sulcus, 3f
 Inferior vestibular nucleus, 131f, 132f, 133
 Infundibular nucleus, 191f, 192
 Infundibular recess, 9, 29f
 Infundibulum, 3f, 8, 25, 69f, 189
 Inner ear, 203, 211–213, 212f
 Innominate canal, 160Q
 Insomnia, 282
 Insula, 3f, 6, 250f
 Insular cortex, 14f, 19f
 Intention tremor, 264
 Intercostal artery, 40f
 Interfascicular oligodendrocytes, 83
 Intermediate nerve, 2f, 151, 153f
 Intermediate zone, 98f
 Intermediolateral cell column, 273
 Intermediolateral nucleus, 99
 Internal arcuate fibers, 104, 105f, 131, 131f
 Internal auditory meatus, 214
 Internal capsule, 19f, 43f, 70f, 250f, 262f
 anatomy of, 5f, 7f, 8, 13f, 14f, 15f, 16f, 17f,
 19f, 22Q, 33f
 development of, 70
 lesions of, 143Q
 Internal carotid artery, 14f, 41–44, 41f, 48–51f
 Internal cerebral veins, 46, 49f
 Internal ophthalmoplegia, 170Q, 273
 Interneurons, 80, 80f, 222, 270
 Internuclear ophthalmoplegia (INO), 174, 177, 179Q,
 217, 218Q, 229, 230f, 232Q, 273
 Interpeduncular cistern, 27f
 Interpeduncular fossa, 7f, 9, 15f
 Interpeduncular nucleus, 16f, 137f, 139
 Interventricular foramen of Monro, 4f, 9, 27f, 29f
 Intervertebral disk herniation, 124
 Intervertebral foramen, 96
 Intracellular digestion, 81

Intracranial hemorrhage, 52–53, 52–53f
 Intracranial hypertension, benign, 31, 36Q
 Intralaminar neurons, 106
 Intralaminar nucleus, 184, 185f, 186f
 Intramural ganglion, 272
 Intraparenchymal hemorrhage, 33f, 52
 Intraparietal sulcus, 3f
 Intraspinal tumors, 85f
 Iodopsin, 222
 Ipsilateral paralysis, 156

J

Jacksonian seizures, 303
 Jaw jerk reflex, 165, 167, 167f
 Jugular foramen syndrome, 177–178
 Junction scotoma, 224
 Juvenile hereditary lower moron neuron disease, 117
 Juxtaestiform body, 135, 212f, 214, 259

K

Kayser–Fleischer ring, 255
 Kernohan notch, 32f
 Kinesin, 87
 Klüver–Bucy syndrome, 244, 245Q
 Korsakoff syndrome, 244, 245Q
 Kugelberg–Wielander disease, 117, 118f

L

Labbé's vein, 49f
 Labyrinth, 211–213, 212f
 bony, 203
 membranous, 203
 Labyrinthectomy, 217
 Labyrinthine artery, 41f, 44, 56Q
 Labyrinthitis, 217
 Lacrimal gland, 153f
 Lacrimal pathway, 152, 153f
 Lacrimal reflex, 167, 170Q
 Lambert–Eaton myasthenic syndrome, 288, 290Q
 Lamina terminalis, 4f, 8, 71
 organum vasculosum of, 34
 Language deficits, 298. *See also* Aphasia; Speech
 Lateral aperture, 29f
 Lateral conjugate gaze deviation, 297, 306Q
 Lateral corticospinal tract, 109, 110f, 111f, 114Q, 125Q, 130f, 263
 lesions of, 119
 transection of, 121, 122f
 Lateral dorsal nucleus, 184, 185f, 186f
 Lateral eminence, 2f
 Lateral funiculus, 5f, 98f
 Lateral geniculate body, 3f, 5f, 8, 187, 188f, 224, 225f
 Lateral geniculate nucleus, 17f, 20f
 Lateral hemispheric cerebellar pathway, 263
 Lateral horn, 98f, 99
 Lateral hypothalamic nucleus, 190, 190f, 196
 Lateral inferior pontine syndrome, 174, 174f
 Lateral lemniscus, 17f, 21f, 134f, 135, 135f, 137f, 138, 204f, 205
 Lateral medullary syndrome, 172–173, 173f, 179Q
 Lateral midpontine syndrome, 174, 180Q
 Lateral nucleus, 186, 191f
 Lateral occipital gyrus, 3f
 Lateral occipital sulcus, 3f
 Lateral occipitotemporal gyrus, 5
 Lateral olfactory stria, 3f, 236
 Lateral posterior choroidal artery, 43f
 Lateral posterior nucleus, 17f, 184, 185f, 186f

Lateral preoptic nucleus, 189, 190f, 191f
 Lateral pterygoid muscle, 166f, 170Q
 Lateral reticular nucleus, 132
 Lateral spinothalamic tract, 106, 107f, 111f, 114Q, 121f
 lesions of, 118f, 119
 transection of, 121, 122f
 Lateral strabismus, 179Q
 Lateral striate artery, 41f, 48f
 Lateral sulcus, 2f, 3f, 14f
 Lateral superior pontine syndrome, 175, 180Q
 Lateral tegmental area, 282
 Lateral ventricles, 1, 3f, 6–7, 12f, 14–16f, 18f, 20f, 21f, 28, 29f, 43f, 73f, 74f, 75f, 250f
 Lateral vestibular nucleus, 134f, 136
 Lateral zone of hemisphere, 259, 259f
 Left posterior cerebral artery, 303
 Left transverse sinus, 46
 Lenticular nucleus, 5f, 7f
 Lentiform nucleus, 70f, 249, 262f
 Leptomeninges, 60
 Lesser petrosal nerve, 160Q
 Levator palpebrae, 149
 Lewy bodies, 81, 288
 Ligamentum flavum, 25f
 Limbic lobe, 4f, 6
 Limbic midbrain nucleus, 242
 Limbic system, 239–244
 connections, 241–243, 241f
 Lingual gyrus, 3f, 4f, 6, 11f, 225
 Lingual nerve, 152, 153f
 Lipofuscin granules, 81
 Lissencephaly, 71
 Locked-in syndrome, 175
 Locus ceruleus, 9, 138, 242, 281, 281f, 291Q
 Longitudinal fissure, 2f, 14f
 Lou Gehrig disease, 118f, 120, 126Q
 Lower motor neuron, 113
 Lower motor neuron lesions, 113, 117–118, 118f
 hypoglossal neuropathy, 158f
 with upper motor neuron lesions, 120
 vagal neuropathy, 157f
 Lower quadrantanopia, 296
 Lumbar artery, 40f
 Lumbar cistern, 26f, 27
 Lumbar cord, 94f, 95, 100, 102Q
 Lumbar enlargement, 95
 Lumbar vertebrae, 94f, 95
 Lumen of diencephalon, 69f
 Lysosomes, 81

M

Macrogia, 62, 82–83
 Macula lutea, 220
 Malleus, 203
 Mammillary body, 4f, 7f, 8, 11f, 20f, 21f, 68, 74f, 189, 191f, 243, 244, 250f
 Mammillary nucleus, 15f, 189, 191f, 192
 Mammillary peduncle, 193f, 194
 Mammillotegmental tract, 193f, 194
 Mammillothalamic tract, 12f, 15f, 194
 Mandibular nerve, 146–148f, 150, 152f, 162, 163, 163f, 170Q
 Mania, 282
 Marcus Gunn pupil, 230, 230f, 232Q
 Massa intermedia, 15f, 19f, 74f
 Masseter reflex, 167, 167f
 Masticatory muscles, 150, 170Q
 Maxillary artery, 45, 160Q

- Maxillary nerve, 146f, 148f, 150, 160Q, 163, 163f, 168f
 Medial dorsal nucleus, 17f, 19f
 Medial eminence, 2f, 5f
 Medial forebrain bundle, 194, 198Q
 Medial geniculate body, 3f, 5f, 8, 180Q, 187, 188f, 198Q, 204f, 205
 Medial geniculate nucleus, 13f, 17f, 20f
 Medial inferior pontine syndrome, 173, 174f, 179Q
 Medial lemniscus, 12f, 17f, 104, 105f, 131–132f, 134–135f, 135, 137f, 140f, 142, 180Q
 decussation of, 131, 131f
 Medial longitudinal fasciculus, 11f, 17f, 20f, 21f, 111f, 130–132f, 133, 136, 139, 141, 212f, 214
 Medial longitudinal fasciculus syndrome, 177, 218Q, 228, 229, 230f, 232Q
 Medial medullary syndrome, 172, 173f
 Medial midbrain syndrome, 176, 176f
 Medial olfactory stria, 3f
 Medial posterior choroidal artery, 43f
 Medial preoptic nucleus, 191, 191f, 198Q
 Medial rectus muscle, 148
 Medial striate artery of Heubner, 41f, 44
 Medial vestibular nucleus, 131f, 132f, 133, 136
 Median aperture, 27f, 29f
 Median eminence of tuber cinereum, 34
 Median zone of hemisphere, 259, 259f
 Mediodorsal nucleus, 184, 185f, 186f, 198Q
 Medulla oblongata, 2f, 7f, 9–10, 61f, 62, 93, 129–134
 anatomy of, 129–134, 130–132f, 140f
 development of, 61f, 62
 lesions of, 122f
 Medullary reticulospinal tract, 111f
 Medullary stria of thalamus, 8
 Medulloblastoma, 67, 85f, 86, 91Q, 265, 266Q
 Megacolon, 275, 276Q
 Meissner corpuscles, 89, 89f, 105f
 Melanin, 81
 Membranous labyrinth, 203
 Memory loss, topographic, 299
 Ménière disease, 217, 218Q
 Meningeal arteries, 45
 Meningeal ramus, 96f, 97
 Meningeal spaces, 25–27f, 26–28
 Meninges, 24–28, 25–27f, 93
 Meningiomas, 28, 36Q, 85f, 86
 Meningitis, 31–32, 31t
 Meningocele
 cranial, 72–73
 spinal, 71, 72f
 Meningoencephalocele, 72–73, 72f
 Meningohydroencephalocele, 72–73, 72f
 Meningomyelocele, 71, 72f
 Merkel tactile disks, 89
 Meroanencephaly, 72
 Mesencephalic nucleus, 130f, 135f, 139, 147f, 164f, 165, 166, 167f
 Mesencephalic tract, 135f, 139, 147f
 Mesencephalon
 anatomy of, 5f, 9, 137f
 development of, 61, 61f, 62, 67–68, 68f
 lesions of, 175–176
 overview of, 138
 Mesoderm, 58
 Mesolimbic pathway, 281
 Metathalamus, 8, 68
 Metencephalon, 61f, 62, 66–67, 67f
 Meyer loop quadrantanopia, 225, 232Q, 233Q
 Microaneurysms, 52
 Microfilaments, 81
 Microglia, 63, 83, 91Q
 Microgyri, 73f
 Microtubules, 81
 Micturition, 274
 Midbrain. *See* Mesencephalon
 Middle cerebellar peduncle, 5f, 7f, 10, 17f, 134f, 135, 135f, 260, 262f
 Middle cerebral artery, 14f, 41f, 42f, 43f, 44, 48–51f, 302
 occlusion of, 197Q, 302
 rupture of, 53
 Middle ear, 203, 210Q
 Middle frontal gyrus, 2, 3f
 Middle internal frontal artery, 42f
 Middle meningeal artery, 45, 160Q
 rupture of, 53, 53f
 Middle temporal gyrus, 3f, 5
 Millard Gubler syndrome, 179Q
 Mitochondrial transport, 87
 Monoventricle, 76f
 Motor aphasia, 298
 Motor areas, cortical, 295f, 296f, 297
 Motor axons, 82t
 Motor facial nucleus, 130f
 Motor homunculus, 296f, 297
 Motor neuroblasts, 64
 Motor neurons, 80, 80f. *See also* Lower motor neuron; Upper motor neuron
 development of, 77Q
 gamma, 90
 Motor nuclei, 130f, 135f
 Motor root, 2f
 MPTP-induced parkinsonism, 254
 Müller cells, 222
 Multiple sclerosis, 118f, 124, 126Q, 217, 218Q, 230
 Multipolar neurons, 80, 80f
 Muscle(s). *See also specific muscles*
 facial expression, 153
 masticatory, 150, 170Q
 oculomotor, 148–149
 paralysis of, 149, 150, 150f, 229–230, 230f, 233Q
 receptors, 90
 stretch reflex, 90, 91Q
 Mutism, akinetic, 297
 Myasthenia gravis, 288, 291Q
 Myasthenic ptosis, 231
 Myelencephalon, development of, 61f
 Myelin sheath, 80f, 82
 Myelinated fibers, 97
 Myelination, of spinal cord, 64
 Myelopathy, 124
 Myeloschisis, 72
 Myotatic reflex, 96f, 101, 102Q
 Myotomes, 98
- N**
- Nasal glands, 153f
 Neocerebellum, 259
 Neocortex, 70, 70f, 293
 Neostriatum, 249
 Nerve(s). *See also specific nerves*
 cranial, 2f, 7f, 145–161, 339–341t
 peripheral
 lesions of, 120
 regeneration of, 86–87
 tumors of, 83–86, 85f
 spinal, 95–97, 95f, 97f
 terminalis, 145

- Nerve cell. *See* Neurons
- Nerve cell body, 81–82
- Nerve deafness, 206, 209Q
- Nerve fibers, 82, 82t
degeneration of, 86–87
myelinated, 97
regeneration of, 86–87, 91Q
unmyelinated, 97
- Nervous system
autonomic. *See* Autonomic nervous system
central. *See* Brain; Central nervous system;
Spinal cord
development of, 58–78
parasympathetic, 270–272, 270t, 271f
peripheral, 58. *See also* Peripheral nerves
sympathetic, 268–270, 269f, 270t
- Neural crest, 58, 59–60, 60f, 77Q
- Neural fold, 59, 59f, 60f
- Neural groove, 59, 59f
- Neural plate, 58, 59f
- Neural tube
defects, 71–72, 72f
development of, 58–59, 59f, 60f,
61–63, 77Q
wall, 63
- Neurilemmoma. *See* Schwannoma
- Neuroblasts, 62
motor, 64
sensory, 64
- Neurofibrillary tangles, 81
- Neurofilaments, 81
- Neuroglia, 82–86
- Neurohistology, 79–92
- Neurohypophysis, 68, 69. *See also* Hypophysis
- Neuroma, acoustic, 169, 176–177, 177f, 206, 218Q
- Neuromelanin, 81
- Neurons, 79–82
bipolar, 79, 80f
cholinergic, 80, 80f
classification of, 79–80, 80f
degeneration of, 86–87
Golgi, 80
interneurons, 80, 80f
lower motor, 113. *See also* Lower motor
neuron lesions
multipolar, 80, 80f
properties of, 80
pseudounipolar, 96
sensory, 80, 80f
unipolar, 79, 80f
upper motor, 112–113. *See also* Upper motor neuron
lesions
- Neuropeptides
nonopioid, 284, 285f
opioid, 283, 283f
in striatal system, 254
- Neuropore, 59, 59f
- Neurotransmitters, 80, 80f, 268–272, 276Q, 278–292. *See also specific types*
classification, 278
clinical correlations for, 287–288, 289–290Q, 291Q
definition, 278
in pain control, 287–288
of parasympathetic nervous system, 270
pathways for, 278
of striatal system, 253–254
of sympathetic nervous system, 268–270
- Nigrostriatal pathway, 280, 280f
- Nissl substance, 80f, 81
- Nitric oxide, 276Q, 278, 287, 289Q
- Node of Ranvier, 80f, 83
- Noncommunicating hydrocephalus, 30, 36Q, 75
- Nonfluent aphasia, 298
- Nonverbal ideation, 299
- Norepinephrine, 270, 276Q, 281–282, 281f
- Normal-pressure hydrocephalus, 30, 307Q
- Notochord, 69f
- Nuclear bag fibers, 90
- Nuclear chain fibers, 90
- Nuclei. *See also specific nuclei*
motor, 130f
sensory, 130f
- Nucleus ambiguus, 65, 66, 130f, 131f, 132f, 133, 143Q,
148f, 156, 272, 274
- Nucleus cuneatus, 129, 130f, 131f
- Nucleus dorsalis of Clarke, 99
- Nucleus gracilis, 129, 130f, 131f
- Nucleus prepositus, 132f
- Nucleus proprius, 99
- Nucleus pulposus, herniation of, 124
- Nystagmus, 154
caloric, 215f, 216, 218Q
monocular horizontal, 229
postrotational, 215
vestibular, 215
- O**
- Obex, 5f
- Occipital eye fields, 232
- Occipital horn, 28, 29f
- Occipital lobe, 3f, 4f, 5–6
- Occipitotemporal gyrus, 3f, 4f
- Ocular fundus, 220
- Ocular motility centers, 232
- Oculocephalic reflex, 215, 215f
- Oculomotor muscles, 148–149
paralysis of, 149, 150, 150f, 229–230, 230f, 233Q
- Oculomotor nerve, 2f, 7f, 9, 32f, 339t
anatomy of, 148–149, 148f
characteristics of, 148–149
clinical correlations for, 149
paralysis of, 149, 150, 150f, 180Q, 229–230,
230f, 233Q
in parasympathetic nervous system, 272
- Oculomotor nucleus, 68, 69f, 130f, 137f, 139, 143Q, 148f
- Oculomotor ptosis, 149, 230f, 231, 233Q
- Oculosympathetic pathway, 112, 112f
- Oculosympathetic ptosis, 231
- Odontoblasts, 60
- Olfactory bulb, 2f, 6, 61, 236, 237f
- Olfactory nerve, 339t
anatomy of, 2f, 7f, 145–146, 146f
clinical correlations for, 146, 159Q
development of, 61
- Olfactory placodes, 61
- Olfactory receptors, 236, 237f
- Olfactory stria, 3f
- Olfactory structures, 2f, 3f, 6
- Olfactory system
anatomy of, 236–237, 237f
clinical correlations for, 237
- Olfactory tract, 2f, 6, 13f, 236, 237f
- Olfactory trigone, 3f, 6
- Oligodendrocytes, 62, 64, 83, 91Q, 159Q
- Oligodendroglia, 62
- Oligodendroglioma, 85f, 86
- Olive, 2f, 7f, 10, 13f, 36Q
- Olivocerebellar tract, 132f, 261
- Olivocochlear bundle, 206
- Olivopontocerebellar degeneration, 265
- One-and-a-half syndrome, 229

- Open medulla, 65–66, 65f, 66f
 - Operculofrontal artery, 42f, 307Q
 - Ophthalmic artery, 48f, 49f
 - Ophthalmic nerve, 146–148f, 150, 162, 163f, 167, 168f
 - Ophthalmic veins, 57Q
 - Ophthalmoplegia
 - internal, 170Q, 273
 - internuclear, 179Q, 217, 218Q, 229, 230f, 232Q
 - Opioid peptides, 196, 283, 283f
 - Opisthotonos, 216
 - Optic chiasm, 2f, 4f, 7f, 8, 14f, 21f, 32f, 74f, 224
 - Optic chiasma, 69f
 - Optic cup, development of, 69
 - Optic disk, 220
 - choked, 147, 231
 - Optic nerve, 159Q, 224, 339t
 - anatomy of, 2f, 7f, 12f, 13f, 32f, 146–147, 146f
 - characteristics of, 146–147
 - clinical correlations for of, 147
 - Optic radiation, 3f, 19f
 - Optic recess, 9
 - Optic stalk, development of, 69
 - Optic tract, 7f, 15f, 16f, 20f, 21f, 43f, 224, 250f
 - Optic ventricle, 250f
 - Optic vesicles, development of, 69
 - Oral cavity, 69f
 - Orbital gyri, 2
 - Orbitofrontal artery, 42f
 - Orbitofrontal cortex, 239
 - Organ of Corti, 203, 209Q
 - Organum vasculosum of lamina terminalis, 34
 - Ossicles, 203
 - Otic ganglion, 272
 - Otic placodes, 61
 - Otitis media, 206, 209Q
 - Otolithic membrane, 213
 - Otosclerosis, 206
 - Outer ear, 152, 202
- P**
- Pacinian corpuscles, 90, 105f
 - Pain
 - endogenous control system for, 287–288
 - receptors, 89
 - referred, 273
 - visceral, 273
 - Pain transmission, 284
 - rate of, 91Q
 - Palate, 157f
 - Palatine glands, 153f
 - Paleocortex, 70, 293
 - Palsy. *See* Paralysis
 - Papez circuit, 239, 241f, 243, 245Q
 - Papilledema, 147, 231
 - Papilloma, of choroid plexus, 85f
 - Parabrachial nucleus of pons, 239
 - Paracentral artery, 42f
 - Paracentral lobule, 4f, 109, 294, 297
 - ischemia of, 302
 - Paracentral sulcus, 4f
 - Parafascicular nucleus, 184, 185f, 186f
 - Parahippocampal gyrus, 3f, 4f, 6, 21f, 32f, 240, 246Q
 - Paralysis
 - in motor neuron disease, 113, 125Q
 - oculomotor, 149, 150, 150f, 229–230, 230f, 233Q
 - sternocleidomastoid muscle, 156
 - superior oblique muscle, 150f, 159Q
 - trapezius muscle, 156
 - Paramedian midbrain syndrome, 175–176, 176f
 - Paramedian reticular formation, 138
 - Paramedian zone of hemisphere, 259, 259f
 - Parasympathetic nervous system, 270–272, 270t, 271f. *See also* Autonomic nervous system
 - Paraterminal gyrus, 4f, 6
 - Paratrigeminal syndrome, 168
 - Paraventricular nucleus, 191, 191f, 199Q
 - Paravermal spinocerebellar pathway, 263
 - Parietal lobe, 2–5, 3f, 4f, 310Q
 - Parieto-occipital artery, 42f, 43f, 50f
 - Parieto-occipital sulcus, 3f, 4f, 11f, 13f, 42f, 43f
 - Parinaud syndrome, 175, 176f, 179Q, 180Q, 228, 230f
 - Parkinson-plus syndrome, 254
 - Parkinsonism, MPTP-induced, 254
 - Parkinson's disease, 254, 256Q, 288, 289–290Q
 - Parotid gland, 155
 - Pars compacta, 137f, 139, 250–251
 - Pars intermedia, 69f
 - Pars nervosa, 69f
 - Pars opercularis, 3f
 - Pars orbitalis, 3f
 - Pars reticularis, 137f, 139, 251
 - Pars triangularis, 3f
 - Pars tuberalis, 69f
 - Patau syndrome, 75
 - Pedunculopontine nucleus, 251, 253
 - Pedunculus cerebri, 138
 - Penetrating branches of middle cerebral artery, 43f
 - Peptic ulcers, 275, 276Q
 - Peptides
 - nonopioid, 284, 285f
 - opioid, 196, 283, 283f
 - Periaqueductal gray matter, 137f, 139
 - Pericallosal artery, 11f, 42f, 48f, 49f
 - Perikaryon, 81
 - Perilymph, 213
 - Peripheral nerves, 58
 - development of, 58–63
 - lesions of, 120
 - regeneration of, 86–87
 - tumors of, 83–86, 85f
 - Peripheral nervous system, 58
 - development of, 58–63
 - Perlia nucleus, 227
 - Permissive serotonin hypothesis, 282
 - Petrous internal carotid artery, 49f, 50f, 51f
 - pH, of cerebrospinal fluid, 30
 - Pharyngeal hypophysis, 69f
 - Phineas Gage syndrome, 297
 - Phrenic nucleus, 100, 102Q
 - Pia mater, 24, 25f, 66f
 - Pial blood vessels, 66f
 - Pigment cells, 60
 - Pill-rolling tremor, 254
 - Pineal body, 4f, 5f, 8, 11f, 34–35, 68
 - Pineal gland, 18f, 283
 - Pineal recess, 9, 29f
 - Pinealocytes, 34
 - Pinealomas, 35
 - Pituitary adenoma, 196, 198Q
 - Pituitary gland. *See* Hypophysis
 - Placodes, 61
 - Planum temporale, 296
 - Poikilothermia, 192, 199Q
 - Poliomyelitis, 117, 118f
 - Polyhydramnios, 76
 - Polymicrogyria, 74f

- Pons, 61f, 74f
 anatomy of, 7f, 9, 15f, 134–138, 135f, 140f, 180Q
 development of, 66–67, 67f
 overview of, 134–138, 135f
 vascular lesions of, 173–175, 174f
- Pontine artery, 41f, 44
- Pontine center for lateral conjugate gaze, 136, 228–229, 229f
- Pontine cistern, 27f
- Pontine nucleus, 13f, 16f, 67, 67f, 77Q, 136, 262f
- Pontine reticulospinal tract, 111f
- Porencephaly, 75f, 76
- Postcentral gyrus, 2, 3f, 294
- Postcentral sensory cortex, 109
- Postcentral sulcus, 3f
- Posterior cerebral artery, 32f, 41f, 43f, 45, 48f, 50f, 51f, 56Q, 187
 occlusion of, 303
- Posterior choroidal artery, 48f, 50f
- Posterior column nuclei, 64, 98f, 99
- Posterior column syndrome, 118f, 119, 122f, 126Q
- Posterior column transection, 121
- Posterior column–medial lemniscus pathway, 104, 105f
- Posterior commissure, 4f, 8, 11f, 17f, 142
- Posterior communicating artery, 41f, 48–50f, 56Q, 187
 aneurysms of, 149
- Posterior fossa cyst, 74f
- Posterior funiculus, 98f
- Posterior horn, 28, 29f, 63f, 64, 98f, 100
 destruction of, 122, 122f
- Posterior inferior cerebellar artery (PICA) syndrome, 40f, 41f, 44, 48f, 50f, 51f, 56Q, 172–173, 173f, 179Q
- Posterior intermediate septum, 98f
- Posterior intermediate sulcus, 98, 98f
- Posterior internal frontal artery, 42f
- Posterior lateral sulcus, 98
- Posterior lobe of cerebellum, 10, 259, 259f
- Posterior median septum, 98f
- Posterior median sulcus, 63f, 98, 98f
- Posterior meningeal artery, 45
- Posterior midbrain syndrome, 176, 176f
- Posterior nerve root lesion, 122f
- Posterior neuropore, 59, 59f
- Posterior nucleus, 191f, 192, 198Q
- Posterior paracentral lobule, 5
- Posterior parietal artery, 42f
- Posterior perforated substance, 7f, 9
- Posterior ramus, 25f, 96, 96f
- Posterior root, 25f, 96, 96f
- Posterior spinal artery, 39, 40f
 occlusion of, 118f
- Posterior spinocerebellar tract, 106–109, 108f, 111f, 114Q, 121f, 130f, 131f, 133
 lesions of, 118f, 120
 transection of, 121, 122f
- Posterior temporal artery, 42f, 43f
- Posterior thoracic nucleus, 106
- Posterior trigeminothalamic tract, 165, 170Q
- Posterior vermis syndrome, 264, 266Q
- Posterolateral sulcus, 98f
- Posterolateral tract of Lissauer, 98f, 106, 111f, 112, 114Q, 147f
- Postermarginal nucleus, 99
- Postganglionic neurons, 268
- Postinfectious polyneuritis, 120
- Postrotational nystagmus, 215
- Precentral gyrus, 1, 3f, 263, 297
- Precentral motor cortex, 109
- Precentral sulcus, 3f
- Precuneus, 4, 4f, 11f
- Prefrontal cortex, 295f, 297
- Preganglionic neurons, 268
- Premotor cortex, 109, 297
- Preolantic artery, 42f
- Preoptic recess, 29f
- Presbycusis, 206, 210Q
- Pretecal nucleus, 142, 226
- Pretectum, 138
- Primary auditory cortex, 295f, 296
- Primary olfactory cortex, 237
- Primary somatosensory cortex, 294, 295f
- Primary visual cortex, 295, 295f
- Primitive node, 59f
- Primitive streak, 59f
- Progressive infantile muscular atrophy, 117, 118f
- Progressive supranuclear palsy, 254
- Prolactin-inhibiting factor, 192
- Prosencephalon, 68
 development of, 61, 61f
- Prosopagnosia, 303
- Protoplasmic astrocytes, 82
- Pseudocoma, 175
- Pseudotumor cerebri, 31, 36Q
- Pseudounipolar cells, 60
- Pseudounipolar ganglion cells, 238
- Pseudounipolar neurons, 96
- Pterygopalatine ganglion, 272
- Pterygopalatine glands, 153f
- Ptosis, 149, 230f, 231, 233Q
- Pulvinar, 5f, 8, 184, 185f, 186f, 197Q
- Pulvinar nucleus, 18f, 19f, 22Q
- Pupil(s)
 Adie, 231
 afferent, 230, 230f
 Argyll Robertson, 230, 230f, 232Q
 Marcus Gunn, 230, 230f, 232Q
 unequal, 229, 232Q
- Pupillary convergence-accommodation reaction, 227–228, 228f
- Pupillary dilation pathway, 227, 228f
- Pupillary light reflex, 147, 225–226, 226f
- Purkinje cells, 261, 262f, 266Q
- Putamen, 6, 14f, 15f, 16f, 17f, 19f, 22Q, 43f, 70f, 76f, 250, 250f, 252f
- Pyramid, 7f, 9, 65f
- Pyramidal cells, 32f, 241
- Pyramidal decussation, 2f, 7f, 130f, 132
- Pyramidal tracts, 131f, 132, 132f
 anterior, 109, 110f, 114–115Q
 lateral, 109, 110f, 114–115Q
 lesions of, 119
- Q**
- Quadrantanopia
 homonymous, 225, 232Q, 296, 307Q
 lower, 296
 Meyer loop, 225, 232Q, 233Q
- R**
- Rachischisis, 72f
- Radial glial cells, 62
- Raeder syndrome, 168
- Rami communicantes, 25f
- Raphe nuclei, 137f, 139, 242, 282, 282f
- Rathke pouch, 69, 69f
- Raynaud disease, 275, 276Q
- Receptive dysprosody, 299, 305, 308Q

Receptors

- cutaneous mechanoreceptors, 89–90, 89f
- muscle, 90
- olfactory, 236, 237f
- pain, 89
- sensory, 89–90
- taste, 237, 238f
- temperature, 89
- Red nucleus, 12f, 16f, 20f, 68, 69f, 137f, 141, 143Q, 176, 262f, 263
- Referred visceral pain, 273
- Reflex
 - Achilles, 102Q
 - ankle jerk, 102Q
 - carotid sinus, 155
 - corneal, 152f, 153, 159Q, 163, 165, 167, 233Q
 - gag, 155, 159Q
 - jaw jerk, 165, 167, 167f
 - lacrimal, 167, 170Q
 - masseter, 167, 167f
 - muscle stretch, 90, 91Q, 102Q
 - myotatic, 96f, 101, 102Q
 - oculocephalic, 215, 215f
 - pupillary light, 147, 225–226, 226f
 - trigeminal, 167
 - vestibulo-ocular, 215–216, 215f
- Relay nuclei, 132–133
- Restiform body, 259
- Reticular formation, 129
- Retina, 220–223, 221f
 - development of, 77Q
- Retrobulbar neuritis, 230
- Retrograde degeneration, 86
- Rexed laminae, 98f, 99–100
- Rhinal sulcus, 70
- Rhodopsin, 222
- Rhombencephalon, 64
 - development of, 61f, 62
- Rhombic lips, 67
- Rhomboid fossa, 5f, 9, 10
- Right transverse sinus, 46
- Rigidity
 - decerebrate, 216
 - decorticate, 216
 - gamma, 216
- Riley-Day syndrome, 275, 276Q
- Rinne tests, 207, 208f, 209Q
- Rods, 222
- Rolandic artery, 42f
- Romberg sign, 119
- Roof plate, 63f, 64, 66, 66f
- Rostral interstitial nucleus, 228
- Rostral medulla, 65–66, 65f, 66f
- Rostral sympathetic trunk, 274
- Rostrum of corpus callosum, 12f
- Rubrospinal tract, 111, 111f, 262f

S

- Saccular aneurysms, 52, 52f
- Saccule, 212, 212f
- Sacral cord, 94f, 95, 100, 102Q
- Sacral parasympathetic nucleus, 99
- Sacral vertebrae, 94f, 95
- Salivatory nuclei, 65, 130f, 132f, 133, 136, 148f
- Satellite cells, 83
- Scala media, 203
- Scala tympani, 203
- Scala vestibuli, 203
- Schwabach test, 207
- Schwann cells, 60, 64, 80f, 83, 91Q

- regeneration of, 86
- Schwannoma, 85f, 86, 91Q
 - acoustic, 169, 176–177, 177f, 206, 217, 218Q
- Sclerotome, 98
- Second-order neurons
 - anterior spinocerebellar tract, 107f, 109
 - anterior spinothalamic tract, 106
 - anterior trigeminothalamic tract, 165
 - cuneocerebellar tract, 108f, 109
 - lateral spinothalamic tract, 106, 107f
 - posterior column–medial lemniscus pathway, 104, 105f
 - posterior spinocerebellar tract, 107, 108f
 - posterior trigeminothalamic tract, 165
- Secondary somatosensory cortex, 294, 295f
- Secondary visual cortex, 295, 295f
- Segmental arteries, 39
- Seizures, Jacksonian, 303
- Semicircular canal, 66f, 212, 212f
- Semicircular ducts, 212, 212f
- Semilunar ganglion, 162
- Sensorineural deafness, 207, 210Q
- Sensory apraxia, 294, 307Q
- Sensory areas, cortical, 294–297, 295f, 296f
- Sensory axons, 82t
- Sensory disorders, 121–124
 - location of, 122f
- Sensory dysprosody, 296
- Sensory homunculus, 294, 296f
- Sensory neuroblasts, 64
- Sensory neurons, 80, 80f
- Sensory nuclei, 130f, 147f
- Sensory pathways, lesions of, 118f, 119–120
- Sensory receptors, 89–90
- Septal nucleus, 14f, 280
- Septal vein, 46, 49f
- Septum pellucidum, 4f, 11f, 14f
- Serotonin, 282–283, 282f, 289Q
- Sexually dimorphic nucleus, 191, 198Q
- Shingles, 120
- Sigmoid sinus, 46, 49f, 51f
- Sinuses, venous dural, 46–47, 47f, 49f, 51f, 56Q, 57Q
- Skull fracture, 35
- Small intensely fluorescent cells, 270
- Smooth muscle, 66f
- Solitary nucleus, 64, 65, 77Q, 130–132f, 131f, 133, 134f, 147f, 239
- Solitary tract, 131f, 132f, 133, 134f, 147f, 153f
- Soma, 81
- Somatic motor nucleus, 99
- Somatic striated muscle (tongue), 66f
- Somatosensory association cortex, 294–296, 295f
- Somatosensory cortex, 104, 105f, 294, 295f
- Somatostatin, 284, 285f
- Spastic paresis, 113
- Spasticity, in upper motor neuron disease, 113, 119
- Spatial perception, 299
- Special somatic afferent (SSA) fibers, 65, 65–67f
- Special visceral afferent (SVA) fibers, 64, 65, 65–67f, 66
- Special visceral efferent (SVE) fibers, 65, 65–67f, 77Q, 162, 166
- Speech areas
 - Broca, 295f, 297–298, 298f, 306Q, 307Q
 - Wernicke, 5, 295f, 296, 298, 298f, 307Q
- Speech deficits, 297, 298. *See also* Aphasia
- Spental artery, 43f
- Sphenoid bone, 69f
- Sphenoparietal sinus, 46
- Spina bifida, 71–72, 72f
- Spinal accessory nerve, 100

- Spinal accessory nucleus, 100, 102Q, 148f
- Spinal artery occlusion, 118f
- Spinal border cells, 99, 109
- Spinal cistern, 27f
- Spinal cord, 93–103
- arteries of, 39, 40f
 - attachments of, 93
 - complete transection of, 122, 122f
 - development of, 63–64, 63f
 - divisions of, 94f, 100, 102Q
 - external morphology of, 93–98
 - hemisection of, 118f, 121, 122f, 126Q
 - internal morphology of, 98–100, 98f, 121f
 - lesions of, 117–128
 - lower motor neuron, 113, 117–118, 118f
 - upper motor neuron, 112–113, 114Q, 119
 - location of, 93, 94f
 - myelination of, 64
 - shape of, 95
 - tethered, 76, 123
 - transverse section of, 98f, 121f
 - tumors of, 85f
 - veins of, 40
 - white matter of, 63
- Spinal epidural space, 26
- Spinal ganglion, 25f, 96, 96f
- with sensory nerve, 63f
- Spinal ganglion cell, 105f
- Spinal lemniscus, 131–132f, 132, 134f, 135, 135f, 137f, 142
- Spinal nerve(s), 95–97, 95f, 97f
- Spinal nerve roots, 95–97
- Spinal nucleus, 131f
- Spinal tracts, 104–116
- ascending, 104–109, 105f, 107f, 111f
 - descending, 109–111, 110–111f, 112f
- Spinal trigeminal nucleus, 65, 130–132f, 134f, 136, 147f, 164, 164f, 165, 167f
- Spinal trigeminal tract, 130–132f, 134f, 136, 147f, 163, 164, 164f
- Spine. *See also* Vertebrae
- divisions of, 94f, 95
 - tumors of, 85f
- Spinocerebellum, 258
- Spinocervical tract, 111
- Spinomesencephalic tract, 111
- Spinoreticular tract, 111
- Spinospinal tract, 111f
- Spinotectal tract, 111f
- Spinothalamic tract, 130f
- Spiral ganglion, 132f, 203
- Spiral organ, 203, 209Q
- Splenium corpus callosum, 3f, 12f
- Split-brain syndrome, 301–302, 301f
- St. Vitus dance, 255, 256Q
- Stapedial nerve, 153f
- Stapedius muscle, 203
- Stapes, 203
- Statognosis, 294
- Stereognosis, 114Q, 294
- Sternocleidomastoid muscle, 156
- paralysis of, 156
- Stomodeum, 69
- Strabismus
- convergent, 151
 - lateral, 179Q
- Straight sinus, 27f, 46, 47f, 49f, 51f, 56Q, 57Q, 74f
- Stria medullaris, 4f, 5f, 9, 10, 19f, 240, 242, 245Q
- Stria terminalis, 5f, 16f, 194, 198Q, 242, 245Q
- Striatum, 249, 250f, 251, 251f, 280
- Stylomastoid foramen, 151, 160Q
- Stylopharyngeus muscle, 155
- Subacute combined degeneration, 118f, 123, 126Q
- Subarachnoid cisterns, 27, 27f
- Subarachnoid hemorrhage, 31t
- Subarachnoid space, 25, 25f, 26–27, 27f, 72f, 93
- Subcallosal area, 4f, 6
- Subclavian steal syndrome, 178
- Subcommissural organ, 34
- Subcortical center for lateral conjugate gaze, 228–229, 229f
- Subcortical center for vertical conjugate gaze, 228
- Subdural hemorrhage/hematoma, 26, 33f, 52, 53f, 56Q
- Subdural space, 26
- Subfalcial herniation, 32f, 33
- Subfornical organ, 34
- Subiculum, 6, 241
- Sublingual glands, 152, 153f
- Submandibular glands, 152, 153f
- Submandibular pathway, 152–153, 153f
- Subparietal sulcus, 4f
- Substance P, 284, 285f, 289Q
- Substantia gelatinosa, 99, 147f
- Substantia nigra, 12f, 13f, 15f, 16f, 20f, 21f, 43f, 68, 69f, 137f, 138, 139, 142, 250f, 251, 252, 284
- Subthalamic nucleus, 6, 8, 13f, 15f, 43f, 250, 250f, 251, 251f, 252f
- Subthalamus, 8, 70f
- development of, 68
- Sulci, development of, 71
- Sulcus limitans, 5f, 9, 10, 63f, 64, 65f, 66f, 131f
- Sulcus of corpus callosum, 4f
- Superficial cerebral veins, 45
- Superficial reflexes, loss of, 119
- Superior anastomotic vein, 49f
- Superior cerebellar artery, 41f, 44, 48f, 50f, 51f, 56Q
- Superior cerebellar peduncle, 5f, 10, 12f, 18f, 108f, 109, 134f, 135, 135f, 137f, 260, 262f
- decussation of, 11f, 17f, 137f, 139
- Superior cerebral veins, 49f, 51f, 57Q
- rupture of, 52, 53f
- Superior cervical ganglion, 112, 112f, 227, 228f
- Superior cistern, 27f, 28, 37Q
- Superior colliculus, 4f, 5f, 9, 18f, 20f, 69f, 130f, 137f, 139
- Superior frontal gyrus, 2, 3f, 4f
- Superior frontal sulcus, 3f
- Superior ganglion, 147f
- Superior internal parietal artery, 42f
- Superior medullary vellum, 5f, 130f
- Superior oblique muscle paralysis, 150f, 159Q
- Superior olivary nucleus, 135, 135f, 204f, 205
- Superior ophthalmic vein, 49f, 57Q
- Superior orbital fissure, 160Q, 162
- Superior parietal lobe, 2, 3f
- Superior parietal lobule, 294, 295f
- Superior petrosal sinus, 47
- Superior rectus, 149
- Superior sagittal sinus, 24–25, 27f, 36Q, 46, 49f, 51f, 57Q, 74f
- Superior salivatory nucleus, 130f, 134f, 136, 148f, 152, 153f, 272
- Superior temporal gyrus, 3f, 5
- Superior temporal sulcus, 3f
- Superior vestibular nucleus, 136
- Suprachiasmatic nucleus, 191, 198Q
- Supramarginal gyrus, 3f, 4, 294–295, 295f
- Supraoptic nucleus, 191, 191f, 199Q
- Supraopticohypophyseal tract, 194
- Suprapineal recess, 9, 29f

Sweat glands, 270t, 276Q
 Swinging flashlight test, 230, 230f
 Sydenham chorea, 255, 256Q
 Sympathetic apraxia, 297, 298
 Sympathetic nervous system, 268–270, 269f, 270t
 Synapses, 82
 chemical, 82
 electrical, 82
 Syringomyelia, 118f, 122f, 123–124, 125Q
 Syringomyelic syndrome, 122f

T

Tabes dorsalis, 118f, 119, 125Q
 Tactile agnosia, 294, 307Q
 Tanyocytes, 62, 91Q
 Tardive dyskinesia, 255, 256Q
 Taste bud cell of tongue, 66f
 Taste buds, 155
 Taste perception, 239
 Taste receptors, 237, 238f
 Tectal (quadrigeminal) plate, 73f
 Tectospinal tract, 111f
 Tectum, 138
 Tegmentum, 134, 138
 Tela choroidea, 8, 9, 65f, 66, 66f, 67f
 Telencephalon
 anatomy of, 1–8
 development of, 61, 61f, 62, 70–71, 70f, 77Q
 Temperature receptors, 89
 Temporal artery, 51f
 Temporal horn, 15f, 20f, 21f, 28, 29f
 Temporal lobe, 3f, 4f, 5
 Temporal pole, 3f
 Tensor tympani muscle, 203
 Tentorium cerebelli, 10, 25, 32f
 Terminal vein, 46
 Tertiary visual cortex, 295, 295f
 Tethered spinal cord, 76, 123
 Thalamic aphasia, 305
 Thalamic syndrome, 189
 Thalamoperforating artery, 50f
 Thalamostriate vein, 46, 49f
 Thalamus, 4f, 5f, 8, 11f, 12f, 13f, 16f, 33f, 43f, 61f, 70f, 76f, 183–189, 250, 250f
 anatomy of, 183–188, 185f, 186f, 188f
 blood supply of, 187
 boundaries of, 183
 clinical correlations for, 188–189
 connections of, 184, 185f, 186f
 development of, 68
 internal capsule of
 blood supply, 187
 infarction, 188, 197Q
 nuclei of, 184–187, 185f, 186f
 overview of, 183
 striatal system and, 251–252
 Thiamine deficiency
 Korsakoff syndrome and, 244, 245Q
 neuropathy due to, 118f, 123, 126Q
 Wernicke encephalopathy and, 196, 199Q, 233Q, 245Q
 Third-order neurons
 anterior spinocerebellar tract, 106, 107f
 anterior spinothalamic tract, 106
 anterior trigeminothalamic tract, 165
 lateral spinothalamic tract, 106, 107f
 posterior column–medial lemniscus pathway, 104, 105f
 posterior spinocerebellar tract, 108f
 posterior trigeminothalamic tract, 165
 Third ventricle, 4f, 5f, 8–9, 15f, 17f, 19f, 27f, 28, 29f, 43f, 70f, 73f, 74f, 75f
 colloid cyst of, 85f
 Thoracic cord, 94f, 95, 100
 Thoracic syndrome, 122f
 Thoracic vertebrae, 94f, 95
 Thrombosis, cavernous sinus, 56Q
 Tic douloureux, 168, 170Q
 Tinnitus, 154
 Tongue, 157–158, 158f
 Tonsil, 10, 11f
 Tonsillar herniation, 32f, 33
 Topographic memory loss, 299
 TORCH syndrome, 76
 Tractus retroflexus, 243, 245Q
 Transcortical mixed aphasia, 305
 Transcortical motor aphasia, 305
 Transcortical sensory aphasia, 305
 Tranforaminal herniation, 32f, 33
 Transtentorial herniation, 32f, 33, 149, 230–231, 230f, 232Q
 Transverse pontine artery, 44
 Transverse pontine fibers, 135f
 Transverse sinuses, 46, 49f, 51f
 Transverse temporal gyrus of Heschl, 5, 5f, 204f, 206
 Trapezius muscle, 156
 paralysis of, 156
 Trapezoid body, 134, 134f, 135f, 204f, 205
 Trigeminal ganglion, 147f, 163
 Trigeminal motor nucleus, 136, 148f, 166, 166f
 Trigeminal nerve, 2f, 7f, 9, 150–151, 162–171, 339t
 anatomy of, 146–148f, 150–151
 characteristics of, 150–151
 clinical correlations for, 151
 dermatomes of, 163f
 divisions of, 162–163, 163f
 lesions of, 168–169
 motor nucleus of, 135f, 136
 overview of, 162
 sensory nuclei of, 130f, 135f, 136, 148f, 165–166, 166f
 Trigeminal neuralgia, 168, 170Q
 Trigeminal reflexes, 167
 Trigemino-cerebellar fibers, 166
 Trigeminothalamic tracts, 163–165, 164f, 170Q
 Trigone, 28, 29f
 Trochlear nerve, 149–150, 339t
 anatomy of, 2f, 5f, 7f, 9, 18f, 23Q, 36Q, 143Q, 146f, 149–150
 clinical correlations for of, 150
 Trochlear nucleus, 68, 130f, 137f, 139, 148f
 Trolard's vein, 49f
 Tuber cinereum, 5f, 7f, 8, 189
 median eminence of, 34
 Tuberohypophyseal tract, 194, 195f, 281
 Tumors
 brain, 36Q, 83–86, 85f, 91Q, 264–265, 266Q
 hypophyseal, 85f
 peripheral nervous system, 83–86, 85f
 spinal/spinal cord, 85f
 Tuning fork tests, 207, 208f
 Tympanic membrane, 203

U

Ulcers, peptic, 275
 Uncal herniation, 32f, 33, 149, 230, 230f, 232Q
 Uncus, 2f, 3f, 4f, 240
 Unipolar neurons, 70f, 79
 Upper brainstem lesions, 122f
 Upper motor neuron(s), 112
 in micturition, 274

Upper motor neuron lesions, 79Q, 113, 114Q, 119, 307Q
 contralateral, 297
 hypoglossal neuropathy, 158f
 with lower motor neuron lesions, 120
 vagal neuropathy, 157f
 Utricle, 212, 212f
 Uvula, 157f

V

Vagal nerve, 2f, 7f, 10, 155–156, 157f, 160Q, 340–341t
 anatomy of, 147f, 148f, 155–156, 157f
 clinical correlations for, 156
 dorsal motor nucleus of, 65
 in parasympathetic nervous system, 272
 Vagal nucleus, 148f
 Vagal trigone, 5f, 10
 Vagus nerve, 340–341t
 Vascular lesions
 brainstem, 172–173, 174f
 pons, 173–175, 174f
 Vasoactive intestinal polypeptide, 276Q
 Veins
 autonomic innervation of, 270t, 274
 of brain, 45–46, 51f
 of spinal cord, 40
 Vena terminalis, 245Q
 Venous angle, 46, 49f, 57Q
 Venous dural sinuses, 46–47, 47f, 49f, 51f, 56Q, 57Q
 Ventral amygdalofugal pathway, 194, 242, 246Q
 Ventral anterior nucleus, 184, 185f, 186f
 Ventral cochlear nucleus, 132f, 136, 204f, 205
 Ventral lateral nucleus, 15f, 185f, 186, 186f, 197Q, 198Q, 262f, 263
 Ventral pallidum, 254
 Ventral posterior nucleus, 185f, 186–187, 186f, 197Q
 Ventral posteroinferior nucleus, 185f, 186f, 187, 212f, 214
 Ventral posterolateral nucleus, 16f, 104, 105f, 185f, 186, 186f, 212f, 214
 Ventral posteromedial nucleus, 16f, 184, 185f, 186f, 239
 Ventral striatopallidal complex, 254
 Ventral striatum, 254
 Ventral tegmental area, 242
 Ventral thalamus, 8
 Ventricle(s), 28–29
 fourth
 anatomy of, 4f, 11f, 27f, 29, 29f, 66, 66f
 development of, 66
 lateral, 1, 3f, 6–7, 12f, 14–16f, 18f, 20f, 21f, 28, 29f
 third, 4f, 5f, 8–9, 15f, 17f, 19f, 27f, 28, 29f
 colloid cyst of, 85f
 Ventricular lumen, 72f
 Ventromedial nucleus, 191, 191f, 199Q
 Vermal nodulus, 10
 Vernet syndrome, 177–178
 Vertebrae. *See also under* Spinal; Spine
 position of, 93, 94f
 segments of, 93, 94f
 Vertebral angiography, 48f, 49, 50–51f, 50f
 Vertebral artery, 25f, 39, 40f, 41, 41f, 44, 48f, 50f, 51f
 Vertebral veins, 25f
 Vertical diplopia, 150
 Vertigo, 154, 216
 benign positional, 217, 218Q
 Vesicles, development of, 61–62, 61f
 Vestibular area, 5f
 Vestibular cortex, 295f, 296

Vestibular ganglion, 132f, 212f
 Vestibular nerve, 130f, 147f, 154, 214, 340t
 Vestibular nucleus, 65, 66, 212f, 214, 262
 Vestibular nystagmus, 215
 Vestibular schwannoma, 168–169, 206, 217, 218Q
 Vestibular system, 211–219
 central connections in, 212f, 214
 disorders of, 216–217, 218Q
 efferent vestibular connections in, 214
 labyrinth in, 211–213, 212f
 medial longitudinal fasciculus in, 214
 overview of, 211
 vestibulo-ocular reflexes in, 215–216
 Vestibulo-ocular reflexes, 215–216, 215f
 Vestibulocerebellar pathway, 262
 Vestibulocochlear nerve, 2f, 9, 27
 Vestibulocochlear nucleus, 134f
 Vestibulospinal tract, 111, 111f, 114Q, 212f, 214
 Viral meningitis, 31–32, 31t
 Visceral epithelium, 66f
 Visceral pain, 273
 Visual association cortex, 295f, 296
 Visual cortex, 225, 295, 295f
 Visual fields, 222–223, 223f
 defects in, 225, 231, 232Q, 233Q, 295
 Visual pathway, 223f, 224–225
 Visual radiation, 307Q
 Visual system, 220–235
 clinical correlations for, 229–231
 convergence-accommodation reaction in, 227–228, 228f
 ocular motility centers in, 228–229
 pupillary dilation pathway in, 227
 pupillary light reflexes/pathway in, 147, 225–226, 226f
 retina in, 220–223, 221f
 Vitamin B₁₂ deficiency
 Korsakoff syndrome and, 244, 245Q
 neuropathy due to, 118f, 123, 126Q
 Wernicke encephalopathy and, 196, 199Q, 233Q, 245Q
 Vomiting center, 10

W

Wacky-wobbly-wet mnemonic, 30
 Wallenberg syndrome, 172–173, 173f, 179Q
 Wallerian degeneration, 84f, 86, 91Q
 Watershed infarcts, 305
 Weber syndrome, 176, 176f, 179Q
 Weber tests, 207, 208f, 209Q
 Werdnig–Hoffmann disease, 117, 118f, 126Q
 Wernicke aphasia, 298, 304, 307Q, 308Q
 Wernicke encephalopathy, 196, 199Q, 233Q, 245Q, 308Q
 Korsakoff syndrome and, 245Q
 Wernicke speech area, 5, 295f, 298, 298f, 307Q
 White communicating ramus, 96f, 97
 White matter, 63f
 of brain, 7, 98f, 100
 of spinal cord, 63
 White ramus, 25f
 Wilson disease, 255, 256Q

Z

Zona incerta, 8